



## Evaluation of Surface Contamination of Bacteria in Various Dental Clinics with Special Reference to Obligate and Facultative Anaerobic Spore Bearing Bacilli

Kannan I<sup>1\*</sup>, Thenmozhivalli PR<sup>2</sup>, Paul Sony<sup>3</sup>, Malini Rose<sup>4</sup>

<sup>1,2,3,4</sup> Department of Microbiology, Tagore Medical College and Hospital, Chennai – 600127

\*Corresponding author's E-mail: [microbiology@tagoremch.com](mailto:microbiology@tagoremch.com)

<i>Article History</i>	<b>Abstract</b>
Received: 06 June 2023 Revised: 05 Sept 2023 Accepted: 25 Nov 2023	<p><i>The occupational health and safety is an important prerequisite in dental clinic setup for wellbeing of both the doctor and patient. Both the patient and dentist are always at the risk of infections. Aim and objectives: There is no proper literature on the survey of bacterial spores, especially of Clostridium species in dental clinics. Hence an attempt has been made in the present pilot study to evaluate the surface contamination with special reference to bacterial spores. Materials and methods: Various dental clinics from Chennai city, India were selected for the present study. Samples were collected from two clinics each from endodontic, prosthodontic, orthodontic, and periodontic. In each clinic important places were selected for sampling. The samples were collected in the form of swabs. The swabs thus obtained were inoculated into Robertson Cooked Meat Medium and was incubated in anaerobic condition at 37°C for 7 days. Each day the tubes were examined for turbidity and colour change and were noted. At the end of 7th day, the smear was prepared from each tube and gram staining was performed. The gram stained slides were examined microscopically for the presence of spore bearing bacilli especially with special reference to terminal spore bearing bacilli. Results and conclusion: From the present study it is clear that the dental clinics invariably possess a lot of aerobic and anaerobic spores irrespective of stringent disinfection procedures. Hence it is mandatory for the dental clinics to undergo periodical microbiological surveillance and to take proper steps in the control of bacterial spores.</i></p>
<b>CC License</b> CC-BY-NC-SA 4.0	<b>Keywords:</b> Surface contamination, dental clinics, anaerobic spores, Clostridium tetani

### 1. Introduction

The occupational health and safety are an important prerequisite in dental clinic setup for well-being of both the doctor and patient. Both the patient and dentist are always at the risk of infections. A lot of research has been conducted to estimate the microbial contamination of dental units. It has been proved that infections spread through blood and saliva through direct or indirect contact, droplets, aerosols, or contaminated instruments and equipment.<sup>1</sup> The researchers are much concerned with the microorganisms arises from the mouth of the patients.<sup>2, 3</sup> Most of the works are concerned with the identification of microorganisms in aerosol or surface with special reference to contamination due to dental procedures.<sup>4, 5</sup> There are also lot of works concerned with the waterline contamination in the dental units.<sup>6, 7</sup> The infection control practice in dentistry is mainly concerned with the microorganisms arises from the patient or from the water source.<sup>8</sup> Hence the approach towards the infection control mainly relies on use of disinfection methods.

The global incidence of tetanus is still estimated at one million cases annually, with a case fatality ratio ranging from 6% to 72%.<sup>9</sup> Hence the infection control methods should help to remove the anaerobic spores also. However, the infection control methods are helpful mostly in the control of microorganism arises due to various dental procedures. There are no evidences to prove that they manage to remove the surface contamination occurred by external sources especially the spores. The spore bearing microorganisms in a hospital environment are always a problem and they arise mainly due to the contamination from the external environment. The personnel who enter into the dental clinic may bring the microorganisms and spores from the outside environment. The bacterial spores may not be removed completely by the disinfection process normally adopted in dental clinics.

There is no proper literature on the survey of bacterial spores, especially of Clostridium species in dental clinics. Hence an attempt has been made in the present pilot study to evaluate the surface contamination with special reference to bacterial spores.

## 2. Materials And Methods

Dental clinics: Various dental clinics from Chennai city were selected for the present study. Samples were collected from two clinics each from endodontic, prosthodontic, orthodontic, and periodontic. In each clinic important sites (Table 1) were selected for sampling.

**TABLE 1.** Risk factors, complications and oral alterations in patients with CKD.


<b>Endodontic clinic</b>	Dental chair, Side tray, Light handle, Floor, Suction tip, Mouth mirror, Tap, Spit out, Triple syringe, Waiting area, Operator's chair
<b>Prosthodontic clinic</b>	Mask, Dental chair, Side tray Spit out, Floor, Dust bin, Light handle, Suction tip, Triple syringe, Waiting area floor, Waiting area chair, Operator's chair
<b>Periodontic clinic</b>	Dental chair, Side tray, Light handle, Floor Scaler tip, Tap, Spit out, Triple syringe
<b>Orthodontic clinic</b>	Dental chair, Side tray, Floor, Tap, Spit out, Triple syringe, Waiting area, Operator's chair, Floor, Booster bottle, Trolley, Window

**Sample collection:** The samples (N=43) were collected in the form of swabs. The sterile swabs were dipped in sterile saline prior to the collection of surface samples. The moist swab was rubbed against the surface with the swirling movement for 30 seconds. Then collected swabs were placed in sterile test tubes and were transported to the lab immediately for further analysis.

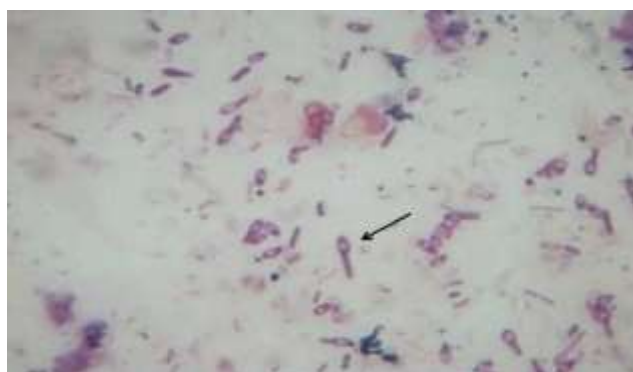**Isolation and identification:** The swabs thus obtained were inoculated into Robertson Cooked Meat Medium (HiMedia) and was incubated in anaerobic condition at 37°C for 7 days. Each day the tubes were examined for turbidity and colour change and were noted. At the end of 7th day the smear was prepared from each tube and gram staining was performed. The gram stained slides were examined microscopically for the presence of spore bearing bacilli especially with special reference to terminal spore bearing bacilli.

## 3. Results and Discussion

At the end of 7th day tubes were finally checked for the turbidity and colour change. Some of the tubes showed turbidity and black indicating the growth of anaerobic bacteria (Figure 1).



**Fig 1:** Robertson cooked meat medium showing the turbidity and black colour



**Fig 2:** Gram stained smear showing the bacilli with terminal bulged spore along with facultative anaerobic bacilli

A smear was prepared from the broth of all tubes irrespective of turbidity and gram staining is performed to visualize the spore bearing bacteria. Some of the smears showed the presence of aerobic spore bearing bacteria (Facultative anaerobic bacteria). Some smears showed the gram positive bacilli with terminal bulged spore whose morphology resembled that of *Clostridium tetani* (Fig 2).

**TABLE 2.** Results obtained from Endodontic clinic.

Site	Clinic 1		Clinic 2	
	Culture result	Smear	Culture result	Smear
Dental chair	Turbidity and blackening	Bacteria morphologically resembling <i>C. tetani</i>	Turbid	Aerobic spore bearer
Side tray	Turbidity and blackening	Bacteria morphologically resembling <i>C. tetani</i>	No turbidity and no colour	No bacteria
Light handle	No turbidity and no colour	No bacteria	No turbidity and no colour	No bacteria
Floor	No turbidity and no colour	No bacteria	No turbidity and no colour	No bacteria
Suction tip	No turbidity and no colour	No bacteria	No turbidity and no colour	No bacteria
Mouth mirror	No turbidity and no colour	No bacteria	No turbidity and no colour	No bacteria
Tap	Turbidity and blackening	Bacteria morphologically resembling <i>C. tetani</i>	No turbidity and no colour	No bacteria
Spit out	Clear	No bacteria	Clear	No bacteria
Triple syringe	Clear	Few aerobic spore bearers	Clear	No bacteria
Waiting area	Clear	No bacteria	Clear	No bacteria
Operator's chair	Turbid	Lot of aerobic spore bearers	Turbid	Lot of aerobic spore bearers

**TABLE 3.** Results obtained from Prosthodontic clinic

Site	Clinic 1		Clinic 2	
	Culture Result	Smear	Culture Result	Smear
Mask	No turbidity		Turbid	Aerobic spore bearer
and no colour	No bacteria	No turbidity and	No turbidity and no colour	No bacteria
no colour	No bacteria		No turbidity and no colour	No bacteria
Dental chair	No turbidity and no colour	No bacteria	No turbidity and no colour	No bacteria
Side tray	Turbidity and no colour	Aerobic spore bearers	No turbidity and no colour	No bacteria
spore bearers			No turbidity and no colour	No bacteria
Spit out	Turbidity and		No turbidity and no colour	No bacteria
blackening	Aerobic spore bearers	Turbid	Clear	No bacteria
Floor	Turbidity and		Clear	No bacteria
blackening	Bacteria morphologically		Clear	No bacteria
resembling <i>C. tetani</i>	Turbid	Lot of aerobic spore bearers	Turbid	Lot of aerobic spore bearers

**TABLE 4:** Results obtained from Periodontic clinic

Site	Clinic 1		Clinic 2	
	Culture result	Smear	Culture result	Smear
Dental chair	No turbidity and no colour	No bacteria	Turbid	Lot of aerobic spore bearers
Side tray	Turbid	Aerobic spore bearers	Turbid and black	Morphology resembling <i>C. tetani</i>
Light handle	Turbid	Morphology resembling <i>C. tetani</i>	Turbid	Morphology resembling <i>C. tetani</i>
Floor	Turbid	Morphology resembling <i>C. tetani</i>	Turbid	Morphology resembling <i>C. tetani</i>
Scaler tip	No turbidity and no colour	No bacteria	Turbid	Lot of aerobic spore bearers
Tap	Turbid	Lot of aerobic spore bearers	Turbid	Lot of aerobic spore bearers
Spit out	No turbidity and no colour	No bacteria	Turbid	No bacteria
Triple syringe	Clear	No bacteria	Clear	No bacteria

**TABLE 5:** Results obtained from orthodontic clini

Site	Clinic 1		Clinic 2	
	Culture result	Smear	Culture result	Smear
Dental chair	Turbid and black	Morphology resembling <i>C. tetani</i> along with lot of aerobic spore bearers	Turbid	Aerobic spore bearers
Side tray	Turbid	Lot of aerobic spore bearers	Turbid	Lot of aerobic spore bearers
Floor	Turbid	Lot of aerobic spore bearers	Turbid	Lot of aerobic spore bearers
Tap	Turbid and black	Lot of aerobic spore bearers	Turbid	Lot of aerobic spore bearers
Spit out	Turbid	Lot of aerobic spore bearers	Turbid	Lot of aerobic spore bearer
Triple syringe	Turbid	Aerobic spore bearers	Turbid	Aerobic spore bearers
Waiting area	Turbid and black	Lot of aerobic spore bearers	Turbid	Lot of aerobic spore bearers
Operator's chair	Turbid and black	Morphology resembling <i>C. tetani</i> .	Turbid and black	Morphology resembling <i>C. tetani</i>
Floor	Turbid and black	Morphology resembling <i>C. tetani</i>	Turbid and black	Morphology resembling <i>C. tetani</i>
Booster bottle	Turbid and black	Morphology resembling <i>C. tetani</i>	Turbid and black	Morphology resembling <i>C. tetani</i>
Trolley	Turbid	Aerobic spore bearers	Turbid and black	Aerobic spore bearers
Window	Turbid and black	Morphology resembling <i>C. tetani</i>	Turbid and black	Morphology resembling <i>C. tetani</i>

The Table 2 depicts the results obtained from two endodontic clinics. The first clinic showed the presence of bacterial resembling *Clostridium tetani* in the dental chair, side tray and tap. The second clinic showed some aerobic spore bearers

The Table 3 gives the results obtained prosodontic clinic. The first clinic showed the presence of bacteria resembling *C. tetani* in floor and dust bin. The second clinic showed the presence of bacteria resembling *C. tetani* in dental chair, side tray and dust bin. Both the clinics showed the presence of lot of aerobic spore bearers.

The Table 4 shows the results obtained from periodontic clinics. The first clinic showed the presence of bacteria morphologically resembling *C. tetani* in light handle and floor. The second clinic showed

the presence of bacteria morphologically resembling *C. tetani* in side tray, light handle and floor. Both the clinics also showed the presence of lot of aerobic spore bearers.

The Table 5 shows the results obtained from orthodontic clinics. The first clinic showed the presence of bacteria morphologically resembling *C. tetani* in dental chair, operator's chair, floor, booster bottle and window. The second clinic showed the presence of bacteria in morphologically resembling *C. tetani* in operator's chair, floor, booster bottle and window. Both the clinics also showed the presence of lot of aerobic spore bearers.

The results obtained from the present study clearly shows that anaerobic spores are prevalent in various dental clinics irrespective the disinfection procedures adopted. Almost all the clinics showed the presence of bacteria morphologically resembling *C. tetani*. Certain clinics even showed their presence in the side tray where the instruments are kept for invasive dental procedures.

Eventhough vaccine is available for tetanus; still the disease remains a threat throughout the world in health care units.<sup>10</sup> Tetanus still occurs sporadically especially in developing countries and can affect even fully immunized persons who fail to develop or maintain adequate immunity with the booster doses of vaccine.<sup>11, 12</sup> *C. tetani* predominantly present in soil and can enter into the dental clinic through various routes. The *C. tetani* spore can enter into the body of human undergoing various dental procedures thus can pose the danger of tetanus infection. Tetanus management is very difficult both in terms of materials and manpower.<sup>13, 14</sup> Overall mortality is approximately 10-50%, however, in certain age groups like neonates it is as high as 90-95%.<sup>15</sup>

#### 4. Conclusion

From the present study it is clear that the dental clinics invariably possess a lot of aerobic and anaerobic spores irrespective of stringent disinfection procedures. Hence it is mandatory for the dental clinics to undergo periodical microbiological surveillance and to take proper steps in the control of bacterial spores. Dental clinics should undergo a sterilization process which should also include fumigation followed by screening for the bacterial spores. Lack of spores is the indication of thorough sterilization of the dental clinics and hence the safety of patients.

#### Acknowledgements

We thank Prof. J. Mala, Chairperson, Tagore group of colleges, for providing necessary facilities for the present study. We are thankful to Dr. T. N. Swaminathan, Advisor and Dr. Chitraa R. Chandran, Principal, Tagore Dental College and Hospital for their kind support and encouragement.

Conflict of interest: No

#### References:

1. Merchant VA. Herpesvirus and other micro-organisms of concern in dentistry. *Dent Clin North Am* 1991; 35:283-98
2. Grenier D. Quantitative analysis of bacterial aerosols in two different dental clinic environments. *Appl Environ Microbiol* 1995; 61:3165-68
3. Osorio R, Toledano M, Liebana J, Rosales JI, Lozano JA. Environmental microbial contamination. Pilot study in a dental surgery. *Int Dent J* 1995; 45:352-57
4. Piazza M, Guadagnino V, Picciotto L, Borgia G, Nappa S. Contamination by hepatitis B surface antigen in dental surgeries. *BMJ* 1987; 295:473-74
5. Legnani P, Checchi L, Pelliccioni GA, D'Achille C. Atmospheric contamination during dental procedures. *Quintessence International* 1994; 25:435-39
6. Atlas RM, Williams JF, Huntington MK. Legionella contamination of dental-unit waters. *Appl Environ Microbiol* 1995; 61: 1208-13
7. Pankhurst CL, Philpott-Howard JN. The microbiological quality of water in dental chair units. *J Hosp Infect* 1993; 23: 167-74
8. Centre for Disease Control and Prevention. Recommended infection-control practices for dentistry. *MMWR Morbid Mortal Wkly Rep* 1993; 42:1-12
9. Oladiran I, Meier DE, Ojelade AA, Olaolorun DA, Adeniran A, Tarpley JL: Tetanus continuing problem in the developing world. *World J Surg* 2002, 26(10):1282-85
10. Oladiran I, Meier DE, Ojelade AA, Olaolorun DA, Adeniran A, Tarpley JL: Tetanus continuing problem in the developing world. *World J Surg* 2002; 26(10):1282-85
11. Lau LG, Kong KO, Chew PH: A ten-year retrospective study of tetanus at a general hospital in Malaysia. *Singapore Med J* 2001; 42(8):346-50
12. Joshi S, Agarwal B, Malla G, Karmacharya B: Complete elimination of tetanus is still elusive in developing countries: a review of adult tetanus cases from referral hospital in Eastern Nepal. *Kathmandu Univ Med J.* 2007; 5(3):378-81
13. Mchembe MD, Mwafongo V: Tetanus and its treatment outcome in Dares Salaam: need for male vaccination. *East African Journal of Public Health* 2005; 2: 22-23

14. Edlich RF, Hill LG, Mahler CA, Cox MJ, Becker DG, Horowitz JH: Management and prevention of tetanus. J Long Term Eff Med Implants 2003; 13(3):139-54
15. Bhatia R, Parbhakar S, Grover VK: Tetanus. Neurol India 2002; 50:398-407