

available at www.sciencedirect.com
journal homepage: www.europeanurology.com/eufocus



Prostate Cancer

Limitations of Prostate Biopsy in Detection of Cribriform and Intraductal Prostate Cancer

Rui M. Bernardino^{a,b,*}, Rashid K. Sayyid^a, Katherine Lajkosz^c, Zizo Al-Daqqaq^d,
Jessica G. Cockburn^a, Julian Chavarriaga^a, Shideh Abedi^a, Ricardo Leão^e, Alejandro Berlin^{f,g},
Theodorus van der Kwast^h, Neil E. Fleshner^a

^aDivision of Urology, Department of Surgical Oncology, University of Toronto, Princess Margaret Cancer Centre, Toronto, Canada; ^bComputational and Experimental Biology Group, NOVA Medical School, Universidade NOVA de Lisboa, Lisbon, Portugal; ^cDepartment of Statistics, Princess Margaret Cancer Center, Toronto, Canada; ^dTemerty Faculty of Medicine, University of Toronto, Toronto, Canada; ^eHospital CUF, Faculty of Medicine, University of Coimbra, Coimbra, Portugal; ^fDepartment of Radiation Oncology, University of Toronto, Toronto, Canada; ^gRadiation Medicine Program, Princess Margaret Cancer Centre, Toronto, Canada; ^hDepartment of Laboratory Medicine and Pathobiology, University of Toronto, Toronto, Canada

Article info

Article history:

Accepted August 31, 2023

Associate Editor: Christian Gratzke

Keywords:

Prostatic neoplasms
Prostate biopsy
Sensitivity

Abstract

Background: The presence of cribriform morphology and intraductal carcinoma (IDC) in prostate biopsies and radical prostatectomy specimens is an adverse prognostic feature that can be used to guide treatment decisions.

Objective: To assess how accurately biopsies can detect cribriform morphology and IDC cancer by examining matched biopsy and prostatectomy samples.

Design, setting, and participants: Patients who underwent radical prostatectomy at The Princess Margaret Cancer Centre between January 2015 and December 2022 and had cribriform morphology and/or IDC in the surgical specimen were included in the study.

Outcome measurements and statistical analysis: We used detection sensitivity to evaluate the level of agreement between biopsy and prostatectomy samples regarding the presence of cribriform morphology and IDC.

Results and limitations: Of the 287 men who underwent radical prostatectomy, 241 (84%) had cribriform morphology and 161 (56%) had IDC on final pathology. The sensitivity of prostate biopsy, using radical prostatectomy as the reference, was 42.4% (95% confidence interval [CI] 36–49%) for detection of cribriform morphology and 44.1% (95% CI 36–52%) for detection of IDC. The sensitivity of prostate biopsy for detection of either IDC or cribriform morphology was 52.5% (95% CI 47–58%). Among patients who underwent multiparametric magnetic resonance imaging–guided biopsies, the sensitivity was 54% (95% CI 39–68%) for detection of cribriform morphology and 37% (95% CI 19–58%) for detection of IDC.

Conclusions: Biopsy has low sensitivity for detecting cribriform morphology and IDC. These limitations should be incorporated into clinical decision-making. Biomarkers for better detection of these histological patterns are needed.

* Corresponding author. Division of Urology, University of Toronto, Princess Margaret Cancer Centre, 700 University Avenue, Toronto, Ontario M5G 1Z5, Canada. Tel. +1 416 9462899; Fax: +1 416 9466590.

E-mail address: ruimbernardino@gmail.com (R.M. Bernardino).

<https://doi.org/10.1016/j.euf.2023.08.010>

2405-4569/© 2023 European Association of Urology. Published by Elsevier B.V. All rights reserved.

Please cite this article as: R.M. Bernardino, R.K. Sayyid, K. Lajkosz et al., Limitations of Prostate Biopsy in Detection of Cribriform and Intraductal Prostate Cancer, Eur Urol Focus (2023), <https://doi.org/10.1016/j.euf.2023.08.010>

Patient summary: Prostate biopsy is not an accurate method for detecting two specific types of prostate cancer cells, called cribriform pattern and intraductal prostate cancer, which are associated with unfavorable prognosis.

© 2023 European Association of Urology. Published by Elsevier B.V. All rights reserved.

1. Introduction

The International Society of Urological Pathology (ISUP) 2019 consensus conference [1] and the Genitourinary Pathology Society white paper [2] on prostate cancer (PCa) mandated routine reporting of cribriform growth pattern (Crib) and intraductal carcinoma (IDC). These patterns are recognized as biologically aggressive forms of PCa and molecular analyses have revealed genomic traits and instability characteristic of aggressive disease. The presence of these patterns at radical prostatectomy (RP) is associated with biochemical recurrence (BCR), metastasis, and disease-specific mortality [3–5].

While detection of Crib and IDC at RP can aid in prognostication, the possibility of influencing treatment decisions has led to a focus on identifying these patterns in prostate biopsies. The presence of IDC and Crib in biopsy samples is associated with BCR and cancer-specific mortality [6,7]. In this regard, the presence of these patterns should exclude patients from active surveillance according to the latest European Association of Urology guidelines [8].

Studies reporting the frequency of both IDC and Crib in prostate biopsy and RP samples have shown a significant difference in prevalence between the sample types. IDC prevalence was 13.7% in biopsy samples and 31.1% in RP specimens [9]. Crib prevalence was 8.9% (10) in prostate biopsies [10] and 25% in RP specimens [11]. The differences in the frequency of IDC and Crib findings between biopsy and RP samples in these small studies suggest significant underestimation of both entities in biopsies, most likely because of sampling errors.

To date, only three studies have addressed the sensitivity of detecting IDC and Crib in biopsies [12–14]. However, these studies were limited by small sample sizes and they aggregated IDC and Crib into one histopathological construct. The aim of the present study was to assess how well biopsy (both systematic biopsy [SBx] and multiparametric magnetic resonance imaging [MRI]-targeted biopsy [TBx]) can detect IDC and Crib individually in paired biopsy and RP samples. We hypothesized that prostate biopsy is not an accurate method for IDC/Crib detection.

2. Patients and methods

2.1. Study design, setting, and participants

Patients with biological samples banked at the McCain Genitourinary Biobank who underwent RP at The Princess Margaret Cancer Centre between January 2015 and December 2022 and had Crib and/or IDC in the surgical specimen were included in the study (Fig. 1). The presence or absence of IDC and Crib in biopsies and RP specimens was adopted as a mandatory element in synoptic reporting in the Department of Pathology in 2015. All pathological slides were read by urogenital pathologists, but not re-reviewed as part of this study. For men who

underwent several biopsies before RP, the latest biopsy before surgery was considered. We excluded patients whose biopsy reports did not specifically reference the presence or absence of IDC and Crib. Although there may have been minor differences in methodology, our institution's regular practice involves obtaining at least 12 cores according to a standard sextant map ultrasound-guided biopsies, and a minimum of three cores from each target for MRI fusion TBx. All patients were offered pre-biopsy MRI, in accordance with current guidelines [8]. The decision to proceed with MRI versus upfront biopsy was made via a shared decision-making process with the patient, depending on the patient's anxiety level, the waiting time, and whether the post-test result would alter performance of a biopsy. If MRI showed a positive lesion (Prostate Imaging-Reporting and Data System [PI-RADS] score of ≥ 3), patients were typically offered a combined biopsy approach. Select patients with a prior negative SBx may have undergone subsequent TBx alone. A MAGNETOM Verio 3-T system with a four-channel, phased-array surface coil is used in our institution to perform MRI. The reporting system used is PI-RADS v2. The study received institutional review board approval (CAPCR: 22-5908). Informed consent was not required.

2.2. Study outcomes

The aim of this study was to assess the performance characteristics of prostate biopsies for detection of IDC and/or Crib in patients with these patterns in their RP specimen. We also investigated whether MRI fusion biopsy improves the sensitivity of SBx for detection of these patterns. Sensitivity and specificity were calculated for the entire cohort and were further stratified by SBx or fusion biopsy approach. As a secondary objective, we compared the prevalence of unfavorable pathological features in men for whom IDC and/or Crib was identified in their biopsy samples to those who did not exhibit these architectural features. We also examined rates of post-RP failure for patients with IDC and Crib at biopsy, defined as time to BCR (2 consecutive postoperative serum prostate-specific antigen [PSA] levels >0.2 ng/ml) and evaluated predictors of IDC/Crib at prostate biopsy.

2.3. Study variables

IDC was defined as lumen-spanning proliferation of carcinoma cells distending antecedent ducts or glands. Crib was defined as an expansile area of carcinoma cells without intervening stroma or vasculature and at least the size of an average (200 μ m in diameter) benign gland and with multiple punched-out lumina. Immunostaining for basal cell markers to help distinguish between IDC and Crib was performed on a case-by-case basis [13].

Patient age, PSA before RP, PI-RADS score, biopsy approach (transrectal ultrasound-guided template or MRI fusion), and biopsy and RP grade group (GG) were reported.

2.4. Statistical analysis

Summary statistics were used to describe continuous and categorical variables. Comparison of categorical variables was conducted using χ^2 or Fisher's exact tests. For parametric and nonparametric comparisons of continuous variables, the t test and Mann-Whitney U test, respectively, were used. Univariable logistic regression was used to predict

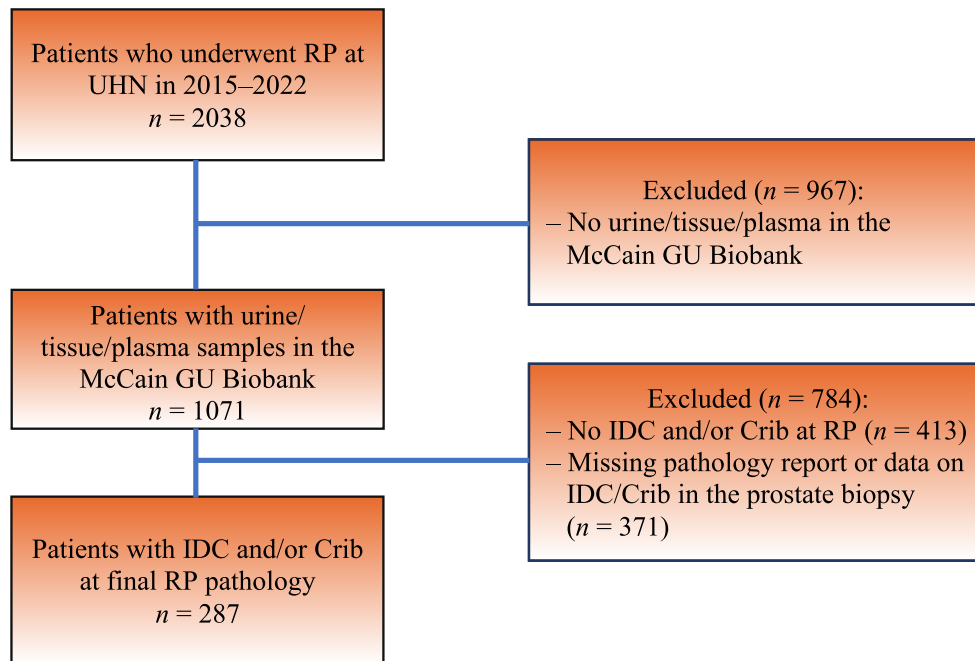


Fig. 1 – Flowchart of patient selection. Crib = cribriform morphology; GU = genitourinary; IDC = intraductal carcinoma; RP = radical prostatectomy; UHN = University Health Network.

the odds of biopsy detection of IDC/Crib. All predictors were modeled as continuous variables, except for the number of previous biopsies which was modeled as 0 versus >1. PSA was log-transformed as its distribution in the cohort was skewed. Age at RP, log PSA before RP, percentage Gleason grade 4, number of cores sampled, number of positive cores, number of previous biopsies, and the highest percentage of core involved by tumor (HPCI) were included. Only variables that were significant on univariable analysis ($p < 0.05$) were included in the final multivariable logistic regression model. Time-to-event analysis was performed using the Kaplan-Meier method.

All statistical analyses were performed using R v4.2.0 (R Foundation for Statistical Computing, Vienna, Austria). All hypothesis tests were two-sided and a p value < 0.05 was considered statistically significant.

3. Results

The study cohort consisted of 287 patients with IDC and/or Crib at RP pathology (Fig. 1). The median patient age was 64.6 yr (interquartile range 59.9–69.0). Median serum PSA before RP was 8.1 ng/ml (interquartile range 5.9–11.9). Among the prostate biopsy specimens, 79 (28%) had IDC and 106 (39%) had Crib; among the RP specimens, 161 (56%) had IDC and 241 (84%) had Crib. SBx was performed in 224 patients (78%) and TBx in 63 (22%; Table 1). In total 54 patients (19%) had multiple sets of biopsies. None of them exhibited IDC/Crib at first biopsy.

The sensitivity of biopsy for individual detection of Crib and IDC confirmed on RP was 42.4% (95% confidence interval [CI] 36–49%) and 44.1% (95% CI 36–52%), respectively. The biopsy sensitivity for detecting either pattern was 52.5% (95% CI 47–58%; Table 2).

The specificity of biopsy for individual detection of Crib and IDC confirmed on RP was 79.1% (95% CI 64–90%) and

93.6% (95% CI 88–97%), respectively. One patient with Crib (out of 9 with a false-positive biopsy) and two patients with IDC (out of 8 with a false-positive biopsy) would meet the criteria for active surveillance according to current guidelines [8] (Supplementary Table 1).

In the TBx group, biopsy sensitivity was 54% (95% CI 39–68%) for Crib and 37% (95% CI 19–58%) for IDC detection. In the SBx-only group, biopsy sensitivity was 39.1% (95% CI 32–47%) for Crib and 45.5% (95% CI 37–54%) for IDC detection (Table 2).

The sensitivity for detection of either IDC or Crib marginally increased from 50.7% (95% CI 44–57%) to 58.7% (95% CI 46–71%) in the group with MRI-fusion biopsy over SBx alone (Table 2). We also compared biopsy sensitivity for detection of IDC, Crib, and IDC and/or Crib for (1) the full cohort versus SBx only, (2) the full cohort versus TBx, and (3) SBx only versus TBx. TBx resulted in a nonsignificant increase in biopsy sensitivity of approximately 10% across all scenarios ($p > 0.08$) and a nonsignificant decrease of 8% ($p > 0.5$) for specific detection of IDC.

We also interrogated baseline differences between true-positive and false-negative biopsies for IDC/Crib (Table 3). In our cohort, the mean number of positive cores significantly differed between the groups with IDC-positive biopsies and IDC-negative biopsies (7.6 vs 6.6; $p = 0.02$) but not between the groups with Crib-positive biopsies and Crib-negative (7.5 vs 6.6; $p = 0.07$). The mean number of positive cores also differed significantly between the group with positive biopsy for either IDC or Crib and the group with IDC- and Crib-negative biopsy (7.4 vs 6.4; $p = 0.03$). In the SBx-only group, the number of positive cores differed between subgroups with IDC-positive versus IDC-negative biopsies (7.8 vs 6.2; $p = 0.001$), Crib-positive versus

Table 1 – Baseline patient characteristics

Parameter	Result
Median age, yr (IQR)	64.6 (59.9–69.0)
Median preoperative PSA, ng/ml (IQR)	8.1 (5.9–11.9)
MRI PI-RADS score, n (%)	
1–3	6 (9)
4–5	65 (92)
Biopsy type, n (%)	
Systematic	224 (78)
MRI-targeted	63 (22)
Number of previous biopsies, n (%)	
0	233 (81)
1	35 (12)
2	16 (6)
3	3 (1)
Biopsy grade group, n (%)	
Grade group 1	13 (5)
Grade group 2	167 (58)
Grade group 3	62 (22)
Grade group 4	30 (11)
Grade group 5	14 (5)
IDC on biopsy, n (%)	
Present	79 (28)
Absent	207 (72)
Not available	1
Cribriform pattern on biopsy, n (%)	
Present	106 (39)
Absent	166 (61)
Not available	15
Pathologic stage on RP, n (%)	
pT2	104 (36)
pT3a	128 (45)
≥pT3b	55 (19)
Pathologic grade group on RP, n (%)	
Grade group 1	5 (2)
Grade group 2	153 (54)
Grade group 3	81 (29)
Grade group 4	12 (4)
Grade group 5	20 (7)
IDC on RP pathology, n (%)	
Yes	161 (56)
No	126 (44)
Cribriform pattern on RP pathology, n (%)	
Yes	241 (84)
No	46 (16)
Positive margins, n (%)	
Yes	97 (34)
No	190 (66)
Pelvic lymph node–positive, n (%)	
Yes	23 (8)
No	264 (92)

IDC = intraductal carcinoma; IQR = interquartile range; MRI = magnetic resonance imaging; PI-RADS = Prostate Imaging-Reporting and Data System; PSA = prostate-specific antigen; RP = radical prostatectomy.

Table 2 – Sensitivity of prostate biopsy by approach

Histology	Sensitivity, % (95% confidence interval)		
	PBx	SBx	TBx
IDC	44.1 (36–52)	45.5 (37–54)	37.0 (19–58)
Cribriform	42.4 (36–49)	39.1 (32–47)	54.0 (39–68)
Either IDC or cribriform	52.5 (47–58)	50.7 (44–57)	58.7 (46–71)

IDC = intraductal carcinoma; PBx = prostate biopsy without discrimination between SBx or TBx; SBx = systematic biopsy; TBx = magnetic resonance imaging–targeted biopsy.

Crib-negative biopsies (7.4 vs 6.3; $p = 0.04$), and negative biopsies versus either IDC- or Crib-positive biopsies (7.3 vs 6.1, $p = 0.02$).

PI-RADS scores of 4–5 were significantly more frequent for Crib-positive than for Crib-negative biopsies (30.2% vs 19.3%; $p = 0.05$) but not for IDC-positive versus IDC-

negative biopsies (16.5% vs 25.1%; $p = 0.16$). Notably, more patients with IDC at biopsy had GG ≥ 3 at biopsy (51.9% vs 31.5%; $p = 0.002$) and RP (47.5% vs 37.2%; $p = 0.002$). Similarly, more patients with Crib at biopsy had GG ≥ 3 at biopsy (61.3% vs 21.2%; $p = 0.001$) and RP (59.6% vs 28.2%; $p = 0.001$; [Table 3](#)). Comparison of final pathological stage revealed that pT3 (31.6% vs 14.5%; $p = 0.002$) and positive lymph nodes (15.2% vs 5.3%; $p = 0.01$) were significantly more common for patients with IDC-positive biopsy findings. These trends were not observed for Crib ([Table 3](#)).

In the multivariable model, age, percentage Gleason grade 4 at biopsy, and HPCI were all independently associated with IDC/Crib at biopsy. Specifically, age (odds ratio 1.05, 95% CI 1.01–1.11; $p = 0.03$), percentage Gleason grade 4 at biopsy (odds ratio 1.04, 95% CI 1.03–1.05; $p = 0.001$), and HPCI (odds ratio 1.03, 95% CI 1.03–1.05; $p < 0.001$) were associated with higher odds of IDC/Crib at biopsy ([Table 4](#)).

Analysis of time to BCR after RP revealed that the probability of 1-yr, 3-yr, and 5-yr BCR-free survival was lower for patients with IDC ($p = 0.003$), for patients with Crib ($p < 0.001$), and for patients with either IDC and/or Crib ($p < 0.001$) on prostate biopsy in comparison to those without either or both features ([Fig. 2](#)).

4. Discussion

In this study involving 287 individuals with IDC and or/Crib at RP, we observed that the biopsy detection sensitivity was poor, at 44.1% for IDC and 42.4% for Crib individually, and slightly higher when considering IDC and/or Crib together, at 52.5%.

The frequency of PI-RADS 4 or 5 lesions on MRI did not differ significantly between the IDC-positive and IDC-negative biopsy groups. However, patients with Crib-positive biopsies were more likely to have PI-RADS 4 or 5 lesions than those with Crib-negative biopsies. MRI fusion TBx led to a nonsignificant increase in biopsy sensitivity of approximately 10% across all scenarios, except for detection of IDC, for which it demonstrated a nonsignificant decrease in sensitivity of 8%. Prendeville et al [15] concluded that MRI/ultrasound fusion TBx was associated with a significant increase in detection of IDC/Crib in comparison to sextant SBx of MRI-negative regions. However, they were unable to correlate their findings to final histopathology, so evaluation of the sensitivity of MRI for IDC/Crib detection was not possible [15].

There are controversial results regarding the ability of MRI to predict IDC/Crib presence in RP specimens. Mikoshi et al [16] reported that MRI detectability was not related to either the presence or the percentage of IDC. They concluded that the MRI detectability of clinically significant PCa (csPCa) was strongly associated with the relative area fractions of cancer cells, stroma, and luminal spaces in PCa rather than conventional histopathological parameters. Conversely, Cai et al [17] found that MRI has high sensitivity for IDC/Crib detection. However, the problem lies in the difference between sensitivity and positive predictive value (PPV). Although the MRI sensitivity for IDC/Crib is high, the PPV of abnormal MRI remains at 28.5%, meaning that among cases with abnormal MRI for a lesion, IDC/Crib is found in only 29% of cases at RP [18]. This does not repre-

Table 3 – Baseline patient characteristics stratified by biopsy findings

Variable	IDC		p value ^a	Cribriform pattern		p value ^a	Either IDC or cribriform pattern		p value ^a
	Positive (n = 79)	Negative (n = 207)		Positive (n = 106)	Negative (n = 166)		Positive (n = 149)	Negative (n = 135)	
Median age, yr (IQR)	64.7 (48.0–77.1)	64.6 (43.0–75.0)	0.62	66.2 (48.0–77.1)	63.9 (43.0–75.7)	0.07	65.3 (48.0–77.1)	63.9 (43.0–74.9)	0.02
Median preoperative PSA, ng/ml (IQR)	8.5 (5.9–12.6)	8.1 (5.9–11.6)	0.53	8.9 (6.4–14.4)	7.8 (5.6–10.7)	0.03	8.4 (6.0–13.0)	7.9 (5.6–10.9)	0.18
Biopsy type, n (%)									
Systematic	65 (82.3)	158 (76.3)	0.35	78 (73.6)	133 (80.1)	0.27	112 (75.2)	109 (80.7)	0.32
MRI-targeted	14 (17.7)	49 (23.7)		28 (26.4)	33 (19.9)		37 (24.8)	26 (19.3)	
Biopsy grade group, n (%)									
Grade group 1	0	13 (6.3)	0.002	0	13 (7.9)	<0.001	0	13 (9.7)	<0.001
Grade group 2	38 (48.1)	128 (62.1)		41 (38.7)	117 (70.9)		67 (45.0)	97 (72.4)	
Grade group 3	23 (29.1)	39 (18.9)		38 (35.8)	22 (13.3)		47 (31.5)	15 (11.2)	
Grade group 4	10 (12.7)	20 (9.7)		19 (17.9)	9 (5.5)		23 (15.4)	7 (5.2)	
Grade group 5	8 (10.1)	6 (2.9)		8 (7.5)	4 (2.4)		12 (8.1)	2 (1.5)	
Not available	0	1		0	1		0	1	
Pathologic RP grade group, n (%)									
Grade group 1	1 (1.3)	4 (2.0)	<0.001	1 (1.0)	4 (2.4)	<0.001	1 (0.7)	4 (3.0)	<0.001
Grade group 2	29 (37.2)	123 (60.3)		34 (32.7)	111 (67.7)		56 (38.1)	94 (70.7)	
Grade group 3	24 (30.8)	57 (27.9)		43 (41.3)	36 (22.0)		54 (36.7)	27 (20.3)	
Grade group 4	5 (6.4)	7 (3.4)		7 (6.7)	4 (2.4)		8 (5.4)	4 (3.0)	
Grade group 5	8 (10.3)	12 (5.9)		12 (11.5)	6 (3.7)		17 (11.6)	3 (2.3)	
Not assigned ^b	12 (15.1)	4 (1.4)		9 (8.5)	5 (3.0)		13 (8.7)	3 (2.2)	
MRI PI-RADS score, n (%)									
1–3	1 (1.3)	5 (2.4)	0.16	1 (0.9)	5 (3.0)	0.05	2 (1.3)	4 (3)	0.21
4–5	13 (16.5)	52 (25.1)		32 (30.2)	32 (19.3)		39 (26.2)	26 (19.3)	
Not performed	65	150		73	129		108	105	
Pelvic lymph node–positive, n (%)									
Yes	12 (15.2)	11 (5.3)	0.01	12 (11.3)	9 (5.4)	0.12	17 (11.4)	6 (4.4)	0.05
No	67 (84.8)	196 (94.7)		94 (88.7)	157 (94.6)		132 (88.6)	129 (95.6)	
Positive margins, n (%)									
Yes	25 (31.6)	72 (34.8)	0.72	36 (34.0)	57 (34.3)	1	50 (33.6)	46 (34.1)	1
No	54 (68.4)	135 (65.2)		70 (66.0)	109 (65.7)		99 (66.4)	89 (65.9)	
Pathologic RP stage, n (%)									
pT1–2	54 (68.4)	177 (85.5)	0.002	82 (77.4)	137 (82.5)	0.37	112 (75.2)	117 (86.7)	0.02
≥pT3 or worse	25 (31.6)	30 (14.5)		25 (31.6)	29 (17.5)		37 (24.8)	18 (13.3)	

IDC = intraductal carcinoma; IQR = interquartile range; MRI = magnetic resonance imaging; PI-RADS = Prostate Imaging-Reporting and Data System; PSA = prostate-specific antigen; RP = radical prostatectomy.

^a Statistically significant values are denoted in bold font.

^b Patients received neoadjuvant hormone therapy.

Table 4 – Univariable and multivariable logistic regression analysis evaluating predictors of intraductal carcinoma/cribriform pattern at prostate biopsy

Variable	Univariable regression		Multivariable regression	
	OR (95% CI)	p value ^a	OR (95% CI)	p value ^a
Age at RP	1.04 (1.00–1.08)	0.04	1.05 (1.01–1.11)	0.03
Log PSA before RP	1.23 (0.85–1.80)	0.28		
Percentage grade group 4	1.03 (1.02–1.04)	<0.001	1.04 (1.03–1.05)	<0.001
Number of cores sampled	0.98 (0.90–1.05)	0.56		
Number of positive cores	1.10 (1.02–1.19)	0.01	1.10 (1.00–1.21)	0.05
Previous biopsies (>1 vs 0)	0.67 (0.37–1.22)	0.19		
HPCI	1.03 (1.02–1.04)	<0.001	1.03 (1.01–1.04)	<0.001

CI = confidence interval; HPCI = highest percentage of core involved by tumor; OR = odds ratio; PSA = prostate-specific antigen; RP = radical prostatectomy.

^a Statistically significant values are denoted in bold font.

sent adequate classification of these lesions for use in clinical practice.

Other studies have previously reported on IDC and Cribriform concordance between paired biopsy and prostatectomy specimens. Masoomian et al [13], Hollemans et al [14], and Ericson et al [12] reported biopsy sensitivity of 47.2%, 43%, and 56.5% for IDC/Cribriform, respectively, in comparison to 52.5% in our cohort. The findings from all of these studies are similar and highlight the modest sensitivity of biopsy

for IDC/Cribriform detection. However, the aforementioned studies did not distinguish between IDC and Cribriform regarding sensitivity, and grouped them as a single entity. To the best of our knowledge, our study includes the highest number of patients for whom IDC and Cribriform patterns were reported separately. This enabled us to clearly distinguish IDC and Cribriform in terms of sensitivity: we found a decrease in sensitivity of approximately 10% for individual detection of each pattern in comparison to considering IDC and/or Cribriform together. This

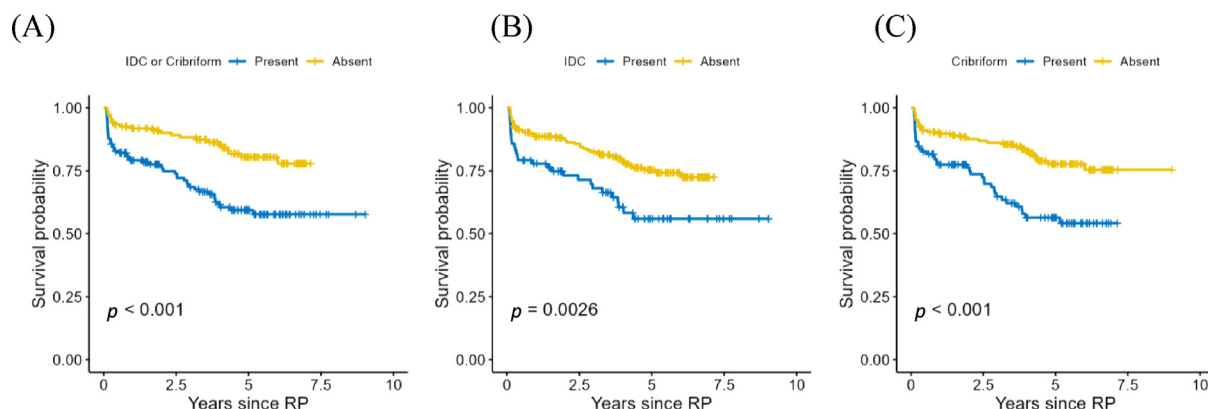


Fig. 2 – Rates of biochemical recurrence following RP: (A) patients with and without either IDC and/or cribriform morphology at biopsy; (B) patients with and without IDC at biopsy; and (C) patients with and without cribriform morphology at biopsy. IDC = intraductal carcinoma; RP = radical prostatectomy.

finding has potential clinical implications for patients with PCa. Several studies have explored the significance of distinguishing between Crib and IDC, but a consensus regarding the clinical relevance is yet to be reached [4,19,20]. Nonetheless, it has been reported that even a small amount of IDC in a prostate biopsy can indicate aggressiveness, even in the absence of high-grade carcinoma or Crib morphology [21]. Furthermore, among patients with metastatic disease detected via prostate-specific membrane antigen positron emission tomography/computed tomography, Crib presence is strongly associated with a lymphatic pattern of metastasis [22]. This emphasizes the importance of differentiating between IDC and Crib to ensure precise documentation of the oncological and clinical outcomes for each pattern.

It is critical to investigate the contrasting characteristics between biopsies that yield true-positive IDC/Crib results and those with false-negative findings. A higher mean number of positive cores was significantly associated with IDC at biopsy, raising two questions. (1) Do IDC lesions have a higher volume than Crib lesions? (2) Is the volume of the lesions of oncological relevance? In spite of its low sensitivity, biopsy diagnosis of IDC/CC adds value to the Cancer of Prostate Risk Assessment score in terms of outcome [23]. We found that patients with false-negative biopsies for IDC/Crib had a more favorable biochemical recurrence rate than patients with true-positive biopsies for IDC/Crib. Observation of a greater extent of Crib pattern has been linked to less favorable prognosis [24]. This association can be attributed to the sampling bias in biopsies, which tend to detect more extensive IDC/Crib. This phenomenon accounts for the significant prognostic impact observed during biopsy.

IDC is typically characterized by cancer cells growing inside the ducts of the prostate gland, while Crib is characterized by cancer cells forming a sieve-like structure [25]. This difference in growth patterns could influence the likelihood of detection via biopsy. It is recognized that accurate determination of pathological PCa grade via biopsy is challenging, as the technique is prone to sampling errors and some carcinomas may be located in regions of the prostate that are difficult to biopsy via a transrectal approach, such as anterior tumors [26]. Conversely, for MRI TBx the number of positive cores did not differ according to the presence of

IDC and/or Crib, suggesting that MRI TBx might not represent adequate classification of these lesions in clinical practice, as previously reported [18]. To the best of our knowledge, only Hogenhout et al [27] include IDC/Crib in comparing the detection of csPCa between transperineal and transrectal prostate biopsy. They concluded that transperineal biopsy has comparable csPCa detection rates to transrectal biopsy when taking IDC/Crib into account. One possible explanation is that sampling of the anterior zone via transperineal biopsy can be challenging in men with a greater prostate volumes, as access can be hampered by surrounding bone structures or motion restriction because of the template used. A freehand method might improve the sampling of anterior regions in these men.

Despite efforts to standardize PCa grading, few studies have addressed the reproducibility of Crib detection. Egevad et al [28] examined the interobserver reproducibility of Crib detection in prostate needle biopsies. In their study, an international panel of experts in prostate pathology independently evaluated a series of biopsies using the latest ISUP criteria. Consensus for or against Crib presence was reached for 90% of the biopsies, with a mean κ value of 0.56. Although there may be variations among observers from different continents, the overall results are in line with previous reproducibility studies on Gleason grading.

We found that the group with IDC-positive biopsies had significantly higher rates of adverse pathology, including pT3 stage and positive lymph nodes. These findings are in line with previous reports that IDC confers worse oncological outcomes in both localized and advanced PCa, whether assessed on biopsy or RP [21]. The clinical significance of this scenario is notable, particularly since IDC has been identified as a potential predictor of nodal metastasis among patients who have undergone RP [29,30]. This observation underscores the possibility of divergent clinical outcomes for such patients and the importance of reporting the Crib and IDC entities individually. Although this oncological trend was not observed for Crib in our cohort, it has been reported for Crib in another study [31].

We also found that the presence of IDC and/or Crib at biopsy was associated with higher Gleason grade (GG ≥ 3) at biopsy and at RP. A systematic review by Porter et al [9] revealed that IDC is infrequent in low-risk cohorts and

significantly more frequent in patients with high-risk disease, rising to >50% among those who developed metastatic or recurrent disease. According to Seyrek et al [7], percentage Gleason grade 4 and the presence of IDC/Crib and Gleason pattern 5 are mutually related in GG 2 RP specimens.

The current study showed that among RP patients, higher PSA was not significantly associated with greater odds of IDC/Crib at biopsy. Conversely, age, percentage Gleason grade 4, and HPCI at biopsy were independently associated with greater odds of IDC/Crib at biopsy. Specifically, for each percentage increment in Gleason grade 4 and HPCI, the odds of IDC/Crib at biopsy were 4% and 3% higher, respectively.

We believe that a validated biomarker would be of great value in detecting IDC/Crib. Current imaging and diagnostic tools (PSA, MRI, biopsy) perform poorly for reliable prediction of IDC/Crib presence. Furthermore, IDC and Crib in biopsy and RP specimens are independent prognostic factors for tumor relapse following radical therapy [4,10]. Recent data suggest that IDC at RP could potentially serve as a marker for lymph node metastasis [29,30] and could potentially be incorporated in future nomograms to improve lymph node metastasis prediction. Lastly, it is of utmost clinical importance to accurately detect PCa exhibiting Crib/IDC morphology, as active surveillance protocols exclude patients with GG 2 disease exhibiting these features.

Study limitations include the single-center setting and the biases inherent to retrospective studies, such as selection bias. However the prospective collection of data for a contemporary cohort of patients involving routine reporting of IDC/Crib by experienced urogenital pathologists in an academic setting (in a center renowned for its interest in IDC/Crib) is a strength that might eliminate the impact of potential bias in a retrospective review of pathology. In keeping with the study objective, we only included patients who had Crib and/or IDC in their surgical specimen. Therefore, we were not able to calculate negative and positive predictive values owing to the naturally high prevalence of these patterns in our cohort because of patient selection. However low sensitivity cannot be solely accounted for by this factor. The pathology report did not account for IDC/Crib volume, which could explain in part the high rate of false-negative results. Long-term oncological outcomes for our cohort are not yet available.

5. Conclusions

Prostate biopsy is not a robust method for reliable detection of Crib and IDC; even with MRI, the sensitivity is moderate at best. Further studies are needed to identify a sensitive marker for better detection of IDC/Crib in the diagnostic pathway to allow a priori planning of individualized treatment strategies. The importance of reporting IDC and Crib individually is highlighted by the potential for distinct clinical outcomes associated with each feature.

Author contributions: Rui M. Bernardino had full access to all the data in the study and takes responsibility for the integrity of the data and the accuracy of the data analysis.

Study concept and design: Bernardino, Sayyid, Lajkosz, Al-Daqqaq, JC, Cockburn, Chavarriaga, Leão, Abedi.

Acquisition of data: Al-Daqqaq, Bernardino.

Analysis and interpretation of data: Bernardino, Sayyid, Abedi, Lajkosz, Al-Daqqaq, JC, Cockburn, Chavarriaga, Leão, Berlin.

Drafting of the manuscript: Bernardino, Sayyid.

Critical revision of the manuscript for important intellectual content: Leão, Berlin, van der Kwast, Fleshner, JC, Cockburn, Chavarriaga.

Statistical analysis: Lajkosz.

Obtaining funding: None.

Administrative, technical, or material support: JC. Cockburn,

Supervision: JC. Cockburn, Leão, Berlin, van der Kwast, Fleshner.

Other: None.

Financial disclosures: Rui M. Bernardino certifies that all conflicts of interest, including specific financial interests and relationships and affiliations relevant to the subject matter or materials discussed in the manuscript (eg, employment/affiliation, grants or funding, consultancies, honoraria, stock ownership or options, expert testimony, royalties, or patents filed, received, or pending), are the following: None.

Funding/Support and role of the sponsor: None.

Acknowledgments: Rui M. Bernardino is supported by Fundacao para a Ciencia e a Tecnologia (2022.13386.BD).

Ethics approval: Appropriate ethics approval was obtained from the University Health Network research ethics board.

Data sharing statement: The data sets generated during and/or analyzed during the current study are available from the corresponding author on reasonable request.

Appendix A. Supplementary data

Supplementary data to this article can be found online at <https://doi.org/10.1016/j.euf.2023.08.010>.

References

- [1] van Leenders GJLH, van der Kwast TH, Iczkowski KA. The 2019 International Society of Urological Pathology consensus conference on prostate cancer grading. *Eur Urol* 2021;79:707–9.
- [2] Epstein JI, Amin MB, Fine SW, et al. The 2019 Genitourinary Pathology Society (GUPS) white paper on contemporary grading of prostate cancer. *Arch Pathol Lab Med* 2021;145:461–93.
- [3] Bernardino RM, Carvalho R, Severo L, Alves M, Papoila AL, Pinheiro C. Prostate cancer with cribriform pattern: exclusion criterion for active surveillance? *Arch Ital Urol Androl* 2020;92:235–8.
- [4] Kweldam CF, Wildhagen MF, Steyerberg EW, Bangma CH, Van Der Kwast TH, Van Leenders GJLH. Cribriform growth is highly predictive for postoperative metastasis and disease-specific death in Gleason score 7 prostate cancer. *Mod Pathol* 2015;28:457–64.
- [5] Hollemans E, Verhoef EI, Bangma CH, et al. Large cribriform growth pattern identifies ISUP grade 2 prostate cancer at high risk for recurrence and metastasis. *Mod Pathol* 2019;32:139–46.
- [6] Sæter T, Vlatkovic L, Waaler G, et al. Intraductal carcinoma of the prostate on diagnostic needle biopsy predicts prostate cancer mortality: a population-based study. *Prostate* 2017;77:859–65.
- [7] Seyrek N, Hollemans E, Osanto S, et al. Cribriform architecture outperforms Gleason pattern 4 percentage and tertiary Gleason pattern 5 in predicting the outcome of grade group 2 prostate cancer patients. *Histopathology* 2022;80:558–65.

- [8] Mottet N, Cornford P, van den Bergh RCN, et al. EAU-EANM-ESTRO-ESUR-ISUP-SIOG guidelines on prostate cancer. Arnhem, The Netherlands: European Association of Urology; 2023. <https://uroweb.org/guidelines/prostate-cancer>.
- [9] Porter LH, Lawrence MG, Ilic D, et al. Systematic review links the prevalence of intraductal carcinoma of the prostate to prostate cancer risk categories. *Eur Urol* 2017;72:492–5.
- [10] Kweldam CF, Kümmerlin IP, Nieboer D, et al. Disease-specific survival of patients with invasive cribriform and intraductal prostate cancer at diagnostic biopsy. *Mod Pathol* 2016;29:630–6.
- [11] Choy B, Pearce SM, Anderson BB, et al. Prognostic significance of percentage and architectural types of contemporary Gleason pattern 4 prostate cancer in radical prostatectomy. *Am J Surg Pathol* 2016;40:1400–6.
- [12] Ericson KJ, Wu SS, Lundy SD, Thomas LJ, Klein EA, McKenney JK. Diagnostic accuracy of prostate biopsy for detecting cribriform Gleason pattern 4 carcinoma and intraductal carcinoma in paired radical prostatectomy specimens: implications for active surveillance. *J Urol* 2020;203:311–9.
- [13] Masoomian M, Downes MR, Sweet J, et al. Concordance of biopsy and prostatectomy diagnosis of intraductal and cribriform carcinoma in a prospectively collected data set. *Histopathology* 2019;74:474–82.
- [14] Hollemans E, Verhoef EI, Bangma CH, et al. Concordance of cribriform architecture in matched prostate cancer biopsy and radical prostatectomy specimens. *Histopathology* 2019;75:338–45.
- [15] Prendeville S, Gertner M, Maganti M, et al. Role of magnetic resonance imaging targeted biopsy in detection of prostate cancer harboring adverse pathological features of intraductal carcinoma and invasive cribriform carcinoma. *J Urol* 2018;200:104–13.
- [16] Mikoshi A, Miyai K, Hamabe F, et al. MRI-detectability and histological factors of prostate cancer including intraductal carcinoma and cribriform pattern. *Prostate* 2022;82:452–63.
- [17] Cai Q, Costa DN, Metter CK, et al. Sensitivity of multiparametric MRI and targeted biopsy for detection of adverse pathologies (cribriform Gleason pattern 4 and intraductal carcinoma): correlation of detected and missed prostate cancer foci with whole mount histopathology. *Urol Oncol* 2022;40:452.e1–e8.
- [18] Bernardino R, Fleshner N. Re: Sensitivity of multiparametric MRI and targeted biopsy for detection of adverse pathologies (cribriform Gleason pattern 4 and intraductal carcinoma): correlation of detected and missed prostate cancer foci with whole mount histopathology. *Eur Urol* 2023;83:583–4.
- [19] Tom MC, Nguyen JK, Lucianò R, et al. Impact of cribriform pattern and intraductal carcinoma on Gleason 7 prostate cancer treated with external beam radiotherapy. *J Urol* 2019;202:710–5.
- [20] Trudel D, Downes MR, Sykes J, Kron KJ, Trachtenberg J, Van Der Kwast TH. Prognostic impact of intraductal carcinoma and large cribriform carcinoma architecture after prostatectomy in a contemporary cohort. *Eur J Cancer* 2014;50:1610–6.
- [21] Miura N, Mori K, Mostafaei H, et al. The prognostic impact of intraductal carcinoma of the prostate: a systematic review and meta-analysis. *J Urol* 2020;204:909–17.
- [22] Bernardino R, Sayyid RK, Al-Daqqaq Z, et al. Lymphotropic pattern of prostate-specific membrane antigen-detected metastases among biochemically recurrent radical prostatectomy patients with cribriform disease. *Eur Urol Focus*. In press. <https://doi.org/10.1016/j.euf.2023.05.005>.
- [23] Yu Y, Lajkosz K, Finelli A, Fleshner N, van der Kwast TH, Downes MR. Impact of cribriform pattern 4 and intraductal prostatic carcinoma on National Comprehensive Cancer Network (NCCN) and Cancer of Prostate Risk Assessment (CAPRA) patient stratification. *Mod Pathol* 2022;35:1695–701.
- [24] Chan E, McKenney JK, Hawley S, et al. Analysis of separate training and validation radical prostatectomy cohorts identifies 0.25 mm diameter as an optimal definition for “large” cribriform prostatic adenocarcinoma. *Mod Pathol* 2022;35:1092–100.
- [25] Zong Y, Montironi R, Massari F, et al. Intraductal carcinoma of the prostate: pathogenesis and molecular perspectives. *Eur Urol Focus* 2021;7:955–63.
- [26] Omer A, Lamb AD. Optimizing prostate biopsy techniques. *Curr Opin Urol* 2019;29:578–86.
- [27] Hogenhout R, Remmers S, van Leenders GJLH, Roobol MJ. The transition from transrectal to transperineal prostate biopsy without antibiotic prophylaxis: cancer detection rates and complication rates. *Prostate Cancer Prostat Dis*. In press. <https://doi.org/10.1038/s41391-022-00641-3>.
- [28] Egevad L, Delahunt B, Iczkowski KA, et al. Interobserver reproducibility of cribriform cancer in prostate needle biopsies and validation of International Society of Urological Pathology criteria. *Histopathology* 2023;82:837–45.
- [29] Kimura K, Tsuzuki T, Kato M, et al. Prognostic value of intraductal carcinoma of the prostate in radical prostatectomy specimens. *Prostate* 2014;74:680–7.
- [30] Downes MR, Xu B, van der Kwast TH. Cribriform architecture prostatic adenocarcinoma in needle biopsies is a strong independent predictor for lymph node metastases in radical prostatectomy. *Eur J Cancer* 2021;148:432–9.
- [31] Marra G, van Leenders GJLH, Zattoni F, et al. Impact of epithelial histological types, subtypes, and growth patterns on oncological outcomes for patients with nonmetastatic prostate cancer treated with curative intent: a systematic review. *Eur Urol* 2023;84:65–85.