

Safe use of fecal microbiota transplant in treatment of graft-versus-host disease in 5-year-old child

Anna Izabela Fałkowska^{1,2*}, Adam Jakubas³, Laura Surdacka³, Jakub Jagiełło³,
Katarzyna Drabko¹, Agnieszka Zaucha-Prażmo¹

¹Department of Pediatric Hematology, Oncology and Transplantology, Medical University of Lublin, Lublin, Poland

²Children's University Hospital of Lublin, Lublin, Poland

³Student Scientific Society of Department of Pediatric Hematology, Oncology and Transplantology,
Medical University of Lublin, Lublin, Poland

Fecal microbiota transplant (FMT) is a promising treatment for bacterial dysregulation within the colon microbiome [1, 2]. It is used in the treatment of various inflammatory diseases of the gastrointestinal tract [2–4]. Recently, FMT application has been reported as a treatment of graft-versus-host disease (GvHD) in adult patients [2, 5–8]. There are few examples of FMT treatment for GvHD in pediatric patients.

Based on an experimental treatment procedure, we present below possible advantages of FMT in post-transplant complication management as an adjunctive treatment of severe, intestinal graft-versus-host disease in a pediatric patient.

A 5-year-old girl with Nijmegen breakage syndrome, diagnosed with T-cell lymphoblastic leukemia, was qualified for allogeneic hematopoietic cell transplantation (allo-HCT) due to poor response to standard chemotherapy. Since there was no matched donor available, she received transplantation from a mismatched family donor. Reduced intensity conditioning consisted of fludarabine, treosulfan and thiotepa. As GvHD prophylaxis, cyclosporine and T-cell depletion were applied.

On day +18 post-transplant, acute gastrointestinal GvHD (GI-GvHD) was diagnosed, later confirmed by endoscopy. First-line treatment with methylprednisolone was induced. Despite a positive initial response, GvHD symptoms increased (i.e. severe diarrhea, electrolyte and protein disturbances, acidosis, and weight loss from 9 to 7 kg). Ruxolitinib, anti-thymocyte globulin (ATG) and a subsequent three mesenchymal stromal cells (MSC) infusions at weekly

intervals were introduced. The patient was switched to a lactose-free and gluten-free diet. After a short-term response, GI-GvHD symptoms returned.

Treatment with infliximab and basiliximab was administered, followed by an additional MSC infusions cycle, and clinical improvement was observed. Due to previous long-lasting chemo- and immunotherapy, the patient's gastro-intestinal tract was chronically colonized by opportunistic bacteria. Microbiological cultures of the stool revealed the presence of multi-resistant bacteria: *Klebsiella pneumoniae* ESBL(+), *Klebsiella oxytoca* ESBL(+), and *Enterococcus faecium* VRE(+).

To improve the patient's microbiota, we decided to transplant the intestinal microflora (FMT). The consent of both her parents and the permission of the Bioethical Committee (KE-0254/219/11/2022) for an experimental treatment were obtained.

The FMT procedure consists of administration to the small or large bowel via endoscopy, enema, or orally in capsule form. Due to the patient's age, low body weight and general condition, the FMT was performed via gastroscopy under general anesthesia by gastroenterology specialists (Figure 1B). The treatment was repeated three times. Due to an infectious complication, the second dose was applied after a month, followed by a third FMT after another week. Each time, 100 mL of thawed product (Human Biome Institute, MBiotix HBI) was given (Figure 1A, 1B).

We observed no relevant complications after each procedure apart from transient diarrhea and vomiting. After the second administration, stool samples confirmed

*Address for correspondence: Anna Izabela Fałkowska,
Department of Pediatric Hematology, Oncology and Transplantology,
Medical University of Lublin, Al. Raclawickie 1, 20–059 Lublin, Poland,
e-mail: annaizabelafalkowska@gmail.com

Received: 25.04.2023 Accepted: 18.05.2023 Early publication date: 16.08.2023

This article is available in open access under Creative Common Attribution-Non-Commercial-No Derivatives 4.0 International (CC BY-NC-ND 4.0) license, allowing to download articles and share them with others as long as they credit the authors and the publisher, but without permission to change them in any way or use them commercially.



Copyright © 2023

The Polish Society of Haematologists and Transfusiology,
Institute of Haematology and Transfusion Medicine.

All rights reserved.

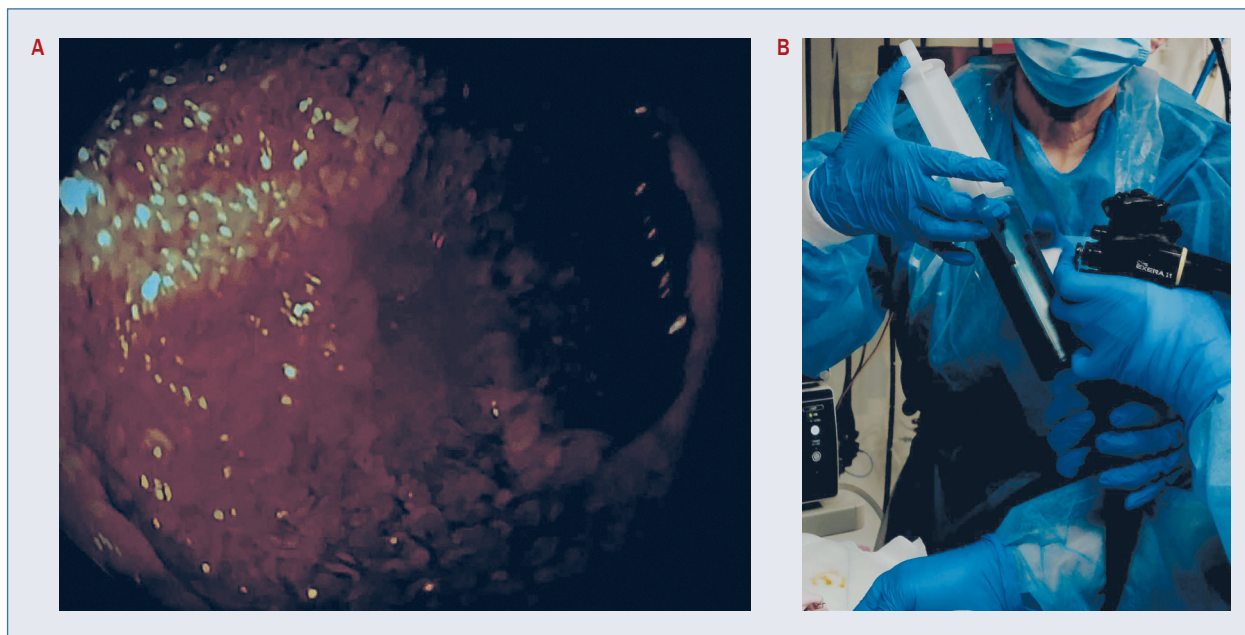


Figure 1A. Endoscopy image of colon; **B.** Fecal microbiota administration

long-lasting colonization by physiological flora of digestive tract – *Enterobacter spp.* Moreover, clinical symptoms of GI-GvHD decreased, resulting in reduced abdominal pain and better stool formation.

GvHD is the major complication of allo-HCT. The mechanism of pathology is based on a significant increase in pro-inflammatory cytokines, which either directly or indirectly activate populations of effector cells and damage target organs such as the skin, liver and gastrointestinal tract [6]. Severe, stage IV GvHD is a relevant complication, affecting patients' survival rate and quality of life; it is one of the leading causes of death after allo-HCT [7].

FMT is a transplant of fecal filtrates from healthy donors into the gastrointestinal tract of recipient patients. The effectiveness of this method was first proven in patients with recurrent *Clostridium difficile* infection (rCDI). Research has also confirmed the effectiveness and safety of FMT in patients with inflammatory bowel disease (IBD) [3].

Studies of adult patients have confirmed the safety of FMT in the treatment of GI-GvHD [8]. Our report confirms the feasibility of the procedure even in a low body weight child. Severe complications were not observed in our patient.

A study on patients with stage IV GI-GvHD proved the beneficial effect of FMT on the diverse increase of intestinal microflora, especially beneficial bacteria, compared to before the procedure [9]. Such a positive, persistent effect was also achieved in our case.

Other analyses on adult populations have proved the immunoregulatory, hormonal and anti-inflammatory beneficial effects of FMT on the intestine [9, 10].

In conclusion, the FMT procedure was safe and efficient despite the low body weight, congenital immunodeficiency, and extensive immunosuppression encountered in our patient. As a result, the gastrointestinal tract was colonized with physiological bacterial flora and the effect persists despite further continuation for immunosuppressive treatment. FMT is a promising method, but its use in children with GvHD still requires more research into the safety and efficacy of the procedure.

Authors' contributions

AIF and AZ-P were responsible for the conception and design of the paper. AIF, KD and AZ-P shared the patient's clinical data. AIF, AJ, LS, JJ contributed to the acquisition of literatures and prepared the final manuscript for publication, supervised by AZ-P. All authors discussed and accepted the final article.

Conflict of interest

The authors declare no conflict of interest.

Financial support

None.

Ethics

The work described in this article has been carried out in accordance with The Code of Ethics of the World Medical Association (Declaration of Helsinki) for experiments involving humans; EU Directive 2010/63/EU for animal experiments and uniform requirements for manuscripts submitted to biomedical journals.

References

1. Gupta S, Allen-Vercoe E, Petrof EO. Fecal microbiota transplantation: in perspective. *Therap Adv Gastroenterol*. 2016; 9(2): 229–239, doi: [10.1177/1756283X15607414](https://doi.org/10.1177/1756283X15607414), indexed in Pubmed: [26929784](https://pubmed.ncbi.nlm.nih.gov/26929784/).
2. Ianiro G, Bibbò S, Porcari S, et al. Fecal microbiota transplantation for recurrent *C. difficile* infection in patients with inflammatory bowel disease: experience of a large-volume European FMT center. *Gut Microbes*. 2021; 13(1): 1994834, doi: [10.1080/19490976.2021.1994834](https://doi.org/10.1080/19490976.2021.1994834), indexed in Pubmed: [34709989](https://pubmed.ncbi.nlm.nih.gov/34709989/).
3. Lin D, Hu Bo, Li P, et al. Roles of the intestinal microbiota and microbial metabolites in acute GVHD. *Exp Hematol Oncol*. 2021; 10(1): 49, doi: [10.1186/s40164-021-00240-3](https://doi.org/10.1186/s40164-021-00240-3), indexed in Pubmed: [34706782](https://pubmed.ncbi.nlm.nih.gov/34706782/).
4. van Nood E, Speelman P, Nieuwdorp M, et al. Fecal microbiota transplantation: facts and controversies. *Curr Opin Gastroenterol*. 2014; 30(1): 34–39, doi: [10.1097/MOG.0000000000000024](https://doi.org/10.1097/MOG.0000000000000024), indexed in Pubmed: [24241245](https://pubmed.ncbi.nlm.nih.gov/24241245/).
5. Alabdjalbar MS, Aslam HM, Veeraballi S, et al. Restoration of the original inhabitants: a systematic review on fecal microbiota transplantation for graft-versus-host disease. *Cureus*. 2022; 14(4): e23873, doi: [10.7759/cureus.23873](https://doi.org/10.7759/cureus.23873), indexed in Pubmed: [35530905](https://pubmed.ncbi.nlm.nih.gov/35530905/).
6. Mickovski I, Ilievska DB, Georgievski B, et al. Graft-versus-host disease in patients treated with allogenic hematopoietic cell transplantation: experience from North Macedonia. *Acta Haematol Pol*. 2021; 52(5): 509–515, doi: [10.5603/ahp.2021.0090](https://doi.org/10.5603/ahp.2021.0090).
7. Spalek A, Woźniczka K, Armatus A, et al. Ruxolitinib for steroid-refractory acute graft versus host disease: case series and literature review. *Acta Haematol Pol*. 2022; 53(1): 66–68, doi: [10.5603/ahp.2022.0006](https://doi.org/10.5603/ahp.2022.0006).
8. Bilinski J, Lis K, Tomaszewska A, et al. Fecal microbiota transplantation in patients with acute and chronic graft-versus-host disease-spectrum of responses and safety profile. Results from a prospective, multicenter study. *Am J Hematol*. 2021; 96(3): E88–E91, doi: [10.1002/ajh.26077](https://doi.org/10.1002/ajh.26077), indexed in Pubmed: [33326127](https://pubmed.ncbi.nlm.nih.gov/33326127/).
9. Zhao Ye, Li X, Zhou Y, et al. Safety and efficacy of fecal microbiota transplantation for grade IV steroid refractory GI-GvHD patients: interim results from FMT2017002 trial. *Front Immunol*. 2021; 12: 678476, doi: [10.3389/fimmu.2021.678476](https://doi.org/10.3389/fimmu.2021.678476), indexed in Pubmed: [34220825](https://pubmed.ncbi.nlm.nih.gov/34220825/).
10. Ouyang J, Isnard S, Lin J, et al. Treating from the inside out: relevance of fecal microbiota transplantation to counteract gut damage in GVHD and HIV infection. *Front Med (Lausanne)*. 2020; 7: 421, doi: [10.3389/fmed.2020.00421](https://doi.org/10.3389/fmed.2020.00421), indexed in Pubmed: [32850913](https://pubmed.ncbi.nlm.nih.gov/32850913/).