



Multimodality imaging and hybrid treatment of pulmonary artery stenosis in a patient with a high risk of airway compression

Authors: Judyta Szeliga, Jacek Kołcz, Barnaba Piwowarczyk, Sebastian Góreczny

Article type: Clinical vignette

Received: June 11, 2023

Accepted: August 28, 2023

Early publication date: September 15, 2023

This article is available in open access under Creative Common Attribution-Non-Commercial-No Derivatives 4.0 International (CC BY-NC-ND 4.0) license, allowing to download articles and share them with others as long as they credit the authors and the publisher, but without permission to change them in any way or use them commercially.

Multimodality imaging and hybrid treatment of pulmonary artery stenosis in a patient with a high risk of airway compression

Short title: Multimodality imaging and hybrid treatment of pulmonary artery stenosis

Judyta Szeliga¹, Jacek Kołcz², Barnaba Piwowarczyk³, Sebastian Góreczny¹

¹Department of Pediatric Cardiology, University Children's Hospital, Jagiellonian University Medical College, Kraków, Poland

²Department of Pediatric Cardiac Surgery, University Children's Hospital, Faculty of Medicine, Jagiellonian University Medical College, Kraków, Poland

³Department of Pediatric *Pulmonology*, Allergology and Dermatology University Children's Hospital, Jagiellonian University Medical College, Kraków, Poland

Correspondence to:

Sebastian Góreczny, MD, PhD,

Department of Paediatric Cardiology,

University Children's Hospital,

Faculty of Medicine, Jagiellonian University Medical College,

Wielicka 265, 30–669 Kraków, Poland,

phone: +48 12 333 90 50,

e-mail: sebastian.goreczny@uj.edu.pl

Patients with congenital heart defects and hypoplastic pulmonary arteries often require multiple surgical and percutaneous interventions. In those with pulmonary artery stenosis and the risk of compression of adjacent airways, bronchoscopic guidance may reduce complications [1]. Hybrid approach by combining the strengths of surgical and transcatheter treatments during one anesthesia, enables effective conduction of complex procedures [2]. Recent technological advancements provide multiple imaging techniques that allow a patient-tailored approach [3–5].

We present application of multimodality imaging, including computed tomography, virtual reality, bronchoscopy for the planning and guidance of hybrid pulmonary artery stenting in a complex congenital heart defect.

A 13-year-old girl (42 kg), diagnosed with tetralogy of Fallot, pulmonary atresia, pulmonary arteries hypoplasia and major aortopulmonary collateral arteries, after surgical correction with right ventricle-to-pulmonary artery conduit (Contegra 12 mm) and collateral unifocalization, was referred from an outpatient clinic. On admission, an echocardiogram showed severe right ventricular hypertrophy, moderate tricuspid regurgitation with high gradient (130 mm Hg) and significant conduit narrowing consistent with suprasystemic pressure in the right ventricle. A computed tomography scan revealed concentric calcification of the conduit and severe tubular narrowing of the medial and distal part of the right pulmonary artery (**Figure 1A**). The artery coursed between the major lobar bronchus and the ascending aorta, creating risk of airway compression in the case of stent implantation.

The routine computed tomography scans were additionally analyzed with VMersive software (VR-Learning, Warszawa, Poland) to prepare a three-dimensional virtual model, enabling simulation of various stents placement and assessment of interaction with adjacent structures. (**Figure 1B, C**; Supplementary material, *Video S1*).

After discussion at a multidisciplinary meeting, the patient was qualified for the hybrid pulmonary artery dilatation and conduit replacement. Through a midline thoracotomy, a short vascular sheath (7 Fr) was introduced in the distal part of the degenerated conduit. A 10 × 30 mm PowerFlex balloon (Cordis) was advanced and gradually inflated in the narrow right pulmonary artery with simultaneous bronchoscopic evaluation of the right bronchus. Already at the subnominal pressure a partial bronchial occlusion was observed (**Figure 1D**) and further balloon inflation to 8 atmospheres caused significant compression of the bronchus (**Figure 1E**), which was confirmed preprocedural with virtual reality simulation with a 10 mm stent. Subsequently, an 8 × 20 mm Formula stent (Cook Medical) was gradually inflated with simultaneous visualization of the right bronchus, providing optimal vessel diameter and pulmonary blood flow while minimizing compression of the adjacent airway (**Figure 1F**). The position of the stent and improved blood flow through the pulmonary artery was confirmed in the final angiography (**Figure 1F**). Next, the heavily calcified conduit was replaced with a 27 mm Hancock II bioprosthetic valve (Medtronic). The postoperative course was uneventful. In a 5-month follow-up, echocardiography confirmed mild tricuspid valve regurgitation with gradient of 55 mm Hg and unobstructed flow in the right pulmonary artery stent.

In cases of a risk of airway compression multimodality imaging including routine computed tomography and bronchoscopy as well as more advanced virtual reality simulation, enabling selection of the optimal stent diameter reducing the risk of airway compression.

Supplementary material

Supplementary material is available at https://journals.viamedica.pl/kardiologia_polska.

Article information

Acknowledgments: To Adam Koleśnik from Cardiovascular Interventions Laboratory, The Children's Memorial Health Institute, Warsaw, Poland for spreading clear benefits of implementing virtual modelling in heart defects. To Anna Grondalski from the Pomeranian Medical University of Szczecin for editing the text.

Conflict of interest: None declared.

Funding: Virtual Reality project is supported by the Jagiellonian University Medical College internal grant No. N41/DBS/001219.

Open access: This article is available in open access under Creative Common Attribution-Non-Commercial-No Derivatives 4.0 International (CC BY-NC-ND 4.0) license, which allows downloading and sharing articles with others as long as they credit the authors and the publisher, but without permission to change them in any way or use them commercially. For commercial use, please contact the journal office at kardiologiapolska@ptkardio.pl.

REFERENCES

1. Ebrahim M, Hagood J, Moore J, et al. Bronchoscopic guidance of endovascular stenting limits airway compression. *Catheter Cardiovasc Interv.* 2015; 85(5): 832–836, doi: [10.1002/ccd.25772](https://doi.org/10.1002/ccd.25772), indexed in Pubmed: [25504498](https://pubmed.ncbi.nlm.nih.gov/25504498/).
2. Gil-Jaurena JM, Zunzunegui JL, Pérez-Caballero R, et al. Hybrid procedures. Opening doors for surgeon and cardiologist close collaboration. *Front Pediatr.* 2021; 9: 687909, doi: [10.3389/fped.2021.687909](https://doi.org/10.3389/fped.2021.687909), indexed in Pubmed: [34386468](https://pubmed.ncbi.nlm.nih.gov/34386468/).
3. Bruckheimer E, Goreczny S. Advanced imaging techniques to assist transcatheter congenital heart defects therapies. *Progress in Pediatric Cardiology.* 2021; 61: 101373, doi: [10.1016/j.ppedcard.2021.101373](https://doi.org/10.1016/j.ppedcard.2021.101373).
4. Proniewska K, Khokhar AA, Dudek D. Advanced imaging in interventional cardiology: mixed reality to optimize preprocedural planning and intraprocedural monitoring. *Kardiol Pol.* 2021; 79(3): 331–335, doi: [10.33963/KP.15814](https://doi.org/10.33963/KP.15814), indexed in Pubmed: [33599454](https://pubmed.ncbi.nlm.nih.gov/33599454/).

5. Topuzov N, Jaszewska A, Migdał A, et al. Virtual simulations in planning intravascular treatment of aortic coarctation - a retrospective analysis. *Adv Interv Cardiol.* 2022; 18(3): 276–282, doi: [10.5114/aic.2022.120377](https://doi.org/10.5114/aic.2022.120377), indexed in Pubmed: [36751294](https://pubmed.ncbi.nlm.nih.gov/36751294/).

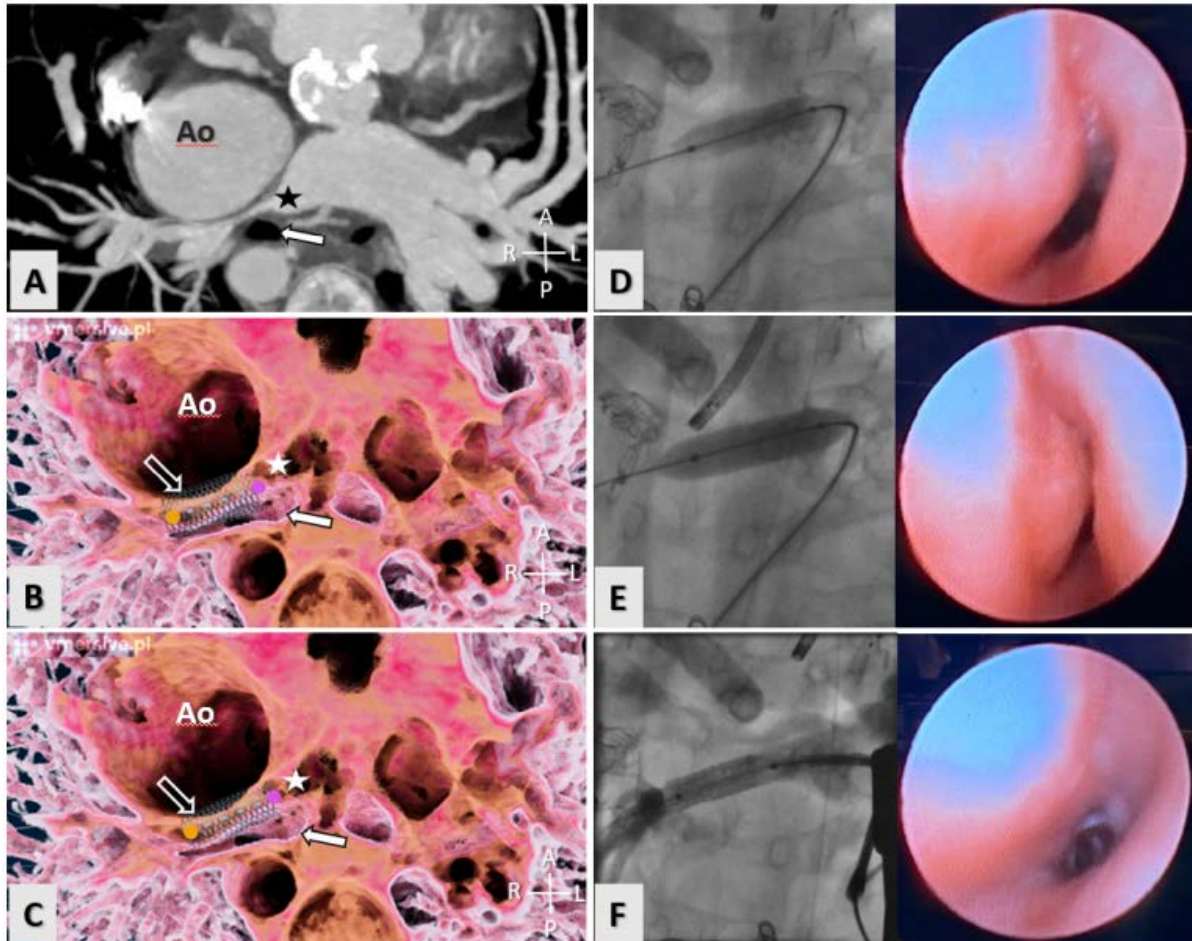


Figure 1. Application of multimodality imaging, including computed tomography, virtual reality, bronchoscopy for planning and guidance of hybrid right pulmonary artery stenting in a patient at risk of bronchial compression. **A.** Computed tomography scan: (cross-sectional view at the level of pulmonary arteries): right pulmonary artery – star, lobar bronchus — white arrow. **B.** Virtual reality simulation (cross-sectional view at the level of pulmonary arteries): a 10 × 20 mm stent — empty arrow, right pulmonary artery — star, lobar bronchus — white arrow. **C.** Virtual reality simulation (cross-sectional view at the level of pulmonary arteries): 8 × 20 mm stent — empty arrow, right pulmonary artery — star, lobar bronchus — white arrow. **D:** On the left side — a posterior — anterior fluoroscopic view: a 10 × 30 mm balloon catheter inflated in the right pulmonary artery to 1 atmosphere; on the right side — bronchoscopic view: partially compressed lobar bronchus. **E.** On the left side — a posterior — anterior fluoroscopic

view: a 10×30 mm balloon catheter expanded in right pulmonary artery to 8 atmospheres; on the right side — bronchoscopic view: near total compression of the lobar bronchus. **F.** On the left side — fluoroscopic posterior — anterior view: a 8×20 mm stent implanted into the right pulmonary artery; on the right side — bronchoscopic scan: patent lobar bronchus

Abbreviations: Ao, ascending aorta; A, anterior; P, posterior; R, right; L, left