



## **Hematoma of the interatrial septum after surgery for a giant aneurysm of the sinus of Valsalva**

**Authors:** Jerzy Pacholewicz, Andrzej Żych, Szymon Olędzki, Tomasz Jędrzejczak,  
Edyta Płóńska-Gościniak

**Article type:** Clinical vignette

**Received:** June 6, 2023

**Accepted:** August 6, 2023

**Early publication date:** September 1, 2023

This article is available in open access under Creative Common Attribution-Non-Commercial-No Derivatives 4.0 International (CC BY-NC-ND 4.0) license, allowing to download articles and share them with others as long as they credit the authors and the publisher, but without permission to change them in any way or use them commercially.

# **Hematoma of the interatrial septum after surgery for a giant aneurysm of the sinus of Valsalva**

**Short title:** Intramural hematoma

Jerzy Pacholewicz<sup>1</sup>, Andrzej Żych<sup>1</sup>, Szymon Olędzki<sup>2</sup>, Tomasz Jędrzejczak<sup>1</sup>, Edyta Płońska-Gościńskiak<sup>2</sup>

<sup>1</sup>Department of Cardiac Surgery, Pomeranian Medical University, Szczecin, Poland

<sup>2</sup>Department of Cardiology, Pomeranian Medical University, Szczecin, Poland

## **Correspondence to:**

Szymon Olędzki, MD, PhD,

Department of Cardiology,

Pomeranian Medical University,

Powstańców Wielkopolskich 72, 70–111 Szczecin, Poland,

phone: +48 664 992 092,

e-mail: soledzki@gmail.com

A sinus of Valsalva aneurysm (SVA) is a rare but potentially life-threatening condition. The prevalence of SVAs in the general population is estimated at 0.09% to 0.1% [1, 2]. In most patients, SVA is a congenital rather than acquired cardiac abnormality. Interatrial septum dissection and hematoma is a very rare complication. It may occur after aortic root or mitral valve surgery and casuistically after percutaneous interventions (ablation) or cardiopulmonary resuscitation [3].

A 66-year-old woman was admitted to the hospital for extended diagnostic workup after an incidental finding of a giant SVA during routine transthoracic echocardiography (TTE) before cardioversion for paroxysmal atrial fibrillation. The patient underwent TTE (**Figure 1A**), transesophageal echocardiography (TEE), and cardiac computed tomography (including coronary computed tomography angiography), which revealed a giant non-coronary sinus of Valsalva aneurysm (97 × 55 mm) (**Figure 1B**), without aortic dissection, no significant lesions in coronary arteries were reported. In addition, bicuspid aortic valve without significant dysfunction and pericardial effusion of up to 8 mm were revealed.

Surgical treatment (**Figure 1C**) included resection of the aneurysm from the side of the pericardium and reconstruction with a dacron graft sutured at the left ventricular outflow tract below the aortic annulus (as in David procedure). Next, the graft was sutured to the aorta, using the continuous suturing technique. Aortic valve repair was performed. Intraoperative TEE revealed no regurgitation. After declamping the aorta, the bleeding from the roof of left atrium appeared (the dissection occurred after cutting through the aneurysm as an extension of the cut after applying traction to the aneurysm sac). The dissection was sutured. Follow-up TEE revealed severe aortic valve regurgitation requiring bioprosthetic aortic valve implantation (Hancock II, 23 mm).

After the procedure, worsening of kidney function, increased levels of inflammatory markers, second-degree atrioventricular block requiring temporary cardiac pacing, and atrial fibrillation and flutter were observed. TTE revealed an interatrial septal hematoma (**Figure 1D**). The haematoma was caused by damage to the mitro-aortic curtain while placing sutures on the non-coronary leaflet. During hospitalization, the patient was treated with antiarrhythmic drugs and antibiotics. Conduction disorders resolved and kidney function improved. Partial resorption of hematoma was also noted (**Figure 1E**). Cardiac rehabilitation was uneventful. Complete resorption of the hematoma was noted in the 1-year follow-up (**Figure 1F**). The patient is currently in a good clinical condition and remains under the care of the cardiac clinic.

Both the SVA and interatrial septal hematoma may cause considerable concern. If an unruptured SVA is present, surgical treatment of symptomatic or large aneurysms is acceptable (the cutoff varies depending on the presence of other abnormalities, such as bicuspid aortic valve or connective tissue disease) [4]. On the other hand, the management of patients with intramural hematoma is debatable [5]. It seems that the choice of treatment should be guided by the patient's clinical condition and pericardial bleeding [5]. Both invasive and noninvasive cardiologists should have sufficient knowledge about both conditions to be able to make adequate decisions on patient management.

### **Article information**

**Conflict of interest:** None declared.

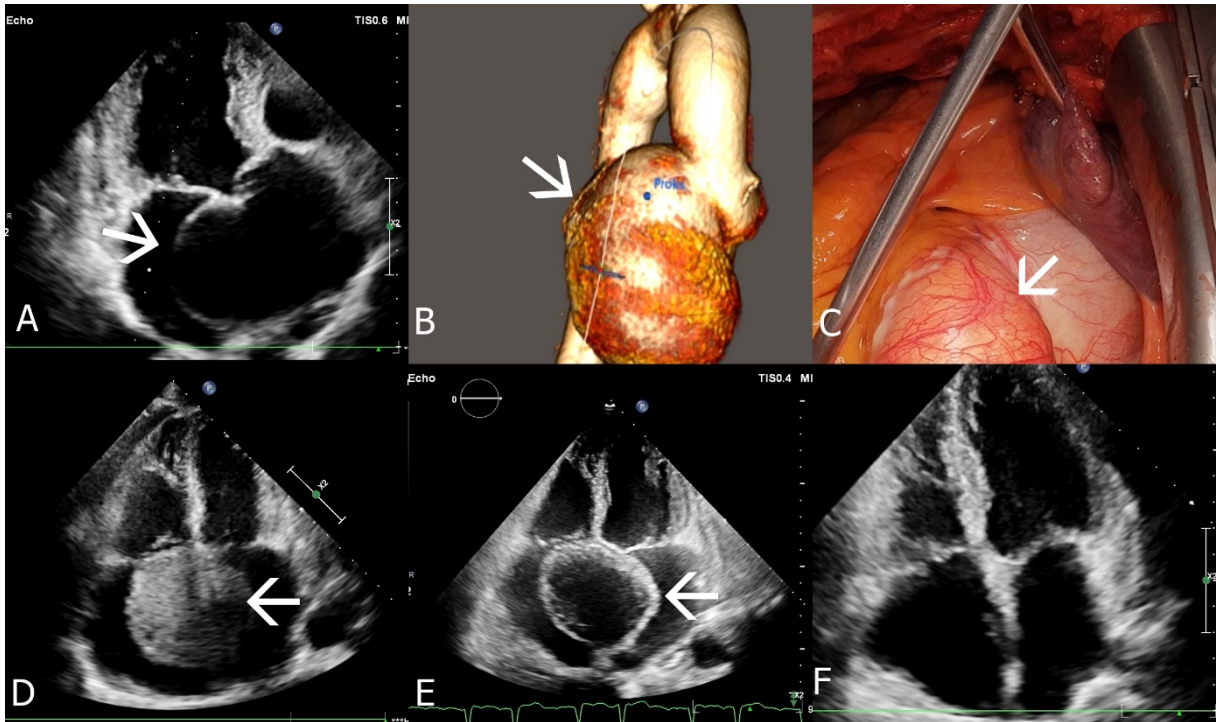
**Funding:** None.

**Open access:** This article is available in open access under Creative Common Attribution-Non-Commercial-No Derivatives 4.0 International (CC BY-NC-ND 4.0) license, which allows downloading and sharing articles with others as long as they credit the authors and the

publisher, but without permission to change them in any way or use them commercially. For commercial use, please contact the journal office at [kardiologiapolska@ptkardio.pl](mailto:kardiologiapolska@ptkardio.pl).

## References

1. Feldman DN, Roman MJ. Aneurysms of the sinuses of Valsalva. *Cardiology*. 2006; 106(2): 73–81, doi: [10.1159/000092635](https://doi.org/10.1159/000092635), indexed in Pubmed: [16612073](https://pubmed.ncbi.nlm.nih.gov/16612073/).
2. Arcario MJ, Lou S, Taylor P, et al. Sinus of valsalva aneurysms: a review with perioperative considerations. *J Cardiothorac Vasc Anesth*. 2021; 35(11): 3340–3349, doi: [10.1053/j.jvca.2020.12.016](https://doi.org/10.1053/j.jvca.2020.12.016), indexed in Pubmed: [33431271](https://pubmed.ncbi.nlm.nih.gov/33431271/).
3. Bernabeu Santisteban R, Johannessen López MV, Carmona García P, et al. An unusual intraoperative finding: Left atrial dissecting intramural hematoma after aortic root replacement. *JTCVS Tech*. 2022; 13: 14–17, doi: [10.1016/j.xjtc.2022.03.016](https://doi.org/10.1016/j.xjtc.2022.03.016), indexed in Pubmed: [35711235](https://pubmed.ncbi.nlm.nih.gov/35711235/).
4. Erbel R, Aboyans V, Boileau C, et al. 2014 ESC Guidelines on the diagnosis and treatment of aortic diseases: Document covering acute and chronic aortic diseases of the thoracic and abdominal aorta of the adult. The Task Force for the Diagnosis and Treatment of Aortic Diseases of the European Society of Cardiology (ESC). *Eur Heart J*. 2014; 35(41): 2873–2926, doi: [10.1093/eurheartj/ehu281](https://doi.org/10.1093/eurheartj/ehu281), indexed in Pubmed: [25173340](https://pubmed.ncbi.nlm.nih.gov/25173340/).
5. Meier D, Antiochos P, Herrera-Siklody C, et al. Interatrial septum dissection and atrial wall hematoma following transseptal puncture: A systematic review of the literature. *Catheter Cardiovasc Interv*. 2020; 96(2): 424–431, doi: [10.1002/ccd.28554](https://doi.org/10.1002/ccd.28554), indexed in Pubmed: [31642609](https://pubmed.ncbi.nlm.nih.gov/31642609/).



**Figure 1.** **A.** Transthoracic echocardiogram (TTE) before the procedure, modified 5-chamber view (arrow indicates the sinus of Valsalva aneurysm). **B.** Cardiac computed tomography angiography: 3-dimensional reconstruction (arrow indicates the sinus of Valsalva aneurysm). **C.** Periprocedural image. **D.** TTE; 4-chamber view (arrow indicates an intramural hematoma). **E.** TTE, 4-chamber view 7 days after the procedure, partial resolution of the hematoma (arrow indicates intramural hematoma). **F.** TTE, 4-chamber view 1 year after the procedure, resolution of the hematoma