

Anatomical characteristics of the accessory hepatic lobe and its clinical-functional particularities

Camila Ribeiro Martins Schwantes¹, Bruna Leticia Miler¹, Ana Cristina Oliveira Gimenes², Geisy Natiele Borges Ribeiro³, Suellen Keyze Almeida Lima⁴, Luciana Estevam Simonato¹, Nilton Cesar Pezati Boer¹, Isabella Glória Camargo⁵, Fernando Flávio Pavan da Silva⁵, Jean Donizete Silveira Taliari^{5,6} and Rogério Rodrigo Ramos^{5,6,7,8*}

¹Medical school, Universidade Brasil (UB), Fernandópolis, SP, Brazil.

²Medical school, Universidade Nove de Julho (UNINOVE), São Bernardo do Campo, SP, Brazil.

³Medical school, Centro Universitário de Mineiros (UNIFIMES), Mineiros, GO, Brazil.

⁴Medical school, Centro Universitário do Planalto Central Aparecido dos Santos (UNICEPLAC), Brasília, DF, Brazil.

⁵Medical school, Centro Universitário de Santa Fé do Sul (UNIFUNEC), Santa Fé do Sul, SP, Brazil.

⁶Department of Human Anatomy, Universidade Brasil, Fernandópolis, SP, Brazil.

⁷PhD, Medical Residency Program in General Surgery in Anatomy for Residents, Universidade Brasil, Fernandópolis, SP, Brazil.

⁸Bentham Science Ambassador, Fernandópolis, SP, Brazil.

*Corresponding author:

E-mail address: rogerio.enfer@gmail.com tel. +55 17 3465 4200

Abstract

Riedel's lobe (ectopic lobe), also known as the accessory hepatic lobe, consists of an anatomical variation characterized by a tongue-shaped protrusion on the visceral surface of the liver right lobe, fixed by a pedicle. This variant draws attention in the clinical practice, as it can be mistaken for a tumor due to its elongated aspect. The aim of this research was to conduct a study on the anatomical characteristics and clinical and functional peculiarities of the accessory hepatic lobe. The paper is based on a integrative review and observational study on a cadaveric specimen. A cadaver with anatomical variation was used. Data were collected in PubMed, Scielo, and VHL. 257 articles were found in the databases, but only 13 were used for research. In careful review, two rare cases of the accessory lobe in the left lobe of the liver, hypoplastic left lobes, and agenesis of the right hepatic lobe, and often the clinical picture without changes in signs and symptoms were found. These morphological abnormalities' clinical impact is limited in the absence of underlying liver disease, cirrhosis, or known cancer. In case of complications or after the diagnosis of pedunculated tumors in the liver, laparoscopy is well indicated for removing these lobes or tumors.

Keywords: Riedel's lobe, Accessory hepatic lobe, Hepatic lobe anatomical variations.

1. INTRODUCTION

Riedel's lobe has this name because Bernhard Moritz Carl Ludwig Riedel (German surgeon, 1849-1916) reported it in 1888 in seven female patients who presented palpable masses in the right hypochondrium, which were later confirmed in a surgical procedure. This hepatic segment, defined as a supernumerary lobe of the liver, composed of the hepatic parenchyma, has continuity to the liver via a fixation stem (Figure 1). Its shape, size, and location are variable, often located in the right liver part, attached by a pedicle containing vessels and bile ducts, most of which are located on the underside of the liver or infrahepatic^[1].

Also known as the accessory hepatic lobe, it consists of an anatomical variation, characterized by a tongue-shaped projection of the anterior border of the right lobe of the liver to the right of the gallbladder (Figure 1), in addition to the level of the lower costal cartilage when transmitted on cross-sectional images^[2]. The prevalence is around 3.3 to 31% depending on the diagnostic criteria and used methods, and is more commonly found in women (H: M = 1: 3)^[3]. Also, this anomaly can be mistaken for a tumor due to its elongated appearance^[4].

This morphological lobulation is relatively asymptomatic, rarely found on physical examination, being diagnosed in an endoscopic procedure during abdominal surgery, necropsy^[5], or cadaver dissection in the human anatomy laboratory.

Understanding this anomaly is essential for medical students and medical residents, especially clinical surgeons, due to the experience of several cases reporting malignancy and torsion involving Riedel's lobe, besides being a differential diagnosis for hepatomegaly and mistaken for a tumor mass. Therefore, this research aimed to perform a literature review and observational study on the accessory hepatic lobe's anatomical characteristics and its clinical-functional particularities.

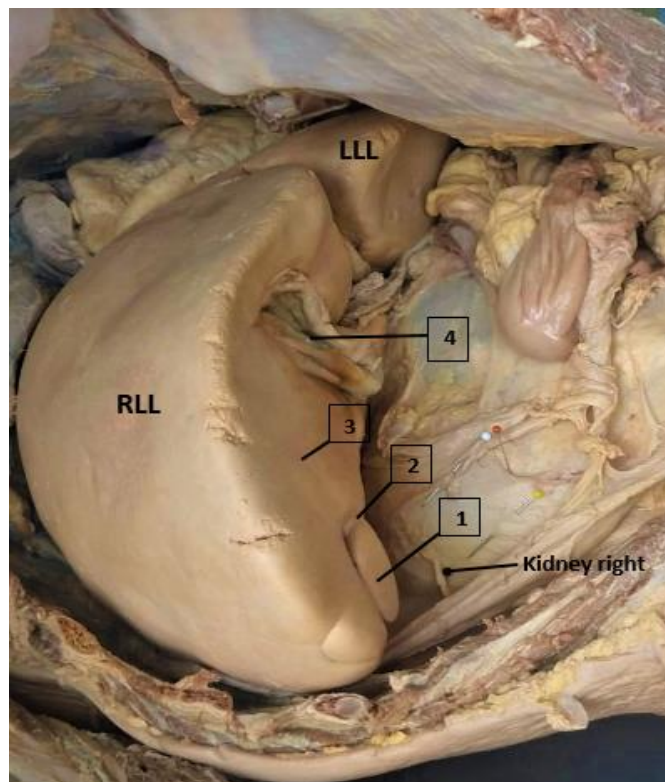


Figure 1. Accessory hepatic lobe. Legend: right liver lobe (RLL); left liver lobe (LLL); accessory hepatic lobe (1); fixation stem or pedicle (2); visceral surface (3); gallbladder (4), white pin (peritoneum); red pin (pararenal fatty body); yellow pin (Gerota's fascia).

2. METHODOLOGY

The paper is based on an integrative review and observational study using a cadaveric specimen. For the observational study, a cadaveric specimen from the Human Anatomy Laboratory of the Universidade Brasil, Campus Fernandópolis, SP, was used. It was a formalized male cadaver. According to Brazilian Law 8501, the material was used on November 30, 1992, which provides unclaimed cadavers for study or scientific research purposes. The review's data search focused on the following steps: review topic selection; literature search; literature selection/collection, reading and analysis; review writing; and references^[6].

The scientific articles included in the study were obtained through the following platforms: Virtual Health Library (VHL), PubMed, and Google Scientific Electronic Library Online (SciELO). The titles and abstracts researched for the bibliographical survey were through the keywords: Riedel Lobe, Accessory Hepatic Lobe, and Anatomical Variation of the Hepatic Lobe.

The inclusion criteria were articles in the English language (2005 to 2021), available in their entirety, addressing the accessory hepatic lobe's anatomical and clinical characteristics, excluding articles that did not meet the established criteria. After the search criteria, the titles and abstracts were examined in total, so a series of articles for the review were found, 257 studies, and submitted to the eligibility analysis. Then 87 studies were selected for careful evaluation, and 13 were included and discussed in this study (Figure 2).

According to the search refinement, few studies were found on the subject. In the Virtual Health Library, 156 studies were identified, 30 articles with the descriptor Riedel's lobe, accessory hepatic lobe (101 articles), and hepatic lobe anatomical variation (25 articles). The publications from 2005 to 2020 were homogeneous, and no articles were found in the 2021 period. In PubMed, 100 articles were found, 20 with the descriptor Riedel's lobe, accessory hepatic lobe (42 articles), and hepatic lobe anatomical variation (38 articles). There was little research in the period from 2005 to 2014, totaling 37 articles. However, the prominence was found between 2015 to 2018, with 50 articles, already in 2019 to 2021, there is little progress in research, with 13 articles. Finally, in the SciELO platform, the publications found in this agency were heterogeneous, for having only one study related to the theme, being 1 article from 2008 related to the accessory hepatic lobe.

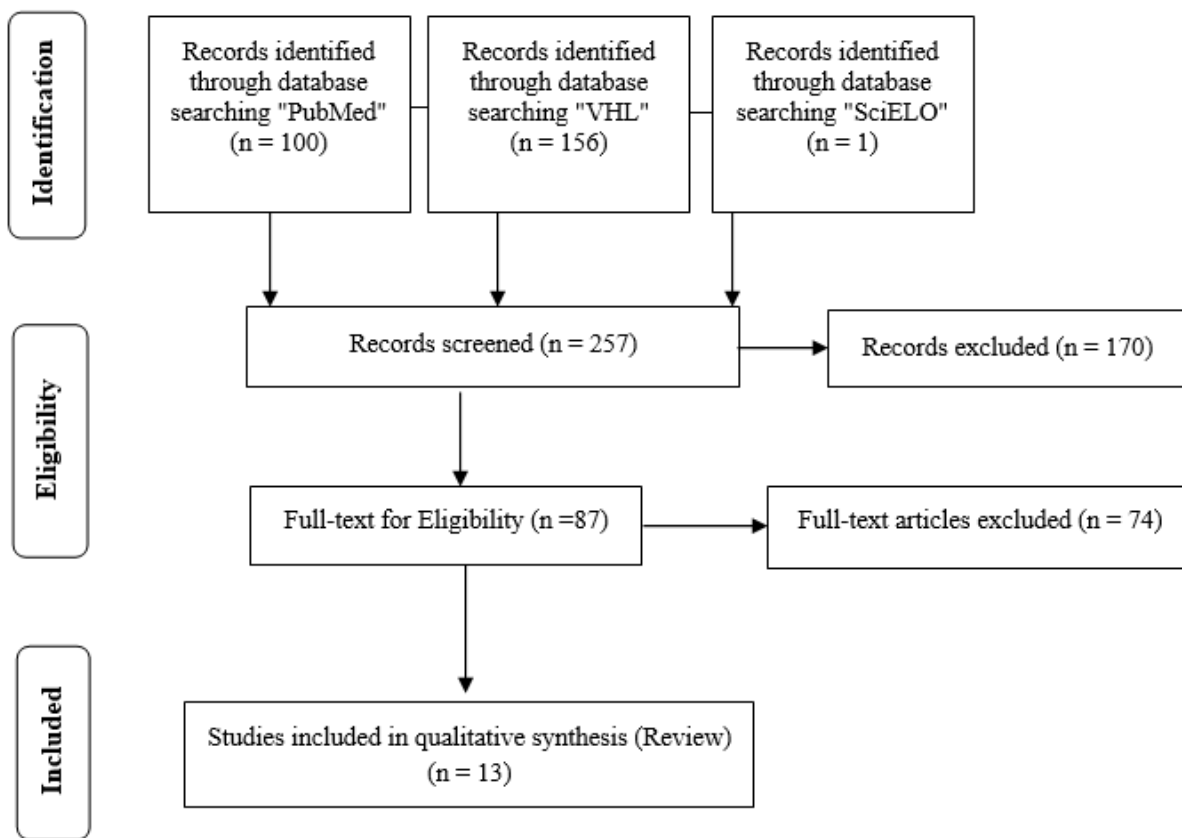


Figure 2. Flowchart.

3. RESULTS AND DISCUSSION

Figure 1 shows an increase in liver gland size, a characteristic defined as hepatomegaly. Due to this pathology, the lower border of the liver right lobe is very close to the iliac crest. This may confuse the health professional during the percussion in this area, presenting a change from a tympanic sound to a solid sound. In addition, the ectopic liver lobe is noticeable on the liver's visceral side in the right lobe. Note that the lobe is in the visceral surface's posteroinferior position, superior to the right kidney. As for the ectopic lobe location, clinically, it is believed that the sharp pain in the right upper quadrant can be confused with

severe abdominal pain when it is in the inflammatory process. This tongue-shaped liver morphology is an anatomical variation factor called the accessory hepatic lobe or Riedel's lobe.

Regarding the Riedel's lobe anatomical aspects, the study of Akbulut et al.^[3] describes a rare case of an accessory lobe in the liver's left lobe. The patient, in this case, was an 81-year-old patient with cholecystitis, who presented a palpable mass in the right upper abdominal quadrant that extended to the epigastric region. It is important to emphasize that the imaging exams did not show the hepatic anomaly and were only discovered in the emergency laparotomy for acute abdomen due to obstruction of the pyloric region. Medically, Murphy's sign was positive in the presence of normal liver enzymes. Similar clinical case in an 80-year-old woman with similar clinical findings and anatomical changes^[7].

Another relevant aspect is liver agenesis. Agenesis is a term used to designate a lobe's absence, but the missing segment is replaced by fibrous tissue. This anomaly is an uncommon condition and was observed in the studies of Nacif et al.^[8]. The authors report that the finding is a rare congenital abnormality and defined as the absence of the right hepatic lobe. This type of situation can be diagnosed by ultrasound (US), computed tomography (CT), magnetic resonance imaging (MRI), or found during a surgical intervention in laparotomy maneuver.

In the study by Salzman et al.^[9], A case report of an adolescent girl suffering from right upper quadrant abdominal pain worsened with body movements and ameliorated with ibuprofen. In this case, Murphy's sign was negative, liver enzymes normal, and the spleen was mildly enlarged. Imaging examinations showed a liver abnormality where the right lobe had an extension extending to the iliac crest.

Chien et al.^[10] described the case of a 52-year-old patient with macroscopic hematuria and severe right flank pain. CT scan revealed a right renal mass of 7.8 ± 7.4 cm, and a laparoscopic right radical nephrectomy was planned. CT scan review revealed a Riedel's lobe extending caudally past the lower pole of the right kidney to the greater pelvis, compressing this region. The authors' reported difficulty was that Riedel's lobe obscured the operative field during right renal transperitoneal laparoscopic surgery, determining that failure to diagnose the accessory lobe may be an intraoperative complication.

The study by Savopoulos et al.^[11], described the case of a 71-year-old patient, referring for hypergammaglobulinemia, with a clinical history of bilateral total hip arthroplasty that required a revision due to a local infection four years ago. The physical examination was unremarkable, and the patient was afebrile, with no palpable mass in the abdomen and no changes in laboratory tests. A thoracoabdominal computed tomography scan was performed, and in addition to many artifacts resulting from the bilateral hip arthroplasty, it revealed a collection in the right iliopsoas (abscess or hematoma) and a 24 cm homogeneous pedunculated mass in the liver's right lobe, elongated downward, ending inferiorly to the iliac crest; the Riedel's lobe was then diagnosed.

The study by Kurniawan et al.^[1], on the other hand, reports the case of a 38-year-old patient who sought her gynecologist with a significant lower quadrant abdominal discomfort complaint. Physical examination showed stable vital signs and unchanged gynecological examinations. In the same exam, hepatomegaly was found by accident, later confirmed by hepatobiliary ultrasonography. The result showed an extension of the liver right lobe through the lower lobe of the right kidney, while the gallbladder, spleen, and pancreas appeared to be in healthy condition.

It is interesting to highlight a study of 58 liver specimens obtained from cadavers. Medical students from 2004 to 2012 at the Department of Anatomy of the MIMS medical school performed the study. Of the 58 specimens, 24 (41.37%) were standard, without fissures or accessory lobe and normal contour. Of the remaining 34 specimens, 31 (53.44%) specimens, despite appearing normal, had accessory fissures in the left lobe, right lobe, caudate lobe, and square lobe resulted in the formation of accessory lobes. Hypoplastic left lobes were observed in 2 (3.44%) specimens. The lingular process of the left lobe was present in only one specimen (1.72%). Observing the right lobe specifically, in only one specimen, two small accessory lobes were observed near the gallbladder base near the lower border^[5].

One point to emphasize is that the accessory lobe can simulate a mass^[12] in the right upper quadrant, with symptoms such as pain, vomiting, constipation, or local edema^[2].

In this context, Riedel's lobe is a rare anomaly^[13] found in the right hepatic lobe, characterized by an abnormal elongation that extends near the right iliac crest, usually producing pain, discomfort, or even the need for surgical intervention. Minor symptoms include acute or recurrent abdominal discomfort, nausea, constipation, or edema caused by extrinsic compression or an episode of torsion in this lobe with compression of adjacent tissues^[2,9]. It should be evidenced that no pathognomonic sign for people with Riedel's lobe was found in any study addressing pathognomonic signs, making clinical diagnosis harder.

Such findings point out that the clinical picture usually shows discomfort in the right upper flank, without changes in vital signs and laboratory tests in most cases^[1]. Imaging examinations or surgical findings made the discovery. In most cases, the treatment is conservative, consisting of rest, cold compresses, non-steroidal anti-inflammatory drugs, and medical attention in about three months for monitoring^[11].

4. CONCLUSION

Riedel's lobe and other liver accessory lobes are anatomical variations with no particular consequences, except as a confounding source with tumors or the exceptional twisting of pedunculated shape. In the absence of underlying liver disease, cirrhosis, hepatomegaly, or known cancer, these morphological abnormalities' clinical impact is somewhat limited. In case of complications or after the diagnosis of pedunculated tumors in the liver, laparoscopy is well indicated for removing these lobules or tumors.

CONFLICTS OF INTEREST

The authors declare no conflict of interest.

References

- [1] Kurniawan J, Anggraeni D, Dewiasty E, Lutfie L. Riedel's lobe: clinical importance of a rare variant in liver morphology. *Acta Med Indones.* 2017;49(1):57-62.
- [2] Glenisson M, Salloum C, Lim C, et al. Accessory liver lobes: anatomical description and clinical implications. *J Visc Surg.* 2014;151(6):451-5.

- [3] Akbulut S, Basak F, Sevinc MM. Gastric outlet obstruction caused by Riedel's lobe of the liver: A diagnostic and therapeutic challenge for surgeons. *Hepato-Gastroenterology*. 2011;58:589-92.
- [4] Ramos RR, Simonato LE, Godoy JMP, et al. Morphological characteristics of the in formalized corps: an observational study. *IJDR*. 2020;10(03):34746-48.
- [5] Vinnakota S, Jayasree N. A new insight into the morphology of the human liver: a cadaveric study. *International Scholarly Research Notices Anatomy*. 2013;24:1-6.
- [6] Grant MJ, Booth A. A typology of reviews: an analysis of 14 review types and associated methodologies. *Health Info Libr J*. 2009;26(2):91-108.
- [7] Bensaad A, Algaba R. Images in medicine: Riedel's lobe of the liver. *Pan African Medical Journal*. 2017;28:211.
- [8] Nacif LS, Buscariolli Ydos S, D'Albuquerque LA, Andraus W. Agenesis of the right hepatic lobe. *Case Rep Med*. 2012;2012:415742.
- [9] Salzman SM, Schroff E, Goldman MD, Chung E. Riedel Fight Song: a case report of riedel lobe presumed to be hepatomegaly. *International J Contemporary Pediatrics*. 2016;3(3);1089-91.
- [10] Chien GW, Orvieto MA, Galocy RM, Sokoloff MH, Shahav AL. Technical considerations for laparoscopic right renal surgery in presence of Riedel's lobe of the liver. *J Endourology*. 2005;19(3):300-2.
- [11] Savopoulos C, Kakaletsis N, Kaiafa G, Iliadis F, Kalogera-Fountzila A, Hatzitolios AI. Riedel's lobe of the liver: a case report. *Medicine (Baltimore)*. 2015;94(3):e430.
- [12] Elfeshawy MS. Bilobed spleen, transposition of the inferior vena cava and Riedel lobe: an extremely rare imaging finding in the same case. *BJR Case Rep*. 2018;5(2):20180091.
- [13] Natarajan S, Jayasudha, Periasamy M, Rangasamy S. Torsion of accessory hepatic lobe. *J Indian Assoc Pediatr Surg*. 2017;22:55-56.