

Trivial isolated bilateral clavicle fracture: a case report

¹Mohd Muhaimin, Mohamad Ridhwan, LH Ong ²ZH Phang

¹Orthopaedic department, Faculty of Medicine and Health Sciences, Universiti Malaysia Sarawak

²Orthopedic department, Hospital Umum Sarawak

INTRODUCTION:

Bilateral clavicle fracture is a rare occurrence and associated with high energy trauma.¹ We would like to present a case report of a patient sustained bilateral clavicle fracture after a low energy trauma.

REPORT:

Our case report presents a 36 year old female with no comorbidities, had a self-accident while riding motorcycle alone. Post trauma patient still able to get up by herself, only complained of bilateral shoulder pain.

Patient went to seek treatment to a nearby clinic a day later, however patient was given 2 weeks follow up for her injuries. Later, patient was referred to our center after 2 weeks follow up due to persistent pain. Throughout the period, patient denied any breathing difficulties or other bony injuries.

Patient was counselled for operation upon review in our center and went for bilateral clavicle plating under elective setting. On our preoperative assessment, the skin condition is good, no evidence of ecchymosis or skin tentin. Neurovascular status is intact for bilateral upper limbs. Internal fixation using anatomical 3.5mm locking plates were used and procedure was uneventful.

Post operative follow up showed excellent results with good range of motion over bilateral shoulder joints. Xray radiograph showed good union over bilateral clavicle.

We decided to go for surgical fixation as both fractures are displaced and causing persistent pain to the patient even after conservative measures of immobilization and pain control. As surgical intervention reduced risk of non-union, this factor must be considered to achieve faster functional recovery.² Current evidence is still

debatable of when to do the surgery and is decided based on the functional demand and symptoms presented by the patient.

CONCLUSION:

Isolated bilateral clavicle fracture is uncommon, and surgery is an option in cases of displaced fracture and persistent pain.

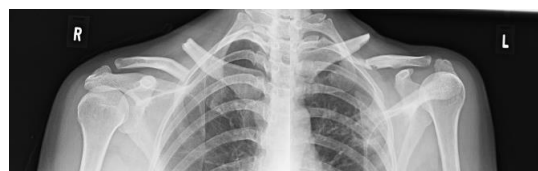

Figure 1: Patient preoperative xray

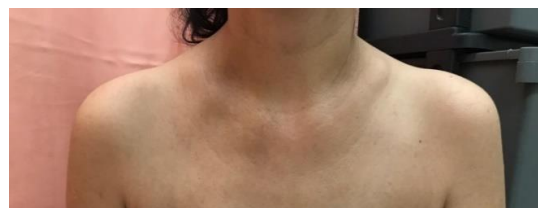


Figure 2: Preoperative skin condition

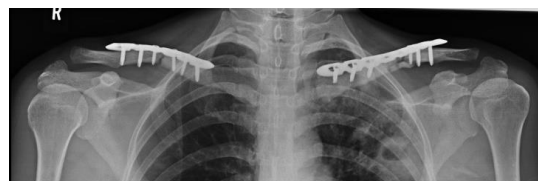

Figure 3: Post operative xray

REFERENCES:

1. Mishra, A, Acharya, K, Timilsina, A, et al. Isolated bilateral clavicular fracture: A case report. *Clin Case Rep.* 2022
2. Bajuri MY, Boon HW. Bilateral Clavicle Fractures: A Case Report. *Malays Orthop J.* 2018 Mar;12(1):60-62.