

## Encephalic xanthomas in a large malayan chevrotain (*Tragulus napu*)

María F. González, Silvia Sisó<sup>b</sup>, Ingrid D. Pardo<sup>c</sup>, Francisco R. Carvallo<sup>d\*</sup>

**ABSTRACT.** An adult water chevrotain was euthanized due to severe non-responsive pododermatitis. Incidentally, multiple to coalescing cholesterol granulomas were identified within the right diencephalon, characterized by the presence of foamy macrophages and cholesterol clefts consistent with encephalic xanthomas. No clinical signs or predisposing conditions associated with this finding were identified. This is the first known report of encephalic xanthomas in this species.

*Key words:* brain, cholesteatoma, cholesterol granuloma.

**RESUMEN.** Un ciervo ratón grande adulto es eutanasiado debido a una pododermatitis que no responde al tratamiento. Incidentalmente, se identifican numerosos granulomas de colesterol en el diencefalo derecho, los que se caracterizan por la presencia de macrófagos espumosos y cristales de colesterol, consistentes con xantomas cerebrales. No se identificaron signos clínicos o condiciones predisponentes asociados con este hallazgo. Este es el primer reporte de xantomas cerebrales en esta especie.

*Palabras clave:* cerebro, colesteatoma, granuloma de colesterol.

A 15 year-old, male large malayan chevrotain (*Tragulus napu*) kept in captivity was euthanized and presented for necropsy due to severe chronic pododermatitis which did not improve with treatment. Necropsy findings included suppurative pododermatitis, from which *Pasteurella multocida* was isolated, and also bilateral congenital renal cysts. In the brain, a 0.5 × 0.2 white linear lesion was identified in the right ventral thalamus, involving the optic tract and in close proximity to the crus cerebri (figure 1). Representative samples of multiple organs were collected and fixed in 10% neutral buffered formalin. After routine paraffin embedding, 4 µm thick hematoxylin and eosin (H&E) sections were prepared. In addition, selected sections of the brain were stained with Ziehl-Nielsen, luxol fast blue and Periodic acid Schiff stains. At the junction of the right thalamus and the cerebral cortex, there were numerous coalescing granulomas embedded within the gray and white matter areas, composed of sheets of foamy macrophages containing a granular, faintly eosinophilic granular cytoplasmic material (figure 2). Granulomas contained large numbers of acicular cholesterol-like crystals, a few lymphocytes and occasional neutrophils. Immunohistochemistry for CD-204 strongly labeled the cytoplasm of foamy cells, confirming their histiocytic origin (figure 2, inset). Granulomas within white matter tracts, i.e. optic tract, were not associated with myelin loss since no reduction of myelin was observed in sections stained with luxol fast blue. Other sections of the

brain also displayed very small aggregates of foamy cells, but no crystals were delineated. No acid-fast bacteria or fungal organisms were recognized in any of those lesions. No cholesterol granulomas were identified in any of the other examined tissues. With this information, a diagnosis of encephalic cholesterol granulomas (encephalic xanthomas) was reached.

Xanthomas (Greek “xanthos”, meaning yellow), also called xanthogranulomas, cholesteatomas or cholesterol granulomas, are rare non-neoplastic masses composed of large foamy macrophages, containing clear vacuoles in cytoplasm, Touton type mononuclear giant cells with eccentric nuclei, abundant material and cholesterol clefts, and less frequently with the presence of lymphocytes and fibrosis (Ozmen and Holigur 2011, Kheirandish *et al* 2013, Mauldin and Peters-Kennedy 2016). Although these lesions are not neoplastic, it can invade locally (Kheirandish *et al* 2013). Xanthomas have been reported in human and multiple animal species, in which the most frequent locations are the skin, sub cutis and tendon sheaths, but other tissue can also be affected. In humans, xanthomas are a common feature of cerebrotendinous xanthomatosis, which has been associated with an autosomal recessive mutation of the *CYP27A1* gene encoding a cytochrome p450 oxidase, and causes a defect of the sterol 27-hydroxylase enzyme (Björkhem 2013).

In animals, encephalic xanthomas have been described in Cuban tree frogs (Carpenter *et al* 1986), geckos (Garner *et al* 1999), green water dragons (Kummrow *et al* 2010), a dog (Cramer *et al* 2011), meerkats (Sladky *et al* 2010) and horses (Summer *et al* 1995, Cantile and Youseef 2016). In these animals, the xanthomas were located principally in the ventricles, hypothalamus, pituitary gland and in the white matter of the spinal cord, not always associated with neurologic signs. When present, clinical signs depend on the location of the lesions, and include decreased motor activity, opisthotonus, horizontal head bobbing and incoordination (Carpenter *et al* 1986, Kummrow *et al* 2010).

Accepted: 02.05.2017.

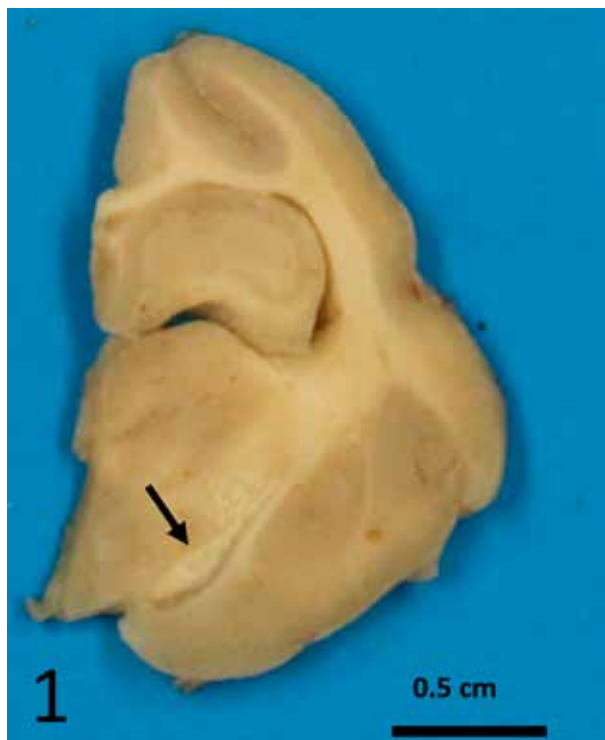
<sup>a</sup>Facultad de Recursos Naturales y Medicina Veterinaria, Universidad Santo Tomás, Talca, Chile.

<sup>b</sup>Department of Pathology, Microbiology and Immunology, School of Veterinary Medicine, University of California, Davis, USA.

<sup>c</sup>Drug Safety, Research and Development, Pfizer Inc., Groton, USA.

<sup>d</sup>California Animal Health and Food Safety Laboratory, University of California, Davis, USA.

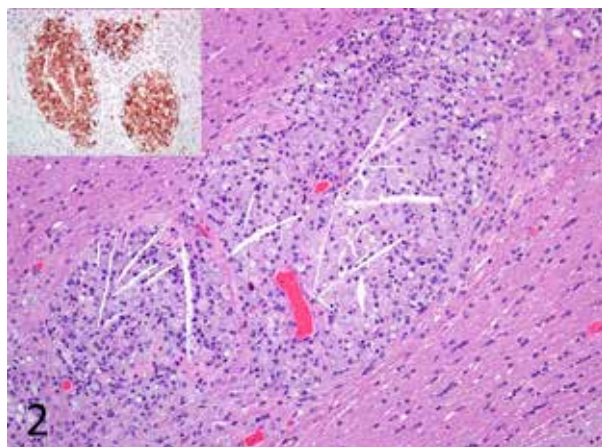
\*Corresponding author: F Carvallo; 105 W Central Ave, San Bernardino, CA 92408, USA; fcarvallo@ucdavis.edu



**Figure 1.** Transverse section of the brain (thalamus) with the presence of a linear white lesion in the right ventral thalamus (arrow).

The pathogenesis of xanthomas is not clearly understood, but disorders in lipid metabolism and metabolic disease have been postulated (Kheirandish *et al* 2013, Ravens *et al* 2013). In humans, dogs and cats, xanthomas have been associated with hyperlipidemia (Wisselink *et al* 1994, Banajee *et al* 2011, Ozmen and Haligur 2011, Kheirandish *et al* 2013) as well as other factors such as diabetes mellitus, glucocorticoid therapy or high cholesterol diets (Wisselink *et al* 1994, Mauldin and Peters-Kennedy 2016), hypothyroidism, hyperadrenocorticism, genetic factors and systemic diseases (Cramer *et al* 2011, Lipar *et al* 2011, Kheirandish *et al* 2013). In horses, choroid plexus cholesterol granulomas are frequent in old animals and appear to be initiated by chronic congestion, edema and hemorrhage into the plexus stroma. Infiltration of macrophages containing lipid and hemosiderin follows, with deposits of cholesterol clefts which could act as a foreign body, triggering low grade inflammation (Cantile and Youseef 2016). In the water chevrotain described here, lesions were found at the margin of the right thalamus, sparing the choroid plexuses. These lesions were not associated with neurological signs. Additionally, blood cholesterol levels were within normal range for the species, and there was no previous history of cerebral trauma or trauma-related microscopic lesions.

In conclusion, to the authors' knowledge, this is the first published report of encephalic xanthomas in a water



**Figure 2.** Thalamus displaying two coalescing granulomas, composed of numerous foamy macrophages lining the silhouettes of cholesterol clefts. Hematoxylin and eosin, 400X. Inset: CD-204 Immunohistochemistry labeling the cytoplasm of foamy cells, confirming their histiocytic origin. Meyer's Hematoxylin counterstain, 200X.

chevrotain. In this case, the described lesion was considered an incidental finding. The pathogenesis of this condition remains unclear.

#### ACKNOWLEDGEMENTS

The authors acknowledge Mrs. Sue Ellen Uzal and Dr. Francisco Uzal for the English review of this manuscript.

#### REFERENCES

- Banejee KH, Orandle MS, Ratteree W, Bauer RW, Gaunt ST. 2011. Idiopathic solitary cutaneous xanthoma in a dog. *Vet Clin Pathol* 40, 95-98.
- Björkhem I. 2013. Cerebrotendinous xanthomatosis. *Curr Opin Lipidol* 24, 283-287.
- Cantile C, Youssef S. 2016. Nervous System. In: Maxie MG (ed). *Jubb, Kennedy and Palmer's Pathology of domestic animals*. 6<sup>th</sup> ed, Vol 1. Elsevier Saunders, Philadelphia PA, USA, Pp 250-406.
- Carpenter JL, Bachrach Jr A, Albert DM, Vainisi SJ, Goldstein MA. 1986. Xanthomatous keratitis disseminated xanthomatosis, and atherosclerosis in Cuban tree frogs. *Vet Pathol* 23, 337-339.
- Cramer SD, Miller AD, Medici EL, Bruner JD, Ritchey JW. 2011. Sellar xanthogranuloma in a dog. *J Vet Diagnost Invest* 23, 387-390.
- Garner MM, Lung NP, Murray S. 1999. Xanthomatosis in geckos: five cases. *J Zoo Wildl Med* 60, 443-447.
- Kheirandish R, Azizi S, Azari O. 2013. Cutaneous xanthoma in a domestic pigeon: pathologic study (case report). *Glob Vet* 10, 140-143.
- Kummrow MS, Berkvens CN, Paré JA, Smith DA. 2010. Cerebral xanthomatosis in three green water dragons (*Physignathus cocincinus*). *J Zoo Wildl Med* 41, 128-132.
- Lipar N, Horvatek D, Prukner-Radovčić E, Kurilj AG, Radišić B, *et al*. 2011. Subcutaneous xanthoma in a cockatiel (*Nymphicus hollandicus*) - a case report. *Vet Arhiv* 81, 535-543.
- Mauldin EA, Peters-Kennedy J. 2016. Integumentary system. In: Maxie MG (ed). *Jubb, Kennedy and Palmer's Pathology of domestic animals*. 6<sup>th</sup> ed, Vol 1. Elsevier Saunders, Philadelphia PA, USA, Pp 509-736.
- Ozmen O, Haligur M. 2011. A case of xanthoma in a Saanen goat. *Vet Dermatol* 23, 150-152.

- Raven PA, Vogelnest LJ, Piripi SA. 2013. Unique presentation of normalipaeamic cutaneous xanthoma in a cat. *Aust Vet J* 91, 460-463.
- Sladky KK, Dalldorf FG, Steinberg H, Wright JF, Loomis MR. 2010. Cholesterol granulomas in three meerkats (*Suricata suricatta*). *Vet Pathol* 37, 684-686.
- Summer BA, Cummings JF, de Lahunta A. 1995. Principles of Neuropathology. In: Summer BA, Cummings JF, de Lahunta A (eds). *Veterinary Neuropathology*. Mosby, St. Louis MO, USA, Pp 1-67.
- Wisselink MA, Koeman JP, Wensing T, de Bruijne J, Willemsse T. 1994. Hyperlipoproteinaemia associated with atherosclerosis and cutaneous xanthomatosis in a cat. *Vet Quart* 16, 199-202.

