

Stationary and Recurrent Properties of Atrial Fibrillation Conduction Patterns in Goat

Citation for published version (APA):

van Hunnik, A., Zeemering, S., Podziemski, P., Simons, J., Gatta, G., Maesen, B., Kuiper, M., Verheule, S., & Schotten, U. (2018). Stationary and Recurrent Properties of Atrial Fibrillation Conduction Patterns in Goat. In *2018 COMPUTING IN CARDIOLOGY CONFERENCE (CINC)* (Vol. 45). IEEE. <https://doi.org/10.22489/CinC.2018.291>

Document status and date:

Published: 01/01/2018

DOI:

[10.22489/CinC.2018.291](https://doi.org/10.22489/CinC.2018.291)

Document Version:

Publisher's PDF, also known as Version of record

Document license:

Taverne

Please check the document version of this publication:

- A submitted manuscript is the version of the article upon submission and before peer-review. There can be important differences between the submitted version and the official published version of record. People interested in the research are advised to contact the author for the final version of the publication, or visit the DOI to the publisher's website.
- The final author version and the galley proof are versions of the publication after peer review.
- The final published version features the final layout of the paper including the volume, issue and page numbers.

[Link to publication](#)

General rights

Copyright and moral rights for the publications made accessible in the public portal are retained by the authors and/or other copyright owners and it is a condition of accessing publications that users recognise and abide by the legal requirements associated with these rights.

- Users may download and print one copy of any publication from the public portal for the purpose of private study or research.
- You may not further distribute the material or use it for any profit-making activity or commercial gain
- You may freely distribute the URL identifying the publication in the public portal.

If the publication is distributed under the terms of Article 25fa of the Dutch Copyright Act, indicated by the "Taverne" license above, please follow below link for the End User Agreement:


www.umlib.nl/taverne-license

Take down policy

If you believe that this document breaches copyright please contact us at:

repository@maastrichtuniversity.nl

providing details and we will investigate your claim.



Patterns of axillary staging and management in clinically node positive breast cancer patients treated with neoadjuvant systemic therapy: Results of a survey amongst breast cancer specialists



J.M. Simons^{a, b, k, *}, A.J.G. Maaskant-Braat^c, E.J.T. Luiten^d, M.H.K. Leidenius^e, T.J.A. van Nijnatten^f, P.G. Boelens^g, L.B. Koppert^a, C.C. van der Pol^h, C.J.H. van de Velde^g, R.A. Audisioⁱ, M.L. Smidt^{j, k}

^a Erasmus Medical Center Rotterdam, Department of Surgical Oncology, Rotterdam, the Netherlands

^b University Medical Center Utrecht, Department of Surgical Oncology, Utrecht, the Netherlands

^c Maxima Medisch Centrum, Department of Surgical Oncology, Eindhoven, the Netherlands

^d Amphia Hospital, Department of Surgical Oncology, Breda, the Netherlands

^e Helsinki University Hospital, Department of Breast Surgery, Helsinki, Finland

^f Maastricht University Medical Center+, Department of Radiology and Nuclear Medicine, Maastricht, the Netherlands

^g Leiden University Medical Center, Department of Surgery, Leiden, the Netherlands

^h Alrijne Hospital, Department of Surgical Oncology, Leiderdorp, the Netherlands

ⁱ Institute of Clinical Sciences, Sahlgrenska University Hospital, Department of Surgery, Göteborg, Sweden

^j Maastricht University Medical Center+, Department of Surgical Oncology, Maastricht, the Netherlands

^k Maastricht University Medical Center+, GROW – School for Oncology and Developmental Biology, Maastricht, the Netherlands

ARTICLE INFO

Article history:

Received 11 February 2019

Received in revised form

3 July 2019

Accepted 12 August 2019

Available online 13 August 2019

Keywords:

Breast cancer

Neoadjuvant systemic therapy

Axillary staging

Node-positive

Treatment-response

Axillary lymph node dissection

ABSTRACT

Introduction: Various options for axillary staging after neoadjuvant systemic therapy (NST) are available for breast cancer patients with a clinically positive axillary node (cN+). This survey assessed current practices amongst breast cancer specialists.

Materials and methods: A survey was performed amongst members of the European Society of Surgical Oncology and two UK-based Associations: the Association of Breast Surgery and the British Association of Surgical Oncology. The survey included 3 parts: 1. general information, 2. diagnostic work-up and 3. axillary staging after NST.

Results: A total of 310 responses were collected: parts 1, 2 and 3 were fully completed by 282 (91%), 270 (87.1%) and 225 (72.6%) respondents respectively. After NST, 153/267 (57.3%) respondents currently perform ALND routinely and 114 (42.7%) respondents perform less invasive restaging of the axilla with possible omission of ALND. In the latter group, 85% does and 15% does not use nodal response seen on imaging to guide the axillary restaging procedure. Regarding respondents that do use imaging: 95% would perform a less invasive staging procedure in case of complete nodal response on imaging (63% sentinel lymph node biopsy (SLNB), excision of a previously marked positive node with SLNB (21%) and without SLNB (11%)). In case of no nodal response on imaging 77% would perform ALND.

Conclusion: Current axillary staging and management practices in cN+ patients after NST vary widely. To determine optimal axillary staging and management in terms of quality of life and oncologic safety, breast specialists are encouraged to include patients in clinical trials/prospective registries.

© 2019 Elsevier Ltd, BASO ~ The Association for Cancer Surgery, and the European Society of Surgical Oncology. All rights reserved.

Introduction

The management of the axilla in clinically node-negative breast cancer patients has evolved towards a less or even non-invasive approach. For clinically node-positive breast cancer patients

* Corresponding author. Department of Surgery, University Medical Center Utrecht, P.O. Box 85500, 3508 GA, Utrecht, the Netherlands.

E-mail address: j.m.simons@umcutrecht.nl (J.M. Simons).

(cN+) however, the axillary lymph node dissection (ALND) has been the standard of care until recently. cN + patients are increasingly receiving systemic therapy before surgery (i.e. neo-adjuvant systemic therapy (NST)). As a result of NST, in at least 1/3 of pre-treatment cN + patients the axilla converts to node-negative [1]. In case of a pathologic complete response (pCR) in the axilla, ALND may be unnecessary and its purpose is therefore being questioned [2,3].

In order to identify cN + ypN0 patients, several less invasive procedures have been proposed. These procedures can be largely divided into 3 groups: sentinel lymph node biopsy (SLNB), excision of a pre-treatment marked positive lymph node (e.g. MARI: Marking Axillary lymph node with Radioactive Iodine seed) [4] or procedures involving the combination of both (e.g. TAD: Targeted Axillary Dissection [5], RISAS: Radioactive Iodine Seed localization in the Axilla combined with a SLNB; the iodine seed is placed in the positive axillary lymph node prior to start of NST [6]). Currently, no consensus exists on which procedure is most accurate for axillary staging after NST. Moreover, long-term data on whether these less invasive procedures can safely replace ALND, even in case of axillary pCR, are lacking.

The lack of evidence based consensus guidelines for cN + patients treated with NST results into broadly differing patterns of care in the management of the axilla. The present survey focused on breast cancer specialists (mainly European) to assess current practices regarding diagnostic work up and axillary staging in cN + patients treated with NST.

Materials and methods

Participants and survey

An anonymous survey was made accessible to members of the European Society of Surgical Oncology, the Association of Breast Surgery (ABS) and the British Association of Surgical Oncology (BASO). A link to the survey was uploaded on the websites of these 3 Associations and included in several newsletters. The survey was developed using SurveyMonkey Inc. and consisted of 3 parts: 1. general information, 2. diagnostic work-up/indications for NST and 3. axillary staging after NST. The expected time spent to complete the survey was approximately 5–10 min. The maximum number of questions was 38.

Collection and analysis of responses

Responses were collected from March to October 2018. Statistical analysis was performed using IBM SPSS Statistics for Windows, version 24 (IBM, Corp, Armonk, New York, USA). For each question, the number of respondents was determined. The selected answers to each question were reported as percentages of the total number of responses to each question. Subgroups were created for respondents that routinely performed ALND and respondents that selectively omitted ALND in cN + patients. To compare unpaired categorical variables the Chi-squared test was used. A p-value of $\leq .05$ was considered statistically significant.

Results

General information

Characteristics regarding general information of the respondents are summarized in Table 1. A total of 310 respondents submitted the survey, of whom 282 (91%) fully completed the first section on general information. All 310 respondents felt this topic to be clinically relevant. Institutional lack of consensus was

Table 1
General information characteristics.

Variable	Total responses n = 310 (%)
Confirm Clinical relevance of topic	310 (100.0)
Institutional lack of consensus	113 (36.7)
Dissatisfaction with local protocols	94 (30.5)
Variable	Total responses n = 282 (%)
Qualification	
Surgical oncologist	230 (81.5)
Surgeon, participating in surgical oncology fellowship	25 (8.9)
Surgical resident	12 (4.3)
Other ^a	15 (5.3)
Practicing in Continent	
Europe	208 (73.8)
Asia	44 (15.6)
North America	5 (1.7)
South America	11 (3.9)
Africa	14 (5.0)
Institution	
University hospital	125 (44.3)
Breast cancer specific hospital	21 (7.4)
Large non-university teaching hospital	79 (28)
Community hospital	29 (10.3)
Other ^b	28 (10)
Years of experience as a specialist	
≤ 5	67 (23.7)
6–10	58 (20.6)
11–15	46 (16.3)
≥ 16	111 (39.4)
Number of new breast cancer patients at institutional level (yearly)	
≤ 500	213 (76.1)
500–1000	45 (16.1)
≥ 1000	22 (7.8)
Unknown/not sure	2 (not included in percentage calculation)
Percentage of patients treated with NST	
0–15%	112 (41.7)
16–30%	90 (33.2)
31–45%	27 (10.0)
46–60%	26 (9.6)
>61%	16 (5.9)
Unknown/not sure	11 (not included in percentage calculation)
On-site radiotherapy facility present	
Yes	184 (65.2)
No	98 (34.8)

^a Other: 1x medical oncologist, 1x radiotherapist, 1x final year trainee in breast surgery, 5x general surgeon, 1x plastic surgeon, 1x pediatric surgeon, 1x pharmacist, 2x gynaecologist, 2x associate specialist.

^b Other: 12x comprehensive cancer center, 10x private hospital, 5x district general hospital, 1x maternity and gynaecology hospital.

reported by 113/310 (36.5%) respondents. Dissatisfaction with local protocols for axillary staging and management was reported by 94/310 (30.3%) respondents as a consequence of the lack of consensus or protocols, performing ALND irrespective of response to NST, concerns regarding insufficient data on long-term oncologic safety, management differing per individual case and disagreement between specialties. Respondents experiencing lack of consensus in their institution were less often satisfied with current practices compared to respondents experiencing consensus: 46.9% vs. 82.7% respectively ($p < .001$).

Diagnostic work-up and indications for NST

A total of 270/282 (95.7%) respondents fully completed the second section on diagnostic work-up and indications for NST. Axillary ultrasound was routinely performed to assess the axilla prior to start of NST by 87% of respondents. The main reasons not to perform axillary ultrasound were: a normal physical examination of the axilla or other imaging modalities were performed (i.e. PET-

CT or MRI). The majority of respondents (70.9%) did not perform other imaging examinations in addition to axillary ultrasound to determine the axillary tumour load prior to NST. The majority of 210 respondents (74.5%) stated either FNAC or CNB was mandatory to confirm cN + disease, the remainder relied on physical examination and/or imaging. The main reasons not to perform FNAC or CNB were radiological signs of distant metastasis, patient age or very high clinical suspicion of axillary lymph node status (i.e. FNAC or CNB outcome would not change treatment plan).

For 27.4% of respondents, cN + status was always an indication for NST in physically fit breast cancer patients aged <70 years and for 11% of respondents this was (almost) never the case. For the remaining respondents, the following factors influence whether NST was indicated in cN + patients: histological subtype, molecular biology, cN status, size of primary tumour, tumour grade and patient preferences. The vast majority of respondents (79%), indicated that gene expression profiling was (almost) never performed to advice for NST.

The majority of respondents (168/270; 62.2%) never marked the pathologically positive lymph node prior to NST. One quarter breast specialists (69/270; 25.6%) marked the positive lymph node as standard of care and 33/270 (12.2%) only performed this as part of clinical trials. The majority of respondents who mark the positive lymph node prior to NST use a radiopaque clip (76/100; 76%). Other methods to mark the lymph node prior to NST were iodine seed or

injection of charcoal. Respondents who omitted ALND in cN + patients, marked lymph nodes more often than respondents who routinely performed ALND (50.8% vs. 26.8%, $p < .001$).

Axillary staging and treatment after NST

A total of 225/270 (83.3%) respondents fully completed the third and last section of the survey on axillary staging and treatment after NST. After NST, ALND was routinely performed by 153/267 respondents (57.3%). This rate was comparable between European respondents (56.3%) and non-European respondents (59.7%). The remaining 114/267 respondents performed less invasive restaging of the axilla with possible omission of ALND based on several clinicopathologic characteristics including; cN status prior to NST, number of positive lymph nodes prior to NST, age and presence of comorbidities (see Fig. 1). Besides these characteristics, 85% rely on nodal response seen on imaging to choose the axillary staging procedure (see Fig. 2). The nodal response was assessed (during and/or after NST) by means of ultrasound (88%) and/or MRI (46.3%) and/or PET/CT (22.2%). In case of complete nodal response on imaging, 95% (77/81) performed a less invasive axillary staging procedure, mainly SLNB (63%). The remainder prefer SLNB combined with excision of a previously marked positive lymph node (21%) or excision of a previously marked positive lymph node without SLNB (11%). Five percent ($N = 4$) of respondents did not perform any

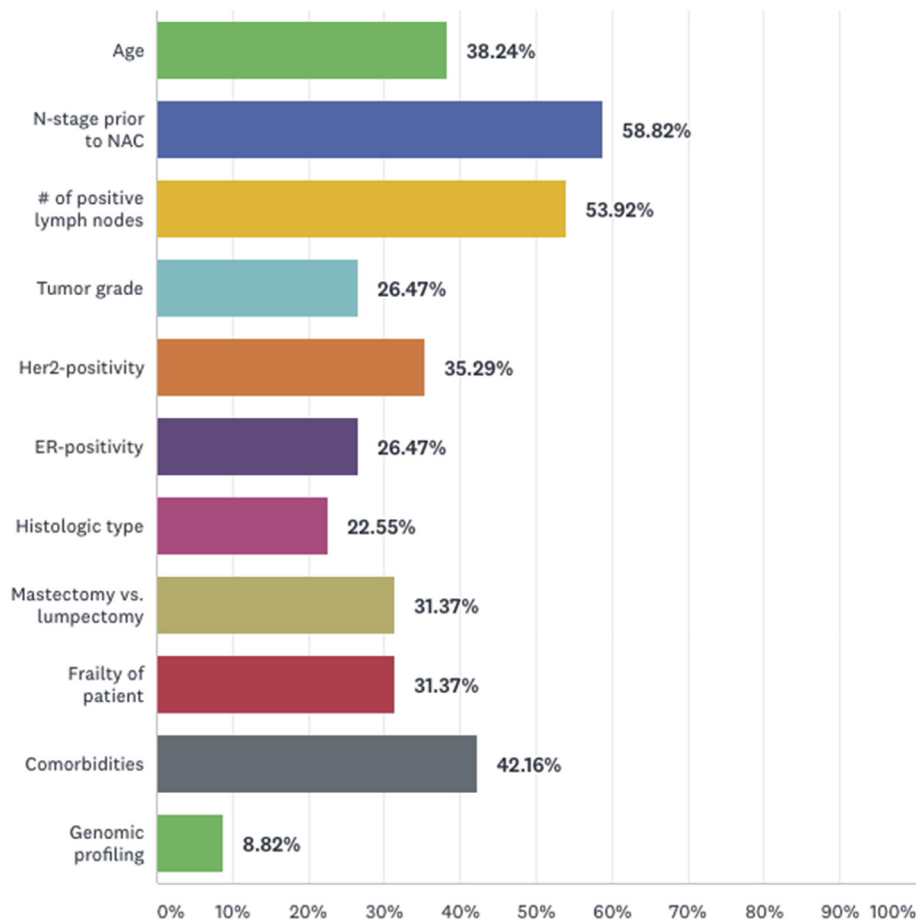


Fig. 1. Less invasive axillary restaging with possible omission of ALND is performed in cN + patients dependent on (a combination of) the below characteristics.*.

*114 respondents reported to perform less invasive restaging of the axilla with possible omission of ALND in cN

+ patients of whom 102 respondents reported on the above characteristics. Respondents could select multiple answers, therefore percentages do not add up to 100%. Sixty-four percent of respondents selected 3 or more characteristics.

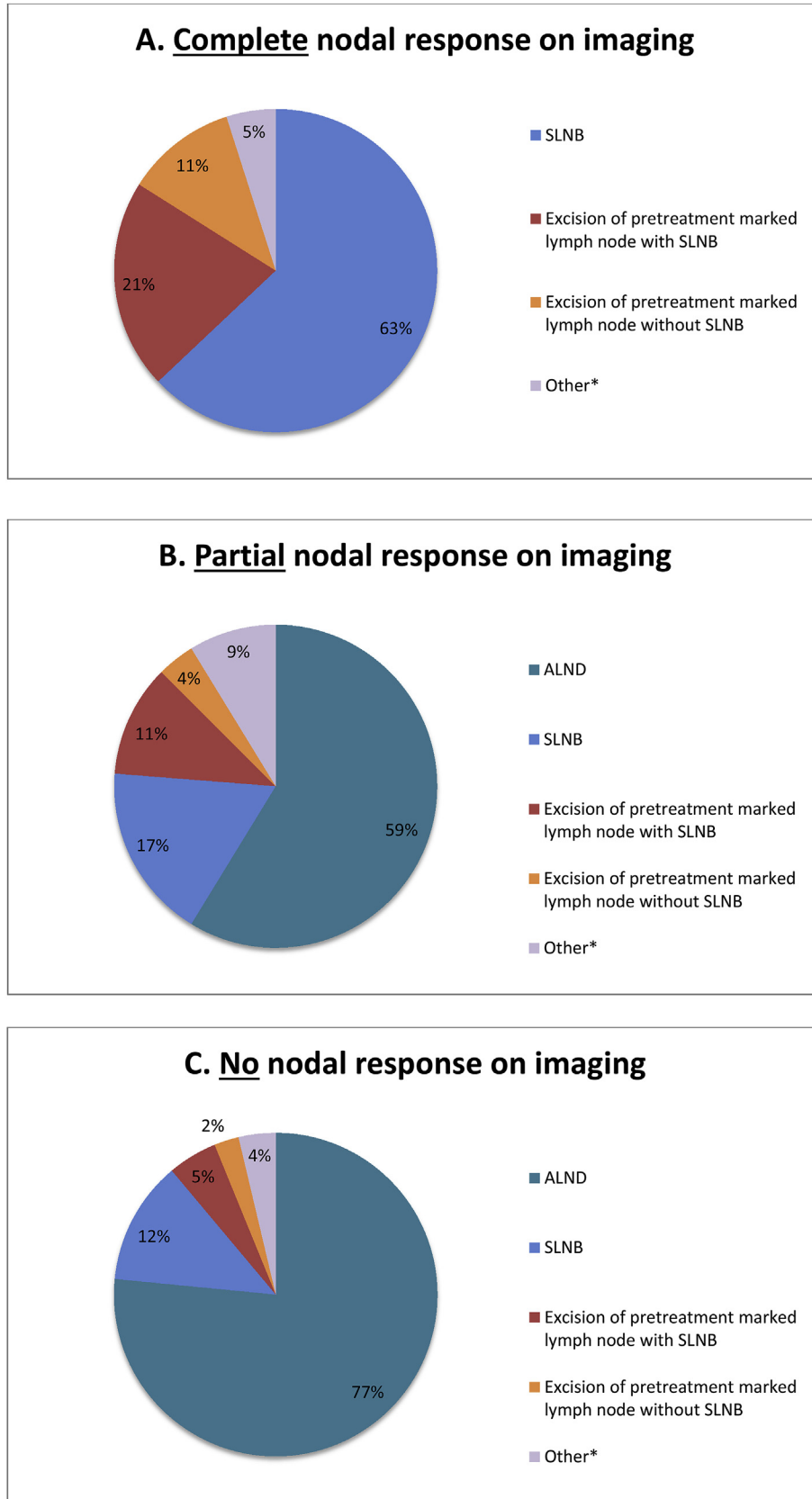


Fig. 2. Type of axillary staging procedure based on the degree of nodal response seen on imaging (A: complete nodal response, B: Partial nodal response, C: no nodal response). NB: 84 of 92 respondents who used nodal response on imaging to guide axillary restaging in cN

+ patients submitted an answer. Three respondents were excluded from this analysis because of contradicting answers.

*Other: 2x

surgical staging procedure in patients with complete nodal response on imaging: 1 respondent opted for adjuvant radiotherapy, 2 respondents opted for a “wait and see” approach and 1 respondent stated this would depend on breast response and axillary tumour burden pre-NST. In case of partial or no nodal response on imaging, ALND was performed by the majority of respondents (59% and 76% respectively).

Several respondents (28/225) reported that the prescription of adjuvant radiotherapy and extension of fields also depended on factors other than pathologic response, like the number of suspicious or positive lymph nodes prior to NST. In case final pathologic assessment of lymph nodes showed axillary pCR, 70% of remaining respondents (138/197) recommended no further axillary treatment (this rate was similar for respondents that did and did not routinely perform ALND (86/121 (71%) and 52/76 (68%) respectively, $p = .692$). In case final pathologic assessment of lymph nodes showed macrometastasis, 48% of respondents (93/194) recommended adjuvant regional radiotherapy (this rate was similar for respondents that did and did not routinely perform ALND (38/78 (48.7%) and 55/116 (47.4%) respectively, $p = .859$).

Amongst respondents that omitted ALND in cN + patients compared to respondents that routinely performed ALND, satisfaction rates with local protocols were 74.6% and 66% respectively ($p = .133$) and institutional consensus rates were 60.5% and 66% respectively ($p = .356$). Patient preferences influence axillary staging and management always in 14%, most of the time in 32%, sometimes in 47% and never in 7% of respondents. These rates were similar for respondents that performed ALND routinely and respondents that omitted ALND in cN + patients.

Discussion

Patients with cN + breast cancer treated with NST achieve an axillary pCR in up to 74%, depending on tumour characteristics [1,6,7]. In pursue of omitting ALND in these patients, several less invasive staging procedures have been proposed to identify axillary pCR. This survey displays the great variety of axillary staging procedures and treatment protocols, thereby indicating a worldwide need for consensus regarding the optimal method for axillary staging after NST in cN + patients.

Our survey shows that axillary staging and management vary from a minimum ‘wait and see’ approach (in case of complete nodal response on imaging) to a ‘most extensive’ ALND combined with adjuvant radiotherapy. A survey amongst members of the American society of breast surgeons indicated that only 15% still performed ALND in all cN + patients after NST [8]. In our current survey, as much as 57.3% still performed ALND routinely in all cN + patients after NST. Interestingly, the survey by Caudle et al. documented that respondents that had not incorporated less invasive staging procedures were more aware of their downsides (like the false negative rates of the Z1071, Sentina and SN-FNAC trials) [8]. We did not explicitly ask respondents to provide reasons for still performing ALND, but several respondents voluntarily reported “concerns on long-term oncologic safety” of less invasive procedures. This indicates that there is still need for convincing evidence to support

replacing ALND with less invasive procedures.

Over recent years, two methods have been proposed for axillary staging that involve excision of the pre-treatment marked positive lymph node, i.e. MARI (in which only the marked lymph node is excised after NST) [4] and TAD/RISAS (in which both the marked lymph node and the sentinel lymph nodes are excised after NST) [5,9,10]. The marking of positive lymph nodes prior to NST, was performed by 1/3 of respondents. Even respondents who routinely performed ALND, reported marking positive lymph nodes prior to NST (27%). This was comparable to the results of the previously mentioned survey, which indicates that specialists do not always aim to retrieve the marked lymph node during surgery. Trial participation might be a reason for this. Widespread implementation of marking the positive lymph node prior to NST may be hampered by lack of resources or experience to perform this procedure.

Besides excision of the marked lymph node, the SLNB has been proposed to replace ALND [1,11–13]. Although accuracy of SLNB has been questioned, our survey shows that a substantial number of respondents does opt for solitary post-NST SLNB to enable subsequent omission of ALND in cN + patients. Several currently accruing trials focus on different less invasive axillary management options for cN + patients treated with NST (amongst others RISAS [10], TAXIS [14], Alliance 11202 [15], NSABP-51/RTOG 1304 [16]). While awaiting results of these ongoing trials to reach consensus and to ensure consistent axillary treatment plans, it is important to inform patients adequately on the benefits and shortcomings of the different available options. Less invasive staging procedures may avoid the morbidity associated with ALND, but may also leave therapy resistant disease behind (of which implications on prognosis are yet unknown).

The vast majority (85%) of respondents who perform less invasive restaging of the axilla with possible omission of ALND relies on the degree of nodal response on imaging to guide axillary staging. Several imaging modalities have previously been studied for their accuracy regarding nodal response assessment [17–19]. In general, imaging is associated with low accuracy for discriminating between axillary pCR and axillary residual disease. Therefore, its use is impeded in clinical practice. Nonetheless, some studies reported on the accuracy of SLNB when performed only in patients who have a complete nodal response on imaging and concluded that incorporating imaging may decrease the risk of missing residual disease [20–22].

This survey has a few limitations. The survey was directed at all breast cancer specialists, yet over 90% of respondents comprised surgeons and surgical oncologists. Approximately 25% of respondents were practicing outside of Europe, which could further add to the wide variety of reported practices. Comments provided by respondents indicated that our survey did not cover all current axillary staging and management practices. Amongst voluntarily reported practices not covered in our survey were: considering breast response as a factor for omission of ALND, sampling lymph nodes with FNAC or CNB after NST to guide axillary surgery, performing SLNB with removing at least 4 sentinel lymph nodes and determining the need for radiotherapy

wait and see, 1x

adjuvant radiotherapy, 1x

dependent on breast response and axillary tumour burden pre-NST.

*Other: 1x

ALND with axillary reverse mapping, 1x

level 1 axillary dissection, 5x

dependent on breast response

and/or axillary tumour burden pre-NST and/or axillary tumour burden post-NST.

*Other: 3x

dependent on axillary tumour burden pre-NST and/or breast surgical treatment plan.

prior to NST. Regarding breast response, previous studies have shown a correlation between a complete response in the breast and ypN0 status [23,24]. However, this link is especially strong in cN0 patients. When it comes to cN + patients, this correlation is weak and breast pCR should therefore not be used to guide axillary surgery.

Some respondents questioned whether the development of recurrences following omission of ALND in cN + patients treated with NST may have legal repercussions. Although the answer options in our survey did not cover all beliefs and practices, our survey did manage to provide a thorough overview of the wide variety of current practices and the associated significant rates for lack of consensus and dissatisfaction with local protocols.

Conclusion

In conclusion, axillary staging and management practices for cN + patients treated with NST appear to vary widely. This indicates the need for a consensus. Breast cancer specialists should continue to join efforts to encourage cN + patients to participate in clinical trials or registries regarding axillary staging and management after NST. Consequently, we can gather evidence and crystallize accurate and safe axillary staging and management of cN + patients treated with NST.

Declarations of interest

None.

Competing interests

The authors have no competing interests to declare.

Acknowledgements

We thank all participants for contributing to this study. We thank the following Associations for assistance with circulating the survey: Association of Breast Surgery, British Association of Surgical Oncology and European Society of Surgical Oncology.

JM Simons received salary from the Dutch Cancer Society (KWF Kankerbestrijding).

References

- [1] van Nijnatten TJ, et al. The diagnostic performance of sentinel lymph node biopsy in pathologically confirmed node positive breast cancer patients after neoadjuvant systemic therapy: a systematic review and meta-analysis. *Eur J Surg Oncol* 2015;41:1278–87.
- [2] Mougalian SS, et al. Ten-year outcomes of patients with breast cancer with cytologically confirmed axillary lymph node metastases and pathologic complete response after primary systemic chemotherapy. *JAMA Oncol* 2016;2:508–16.
- [3] Hennessy BT, et al. Outcome after pathologic complete eradication of cytologically proven breast cancer axillary node metastases following primary chemotherapy. *J Clin Oncol* 2005;23:9304–11.
- [4] Donker M, et al. Marking axillary lymph nodes with radioactive iodine seeds for axillary staging after neoadjuvant systemic treatment in breast cancer patients: the MARI procedure. *Ann Surg* 2015;261:378–82.
- [5] Caudle AS, et al. Improved axillary evaluation following neoadjuvant therapy for patients with node-positive breast cancer using selective evaluation of clipped nodes: implementation of targeted axillary dissection. *J Clin Oncol* 2016;34:1072–8.
- [6] Dominici LS, et al. Cytologically proven axillary lymph node metastases are eradicated in patients receiving preoperative chemotherapy with concurrent trastuzumab for HER2-positive breast cancer. *Cancer* 2010;116:2884–9.
- [7] van la Parra RF, Kuerer HM. Selective elimination of breast cancer surgery in exceptional responders: historical perspective and current trials. *Breast Cancer Res* 2016;18:28.
- [8] Caudle AS, et al. Use of sentinel lymph node dissection after neoadjuvant chemotherapy in patients with node-positive breast cancer at diagnosis: practice patterns of American society of breast surgeons members. *Ann Surg Oncol* 2017;24:2925–34.
- [9] Siso C, et al. Intraoperative ultrasound-guided excision of axillary clip in patients with node-positive breast cancer treated with neoadjuvant therapy (ILINA trial) : a New tool to guide the excision of the clipped node after neoadjuvant treatment. *Ann Surg Oncol* 2018;25:784–91.
- [10] van Nijnatten TJA, et al. A novel less-invasive approach for axillary staging after neoadjuvant chemotherapy in patients with axillary node-positive breast cancer by combining radioactive iodine seed localization in the axilla with the sentinel node procedure (RISAS): a Dutch prospective multicenter validation study. *Clin Breast Canc* 2017;17:399–402.
- [11] Boileau JF, et al. Sentinel node biopsy after neoadjuvant chemotherapy in biopsy-proven node-positive breast cancer: the SN FNAC study. *J Clin Oncol* 2015;33:258–64.
- [12] Boughey JC, et al. Sentinel lymph node surgery after neoadjuvant chemotherapy in patients with node-positive breast cancer: the ACOSOG Z1071 (Alliance) clinical trial. *J Am Med Assoc* 2013;310:1455–61.
- [13] Kuehn T, et al. Sentinel-lymph-node biopsy in patients with breast cancer before and after neoadjuvant chemotherapy (SENTINA): a prospective, multicentre cohort study. *Lancet Oncol* 2013;14:609–18.
- [14] Henke G, et al. Tailored axillary surgery with or without axillary lymph node dissection followed by radiotherapy in patients with clinically node-positive breast cancer (TAXIS): study protocol for a multicenter, randomized phase-III trial. *Trials* 2018;19:667.
- [15] NCT01901094. Comparison of axillary lymph node dissection with axillary radiation for patients with node-positive breast cancer treated with chemotherapy. Principal Investigator: judy boughey. Mayo clinic. Available, <https://clinicaltrials.gov/ct2/show/NCT01901094>. [Accessed 24 January 2019].
- [16] NCT01872975. Standard or comprehensive radiation therapy in Treating Patients with early-stage breast cancer previously treated with chemotherapy and surgery. Principal investigator: norman wolmar, MD. NSABP Foundation Inc. Available at: <https://clinicaltrials.gov/ct2/show/NCT01872975>. Accessed January 24, 2019.
- [17] van Nijnatten TJA, et al. Diagnostic performance of gadofosveset-enhanced axillary MRI for nodal (re)staging in breast cancer patients: results of a validation study. *Clin Radiol* 2018;73:168–75.
- [18] Schipper RJ, et al. Noninvasive nodal restaging in clinically node positive breast cancer patients after neoadjuvant systemic therapy: a systematic review. *Eur J Radiol* 2015;84:41–7.
- [19] Le-Petross HT, et al. Axillary ultrasound identifies residual nodal disease after chemotherapy: results from the American college of surgeons Oncology group Z1071 trial (alliance). *AJR Am J Roentgenol* 2018;210:669–76.
- [20] Boughey JC, et al. Axillary ultrasound after neoadjuvant chemotherapy and its impact on sentinel lymph node surgery: results from the American college of surgeons Oncology group Z1071 trial (alliance). *J Clin Oncol* 2015;33:3386–93.
- [21] Kang E, et al. Feasibility of sentinel lymph node biopsy in breast cancer patients with initial axillary lymph node metastasis after primary systemic therapy. *J Breast Cancer* 2011;14:147–52.
- [22] Pinero-Madrona A, et al. Selective sentinel lymph node biopsy after neoadjuvant chemotherapy in breast cancer: results of the GEICAM 2005-07 study. *Cir Esp* 2015;93:23–9.
- [23] Samiei S, et al. Correlation between pathologic complete response in the breast and absence of axillary lymph node metastases after neoadjuvant systemic therapy. *Ann Surg* 2018. <https://doi.org/10.1097/SLA.0000000000003126>.
- [24] Tadros AB, et al. Identification of patients with documented pathologic complete response in the breast after neoadjuvant chemotherapy for omission of axillary surgery. *JAMA Surg* 2017;152:665–70.