

Herzschr Elektrophys  
<https://doi.org/10.1007/s00399-023-00976-x>  
Received: 8 September 2023  
Accepted: 3 October 2023

© The Author(s), under exclusive licence to  
Springer Medizin Verlag GmbH, ein Teil von  
Springer Nature 2023



# Use of mexiletine in therapy-refractory recurrent ventricular tachycardia storm

Mihaly D. Szonyi<sup>1,2</sup> · Robert Pap<sup>3</sup> · Mate Vamos<sup>3</sup>

<sup>1</sup> Gottsegen National Cardiovascular Center, Budapest, Hungary

<sup>2</sup> Doctoral School of Clinical Medicine, University of Szeged, Szeged, Hungary

<sup>3</sup> Cardiac Electrophysiology Division, Department of Internal Medicine, University of Szeged, Szeged, Hungary

## Abstract

Electrical storm due to recurrent ventricular tachycardias (VTs) is a life-threatening arrhythmic emergency. The authors present a case report of a 69-year-old male patient with VT storm of non-ischemic etiology. Despite optimal medical treatment escalated by amiodarone antiarrhythmic drug therapy, the patient experienced multiple implantable cardioverter defibrillator (ICD) shocks. An electrophysiological study revealed an epicardial substrate; however, considering the patient's extreme obesity and active anticoagulant effect, catheter ablation was deemed to be unfeasible. Subsequently, mexiletine was added to the patient's drug regimen, resulting in successful control of arrhythmias during the following 6 months. Although the most recent European guidelines for the management of patients with ventricular arrhythmias mention mexiletine only for the treatment of LQT3 patients, its use for treatment-refractory VT storm seems to also be an important indication area.

## Keywords

Mexiletine · Antiarrhythmic drugs · Ventricular arrhythmias · VT · ICD · Electric storm · Sodium channel blocker

## Medical history

A 69-year-old male patient had a history of atrial fibrillation, hyperlipidemia, extreme obesity (150 kg), type 2 diabetes mellitus, hypertension and asthma bronchiale. In 2021, he underwent electrical cardioversion due to a monomorphic ventricular tachycardia (VT). Echocardiography showed dilated heart chambers with reduced left ventricular ejection fraction (LVEF: 34%), augmented right ventricular systolic pressure, moderate to severe tricuspid regurgitation, and mild to moderate mitral regurgitation. Coronary angiography excluded significant coronary artery disease. Accordingly, the medical therapy was optimized and a secondary prophylactic single-chamber ICD was implanted (Primo MRI VR DVMD3D1, Medtronic Inc., Minneapolis, MN, USA).

## Observations

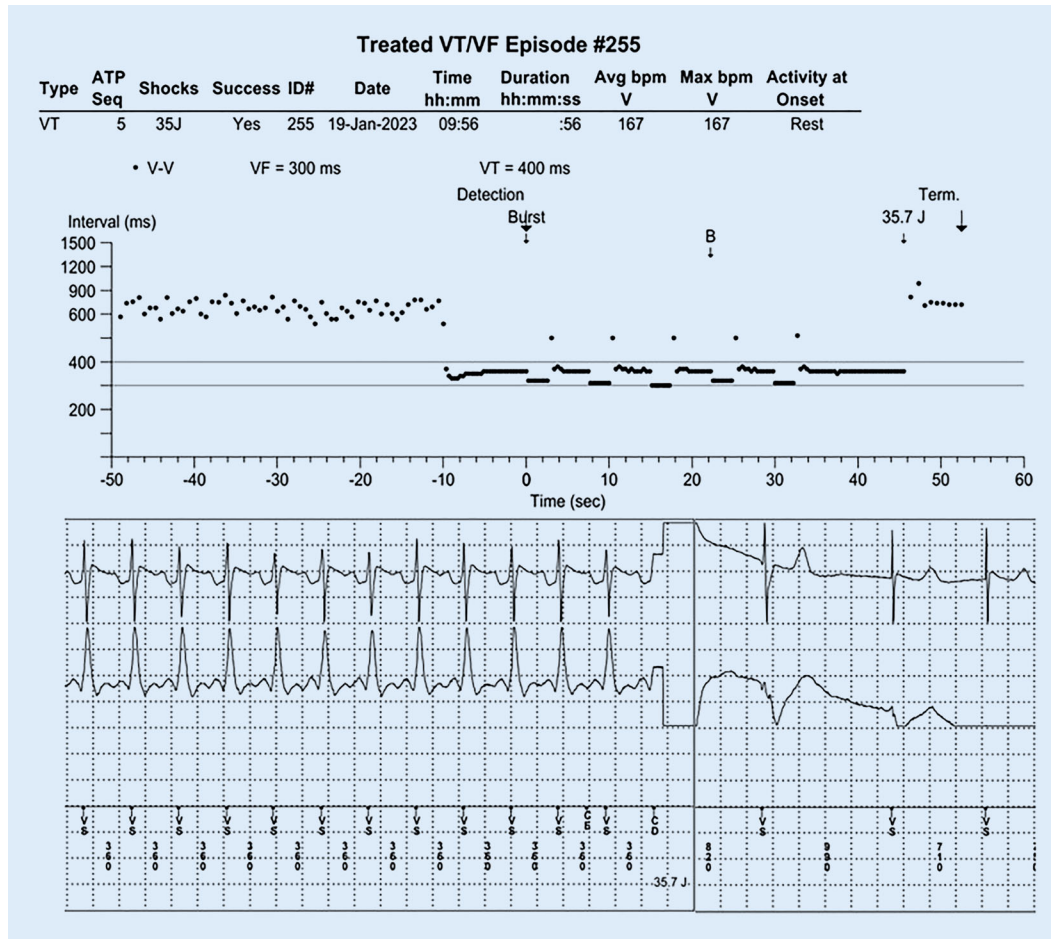
During a series of ambulatory controls, the patient's ICD holter recorded multiple adequate shocks due to monomorphic VT (~170 bpm); antiarrhythmic therapy with amiodarone was subsequently initiated (beyond the maximal dose of metoprolol-succinate). Despite the antiarrhythmic drug therapy, the patient experienced recurrent VT episodes, leading to multiple ICD shocks, presenting to our ward in a VT storm on the 19th of January, 2023 (■ Fig. 1).

## Diagnosis

Reversible causes as triggering factors of the arrhythmia could not be identified. Despite intravenous amiodarone overloading his VTs were incessant, requiring multiple electrical cardioversions and propofol se-



Scan QR code & read article online



**Fig. 1** ◀ One of the ventricular tachycardias recorded and treated by the ICD

dation. Afterwards an electrophysiological study was performed, that suggested an epicardial substrate (▣ Fig. 2).

### Therapy and its course

Due to the patient's extreme obesity an epicardial access would have only been possible after surgical preparation. Considering also the active anticoagulant effect, a decision was made against the epicardial ablation due to the significantly increased procedural risk. Therefore, oral mexiletine (3 × 200 mg) was added to the patient's antiarrhythmic drug regimen. With this escalated antiarrhythmic therapy, the pa-

tient stabilized and no more rhythm disturbances were observed during his hospital stay.

During remote and ambulatory follow-ups, the patient's ICD recorded no malignant arrhythmias, indicating successful control of arrhythmias during the following 6 months. Although the patient experienced tinnitus as a potential side effect, discontinuation of mexiletine did not alleviate the symptom, prompting its reintroduction.

### Discussion

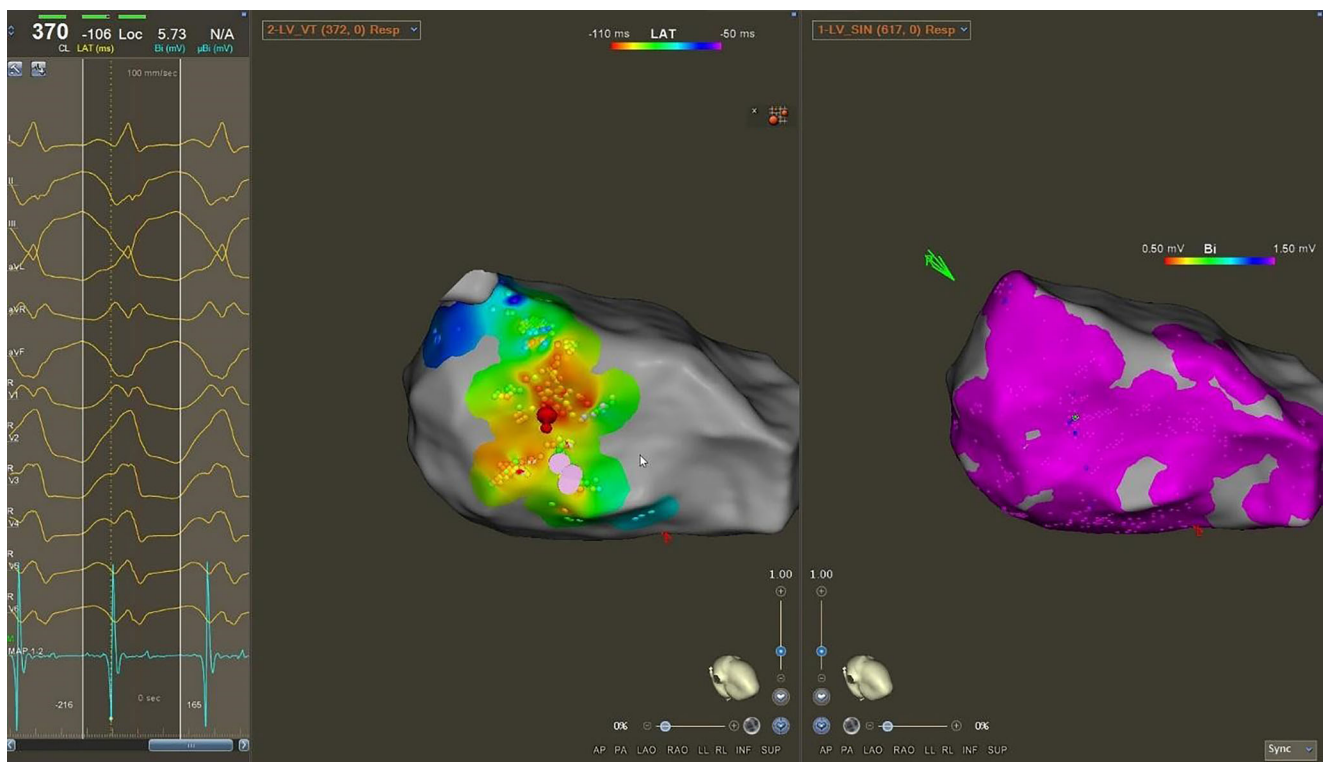
VT storm is a critical condition characterized by recurrent and sustained episodes of VT, often leading to hemodynamic instability and life-threatening consequences [1]. The underlying etiology of VT storm can vary [2], and the management remains challenging, particularly in patients with complex medical history and therapy-resistant arrhythmia [3]. Conventionally, class III antiarrhythmic medication, such

as amiodarone and sedation are employed as the first-line therapy. However, in refractory cases or when ablation is not successful or feasible, alternative treatments need to be explored.

Mexiletine, a class IB antiarrhythmic drug, has emerged as a potential treatment option for patients with therapy-refractory ventricular arrhythmias, including VT storm [4]. By selectively targeting the persistent late inward sodium current ( $I_{Na,late}$ ), mexiletine offers a promising strategy to suppress arrhythmogenic triggers and improve outcomes in this high-risk patient population [5, 6]. By targeting the late sodium current, mexiletine reduces the prolonged action potential duration and abnormal depolarization, thereby stabilizing the cardiac electrophysiological milieu [5].

Recently, two systematic reviews were published regarding the efficacy of mexiletine therapy in patients with incessant or recurrent VT's. In Van der Ree et al's summary, comprising of 221 studies including

Abbreviations	
ICD	Implantable cardioverter defibrillator
LVEF	Left ventricular ejection fraction
PVCs	Premature ventricular contractions
VF	Ventricular fibrillation
VT	Ventricular tachycardia



**Fig. 2** ▲ A 12-lead ECG (a), focal endocardial activation on the left ventricular electroanatomic map during VT (b) and lack of endocardial voltage abnormality during sinus rhythm (c), along with unsuccessful endocardial ablation (red tags) suggested an epicardial VT substrate

8970 patients, a decrease in ventricular arrhythmias of >50% was observed in 72% of the studies for PVCs, 64% for VTs, and 33% for VFs [6]. Ali et al.'s meta-analysis included four studies with 91 implantable cardioverter-defibrillator patients, and they found a significant decrease in the number of ventricular arrhythmias (100% before vs. 60.4% after mexiletine treatment,  $p < 0.001$ ) and appropriate ICD shocks (90.9% before vs. 62.5% after mexiletine treatment,  $p < 0.001$ ) after the administration of mexiletine [7].

In the presented case, in accordance with the results of the aforementioned studies, the addition of mexiletine to the patient's drug regimen resulted in a notable reduction in the occurrence of malignant arrhythmias, as evidenced by the absence of recorded events during remote and ambulatory follow-up. This observation suggests the potential efficacy of mexiletine as an adjunctive therapy in managing refractory VT storm, particularly when conventional treatment approaches have proven insufficient [4]. Traditionally, the combination of class III antiarrhythmic drugs (potassium antagonists) such

as amiodarone with class I antiarrhythmic drugs (sodium antagonists) has been avoided due to the risk of electromechanical uncoupling. However, this risk seems to be comparatively low if patients are well monitored during the phase of initiation and uptitration.

Some gastrointestinal and neurological side-effects of mexiletine (such as nausea, gastrointestinal pain, constipation, diarrhea, tremor, dizziness, headache, paresthesia) deserves monitoring, although most of these are known to be dose-related or can be minimized by taking the drug with food [4, 5].

Notably, the latest European guidelines for the management of patients with ventricular arrhythmias recommend mexiletine as a first-line, genotype-specific treatment strategy for LQT3 patients; however, its use for therapy refractory VT storm is not mentioned at all [1].

This case review highlights the challenges faced in managing patients with VT storm of a non-ischemic etiology. The addition of mexiletine to the patient's drug regimen demonstrated favorable outcomes, suggesting its potential efficacy in

controlling refractory ventricular arrhythmias in VT storm, also when catheter ablation was not feasible. Further investigation and prospective studies involving larger patient cohorts are warranted to explore the role of mexiletine in this patient population, including the optimal dosing regimen and long-term safety profile.

#### Corresponding address

**PD Dr. med. habil. Mate Vamos, MD**  
Cardiac Electrophysiology Division,  
Department of Internal Medicine, University of Szeged  
Semmelweis u. 8., 6725 Szeged, Hungary  
vamos.mate@gmail.com  
vamos.mate@med.u-szeged.hu

#### Declarations

**Conflict of interest.** M. Vamos reports consulting fees and/or nonfinancial support from Biotronik, Medtronic, Biosense Webster and Pfizer outside the submitted work. M.D. Szonyi and R. Pap declare that they have no competing interests.

For images or other information within the manuscript which identify patients, consent was obtained from them and/or their legal guardians.

## References

1. Zeppenfeld K, Tfelt-Hansen J, de Riva M et al (2022) 2022 ESC guidelines for the management of patients with ventricular arrhythmias and the prevention of sudden cardiac death: developed by the task force for the management of patients with ventricular arrhythmias and the prevention of sudden cardiac death. *Eur Heart J* 43:3997–4126. <https://doi.org/10.1093/eurheartj/ehac262>
2. Israel CW, Serge Barold S (2007) Electrical storm in patients with an implanted defibrillator: a matter of definition. *Ann Noninvasive Electrocardiol* 12:375–382. <https://doi.org/10.1111/j.1542-474X.2007.00187.x>
3. Eifling M, Razavi M, Massumi A (2011) The evaluation and management of electrical storm. *Texas Hear Inst J* 38:111–121
4. Vamos M, Zsigmond E-J, Hohnloser SH (2023) Indications for mexiletine in the new ESC guidelines and beyond. *Expert Opin Pharmacother* 24:1403–1407. <https://doi.org/10.1080/14656566.2023.2223964>
5. Brunton LL, Lazo JS, Parker K et al (2006) Book review: goodman and gilman's the pharmacological basis of therapeutics: digital edition, 11th edition. *Ann Pharmacother* 40:1218–1218. <https://doi.org/10.1345/aph.1G685>
6. van der Ree MH, van Dussen L, Rosenberg N et al (2022) Effectiveness and safety of mexiletine in patients at risk for (recurrent) ventricular arrhythmias: a systematic review. *EP Eur* 24:1809–1823. <https://doi.org/10.1093/europace/euac087>
7. Ali H, Cristiano E, Lupo P et al (2022) Oral mexiletine for ventricular tachyarrhythmias treatment in implantable cardioverter-defibrillator patients: a systematic review of the literature. *Minerva Cardiol Angiol*. <https://doi.org/10.23736/S2724-5683.22.06176-2>

**Publisher's Note.** Springer Nature remains neutral with regard to jurisdictional claims in published maps and institutional affiliations.

## Verwendung von Mexiletin bei therapierefraktärem rezidivierendem VT-Sturm (VT: ventrikuläre Tachykardie)

Elektrischer Sturm bei rezidivierenden Kammertachykardien ist ein lebensbedrohlicher arrhythmischer Notfall. Wir präsentieren einen Fallbericht eines 69-jährigen Mannes mit VT-Sturm (VT: ventrikuläre Tachykardie) nichtischämischer Ätiologie. Trotz optimierter medikamentöser Therapie, die auch durch eine antiarrhythmische medikamentöse Therapie mittels Amiodaron eskaliert wurde, erlitt der Patient mehrere ICD-Schocks (ICD: implantierbarer Kardioverterdefibrillator [„implantable cardioverter-defibrillator“]). Eine elektrophysiologische Untersuchung ergab ein epikardiales Substrat. Angesichts der extremen Adipositas des Patienten und der aktiven gerinnungshemmenden Therapie schien eine Katheterablation eher nicht durchführbar zu sein. Anschließend wurde die medikamentöse Therapie mittels Mexiletin ergänzt, was zu einer erfolgreichen Arrhythmiekontrolle über einen Zeitraum von 6 Monaten führte. Obwohl Mexiletin in den neuesten europäischen Leitlinien zur Therapie von Menschen mit ventrikulären Arrhythmien nur zur Behandlung von LQT3-Patienten (LQT3: langes QT-Syndrom Typ 3) erwähnt wird, scheint sein Einsatz bei therapierefraktärem VT-Sturm ebenfalls ein wichtiges Indikationsgebiet zu sein.

### Schlüsselwörter

Mexiletin · Antiarrhythmische Medikamente · Ventrikuläre Arrhythmien · Kammertachykardie · ICD · Elektrischer Sturm · Natriumkanalblocker