

Conclusions: These preliminary results demonstrate that lesions overlapping with the self-voice-network can have an impact on the integrity of one's sense-of-self, as quantified by self-other-voice discrimination. Further investigation including post-operative neuropsychological assessment is envisaged to corroborate the findings in a larger cohort and contribute to the prediction of possible postsurgical deficits.

615

BRAIN AND SPINE 3 (2023) 101794 102333
MULTIUSER 3D-VIRTUAL REALITY (SPECTOVR) AND 3D PRINTED MODEL: TWO EFFECTIVE TEACHING TOOLS IN PEDIATRIC NEUROSURGERY

Ladina Greuter¹, Davide Croci¹, Nicole Frank¹, Florian Thieringer¹, Maria Licci¹, Philippe Cattin¹, Jehuda Soleman¹, Raphael Guzman¹.
¹ University Hospital Of Basel, Switzerland

Oral e-Poster Presentations - Booth 1: Trends & Innovation A, September 26, 2023, 1:00 PM - 2:30 PM

Background: Surgical training has been based on learning through observation. However, nowadays with working hour limitations and increasing patients' safety concerns, surgical training is urged to explore new learning methods. Our aim is to evaluate the user experience and possible negative effects of a Virtual-Reality (VR) platform and 3D printed models for interactive multiuser case discussions in pediatric neurosurgery.

Methods: During the pediatric neurosurgery symposium in Basel, Switzerland in 2019, users attending an interactive case discussion in a full immersion VR platform, called SpectoVR and developed at the Department of Bioengineering at the University of Basel, Switzerland, were asked to fill in a questionnaire regarding their experience with VR focusing on simulator sickness symptoms. Another workshop at the same conference used a 3D printed model to train endoscopy and was evaluated with a separate questionnaire.

Results: A total of 60 participants completed the questionnaire. Most (87.1%) participants previously heard of VR, however, only a third had used it before. Using SpectoVR as a fully immersive platform, only few experienced severe simulator sickness symptoms (16%) and none of the participants had to interrupt their VR experience due to symptoms. Both, SpectoVR and the 3D printed model, were rated accurate in representing the relevant anatomy, useful for teaching and training. Twenty-five (80.6%) participants believe that VR models would enhance their clinical practice and users preferred the VR to the 3D printed models.

Conclusions: VR platforms and 3D printed models allow accurate representation of the surgical anatomy. SpectoVR allows patient-specific 3D model rendering for interactive case discussion with up to seven participants, while 3D printed models are more suitable for practicing a surgical skill. Simulator sickness symptoms in our cohort were rare and nobody had to interrupt their VR experience due to such symptoms. Fully immersive VR tools and 3D printed models have opened a new realm of medical teaching and surgical training.

633

BRAIN AND SPINE 3 (2023) 101794 102334
CLASSIFICATION OF BRAIN TUMORS AND DIFFERENTIATION OF TUMOR BORDERS FROM NORMAL TISSUE THROUGH DEEP LEARNING TECHNIQUE APPLIED OVER MR AND MICROSCOPIC IMAGES TAKEN DURING SURGERIES

Efecan Cekiç¹, Ertugrul Pınar², Merve Pınar¹, Adnan Dacıncı¹. ¹ Marmara University, Istanbul, Turkey; ² Private Pendik Yuzyl Hospital, Istanbul, Turkey

Oral e-Poster Presentations - Booth 1: Trends & Innovation A, September 26, 2023, 1:00 PM - 2:30 PM

Background: The most common brain tumors are metastases, meningiomas, and gliomas. Preoperative radiological images guide the physician to diagnosis. The type of tumor is determined by pathological examination. Removing the tumor as much as possible without damaging the normal brain tissue is the fundamental surgery purpose. To reduce damaging normal tissues during surgery, new technologies are needed. In this study, the classification of tumor types and distinguishing borders is estimated separately and hybrid by deep learning software using the surgical video images and patient's MR images. Authors purposed intraoperative histopathological diagnosis of tumors, modify surgery according to it and increase tumor resection with maximum safety.

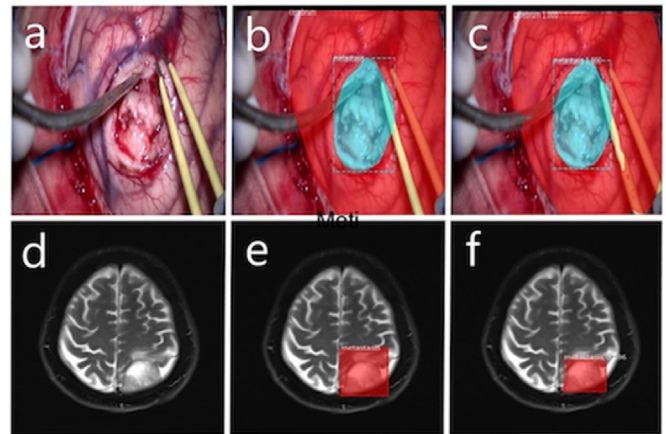
Methods: The article was studied as retrospective study. Dataset was created with videos recorded by a surgical microscope and MRI images of

patients. Images were labeled with VGG Image Annotator (Oxford University). Mask R-CNN was used as algorithm. Classification and border prediction were studied together. As evaluation metrics, precision, recall, DICE, and JAC indexes are used. Surgical microscope dataset was divided into 3: training (2436 (73%)), validation (463 (14%)), and test set (424 (13%)). MR dataset was divided into 2: training (2400 (85.2%)) and test sets (420 (14.8%)).

Results: DICE scores were 94-95% in the validation set, and JAC scores were 89-91%. Validation set reached 96-98% accuracy in pathology estimation (Table 1). In test set, the JAC score results were 69-76% and the DICE score was 72-81%. In pathology prediction, the algorithm reached 83-85% accuracy (Table 2). Estimation of the pathology type in MR images was 90-93% on test set. Accuracy rates in the microscope test set were increased to the range of 93-96% by using algorithm hybrid with both datasets (Table 3). The results were calculated based on the pathology results.

Conclusions: Deep learning algorithms are successful both in terms of border and pathological type prediction using microscope and MR images. Algorithms can help physicians. Integrated operation with augmented reality and neuro-navigation may contribute to robotic surgery.

Optional Image



708

BRAIN AND SPINE 3 (2023) 101794 102335
NOVEL OUTPATIENT TREATMENT STRATEGY FOR CRANIAL INFECTIONS – A SINGLE-CENTER EXPERIENCE

Maximilian-Niklas Bonk¹, Christina Wolfert¹, Philipp Emanuel Kraus¹, Björn Sommer¹, Bastian Stemmer¹, Valeska Simon¹, Reinhard Hoffmann¹, Ehab Shiban¹. ¹ University Hospital Augsburg, Augsburg, Germany

Oral e-Poster Presentations - Booth 1: Trends & Innovation A, September 26, 2023, 1:00 PM - 2:30 PM

Background: Antibiotic therapy of cranial infections is a resource-intensive process. On the background of the recommendation for longer-term antibiotic administration for cranial infections, we established an outpatient intravenous antibiotic administration in our hospital.

Methods: The aim of this study was to evaluate the usefulness of outpatient antibiotic therapy in cranial neurosurgery. For this purpose, we included all patients who received a peripherally inserted central catheter (PICC line) for intravenous antibiotic therapy for cranial infections between 01/20 and 9/22. We evaluated the available patient data with regard to the infectiological and neurosurgical issues. All patients received intravenous antibiotics for at least 6 weeks (inpatient and outpatient).

Results: In total, we were able to include 30 patients. The median age was 58.12 years (SD +/- 13.39 years). The proportion of female patients was 43%. The mean hospital stay was 18.4 days (SD +/- 4.97 days) for total inpatient treatment. Subsequent mean outpatient antibiotic therapy was admitted for 71.7 days (SD +/- 23.18 days). Outpatient mean IV therapy accounted for 53.88 days (SD +/- 18.56 days). The most common pathogens were Staphylococcus epidermidis and cutibacteria. In 9%, microbiological samples were. In all patients, neither radiographic nor laboratory evidence of inflammation was found in the final control. During outpatient intravenous therapy, 12% of patients experienced a difficult patency of the PICC line due to the prolonged administration of antibiotics. This could be corrected radiologically in each case. In addition, one

patient, independent of therapy, showed structural epilepsy after the abscess healing.

Conclusions: Outpatient IV antibiotic therapy via a PICC line catheter is a safe and feasible method for long-term antibiotic treatment of cranial infections.

844

BRAIN AND SPINE 3 (2023) 101794 102336
INNOVATIVE NON-INVASIVE TECHNOLOGY FOR INTRACRANIAL COMPLIANCE MONITORING

Edvinas Chaleckas¹, Vilma Putnynaite¹, Vytautas Petkus¹, Romanas Chomskis¹, Mantas Deimantavicius¹, Laimonas Bartusis¹, Rolandas Zakelis¹, Yasin Hamarat¹, Indre Lapinskiene², Aidanas Preiksaitis², Mindaugas Serpytis², Saulius Rocka², Tomas Jovaisa², Arminas Ragauskas^{1,2}.

¹ Health Telematics Science Institute, Kaunas University of Technology, Kaunas, Lithuania; ² Clinic of Neurology and Neurosurgery, Faculty of Medicine, Vilnius, Lithuania

Oral e-Poster Presentations - Booth 1: Trends & Innovation A, September 26, 2023, 1:00 PM - 2:30 PM

Background: Intracranial compliance (ICC) has been studied to add the value for interpretation of intracranial pressure (ICP) in neuro-critical care and to help to personalize treatment decision making. Invasive ICC (iICC) monitoring is possible using real-time analysis of morphology of iICP pulse waves. It has been shown in previous studies that iICC changes have been linked to iICP pulse wave tidal peak's (P2) amplitude and upstroke peak's (P1) amplitude ratio changes. It has been also demonstrated by analysis of CENTER-TBI study data base that iICP pulse wave shape derived parameters are predictors of mortality after TBI. Such biomarkers were associated with poor outcome in patients with low iICP. Latest studies support the importance of iICP pulse wave form analysis in addition to recording mean iICP. Unfortunately, non-invasive sensors for nICP pulse wave form recording with accuracy and precision needed for clinical practice do not exist.

Methods: Novel technology is proposed for nICP pulse wave recording and analysis. Codman invasive sensors were used for iICP pulse wave recordings. Novel non-invasive nICP sensor is gently applied to the closed eye lid of TBI or stroke patients. 6 piglets were included into animal study of novel sensor's performance. Patients with low, normal and high ICC were included into clinical study.

Results: We found that proposed novel technology records nICP pulse waves which highly correlates ($R = [0,97;0,99]$) with simultaneously recorded iICP pulse waves.

Conclusions: Our study shows that proposed technology is able to record nICP pulse waves which highly correlates ($R=[0,97;0,99]$) with simultaneously recorded iICP pulse waves. nICC real-time monitoring with clinically needed accuracy and precision is possible by using proposed technology.

845

BRAIN AND SPINE 3 (2023) 101794 102337
INTRODUCING A NEW GRADING SYSTEM FOR HEMIFACIAL SPASM SEVERITY USING FACIAL RECOGNITION AND FACIAL TRACKING TECHNOLOGY

Ahmed Al Menabbawy^{1,2}, Lennart Ruhser¹, Ehab El Refaee^{1,2}, Marc Matthes¹, Henry Schroeder¹. ¹ University Medicine Greifswald, Greifswald, Germany; ² Cairo University Hospitals, Cairo, Egypt

Oral e-Poster Presentations - Booth 1: Trends & Innovation A, September 26, 2023, 1:00 PM - 2:30 PM

Background: Hemifacial spasm severity is difficult to be quantified accurately due to the paroxysmal nature of the spasm's frequency. Postoperative outcomes vary among the different patients. Only few studies considered the severity of the preoperative spasms severity into account while evaluating the outcome of surgery. However, the current grading systems are unfortunately not very easy to implement and in many cases the categories overlap. Currently, many technological tools have been available at hand such as facial recognition and tracking technologies. We describe a novel modality to quantify and grade hemifacial

spasms severity precisely.

Methods: Retrospective review of our prospectively maintained database for MVD was done. Preoperative videos were evaluated using Blender open-source software for facial movement tracking. Relevant demographics, disease, and patient related data were also extracted. Blender Software was run to detect the motion for an objective measure of the intensity and severity of the spasms.

Results: We analyzed 50 preoperative videos. The severity varied among patients in terms of the intensity of the spasms and their frequency. We could identify 5 different spasm intensity amplitude ranges and 5 frequency ranges. Accordingly, the patients could be classified into 5 different severity levels.

Conclusions: Facial recognition and tracking technology are accurate and reliable in calculating the severity of hemifacial spasms and can help us objectively comparing the preoperative to the postoperative outcome in patients with persistent spasms.

871

BRAIN AND SPINE 3 (2023) 101794 102338
DIGITAL PATIENT-SPECIFIC 3D MODEL AS AN OBJECTIVE ASSESSMENT TOOL FOR NEUROSURGICAL PLANNING SKILLS

Sahin Hanalioglu¹, Ilkay Isikay¹, Muhammet Enes Gurses¹, Baylar Baylarov¹, Osman Tunc², Nergiz Ercil Cagiltay³, Ilkan Tatar¹, Mustafa Berker¹.

¹ Hacettepe University, Ankara, Turkey; ² Btech Innovation, Ankara, Turkey; ³ Atilim University, Ankara, Turkey

Oral e-Poster Presentations - Booth 1: Trends & Innovation A, September 26, 2023, 1:00 PM - 2:30 PM

Background: Neurosurgical patient-specific 3D models have been shown to facilitate learning, enhance planning skills and improve surgical results. However, there is limited data on the objective validation of these models. Here, we aim to investigate their potential for improving the accuracy of surgical planning process of the neurosurgery residents and their usage as a surgical planning skill assessment tool.

Methods: A patient-specific 3D digital model of parasagittal meningioma case was constructed. Participants were invited to plan the incision and craniotomy first after the conventional planning session with MRI, and then with 3D model. A feedback survey was performed at the end of the session. Quantitative metrics were used to assess the performance of the participants in a double-blind fashion.

Results: A total of 38 neurosurgical residents and interns participated in this study. For estimated tumor projection on scalp, percent tumor coverage increased ($66.4 \pm 26.2\%$ to $77.2 \pm 17.4\%$, $p=0.026$), excess coverage decreased (2232 ± 1322 mm² to 1662 ± 956 mm², $p=0.019$); and craniotomy margin deviation from acceptable the standard was reduced (57.3 ± 24.0 mm to 47.2 ± 19.8 mm, $p=0.024$) after training with 3D model. For linear skin incision, deviation from tumor epicenter significantly reduced from 16.3 ± 9.6 mm to 8.3 ± 7.9 mm after training with 3D model only in residents ($p=0.02$). The participants scored realism, performance, usefulness, and practicality of the digital 3D models very highly.

Conclusions: Patient-specific digital 3D models can be used as educational materials to improve the surgical planning accuracy of neurosurgical residents and to objectively assess their surgical planning skills through various surgical scenarios.

876

BRAIN AND SPINE 3 (2023) 101794 102339
EARLY EXPERIENCE WITH ROBOTIC MICROVASCULAR ANASTOMOSES

Daniel Wiggan¹, Corinne Rabbin-Birnbaum¹, Karl Sangwon¹, Albert Liu¹, Erez Nossek¹, Osamah Choudhry¹. ¹ NYU Langone Health, Manhattan, United States

Oral e-Poster Presentations - Booth 1: Trends & Innovation A, September 26, 2023, 1:00 PM - 2:30 PM

Background: Robotics are becoming increasingly widespread within various neurosurgical subspecialties. The adoption of robotic technology within vascular neurosurgery is of great interest, but data pertaining to its feasibility is currently limited. In this paper we present our novel attempt to evaluate the learning curve