


CASE STUDY

Longitudinal study on nerve ultrasound and corneal confocal microscopy in NF155 paranodopathy

Diamantis Athanasopoulos¹ , Jeremias Motte¹, Anna Lena Fisse¹, Thomas Grueter¹, Nadine Trampe², Dietrich Sturm^{3,4}, Martin Tegenthoff⁴, Melissa Sgodzai¹, Rafael Klimas¹, Luis Querol⁵, Ralf Gold¹ & Kalliopi Pitarokoili¹

¹Department of Neurology, St. Josef Hospital, Ruhr-University, Bochum, Germany

²Department of Neurology, Katholische Kliniken Emscher-Lippe, Germany

³Department of Neurology, Agaplesion Bethesda Hospital, Wuppertal, Germany

⁴Department of Neurology, Bergmannsheil University Hospital, Ruhr University, Bochum, Germany

⁵Unidad de Enfermedades Neuromusculares, Hospital de la Santa Creu i Sant Pau, Barcelona, Spain

Correspondence

Diamantis Athanasopoulos, Department of Neurology, Ruhr University, St. Josef-Hospital, Gudrunstr. 56, 44791 Bochum, Germany. Tel: 0049-15237894362; Fax: 0049-2345092414; E-mail: diamantis.athanasopoulos@ruhr-uni-bochum.de

Funding information

There was no funding source.

Received: 18 March 2020; Revised: 24 April

2020; Accepted: 24 April 2020

Annals of Clinical and Translational Neurology 2020; 7(6): 1061–1068

doi: 10.1002/acn3.51061

Introduction

Chronic inflammatory demyelinating polyneuropathy (CIDP) is a rare relapsing autoimmune neuropathy with a multifaceted presentation.^{1–3} Recently, the description of pathogenic antibodies – predominantly of the IgG4 class – against nodal and paranodal proteins such as neurofascin-186, neurofascin-155, contactin-1, and contactin-associated protein-1 has shed new light to a small subset of CIDP cases.^{4–7}

More specifically, antibodies against neurofascin-155 (NF155) correlate with a distinct clinical phenotype.^{8–14} The response to first-line treatment with intravenous immunoglobulins (IVIg) is poor^{9–11,13,14} but patients show a good response to anti-CD20 targeted therapy.^{13–16}

Here, we report the case of a 27-year-old male with anti-NF155 antibody-positive neuropathy with poor

Abstract

We report the case of a 27-year-old patient with subacute anti-neurofascin-155 neuropathy with bifacial palsy, who showed excellent response to rituximab. We provide longitudinal data of established clinical scores, nerve conduction studies, antibody titers, and novel imaging methods (nerve ultrasonography and corneal confocal microscopy). Clinical and electrophysiological improvement followed the reduction of serum antibody titer and correlated with a reduction of corneal inflammatory cellular infiltrates whereas the increase in the cross-sectional area of the peripheral nerves remained 12 months after first manifestation. Our findings suggest that novel techniques provide useful follow-up parameters in paranodopathies.

response to IVIg but a good response to rituximab (RTX). We provide for the first time in the literature longitudinal findings of high-resolution nerve ultrasound (HRUS) and corneal confocal microscopy (CCM).

Case Description and Results

A 27-year-old male patient was admitted to the clinic due to a subacute, progressive sensorimotor affection of all four extremities. Onset was reported approximately 3 weeks before admission beginning with ascending numbness and prickling of the feet and hands, which rapidly involved the lower extremities up to the groin, followed by a progressive, predominantly distal muscle weakness with concomitant gait disorder. He also reported distal leg pain. No difficulty of speech or swallowing was reported. Mild diarrhea occurred a few weeks before. The past medical and

family history was unremarkable, except from a history of 8 pack-years of cigarette consume and penicillin allergy.

On clinical examination, hypoesthesia of the hands and the lower body with pallesthesia and areflexia of the legs, minor flaccid symmetric distal tetraparesis as well as limb and gait ataxia were noted. Distally, finger flexion and foot dorsiflexion were grade 4 of the Medical Research Council (MRC) sum score on both sides. The remainder of the examination was normal. No autonomic dysfunction was noted.

Cerebrospinal fluid (CSF) analysis revealed an albuminocytologic dissociation with marked increase in protein of 319 mg/dl (normal 15–45 mg/dl) and normal cell count. Oligoclonal bands were absent. Further laboratory testing for other causes of polyneuropathy revealed no abnormalities. Anti-neurofascin-155 IgG (of the IgG4 subclass) antibodies were positive in a high titer of 1:3200 (detected with cell-based immunofluorescence and confirmed with teased-nerve method in two different laboratories). No further antibodies were detected.

NCS revealed marked prolongation of distal motor latency (DML) and F-wave-latencies symmetrically affecting the nerves of the upper extremities and a less symmetric reduction of motor conduction velocity (mCV). The compound muscle action potential (cMAP) amplitudes were normal. The nerves of the lower extremities were not excitable (Figure 1, Table S1). The EFNS/PNS criteria for definite CIDP were fulfilled. MRI studies of the brain and the complete spinal axis were unremarkable.

The initial treatment, pending results of the serology panel, was five cycles of plasma exchange (PE). A brief improvement was followed by a deterioration, including bifacial palsy in approximately 1 week. In view of the in the meantime available positive results for NF155 antibodies the therapy was immediately escalated to RTX (cumulative 2g). Due to a further relapse with deterioration of muscle weakness 1 month later, the patient was treated with IVIg (2 g/kg of body weight) without significant improvement. Therefore, a course of intravenous corticosteroids (4.5 g prednisolone over 5 days) followed by a further PE session (six cycles) were applied. This led to clinical stabilization. However, improvement occurred only 5 months after disease onset (approximately 3 months after Rituximab application). During the following months symptoms improved steadily. At 12 months, we noted a complete recovery of muscle strength, facial weakness, and subjective sensory deficits. Minor gait instability and sensory ataxia persisted, but the patient could walk without aids (Table 1). Repeat treatment with RTX was planned.

The titer of anti-NF155 antibodies started to diminish promptly after initiation of treatment already at first month. This decrease preceded the clinical and electrophysiological improvement (Table 1).

The nerves of the lower extremities remained not excitable after 12 months despite clinical improvement. At the nerves of the upper extremities DML, F-wave-latencies and cMAP-duration prolongation was detected with a peak at 2 months, cMAP amplitudes decreased with a maximum at 5 months. The mCV reduction plateaued at 2 to 5 months. At 12 months mCV, F-wave-latency and cMAP-duration were mostly normalized, cMAP amplitudes and DML also significantly recovered (Figure 1, Table S1).

Needle electromyography initially showed abnormal spontaneous activity which persisted after 12 months. Chronic neurogenic changes were noted at month 2 and also persisted thereafter.

HRUS was performed with the use of an 18 MHz ultrasound transducer. The median, ulnar, common radial, tibial, fibular and sural nerves were studied bilaterally throughout their visualizable courses. The brachial plexus was also assessed in the supraclavicular and interscalene spaces. Standardized CSA measurements were performed at 30 predefined locations according to the protocol of our group.^{17,18} At 2 months after initial diagnosis multifocal peripheral nerve enlargement (median, ulnar, and tibial nerve) was noted. The brachial plexus was enlarged bilaterally. In the following months more nerves showed a cross-sectional area (CSA) enlargement (radial nerve). The Bochum ultrasound score¹⁹ (BUS, ranging from 0 to 4 points, with 1 point given for increased CSA at each of the four following sites: ulnar nerve in Guyons' canal, ulnar nerve in the upper arm, radial nerve in the spiral groove, and sural nerve between the gastrocnemius muscle), which was developed from our group as a marker of CIDP (if more than two sites show increased CSA, score of 2 or more), reached the maximum of 3 points 12 months after initial presentation. A further HRUS marker for clinical progression is the intranerve CSA variability²⁰ (max CSA/min CSA of one nerve), which increased for the majority of the nerves 2–5 months after the initial presentation and stabilized at high values 12 months after. (Figure 2, Table 2).

CCM was performed with a Heidelberg Retina Tomograph III with a Rostock cornea module, the images were analyzed with ACC-Metrics software, version 2.0 (Xin Chen and Mohammad Dabbah, Manchester, UK), the average of five images was calculated. Two months after initial diagnosis CCM showed an increased number of corneal cell infiltrates (121/mm²), but normal corneal nerve fiber density and corneal nerve branch density and only a minor reduction in corneal nerve fiber length. After 12 months the corneal cell infiltrates were markedly reduced (21/mm²). However, there was a progressive reduction in the corneal nerve fiber length and density (Figure 3).

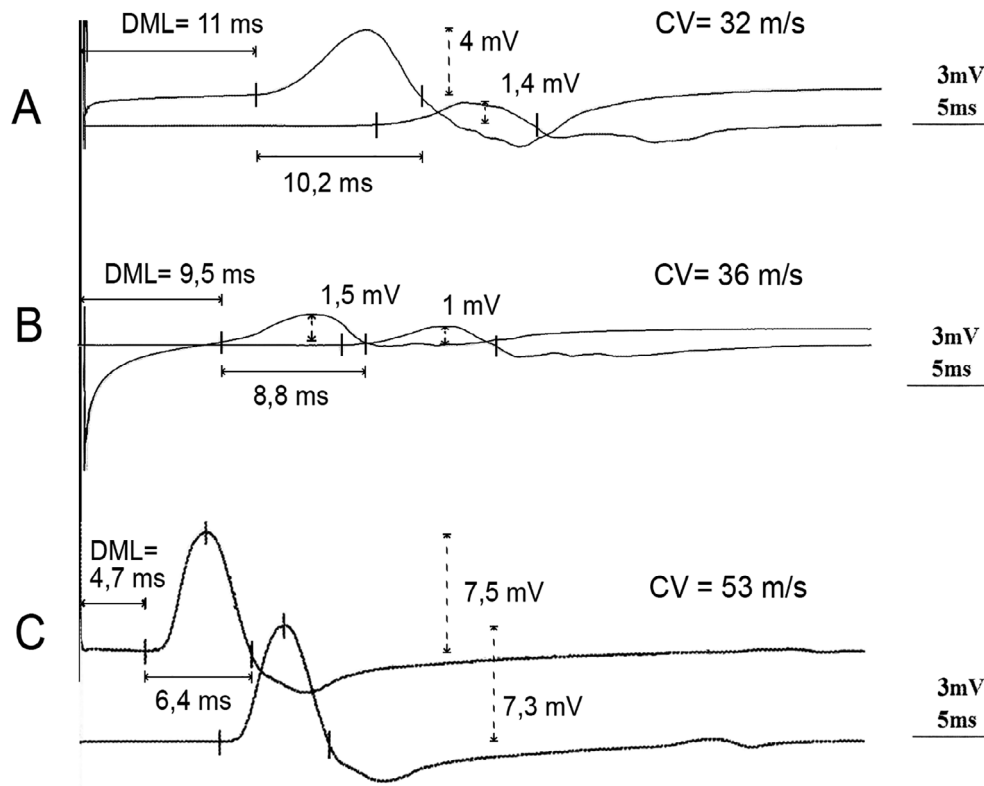


Figure 1. Electroneurography traces of the left median nerve at 2 (Panel A), 5 (Panel B), and 12 months (Panel C). cMAPs after stimulation at the wrist and the elbow. At 2 months a marked prolongation of DML and distal cMAP duration as well as CV slowing were observed. Furthermore a conduction block, with reduction of the cMAP amplitudes >50% after proximal stimulation, is noted. At 5 months the distal cMAP amplitudes are also diminished, while DML, CV, and distal cMAP duration are slightly improved. At 12 months an almost full recovery is observed. The distal cMAP amplitude also recovers to normal values, indicating that the previous marked reduction was mainly due to a distal conduction block. DML, distal motor latency; CV, conduction velocity; cMAP, compound muscle action potential.

Table 1. Evolution of clinical scores, NF155 antibodies titer and CCM parameters

	Onset	1 month	2 months	3 months	5 months	12 months
MRCss	73	65	64.5	52.5	51	80
INCAT/ODSS	3	5	5	6	6	3
NF155 Antibody Titer	1:3200	1:1000	1:320	1:100	1:32	1:32
CCM (cells/mm ²)	121	–	–	–	–	21

INCAT/ODSS, Inflammatory Neuropathy Cause and Treatment Overall Disability Sum Score; MRCss, modified Medical Research Council sum score (max. of 80 with lower scores corresponding to lower muscle strength).

Discussion

This case demonstrates a thorough longitudinal study of a paranodal neuropathy. Acute presentation and progression over 8 weeks in combination with the nerve conduction studies and CSF findings led to the clinical diagnosis of a chronic demyelinating inflammatory polyradiculoneuropathy. Prompt testing for anti-NF155 antibodies helped to diagnose an anti-NF155 immune neuropathy

and enabled early treatment with RTX, based on prior small case series.^{13–16,21}

Bifacial palsy was a noteworthy feature in our case. This is a common manifestation of Guillain-Barré syndrome but rare in CIDP. Cases of NF155 neuropathy with cranial nerve involvement have been reported,^{22,23} the exact incidence remains unknown. In the case of Miller Fisher syndrome, Chiba et al²⁴ showed that GQ1b expression is proportionally higher in oculomotor nerves.

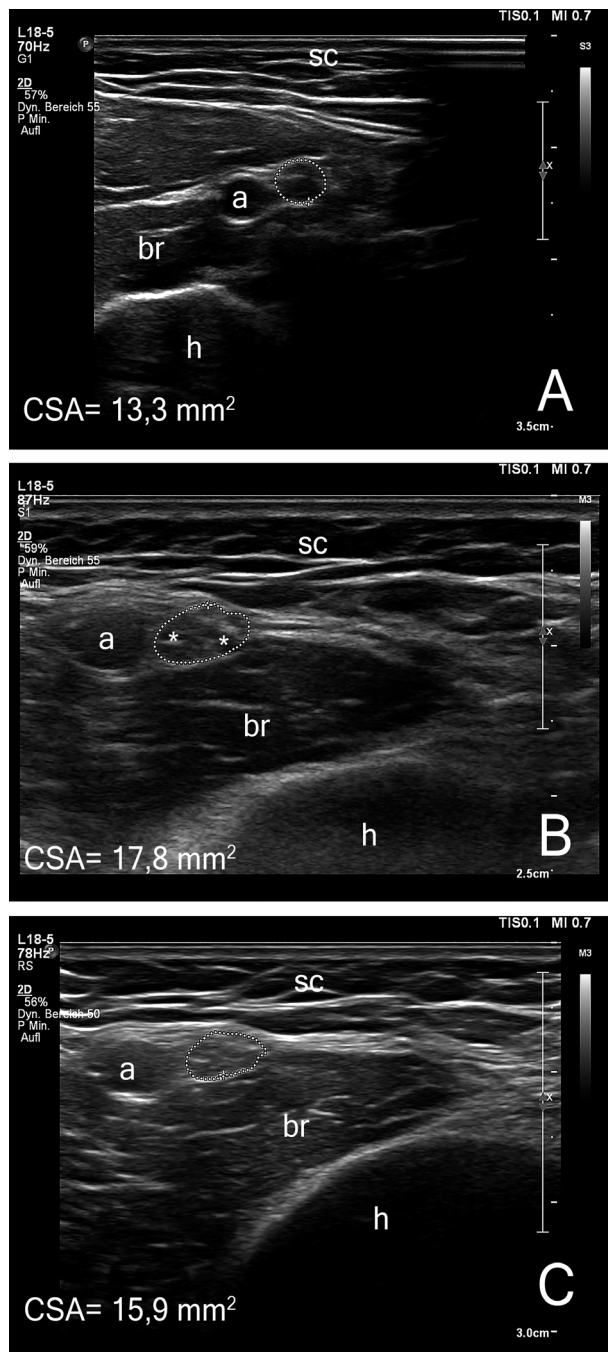


Figure 2. Representative images of high-resolution nerve ultrasound. Transverse images of the left median nerve at the distal upper arm are shown at 2 (Panel A), 5 (Panel B), and 12 months (Panel C). The cross section of the median nerve is outlined with a dotted circle, (h) denotes the humerus, (a) the brachial artery, (sc) the subcutaneous fat. Asterisks in panel B mark individual nerve fascicles. The initially normal CSA increases significantly between months 2 and 5 in the active disease phase (reference range 2,6–14,1 mm²). After clinical stabilization nerve swelling shows a small reduction. Intranerve CSA variability shows a corresponding course. (s. Table 2). CSA, cross-sectional area.

Further studies are required to determine the specific expression of NF155 in cranial nerves.

As previously reported^{9–11,13,14} treatment response after IVIg was poor in our patient. Corticosteroid treatment did not infer any relevant improvement either, which is why we escalated to PE after the second relapse. Although at initial presentation PE lead to a minor and only temporary improvement, disease progression was stopped after the second PE treatment. Although PE was less effective regarding improvement, it led to a decrease in the antibody titer (1 month later). However, the timing of clinical stabilization and the following robust remission (5 months after initial presentation and 4 months after Rituximab) without need for further interventions argue that the anti-CD20 treatment was mainly responsible.

As previously shown^{25,26} the improvement of electrophysiological parameters correlated with the clinical improvement in a lagged fashion, demonstrating that new methods with better temporal correlation to the clinical development are needed.

The anti-NF155 antibodies titer fell promptly after treatment initiation (PE and Rituximab). This trend preceded clinical improvement. Further studies are needed to show if anti-NF155 antibody titers are a useful prognostic and disease monitoring tool.²⁷

To our knowledge, this is the second report¹³ of HRUS findings in anti-NF155 antibody-positive neuropathy, but a longitudinal study has never reported before yet. We saw a multifocal and asymmetric swelling of the nerves distally as well as proximally. The nerves were hypoechogenic, which could imply an inflammatory affection according to previous data.²⁸ The increased CSA of multiple peripheral nerves correlated with previous reports^{10,13} and in accordance with the expected changes in inflammatory neuropathies.^{19,29,30} Bochum ultrasound score increased successively from 1 to 3 points in the course of 12 months indicating that acute paranodopathies do not present with typical sonographical BUS characteristics at the beginning of the disease. An increase in intranerve CSA variability for the majority of nerves coincided temporally with the active disease phase between months 2 and 5. We have previously shown that the increase in CSA variability and BUS correspond with disease progression in typical CIDP.^{20,31,32} At 12 months we did not observe a relevant improvement of CSA or its intranerve variability despite clinical improvement. This could be attributed to the follow-up interval, as previous studies^{20,33} show an improvement over a period of more than 12 months. However, there are no previous longitudinal ultrasound studies on paranodopathies.

To our knowledge, this is the first report of the use of CCM in a case of anti-NF155 antibody-positive autoimmune neuropathy. CCM is a noninvasive technique which

Table 2. Sonographic mean cross-sectional area values in mm².

Nerve	Site	2 Month		5 Month		12 Month		Ref. range
		Right	Left	Right	Left	Right	Left	
Median	Carpal tunnel	15,1	13,4	13,7	13,7	10,9	11,5	1,3–12,6
	Forearm	8	8,2	7,5	7,9	6,73	6,75	3,4–12,6
	Upper arm	14,5	13,3	20,0	17,8	21,9	15,9	2,6–14,1
	<i>intranerve CSA variability</i>	1,8	1,61	2,66	2,25	3,25	2,35	<1,5
Ulnar	Gyuo canal	6,6	5,5	5,03	7,59	9,76	6,16	3,1–7,2
	Forearm	7,6	8,5	6,3	6,79	6,83	5,89	2,9–8,0
	Elbow	7,7	9,3	7,99	8,78	8,57	11	2,5–8,1
	Upper arm	7,7	7,7	9,94	9,43	12,3	9,92	2,9–10,2
	<i>intranerve CSA variability</i>	1,16	1,69	1,97	1,39	1,80	1,86	<1,5
Radial	Spiral groove	6,2	8,7	12,8	7,1	5,69	8,19	0,2–6,3
Brachial Plexus	Intrascapular space	65,1	n/a	20,4	20,1	48,4	35,1	9,3–52,6
	Supraclavicular space	144	145	117	99	96,5	91,8	9,6–82,7
Fibular	Fibular Head	9,9	11,6	9,35	8,72	17,2	10,7	2,5–11,7
	Popliteal fossa	5,2	8,5	11,6	7,69	14,7	10,4	4,0–13,2
	<i>intranerve CSA variability</i>	1,9	1,36	1,24	1,13	1,17	1,03	<1,5
Tibial	Popliteal fossa	23	25,3	44,1	36,8	39,3	47,9	3,0–13,8
	Ankle	14,4	13,6	13,2	15,8	14,5	15,2	3,4–9,2
	<i>intranerve CSA variability</i>	1,59	1,86	3,34	2,33	2,71	3,15	<1,5
Sural	Between heads of gastrocnemius	2,2	2,5	1,4	1,61	1,79	1,53	0,5–3

CSA, cross-sectional area.

has shown its capacity to detect small fiber damage in several types of neuropathies³⁴ and it is used in inflammatory neuropathies recently.^{32,35,36} Patients with autonomic neuropathies and CIDP patients with symptoms of small fiber damage, such as painful neuropathy, show a greater loss of corneal nerve fibers. However, classical CIDP patients still show significant abnormalities.^{35,36} The small fiber damage in the cornea may thus mirror an axonal damage of the peripheral nerves. In our patient a marked decrease in corneal nerve parameters correlated with a remaining reduction of the amplitudes of the nerves in the lower extremities over the course of time. It is noteworthy that no signs or symptoms of small fiber neuropathy were noted at 12 months and the paraesthesias the patient had at presentation had resolved. We have recently shown that an increased number of inflammatory corneal cell infiltrates correlates with disease progression in immunoneuropathies.³² Conversely, in this case the reduction in inflammatory cell infiltrates correlated with clinical remission.

Concluding, we investigated for the first time further CCM and HRUS markers of disease activity in a case of paranodopathy. Surely, longitudinal testing in a larger number of patients is needed to better understand the temporal relation of these alterations but these methods seem to be promising to determine axonal degeneration and inflammatory activity in paranodopathies.

Conflicts of Interest

Athanasopoulos Diamantis has no conflict of interest to report. Jeremias Motte received travel grants from Biogen idec, Novartis AG, Teva and Eisai GmbH, his research is funded by Klaus Tschira Foundation and Ruhr-University, Bochum (FoRUM-program), none related to this work. Anna Lena Fisse received research funding by Georgius Agricola Stiftung Ruhr, received honoraria and travel grants from Novartis AG, Sanofi and Eisai GmbH, none related to this work. Owns shares of Fresenius SE & Co., Gilead Sciences, Medtronic PLC and Novartis AG. Thomas Grueter received travel reimbursement from Sanofi Genzyme and Biogen Idec, none related to this work. Dietrich Sturm received research funding from the Ruhr-University, Bochum (FoRUM-program), none related to this work. Martin Tegenthoff has received speaker honoraria from Pfizer, Novartis, and Mundipharma. He also acknowledges a grant support from Genzyme, none related to this work. Nadine Trampe, Melissa Sgodzai, and Rafael Klimas have no conflict of interest to report. Luis Querol has provided expert testimony for Grifols, SanofiGenzyme, Novartis, UCB, Roche, CSL Behring, Johnson and Johnson, Alexion and Annexon, has received research funds from Novartis Spain, Sanofi-Genzyme, and Grifols, research support from the GBS-CIDP Foundation and the Department of Health of the Government of

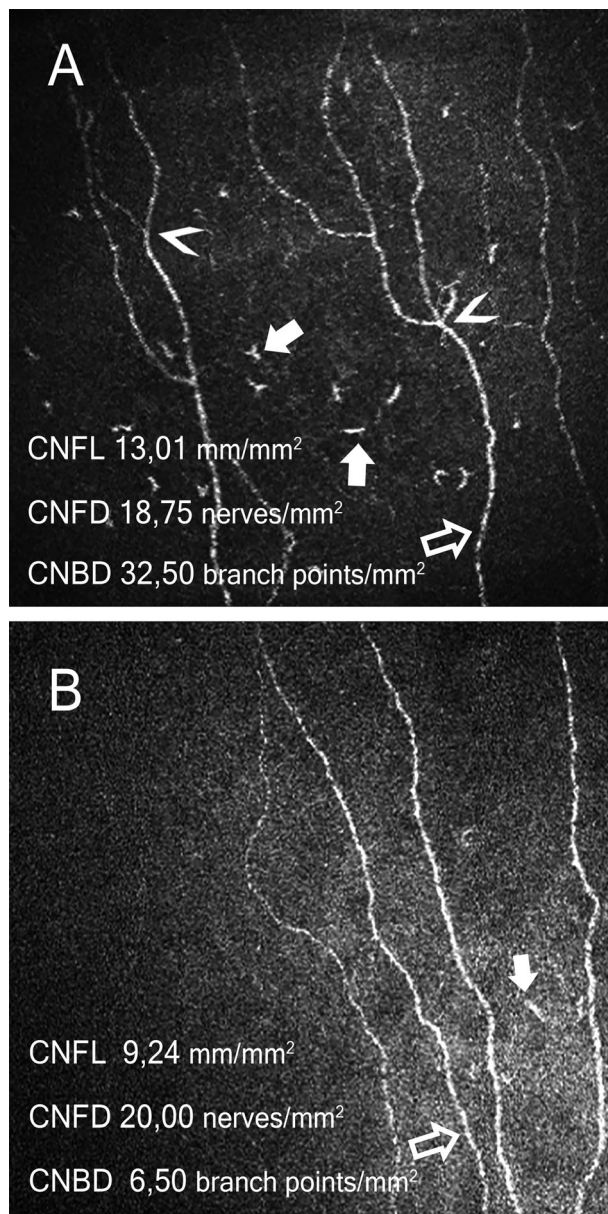


Figure 3. Representative images of corneal confocal microscopy at 2 (Panel A) and 12 months (Panel B). Nerve fibers indicated with open arrows, corneal immunological cells with solid arrows, nerve branch points with arrowheads. At 2 months increased cellular infiltrates of 121/mm² were observed, which were reduced to 21/mm² after treatment. The CNFL and CNBD decreased over the period of time. CNFL, corneal nerve fiber length (normal value > 14,05 mm/mm²), CNFD, corneal nerve fiber density (normal value > 14,54 nerves/mm²), CNBD, corneal nerve branch density (normal value > 16,49 branching points/mm²), normal values from Tavakoli et al. 2015.

Catalonia, as well as travel funding and speaker honoraria from CSL Behring, Novartis and Biogen. R. Gold has received consultation fees and speaker honoraria from Bayer Schering, Biogen idec, Merck Serono, Novartis,

Sanofi-Aventis and TEVA. He also acknowledges grant support from Bayer Schering, Biogen idec, Merck Serono, Sanofi-Aventis and TEVA, none related to this work. Kalliopi Pitarokoili received travel funding and speaker honoraria from Biogen Idec, Novartis and Bayer Schering Pharma and funding from the Ruhr-University, Bochum (FORUM-Program), none related to this work.

Author Contributions

All authors have read and approved the manuscript. Athanasopoulos Diamantis and Jeremias Motte were involved in patient treatment, acquisition, analysis and interpretation of data, and drafting/revising the manuscript for content. Anna Lena Fisse, Thomas Grueter, and Dietrich Sturm were involved in acquisition, analysis and interpretation of data, and drafting/revising the manuscript for content. Nadine Trampe was involved in patient treatment, acquisition, analysis and interpretation of data, and revising the manuscript for content. Martin Tegenhoff, Luis Querol, and Ralf Gold were involved in critical comments during data collection, drafting and manuscript revision. Melissa Sgodzai and Rafael Klimas were involved in acquisition, analysis and interpretation of data, revising the manuscript for content. Kalliopi Pitarokoili was involved in first idea, patient treatment, acquisition, analysis and interpretation of data, drafting and manuscript revision, and study supervision.

Ethical Standards

The patient gave written informed consent.

References

1. Broers MC, Bunschoten C, Nieboer D, et al. Incidence and prevalence of chronic inflammatory demyelinating polyradiculoneuropathy: a systematic review and meta-analysis. *Neuroepidemiology* 2019;52:161–172. <https://doi.org/10.1159/000494291>.
2. Bunschoten C, Jacobs BC, Van den Bergh PYK, et al. Progress in diagnosis and treatment of chronic inflammatory demyelinating polyradiculoneuropathy. *Lancet Neurol* 2019;18:784–794. [https://doi.org/10.1016/S1474-4422\(19\)30144-9](https://doi.org/10.1016/S1474-4422(19)30144-9). Epub 2019 May 7.
3. Lehmann HC, Burke D, Kuwabara S. Chronic inflammatory demyelinating polyneuropathy: update on diagnosis, immunopathogenesis and treatment. *J Neurol Neurosurg Psychiatry* 2019;90:981–987. Published online 2019 Apr 16. <https://doi.org/10.1136/jnnp-2019-320314>.
4. Querol L, Illa I. Paranodal and other autoantibodies in chronic inflammatory neuropathies. *Curr Opin Neurol* 2015;28:474–479. <https://doi.org/10.1097/WCO.000000000000233>.

5. Querol L, Devaux J, Rojas-Garcia R, Illa I. Autoantibodies in chronic inflammatory neuropathies: diagnostic and therapeutic implications. *Nat Rev Neurol* 2017;13:533. <https://doi.org/10.1038/nrneurol.2017.84>.
6. Vural A, Doppler K, Meinl E. Autoantibodies against the node of ranvier in seropositive chronic inflammatory demyelinating polyneuropathy: diagnostic, pathogenic, and therapeutic relevance. *Front Immunol* 2018; 9:1029. Published online 2018 May 14. <https://doi.org/10.3389/fimmu.2018.01029>.
7. Uncini A, Vallat JM. Autoimmune nodo-paranodopathies of peripheral nerve: the concept is gaining ground. *J Neurol Neurosurg Psychiatry* 2017. Published online 2017 Dec 16. <https://doi.org/10.1136/jnnp-2017-317192>.
8. Ng JK, Malotka J, Kawakami N, et al. Neurofascin as a target for autoantibodies in peripheral neuropathies. *Neurology* 2012;79:2241–2248. <https://doi.org/10.1212/WNL.0b013e31827689ad>.
9. Querol L, Nogales-Gadea G, Rojas-Garcia R, et al. Neurofascin IgG4 antibodies in CIDP associate with disabling tremor and poor response to IVIg. *Neurology* 2014;82:879–886. <https://doi.org/10.1212/WNL.000000000000205>.
10. Ogata H, Yamasaki R, Hiwatashi A, et al. Characterization of IgG4 anti-neurofascin 155 antibody-positive polyneuropathy. *Ann Clin Transl Neurol* 2015; 2: 960–971. Published online 2015 Sep 11. <https://doi.org/10.1002/acn3.248>
11. Devaux JJ, Miura Y, Fukami Y, et al. Neurofascin-155 IgG4 in chronic inflammatory demyelinating polyneuropathy. *Neurology* 2016;86:800–807. <https://doi.org/10.1212/WNL.0000000000002418>.
12. Hu W, Xin Y, He Z, Zhao Y. Association of neurofascin IgG4 and atypical chronic inflammatory demyelinating polyneuropathy: A systematic review and meta-analysis. *Brain Behav* 2018; 8: e01115. Published online 2018 Sep 21. <https://doi.org/10.1002/brb3.1115>.
13. Garg N, Park SB, Yiannikas C, et al. Neurofascin-155 IgG4 Neuropathy: Pathophysiological insights, spectrum of clinical severity and response to treatment. *Muscle Nerve* 2017. Published online 2017 Nov 11. <https://doi.org/10.1002/mus.26010>
14. Burnor B, Yang L, Zhou H, et al. Neurofascin antibodies in autoimmune, genetic, and idiopathic neuropathies. *Neurology* 2018;90:e31–e38. <https://doi.org/10.1212/WNL.0000000000004773>.
15. Querol L, Rojas-García R, Diaz-Manera J, et al. Rituximab in treatment-resistant CIDP with antibodies against paranodal proteins. *Neurol Neuroimmunol Neuroinflamm* 2015; 2: e149. Published online 2015 Sep 3. <https://doi.org/10.1212/NXI.0000000000000149>.
16. Painous C, López-Pérez MA, Illa I, Querol L. Head and voice tremor improving with immunotherapy in an anti-NF155 positive CIDP patient. *Ann Clin Transl Neurol* 2018; 5: 499–501. Published online 2018 Mar 7. <https://doi.org/10.1002/acn3.539>.
17. Kerasnoudis A, Pitarokoili K, Behrendt V, et al. Cross sectional area reference values for sonography of peripheral nerves and brachial plexus. *Clin Neurophysiol* 2013;124:1881–1888. Published online 2013 Apr 10. <https://doi.org/10.1016/j.clinph.2013.03.007>.
18. Kerasnoudis A. Nerve ultrasound in a case of chronic inflammatory demyelinating neuropathy. *Muscle Nerve* 2013;47:443–446.
19. Kerasnoudis A, Pitarokoili K, Behrendt V, et al. Nerve ultrasound score in distinguishing chronic from acute inflammatory demyelinating polyneuropathy. *Clin Neurophysiol* 2014;125: 635–641. Published online 2013 Sep 23. <https://doi.org/10.1016/j.clinph.2013.08.014>
20. Fisse AL, Pitarokoili K, Trampe N, et al. Clinical Sonographic and electrophysiologic longitudinal features of chronic inflammatory demyelinating polyneuropathy. *J Neuroimaging*. 2018. Published online 2018 Nov 8. <https://doi.org/10.1111/jon.12579>.
21. Dionne A, Nicolle MW, Hahn AF. Clinical and electrophysiological parameters distinguishing acute-onset chronic inflammatory demyelinating polyneuropathy from acute inflammatory demyelinating polyneuropathy. *Muscle Nerve* 2010;41:202–207. <https://doi.org/10.1002/mus.21480>.
22. Caetano A, Ladeira F, Fernandes M, et al. Acute-onset chronic inflammatory demyelinating polyneuropathy with anti-neurofascin-155 antibodies and bilateral facial nerve enhancement. *J Neuroimmunol*. 2019;336:577026. <https://doi.org/10.1016/j.jneuroim.2019.577026>.
23. Franques J, Chapon F, Devaux J, Mathis S. Cranial nerve hypertrophy in IgG4 anti-neurofascin 155 antibody-positive polyneuropathy. *Neurology* 2017;88:e52. <https://doi.org/10.1212/WNL.0000000000003616>.
24. Chiba A, Kusunoki S, Obata H, et al. Ganglioside composition of the human cranial nerves, with special reference to pathophysiology of Miller Fisher syndrome. *Brain Res* 1997;745:32–36.
25. Bril V, Banach M, Dalakas MC, et al. Electrophysiologic correlations with clinical outcomes in CIDP. *Muscle Nerve* 2010;42:492–497. <https://doi.org/10.1002/mus.21733>.
26. Cirillo G, Todisco V, Ricciardi D, Tedeschi G. Clinical-neurophysiological correlations in chronic inflammatory demyelinating polyradiculoneuropathy patients treated with subcutaneous immunoglobulin. *Muscle Nerve* 2019;60:662–667. <https://doi.org/10.1002/mus.26669>. Epub 2019 Aug 23.
27. Fujita A, Ogata H, Yamasaki R, et al. Parallel fluctuation of anti-neurofascin 155 antibody levels with clinico-electrophysiological findings in patients with chronic inflammatory demyelinating polyradiculoneuropathy. *J Neurol Sci* 2018; 384: 107–112. Published online 2017 Nov 27. <https://doi.org/10.1016/j.jns.2017.11.035>.

28. Fisse AL, Pitarokoili K, Motte J, et al. Nerve echogenicity and intranerve CSA variability in high-resolution nerve ultrasound (HRUS) in chronic inflammatory demyelinating polyneuropathy (CIDP). *J Neurol* 2019;266:468–475. <https://doi.org/10.1007/s00415-018-9158-3>.
29. Kerasnoudis A, Pitarokoili K, Haghikia A, et al. Nerve ultrasound protocol in differentiating chronic immune-mediated neuropathies. *Muscle Nerve* 2016; 54: 864–871. Published online 2016 Sep 21. <https://doi.org/10.1002/mus.25138>.
30. Grimm A, Décard BF, Axer H, The FP. Ultrasound pattern sum score - UPSS. A new method to differentiate acute and subacute neuropathies using ultrasound of the peripheral nerves. *Clin Neurophysiol.* 2015; 126: 2216–2225. Published online 2015 Feb 3. <https://doi.org/10.1016/j.clinph.2015.01.011>.
31. Kerasnoudis A, Pitarokoili K, Gold R, Yoon MS. Nerve Ultrasound and Electrophysiology for Therapy Monitoring in Chronic Inflammatory Demyelinating Polyneuropathy. *J Neuroimaging* 2015; 25: 931–939. Published online 2015 Aug 3. <https://doi.org/10.1111/jon.12279>.
32. Pitarokoili K, Sturm D, Labedi A, et al. Neuroimaging markers of clinical progression in chronic inflammatory demyelinating polyradiculoneuropathy. *Ther Adv Neurol Disord* 2019;12: 1756286419855485. Published 2019 Jun;18. <https://doi.org/10.1177/1756286419855485>.
33. Härtig F, Ross M, Dammeier NM, et al. Nerve ultrasound predicts treatment response in chronic inflammatory demyelinating polyradiculoneuropathy—a prospective follow-up. *Neurotherapeutics.* 2018;15:439–451. <https://doi.org/10.1007/s13311-018-0609-4>.
34. Cruzat A, Qazi Y, Hamrah P. In vivo confocal microscopy of corneal nerves in health and disease. *Ocul Surf* 2017;15:15–47. <https://doi.org/10.1016/j.jtos.2016.09.004>.
35. Schneider C, Bucher F, Cursiefen C, et al. Corneal confocal microscopy detects small fiber damage in chronic inflammatory demyelinating polyneuropathy (CIDP). *J Peripher Nerv Syst* 2014;19:322–327. <https://doi.org/10.1111/jns.12098>.
36. Stettner M, Hinrichs L, Guthoff R, et al. Corneal confocal microscopy in chronic inflammatory demyelinating polyneuropathy. *Ann Clin Transl Neurol* 2016; 3:88–100. Published online 2015 Dec 28. <https://doi.org/10.1002/acn3.275>.

Supporting Information

Additional supporting information may be found online in the Supporting Information section at the end of the article.

Table S1. Selected longitudinal nerve conduction studies findings. Abbreviations: ampl.= amplitudes, dur.= duration, cMAP = compound motor action potential, DML = distal motor latency, lat.= latency, mCV = motor conduction velocity, n/a = not available, x = nonexcitable