



# The First Case Series of Malaria Overlapped with COVID-19 in Iran

Sajjad Fekri Jaski <sup>1</sup>, Mousa Khosravani <sup>2,\*</sup>, Konstantina Boutsika <sup>3,4</sup>, Shohreh Ghadarjani<sup>1</sup>, Ahmad Raeisi <sup>5</sup>, Mahmood Hosseinpoor<sup>6</sup>, Baharolsadat Hosseini <sup>7</sup> and Rouhollah Arshadinezhad<sup>8</sup>

<sup>1</sup>Infectious and Tropical Diseases Research Center, Hormozgan University of Medical Sciences, Bandar Abbas, Iran

<sup>2</sup>Department of Medical Entomology and Vector Control, School of Health, Shiraz University of Medical Sciences, Shiraz, Iran

<sup>3</sup>Swiss Tropical and Public Health Institute, Allschwil, Switzerland

<sup>4</sup>University of Basel, Basel, Switzerland

<sup>5</sup>Ministry of Health & Medical Education, Tehran, Iran

<sup>6</sup>Department of Public Health, Social Determinants in Health Promotion, Research Center, Research Institute for Health, Hormozgan University of Medical Science, Bandar Abbas, Iran

<sup>7</sup>Department of Electrical and Biomedical Engineering, Mazandaran University of Sciences and Technology, Babol, Iran

<sup>8</sup>Non-communicable Diseases Research Center, Fasa University of Medical Sciences, Fasa, Iran

\*Corresponding author: Department of Medical Entomology and Vector Control, School of Health, Shiraz University of Medical Sciences, Shiraz, Iran. Email: [mousa.khosravani2000@yahoo.com](mailto:mousa.khosravani2000@yahoo.com)

Received 2023 March 26; Revised 2023 June 11; Accepted 2023 July 15.

## Abstract

**Introduction:** Although indigenous malaria cases have dramatically declined over the past decades, the COVID pandemic has continued to affect the programs designed to combat malaria, particularly in those countries where hydroxychloroquine and chloroquine have been used as medications for treating COVID. Two immigrants entered Iran illegally from neighboring countries (i.e., Afghanistan and Pakistan). This study mainly aimed to assess the effects of coronavirus disease (COVID-19) on these cases from all aspects (i.e., case-finding, diagnosis, and treatment).

**Case Presentation:** Both cases presented with common symptoms such as fever and shaking chills. In addition, they had no sign of COVID-19, and their oxygen level and CT images were normal in some cases, but they were mistakenly treated as COVID-19 patients long after the onset of malaria symptoms. One of the suspected coronavirus cases was given chloroquine on a voluntary basis for one day, which may have been responsible for the possible relapse in vivax or resistance of plasmodium vivax to chloroquine and the recurrence of parasitemia in falciparum.

**Conclusions:** The active case detection of malaria was affected by the COVID-19 pandemic. Case finding was dramatically decreased with the onset of coronavirus, thereby causing a spurt in malaria incidence. Moreover, the malaria treatment strategy was negatively affected by the misdiagnosis of COVID-19.

**Keywords:** Imported Malaria, COVID-19, Chloroquine, Case-Finding, Misdiagnosis

## 1. Introduction

Several anti-malarial strategies were employed to fight malaria between 1957 - 1980 in Iran, and, as a result, the northern part of the country was protected against this infection, but the southern part continued to face the health challenge (1). The mosquito control program was initiated by using DDT insecticide, but it was replaced with other control methods such as mechanical/biological methods for larvae, space spraying, application of insecticide-treated nets (ITNs), indoor residual spraying (IRS), and application of repellents (2). Needless to say, the exclusive and widespread application of pesticides led to the resistance of anopheles to them (3).

The national malaria program shifted from the control phase to the elimination in 2010 (4, 5). At present, this parasitic infection is confined to Hormozgan, Kerman, Sistan and Baluchistan provinces, located in southern Iran (6). Out of these provinces, Sistan and Baluchistan was more affected by the disease, so the incidence rates in four years (i.e., between 2011 - 2014) were 89.94, 43.9, 38.3, and 30.66 per 100000 people, respectively. The highest numbers of malaria cases were reported from cities including Sarbaz, Nickshahr, and Chabahar in Sistan and Baluchistan province as well as Bandar Abbas, Bandar Jask, and Bandar Lengeh in Hormozgan province (7). Moreover, vivax malaria was most prevalent in Iranian cases, while falciparum was usually seen in migrant

workers from Pakistan and Afghanistan (8, 9). In general, no local malaria cases have been reported from Iran and Hormozgan province since 2018, and the malaria elimination program has been successfully managed (10). Currently, imported cases from neighboring countries are a problematic issue, so a quarter of all cases in the Eastern Mediterranean Region are mostly from Afghanistan and Pakistan (11). Furthermore, the coronavirus disease (COVID-19) has become a worldwide pandemic and health disaster. As of June 2023, according to World Health Organization (WHO), a total of 767,750,853 confirmed cases worldwide - including 6,941,095 deaths - were reported, and a total number of 13,381,641,358 vaccine doses were administered (12). The total of confirmed coronavirus cases in our province was 49,757, including 41,990 outpatients, 6,711 hospitalized patients, and 1,044 death. According to the unpublished data, the current population of Hormozgan is 2,036,363. Although the indigenous malaria cases have declined dramatically for 20 years (i.e., between 2000 to 2020), the COVID pandemic has continued to affect the programs designed to combat malaria, particularly in those countries where hydroxychloroquine and chloroquine have been used as medications for treating COVID. The effectiveness of these compounds against Coronavirus has not been confirmed (13, 14). This study aimed to report two malaria cases misdiagnosed as COVID-19 patients in Hormozgan province and to assess the effects of COVID-19 on these cases from all aspects (i.e., case-finding, diagnosis, and treatment).

## 2. Case Presentation

### 2.1. First Case

A 24 years old man from Badakhshan province in northeastern Afghanistan, near the border with Tajikistan, left his province on February 20, 2021, and arrived in Nimruz province, southwestern Afghanistan, after ten days. Nimruz province borders Iran and Pakistan; therefore, he spent two days crossing Pakistan and entering Iran illegally through Sistan and Baluchestan province. On his path to his final destination, he had to pass the desert and unknown areas. He crossed Kerman and Isfahan provinces into the capital city of Tehran and then found a job in a technical engineering office and worked there for five months and ten days. On August 1, 2021, he felt sick with a high fever and shaking chills and, therefore, was referred to a hospital. He underwent a COVID-19 test with a swab by an on-call physician, but the result was negative. It is noteworthy that he took

chloroquine on a voluntary basis only for one day before receiving the result. The next day, on August 3, 2021, he was referred to the general practitioner of the same hospital again. Prescription drugs included: Pantoprazole 40 mg (ampoule), apotel 1 gr (ampoule), sodium chloride 0.9% 500 mL, codimal-extra (tablet), captopril 25 mg (tablet), bromhexine (syrup), and mocozipt (syrup). The patient also received injections of neurobion and vitamin B complex. On August 8, he complained about the symptoms persisting for 28 days, the ineffectiveness of the prescribed drugs, and the worsening of his condition. The patient continued to suffer from the symptoms for a month. Afterward, he moved to the tourist island of Kish through the Bandar Abbas-Charak route on September 1 for labor and settled in a building with suitable amenities such as electricity and an air conditioner. However, he was unable to work for about 10 days. On September 3, he suffered from a fever reoccurring every other day, body aches, and severe pain. To relieve his pain, the on-call physician of Kish Hospital prescribed some drugs, including multivitamins (capsule), prednisolone (amp), and ketorolac 30 mg (amp). On September 7, he was referred to the Health and Control Disease Center in Kish and underwent several tests except for a malaria test. His biochemistry lab findings were normal (e.g., fasting blood sugar (FBS), blood urea nitrogen (BUN), creatinine (Cr), Cholesterol (including total chol.-LDL and HDL), and triglyceride (TG)). Also, liver function test (LFT) included AST-ALT, and alkaline phosphatase was normal with no change. On the contrary, C-reactive protein (CRP), an acute phase reactant factor, was positive (1+). Erythrocyte sedimentary rate (ESR), which rises in inflammatory and febrile situations, was equal to 125. Complete blood count (CBC) test showed a decreased counting of red blood cell (RBC) with a Hb level equal to 7.6 and a hematocrit percentage equal to 24%. Furthermore, a decreased platelet count (i.e., thrombocytopenia) was seen since his platelet count range was 107 mL. It should be noted that the normal range of platelet count is between 150 to 450 mL. Therefore, the patient was treated symptomatically, and on September 16, he was recommended to undergo a COVID-19 test. Finally, he was referred to a private physician and was recommended to have a blood test at Kish Hospital. Erythrocyte sedimentary rate was raised to 95. Complete blood count-differential (CBC-diff) demonstrated a decreased RBC count and hematocrit (HCT) percentage with severe anemia (hemoglobin amount 8.6 g/dL), but the differential count of lymphocyte, neutrophil, etc. was normal. Kish Medical Laboratory informed the Health Center about the positive vivax malaria of our case on September 21 at 8 pm. All blood-stage of the vivax

parasites (i.e., gametocyte, schizont, trophozoites) were seen in the blood smear during microscopic examination. Our approved malaria case was a reminder of the sad fact that how someone may waste a lot of money (forty million Iranian Rials or ~ US\$150, in this case) on medical treatment, although s/he could be treated almost for free.

## 2.2. Second Case

A 46 years old man set off on foot with his family and a relative from Quetta, a city in Pakistan bordering Iran, on September 10, 2020, and arrived in Mirjaveh, Iran, on September 12. Then this Pakistani man moved to Zahedan on September 13 and then to Bandar Abbas (the capital of Hormozgan province) on September 14, 2020. He stayed in a village near Bandar Lengeh named Divan and worked there as a fish seller, but his relative resided in Kong city, 40 km distance from Divan village. Both of them accessed their favorite amenities in the rented houses, such as electricity and cooling equipment. In our considered case, the 46 years old man complained of a fever with unknown origin (FUO), left flank pain, dysuria, myalgia, and a non-productive cough on September 17 and, therefore, was admitted to rule out the Urosepsis and COVID-19 diagnoses. O<sub>2</sub> (O<sub>2</sub> saturation) was 96%. A physical examination of his lungs was carried out, according to which the auscultation was clear, with no abnormal breath sounds. Potassium (K) was 3.3 mEq, Plt 760 mL in biochemistry and mean corpuscular volume (MCV) in hematology of 79.7 fl. Protein was positive in urine. Serum glutamic-oxaloacetic transaminase (SGOT) and serum glutamic pyruvic transaminase (SGPT) enzymes were 65 U/L and 104 U/L, respectively. Chest CT scan showed no evidence of patchy ground-glass opacity (G.G.O) in lung parenchyma, which may have been due to the early stage of COVID-19. Lung parenchyma, trachea, and bronchus were intact. Pulmonary hilar structures, trachea, and esophagus were all normal. His pericardium had normal thickness without evidence of thickening, calcification, or effusion. No pleural effusion was seen. His chest wall, including ribs, was normal, with no evidence of bone destruction. The findings from the CT scan of his abdomen and pelvic were normal. The initial treatment included sodium chloride 0.9%/2 liters/IV infusion during 24 hours, ampule ciprofloxacin 400 mg/IV per 12 h (intravenous), ampule apotel 1 gr/IV when the temperature was above 38.5 degrees, and pantoprazole 40 mg/PO (tablet) on a daily basis. The following drugs were then added to our patient treatment after a consultation with a cardiologist: Ampule enoxaparin 60 mg/SC/BID and atorvastatin 20 mg/daily (tablet). On September 18, a PCR test was taken from him, and the suspected COVID-19 result was negative. Moreover,

CRP was high in his blood (equaled 44 mg/L). The internist prescribed these medicines: Syrup bromhexin/10 cc/ q 8 h, nebulizer pulmicort/BID, and nebulizer duolin/TDS. According to the progress note, his symptoms were persistent to a great extent, and his blood pressure was within the normal range. The patient was first feverless but then developed fever and nausea. O<sub>2</sub> saturation was normal during this period without supplemental oxygen therapy. On September 19, favipiravir 200 mg (antiviral treatment). Furthermore, the patient was initially given an analgesic (naproxen) based on the clinical and laboratory findings suggesting the presence of COVID-19, but he was discharged on September 21 and recommended to visit an internist later. On October 31, 2020, the patient contracted fever and chills and was, therefore, referred to the health office of Divan village. The next day, he was correctly diagnosed with a vivax malaria case performing malaria rapid diagnostic test (RDTs). He was treated with chloroquine and primaquine based on the national treatment protocol. At the time of the detection, his average temperature was 27°C with humidity of 75%, but no mosquitoes were found or captured in the vicinity of his place. The patient had traveled to Pakistan frequently and illegally.

## 3. Discussion

Both cases presented with common symptoms such as fever and shaking chills. In addition, CRP markers may have diverted the doctors' attention to the presence of an infection like that of malaria. The oxygen level and CT image of the second case were normal, and no alternative diagnosis was reached based on his CT scan findings. However, he was treated as a COVID-19 patient based on the clinical manifestations, although some common clinical symptoms (e.g., fatigue, expectoration, and chest tightness) were not observed in him (Figure 1). Some asymptomatic COVID-19 cases have normal chest CT, which makes it difficult to treat a suspected case as a confirmed COVID patient (15). Some medical staff argue that they should start treatment even if there are no signs of COVID. On the contrary, our patients were from the malarious area where malaria was locally transmitted, but the physicians failed to consider the epidemiological criterion of malaria in these endemic sites. A great number of immigrants entered Iran illegally from the neighboring countries, but Iran's health care system is mostly unable to trace them because they usually adopt different methods to conceal their identity. A peak of COVID, with a total of 10,789 confirmed coronavirus cases, was recorded in Lengeh around August and March 2020. Furthermore, the

COVID-19 pandemic put great strain and stress on clinical staff and caused reducing the number of personnel due to the risk of infection or mortality, which shifted their focus onto, especially outpatients and suspected cases. However, a delayed diagnosis or treatment was not the case with the health care providers working at health offices in smaller areas or villages since they had lower workloads. This may have explained the reason why our second patient was quickly diagnosed with malaria in a village. Our cases - particularly the second case staying with his family members - had been in close contact with people since their arrival in Kish Island and Bandar Lengeh city until the diagnosis time. Although no indigenous malaria cases had been reported from Kish since 2007, and all foci were clear, some vector activities were observed. It is noteworthy that Kish Island is a tourist destination and an important economic zone in southern Iran with a lot of annual visitors. Recorded malaria cases had been imported from adjoining countries into this district. The population is extremely fluid. Traders or unskilled workers move there and often leave to find a job. Bandar Lengeh is a district with a high potential for malaria transmission. The last indigenous case was recorded in 2008 from Bandar Lengeh. The introduced cases were announced in 2017, then imported cases from Afghanistan and Pakistan took over up to now in Lengeh. Two cases were detected passively. The first patient was referred to a hospital, and the second one was referred to a health office in a village. The COVID-19 pandemic affected the active case detection of malaria among high-risk groups performed by health care that were involved in the case finding routinely. Moreover, these personnel participated in the COVID-19 sampling process because of a shortage of staff. Misdiagnosis of our cases placed enormous financial burdens on them due to the hospitalization and undergoing several tests, while anti-malarial drugs were free of charge, and they could have been easily treated almost for free. They had no sustainable sources of income, and their medical care was not covered by health insurance. In addition, the possible side effects of the coronavirus drugs may have posed serious and long-term risks to these patients who had left their countries in the hope of a better life. Another part of misdiagnosis was that they were desperately wandering from home to clinics and vice versa. The first case took CQ for only a day by his own decision. CQ should be taken with primaquine for *Plasmodium vivax*. If he continued with CQ monotherapy, it would cause relapse or resistance as uncomplicated treatment (16, 17). In Iran, CQ is prescribed for those who are exposed to coronavirus, particularly for outpatients or those in the early stages of infection. Therefore,

misdiagnosis in suspected COVID cases may happen. A suspected coronavirus patient receives CQ, while a malaria patient needs CQ and primaquine in combination with its own special does (18). If the case is falciparum malaria, the situation is likely to worsen because falciparum is more resistant to CQ and provides a recurrence of parasitemia (19). Consequently, COVID-19 delays malaria prevention measures and increases the exposure of health providers to coronaviruses, and minimizes the early seeking of medical assistance (20). Moreover, it can certainly impede malaria management, thereby increasing the rate of malaria incidence (21). World Health Organization global malaria programme is aimed at mitigating the negative impact of the coronavirus in malaria-affected countries during the time of the evolving COVID-19 pandemic (22). Fortunately, no local case was observed. However, a new cycle of malaria transmission may begin and continue to an uncontrollable phase so, which spoils the valuable achievement and changes the pattern of malaria elimination programs.

#### Footnotes

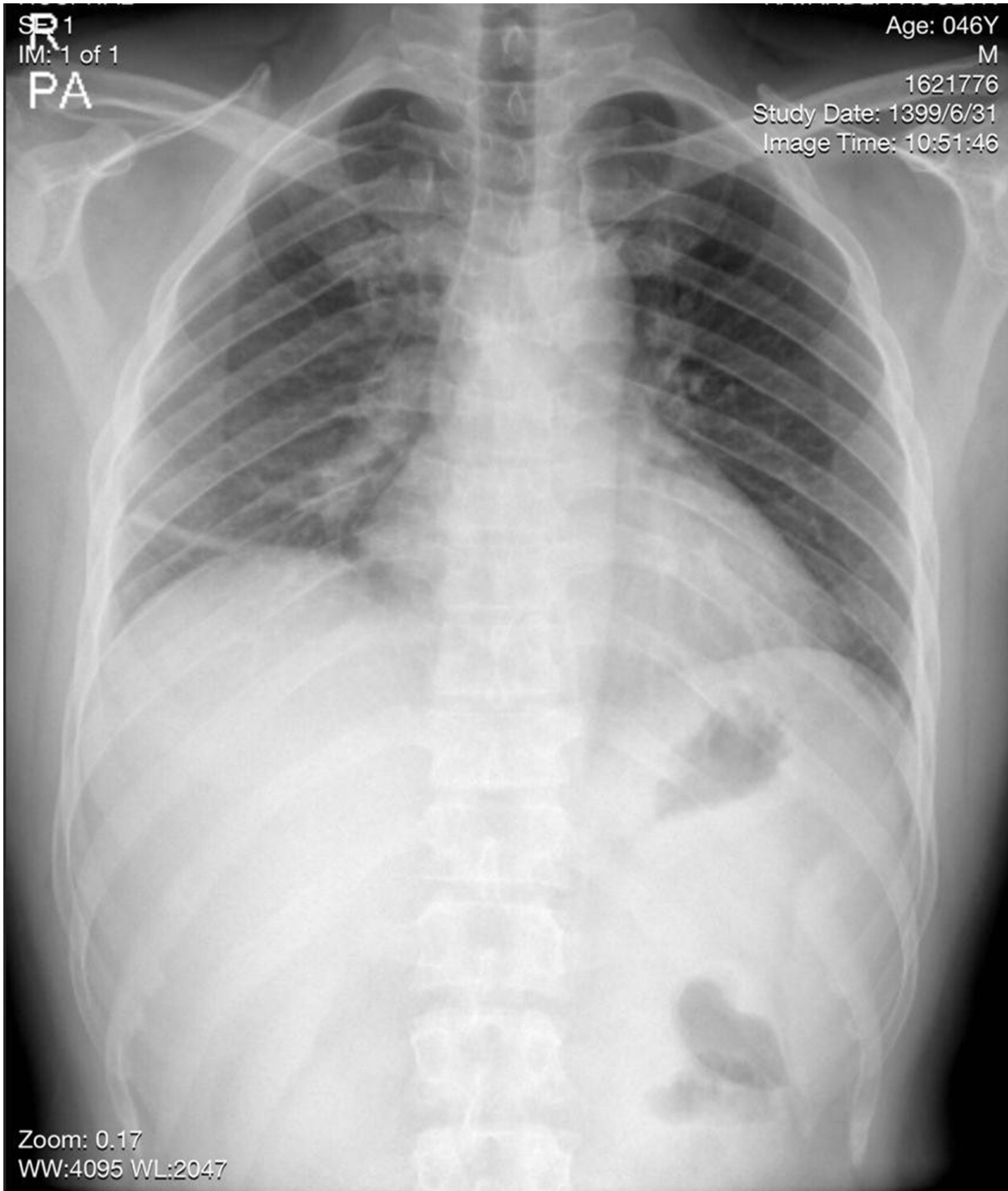
**Authors' Contribution:** The study was designed under the supervision of Sajjad Fekri Jaski. The first and final drafts of the manuscript were written by Mousa Khosravani and Konstantina Boutsika. Patient interviews and interpretation of ST scans and prescriptions were conducted by Shohreh Ghadarjani, Ahmad Raeisi, and Mahmood Hosseinpoor. Data collection from hospitals and health centers was carried out by Baharolsadat Hosseini and Rouhollah Arshadinezhad. All authors read and approved the final manuscript.

**Conflict of Interests:** The authors declare that they have no conflict of interest.

**Data Reproducibility:** The dataset presented in the study is available on request from the corresponding author during submission or after publication. The data are not publicly available due to ethics.

**Funding/Support:** No funds, grants, and other support were received.

**Informed Consent:** The consent document was obtained from the patients at the time of the study. In the beginning, the purpose of the study was elucidated to them in detail. It was also emphasized that this research does not interfere with the treatment process. They welcomed the publication of the results while maintaining their personal data confidential.



**Figure 1.** A spiral chest CT scan of the second case demonstrated no abnormalities in his lungs, such as diffuse, patchy areas of consolidation or strip like opacities



## References

- Edrissian GH. Malaria in Iran: Past and Present Situation. *Iranian J Parasitol.* 2006;**1**(1):1-14.
- Vatandoost H, Mamivandpoor H, Shayeghi M, Abai MR, Yaghoobi-Ershadi MR, Raeisi A, et al. Evaluation of bioefficacy of  $\alpha$ -cypermethrin in long lasting impregnated net (Interceptor®) using analytical method. *Asian Pac J Trop Med.* 2010;**3**(8):642-6. [https://doi.org/10.1016/s1995-7645\(10\)60155-1](https://doi.org/10.1016/s1995-7645(10)60155-1).
- Enayati A, Hanafi-Bojd AA, Sedaghat MM, Zaim M, Hemingway J. Evolution of insecticide resistance and its mechanisms in *Anopheles stephensi* in the WHO Eastern Mediterranean Region. *Malar J.* 2020;**19**(1):258. [PubMed ID: 32680514]. [PubMed Central ID: PMC7367398]. <https://doi.org/10.1186/s12936-020-03335-0>.
- Azizi K, Moemenbellah-Fard MD, Khosravani-Shiri M, Fakoorziba MR, Soltani A. Lethal and Residual Effects of Lambda-cyhalothrin, Deltamethrin and Cyfluthrin Insecticides on Adult Mosquitoes of *Anopheles stephensi* Liston (Diptera: Culicidae) on Different Surfaces. *J Health Sci Surveillance Sys.* 2014;**2**(1):30-5.
- Khosravani M, Rafatpanah A, Amiri SA, Zare A. The Field Practices of Lambda-cyhalothrin and Deltamethrin Insecticides Against Adult Mosquitoes of *Anopheles stephensi* as the Main Vector of Malaria: Residual Effects. *Zahedan J Res Med Sci.* 2017;**19**(4):e7629. <https://doi.org/10.5812/zjrms.7629>.
- Kalantari M, Soltani Z, Ebrahimi M, Yousefi M, Amin M, Shafiei A, et al. Monitoring of Plasmodium infection in humans and potential vectors of malaria in a newly emerged focus in southern Iran. *Pathog Glob Health.* 2017;**111**(1):49-55. [PubMed ID: 28078947]. [PubMed Central ID: PMC5375612]. <https://doi.org/10.1080/20477724.2016.1271094>.
- Norouznejad F, Ghaffari F, Raeisi A, Norouznejad A. Epidemiological status of malaria in Iran, 2011-2014. *Asian Pac J Trop Med.* 2016;**9**(11):1055-61. [PubMed ID: 27890364]. <https://doi.org/10.1016/j.apjtm.2016.09.007>.
- Mohebbi Nodez SM, Khosravani M, Rafatpanah A, Jafarpour S, Jaberhashemi SA. Imported malaria and epidemiologic components of this infection in Qeshm Island, Iran. *Int J Mosq Res.* 2018;**5**(1):143-9.
- Vatandoost H, Raeisi A, Saghafipour A, Nikpour F, Nejati J. Malaria situation in Iran: 2002-2017. *Malar J.* 2019;**18**(1):200. [PubMed ID: 31208453]. [PubMed Central ID: PMC6580592]. <https://doi.org/10.1186/s12936-019-2836-5>.
- MaxSchapira A, Zaim M, Raeisi A, Ranjbar M, Kolifarhood G, Nikpour F, et al. *History of the successful Struggle against malaria in the Islamic Republic of Iran.* 2018. Available from: [https://endmalaria.org/sites/default/files/Iran%20Story%20new%2026\\_Sep\\_2018\\_GF.pdf](https://endmalaria.org/sites/default/files/Iran%20Story%20new%2026_Sep_2018_GF.pdf).
- World Health Organization. *World malaria report 2020: 20 years of global progress & challenges.* 2020. Available from: <https://www.who.int/publications/i/item/9789240015791>.
- World Health Organization. *WHO Coronavirus (COVID-19) Dashboard.* 2023. Available from: <https://covid19.who.int/?mapFilter=deaths>.
- Khuroo MS. Chloroquine and hydroxychloroquine in coronavirus disease 2019 (COVID-19). Facts, fiction and the hype: a critical appraisal. *Int J Antimicrob Agents.* 2020;**56**(3):106101. [PubMed ID: 32687949]. [PubMed Central ID: PMC7366996]. <https://doi.org/10.1016/j.ijantimicag.2020.106101>.
- Hong TS, Gonzalez J, Nahass RG, Brunetti L. Impact of Hydroxychloroquine on Mortality in Hospitalized Patients with COVID-19: Systematic Review and Meta-Analysis. *Pharmacy (Basel).* 2020;**8**(4):208. [PubMed ID: 33167571]. [PubMed Central ID: PMC7711623]. <https://doi.org/10.3390/pharmacy8040208>.
- Kwee TC, Kwee RM. Chest CT in COVID-19: What the Radiologist Needs to Know. *Radiographics.* 2020;**40**(7):1848-65. [PubMed ID: 33095680]. [PubMed Central ID: PMC7587296]. <https://doi.org/10.1148/rjg.2020200159>.
- Ratcliff A, Siswanto H, Kenangalem E, Wuwung M, Brockman A, Edstein MD, et al. Therapeutic response of multidrug-resistant Plasmodium falciparum and P. vivax to chloroquine and sulfadoxine-pyrimethamine in southern Papua, Indonesia. *Trans R Soc Trop Med Hyg.* 2007;**101**(4):351-9. [PubMed ID: 17028048]. [PubMed Central ID: PMC2080856]. <https://doi.org/10.1016/j.trstmh.2006.06.008>.
- Baird JK. Chloroquine resistance in Plasmodium vivax. *Antimicrob Agents Chemother.* 2004;**48**(11):4075-83. [PubMed ID: 15504824]. [PubMed Central ID: PMC525399]. <https://doi.org/10.1128/AAC.48.11.4075-4083.2004>.
- Ladeia-Andrade S, Menezes MJ, de Sousa TN, Silvino ACR, de Carvalho Jr JF, Salla LC, et al. Monitoring the Efficacy of Chloroquine-Primaquine Therapy for Uncomplicated Plasmodium vivax Malaria in the Main Transmission Hot Spot of Brazil. *Antimicrob Agents Chemother.* 2019;**63**(5):e01965-18. [PubMed ID: 30782991]. [PubMed Central ID: PMC6496112]. <https://doi.org/10.1128/AAC.01965-18>.
- Sumawinata IW, Leksana B, Sutamihardja A, Subianto B, Bernadeta; Purnomo, et al. Very high risk of therapeutic failure with chloroquine for uncomplicated Plasmodium falciparum and P. vivax malaria in Indonesian Papua. *Am J Trop Med Hyg.* 2003;**68**(4):416-20. [PubMed ID: 12875290].
- Hakizimana D, Ntizimira C, Mbituyumuremyi A, Hakizimana E, Mahmoud H, Birindabagabo P, et al. The impact of Covid-19 on malaria services in three high endemic districts in Rwanda: a mixed-method study. *Malar J.* 2022;**21**(1):48. [PubMed ID: 35164781]. [PubMed Central ID: PMC8845295]. <https://doi.org/10.1186/s12936-022-04071-3>.
- Gavi S, Tapera O, Mberikunashe J, Kanyangara M. Malaria incidence and mortality in Zimbabwe during the COVID-19 pandemic: analysis of routine surveillance data. *Malar J.* 2021;**20**(1):233. [PubMed ID: 34030711]. [PubMed Central ID: PMC8142064]. <https://doi.org/10.1186/s12936-021-03770-7>.
- World Health Organization. *Tailoring malaria interventions in the COVID-19 response.* 2020. Available from: <https://www.who.int/publications/m/item/tailoring-malaria-interventions-in-the-covid-19-response>.