

SHORT COMMUNICATION

Paraneoplastic Epidermolysis Bullosa Acquisita Associated with Thyroid Carcinoma

Giuseppe Alfonso Lombardo¹, Maria Antonietta Pilla¹, Roberto Benucci¹, Alessandro Monopoli¹, Gianandrea Baliva¹, Tommaso Gobello², Giovanni Di Zenzo³, Giovanna Zambruno³ and Liliana Guerra^{3*}

¹3rd Dermatology Division, ²1st Dermatology Division and ³Laboratory of Molecular and Cell Biology, Istituto Dermatologico dell'Immacolata (IDI)-IRCCS, via dei Monti di Creta 104, IT-00167 Rome, Italy. *E-mail: l.guerra@idi.it

Accepted Aug 19, 2015; Epub ahead of print Aug 25, 2015

Epidermolysis bullosa acquisita (EBA) is a rare acquired subepithelial blistering disease of the skin and mucous membranes associated with autoantibodies against type VII collagen (1, 2). Two main clinical variants are recognized: a classic mechanobullous and an inflammatory type (1, 2). Inflammatory EBA mimics other autoimmune bullous diseases and has at least 4 different clinical presentations: bullous pemphigoid (BP)-like EBA, mucous membrane pemphigoid (MMP)-like EBA, Brunsting-Perry pemphigoid-like EBA and linear IgA bullous dermatosis-like EBA (1, 2). Clinical features, histopathological or immunofluorescence studies are necessary to identify EBA, but they are not sufficient to confirm the diagnosis (1, 2). For a long time direct immunoelectron microscopy has represented the gold standard for EBA diagnosis (2). However, nowadays other methods such as u-serrated pattern analysis by direct immunofluorescence (DIF) microscopy (3), together with detection of circulating autoantibodies to type VII collagen by enzyme-linked immunosorbent assay (ELISA) or immunoblotting (IB) (4), are most frequently used due to their easier availability and feasibility. EBA has frequently been found in association with systemic diseases, in particular inflammatory bowel disease and systemic lupus erythematosus, but also rheumatoid arthritis, amyloidosis, diabetes mellitus, thyroiditis and other endocrinopathies (1, 2). Association with haematological diseases and solid tumours has also been described (5–14).

We report here a case of BP-like inflammatory EBA in which search for an associated disease, prompted by treatment resistance, disclosed an underlying thyroid papillary carcinoma.

CASE REPORT

A 52-year-old man presented with a 3-month history of a pruritic bullous skin eruption. The patient was in good general health, and was not on any medication. Physical examination revealed numerous urticarial papules and plaques, together with tense serous and sero-haemorrhagic vesicles and blisters, erosions and crusts on erythematous and normal skin (Fig. 1 a, b, Fig. S1 a, c¹). The lesions were distributed over the entire body surface, especially the hands, feet, wrists, ankles, shoulders, buttocks and thighs. Slight hyperpigmentation and rare milia were present at sites of healed lesions. Bullous lesions were observed on the sides of the tongue. Nails and hair were not involved. Results of laboratory examinations, including complete blood count, blood

chemistry and urine analysis were within normal limits. Histopathological examination of a bullous lesion of the right thigh revealed a subepidermal blister with a dense infiltrate dominated by neutrophils in the papillary dermis (Fig. 1c). DIF examination of perilesional skin showed a linear deposition of IgG and C3 along the dermal–epidermal junction, with IgG showing a u-serrated pattern (Fig. 1d). Indirect immunofluorescence (IIF) on salt-split skin demonstrated binding of IgG to the dermal side of the split skin (1:160 titre) (Fig. 1e). IB analysis, performed using collagen VII ammonium sulphate precipitated from the medium of WISH epithelioid cell line, revealed the presence of IgG autoantibodies recognizing a band of 290 kDa in patient's serum (Fig. 1f). ELISA for BP180 (MBL, Naka-ku, Nagoya, Japan) was negative, while ELISA based on collagen VII immunodominant domains (MBL) was positive (29 U/ml, n.v. < 6.14).

A diagnosis of BP-like inflammatory EBA was made and treatment with prednisone (1 mg/kg) and dapsone (1.3 mg/kg) started, with only minimal clinical improvement. Two months later, the patient developed a toxic tubular nephropathy. Dapsone was interrupted and renal function parameters returned within normal limits in 3 months. In view of the resistance of EBA to therapy, a series of additional instrumental examinations was then performed. Thorax X-ray, total body computed tomography scan and abdominal-pelvic sonography did not show any abnormality. Thyroid sonography showed the presence of a inhomogeneous hypoechoic solid nodule of 3.4 × 2.5 cm and findings of fine-needle aspiration cytology were compatible with a papillary carcinoma. Serum TSH was 0.2 µIU/ml (normal range 0.35–4.0 µIU/ml), FT3 and FT4 levels were within normal limits. The patient underwent radical thyroid resection followed by radioiodine ablation therapy. Histopathological examination confirmed the diagnosis of papillary carcinoma, follicular encapsulated variant, with oxyphilic cells.

Immediately after thyroidectomy, a remarkable improvement in the skin and mucous membrane disease was noticed, with a marked decrease in new lesion formation, allowing rapid tapering of the steroid therapy. Three months later the patient was free of skin lesions while being treated with prednisone 5 mg every other day (Fig. S1 c–e¹). Steroid therapy was discontinued approximately 10 months later. At a 4-year follow-up the patient remains free of disease, in the absence of signs of cancer.

DISCUSSION

EBA is frequently refractory to the usual treatment modalities for autoimmune blistering diseases (2). Steroids, in combination with other immunosuppressive/modulatory agents, are considered the first-line treatment (1, 2). Methotrexate, azathioprine, cyclosporine, colchicine, dapsone, intravenous immunoglobulins, alone or in combination, are also used (1, 2). The anti-CD20 antibody rituximab has been successfully employed as adjuvant therapy (1, 2).

Our case was at first refractory to therapy with high-dose steroids and dapsone. The resolution of EBA after

¹<http://www.medicaljournals.se/acta/content/?doi=10.2340/00015555-2219>

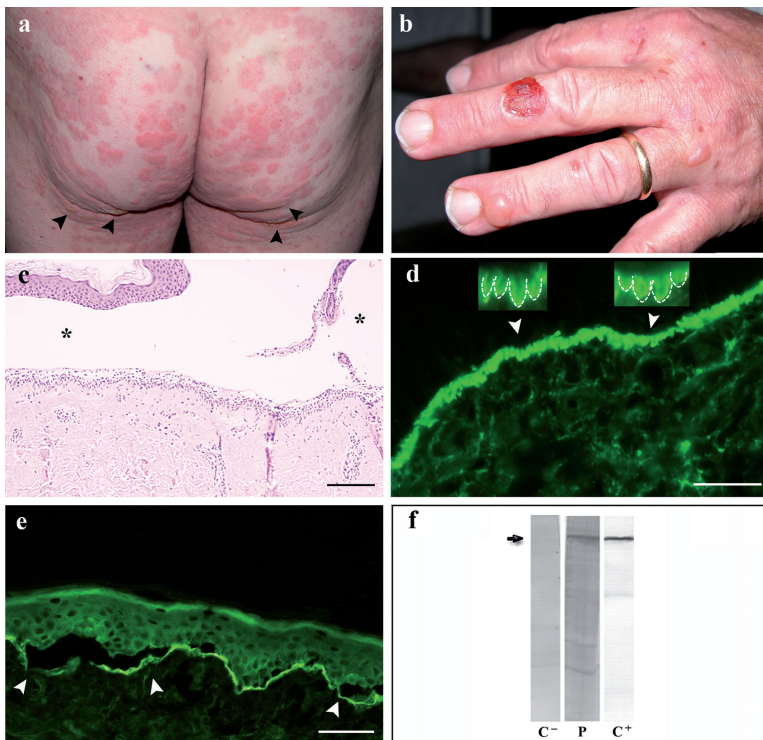


Fig. 1. (a) Urticaria-like erythematous plaques of the buttocks, and flaccid blisters in the infragluteal folds (arrowheads). (b) Tense serous blisters and erosions on the dorsal aspect of the right hand and fingers. (c) Subepidermal blister (*) (haematoxylin-eosin staining). (d) Direct immunofluorescence: immunoglobulin G (IgG) linear deposition along the cutaneous basement membrane zone showing a u-serrated pattern (arrowheads), which is magnified in the insets (dotted lines). (e) Indirect immunofluorescence on human salt-split skin: IgG linear staining along the floor of the split (arrowheads). (f) Immunoblotting analysis showing a 290 kDa band (arrow) recognized by patient serum on a collagen VII enriched protein extract from WISH cells. C⁻: normal human serum and P: patient serum (1:100 dilution). C⁺: anti-collagen VII monoclonal antibody (LH7.2, 1:10 dilution). Scale bars: (c) 100 µm, (d) 25 µm and (e) 50 µm.

tumour removal fits the concept that EBA was triggered and sustained by malignancy via cross-reactivity against epitopes shared by tumour cell proteins and dermal type VII collagen (13). Of note, *de novo* expression of collagen VII has been reported in thyroid carcinomas (15).

Several patients with EBA presenting with myeloma and lymphoproliferative diseases have been described (Table S1¹) (5, 9–11), and a significant association between EBA and haematological malignancies has been found (14). Single cases of benign Schwannoma, lung, breast and cervical carcinoma and EBA have also been reported (Table S1¹) (6–8, 12, 13). However, an EBA course strictly related to the neoplasm has been observed in very few patients (Table S1¹) (5, 7, 8). Our EBA case satisfies the criteria for a paraneoplastic skin disease, i.e. the dermatosis was associated with the presence of a malignancy and most likely developed after the malignancy, was resistant to correctly performed therapies, and rapidly disappeared after the complete removal of the cancer.

ACKNOWLEDGEMENTS

The authors acknowledge support from the Italian Ministry of Health (Ricerca Corrente 2013–2015 to GDZ). The authors would like to thank Naomi De Luca for immunofluorescence analyses.

REFERENCES

- Kim JH, Kim SC. Epidermolysis bullosa acquisita. *J Eur Acad Dermatol Venereol* 2013; 27: 1204–1213.
- Ludwig RJ. Clinical presentation, pathogenesis, diagnosis, and treatment of epidermolysis bullosa acquisita. *ISRN Dermatol* 2013; 2013: 812029.
- Vodegel RM, Jonkman MF, Pas HH, de Jong MC. U-serrated immunodeposition pattern differentiates type VII collagen targeting bullous diseases from other subepidermal bullous autoimmune diseases. *Br J Dermatol* 2004; 151: 112–118.
- Calabresi V, Sinistro A, Cozzani E, Cerasaro C, Lolicato F, Muscianese M, et al. Sensitivity of different assays for the serological diagnosis of epidermolysis bullosa acquisita: analysis of a cohort of 24 Italian patients. *J Eur Acad Dermatol Venereol* 2014; 28: 483–490.
- Baler GR. Epidermolysis bullosa acquisita associated with lymphoma. *J Am Acad Dermatol* 1987; 17: 856–859.
- Klein JS, Goldin HM, Keegan C, Shiomoto G, Israel SR, Bronson DM. Clear-cell carcinoma of the lung in a patient treated with cyclosporine for epidermolysis bullosa acquisita. *J Am Acad Dermatol* 1991; 24: 297.
- Modiano P, Prost C, Barbaud A, Vignaud JM, Grignon Y, Schmutz JL, et al. Epidermolysis bullosa acquisita and benign schwannoma. *J Am Acad Dermatol* 1996; 35: 472–473.
- Etienne A, Ruffieux P, Didierjean L, Saurat JH. Epidermolysis bullosa acquisita and metastatic cancer of the uterine cervix. *Ann Dermatol Venereol* 1998; 125: 321–323.
- Aractingi S, Bachmeyer C, Prost C, Caux F, Flageul B, Fermand JP. Subepidermal autoimmune bullous skin diseases associated with B-cell lymphoproliferative disorders. *Medicine (Baltimore)* 1999; 78: 228–235.
- Engineer L, Dow EC, Braverman IM, Ahmed AR. Epidermolysis bullosa acquisita and multiple myeloma. *J Am Acad Dermatol* 2002; 47: 943–946.
- Radfar L, Fatahzadeh M, Shahamat Y, Sirois D. Paraneoplastic epidermolysis bullosa acquisita associated with multiple myeloma. *Spec Care Dentist* 2006; 26: 159–163.
- Busch JO, Sticherling M. Epidermolysis bullosa acquisita and neuroendocrine pancreatic cancer – coincidence or pathogenetic relationship? *J Dtsch Dermatol Ges* 2007; 5: 916–918.
- Iranzo P, Herrero-González JE, Mascaró-Galy JM, Suárez-Fernández R, España A. Epidermolysis bullosa acquisita: a retrospective analysis of 12 patients evaluated in four tertiary hospitals in Spain. *Br J Dermatol* 2014; 171: 1022–1030.
- Schulze F, Neumann K, Recke A, Zillikens D, Linder R, Schmidt E. Malignancies in pemphigus and pemphigoid diseases. *J Invest Dermatol* 2015; 135: 1445–1447.
- Lohi J, Leivo I, Owaribe K, Burgesson RE, Franssila K, Virtanen I. Neoeexpression of the epithelial adhesion complex antigens in thyroid tumours is associated with proliferation and squamous differentiation markers. *J Pathol* 1998; 184: 191–196.