

4-1-2014

Combination Therapy of Hyaluronic Acid Mesotherapeutic Injections and Sclerotherapy for Treatment of Lower Leg Telangiectasia Without Major Venous Insufficiency: A Preliminary Clinical Study

Tommaso Iannitti

University of Kentucky, tia222@uky.edu

Valentina Rottigni

Poliambulatorio del Secondo Parere, Italy

Federica Torricelli


University of Modena and Reggio Emilia, Italy

Beniamino Palmieri

Poliambulatorio del Secondo Parere, Italy

Right click to open a feedback form in a new tab to let us know how this document benefits you.

Follow this and additional works at: https://uknowledge.uky.edu/physiology_facpub

 Part of the [Physiology Commons](#), and the [Rehabilitation and Therapy Commons](#)

Repository Citation

Iannitti, Tommaso; Rottigni, Valentina; Torricelli, Federica; and Palmieri, Beniamino, "Combination Therapy of Hyaluronic Acid Mesotherapeutic Injections and Sclerotherapy for Treatment of Lower Leg Telangiectasia Without Major Venous Insufficiency: A Preliminary Clinical Study" (2014). *Physiology Faculty Publications*. 126.

https://uknowledge.uky.edu/physiology_facpub/126

This Article is brought to you for free and open access by the Physiology at UKnowledge. It has been accepted for inclusion in Physiology Faculty Publications by an authorized administrator of UKnowledge. For more information, please contact UKnowledge@lsv.uky.edu.

Combination Therapy of Hyaluronic Acid Mesotherapeutic Injections and Sclerotherapy for Treatment of Lower Leg Telangiectasia Without Major Venous Insufficiency: A Preliminary Clinical Study

Notes/Citation Information

Published in *Clinical and Applied Thrombosis/Hemostasis*, v. 20, issue 3, p. 326-330.

© The Author(s) 2012

This article is distributed under the terms of the Creative Commons Attribution-NonCommercial 3.0 License (<http://www.creativecommons.org/licenses/by-nc/3.0/>) which permits non-commercial use, reproduction and distribution of the work without further permission provided the original work is attributed as specified on the SAGE and Open Access page(<http://www.uk.sagepub.com/aboutus/openaccess.htm>).

Digital Object Identifier (DOI)

<https://doi.org/10.1177/1076029612461844>

Combination Therapy of Hyaluronic Acid Mesotherapeutic Injections and Sclerotherapy for Treatment of Lower Leg Telangiectasia Without Major Venous Insufficiency: A Preliminary Clinical Study

Tommaso Iannitti, PhD^{1,2}, Valentina Rottigni, MSc^{2,3},
Federica Torricelli, MSc³, and Beniamino Palmieri, MD, PhD^{2,3}

Clinical and Applied
Thrombosis/Hemostasis
2014, Vol. 20(3) 326-330
© The Author(s) 2012
Reprints and permission:
sagepub.com/journalsPermissions.nav
DOI: 10.1177/1076029612461844
cat.sagepub.com



Abstract

Background. Telangiectasia is the dilation of dermal capillaries mainly due to hypertension and vein insufficiency. Treatments of choice for this condition are sclerotherapy with foam liquid or intradermal fiber optic laser energy delivery. **Aim.** The aim of this study was to assess the efficacy of a new therapeutic approach consisting in the use of polymerized hyaluronic acid mesotherapeutic injections following sclerotherapy in the areas of the skin affected by telangiectasia in patients without major vein insufficiency. **Materials and Methods.** A total of 20 women, aged between 19 and 64 years, affected by recurrent lower leg telangiectasia, were included in this study. Patients were preliminarily submitted to echo color Doppler sonography to rule out severe saphenofemoral valve and lower limb major vein insufficiency. All patients underwent 3 sessions a month of polidocanol 1% capillary injections for 2 months. This was followed by 0.1 ml cross-linked hyaluronic acid introduction in the polidocanol 1% needle track. A total of 50 mesotherapeutic injections (0.05 ml each) were performed on the skin surface where an ice pack was previously applied for 4 to 5 minutes. A follow-up visit was performed at 3 months. The results, based on photographic examination, were rated as follows: poor improvement (0%-50%), good improvement (51%-75%), and very good improvement (76%-100%). The side effects of the clinical procedure, in terms of pain, itching, paresthesia, ecchymosis, and relapse of telangiectasia over the treated skin surface, as well as a persisting pigmentation in the injection spots and induced benefits related to leg heaviness and comfort, were recorded. **Results.** In total, 6 patients displayed a slight venous insufficiency, 3 patients displayed patent venous insufficiency, and 11 patients did not show any venous insufficiency. Before treatment, itching was present in 18 out of 20 patients, paresthesia in 15 out of 20 patients, ecchymosis in 16 out of 20 patients, and leg heaviness in 15 out of 20 patients. At the 3-month follow-up, an improvement of 0% to 50% was observed in 4 patients who had a relapse in telangiectasia. A 51% to 75% improvement was observed in 3 patients and a 76% to 100% improvement occurred in 13 patients. At the 3-month follow-up, itching persisted only in 4 patients; paresthesia was absent in 12 patients, while 3 patients still presented this symptom; ecchymosis was absent in 16 patients; 15 patients reported a feeling of lightweight legs. Among the patients with relapsing telangiectasia, 2 patients reported pigmentation due to hemosiderin deposit in the skin at the 3-month follow-up. The slight venous insufficiency, observed at the beginning of the study, improved in 5 out of 6 patients. The patients' compliance with the procedure was high and 16 out of 20 patients declared their willingness to repeat the whole clinical procedure, if necessary. **Conclusions.** This pilot clinical study supports the use of hyaluronic acid mesotherapeutic injections following sclerotherapy for treatment of lower leg telangiectasia without major venous insufficiency. We propose that the prolonged persistence of cross-linked hyaluronic acid, across the microvascular venous areas, is able to induce a stronger stromal tissue, thus preventing relapse. Further clinical studies, comparing this new approach with existing clinical procedures, are needed in a larger number of patients.

Keywords

hyaluronic acid, polidocanol, mesotherapy, telangiectasia

Introduction

Telangiectasia is the dilation of dermal capillaries mainly due to hypertension and vein insufficiency. Skin telangiectasia is an aesthetic defect characterized by an unpleasant appearance,

¹ Department of Physiology, School of Medicine, University of Kentucky Medical Center, Lexington, KY, USA

² Poliambulatorio del Secondo Parere, Modena, Italy

³ Department of General Surgery and Surgical Specialties, University of Modena and Reggio Emilia Medical School, Surgical Clinic, Modena, Italy

Corresponding Author:

Tommaso Iannitti, Department of Physiology, School of Medicine, University of Kentucky Medical Center, Lexington, KY 40536-0298, USA.

Email: tommaso.iannitti@gmail.com

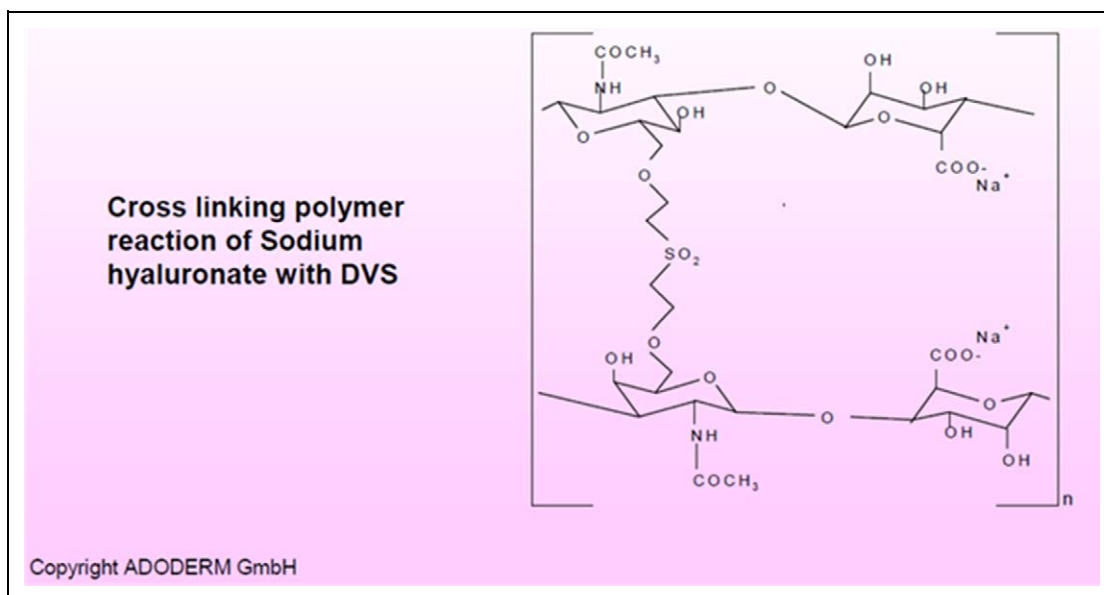


Figure 1. Cross-linking polymer reaction of sodium hyaluronate with divinyl sulfone (DVS; permission to reproduce this picture has been obtained from Adoderm GmbH, Langenfeld, Germany).

but it is also characterized by discomfort, itching, and a high rate of bruising.¹ Nowadays, sclerotherapy with foam liquid and external or intradermal fiber optic laser energy delivery represents the “gold standard” treatment.^{2,3} We hypothesize that application of highly cross-linked hyaluronic acid (HA) mesotherapeutic injections, directly into the dermis affected by telangiectasia, may enhance the capillary network and support the stromal tissue. HA is a natural glycosaminoglycan synthesized by the cell membrane and released into the extracellular matrix.⁴ This polysaccharide is present in all the living organisms where it plays a key structural function. It is made up of disaccharidic units (structure: [D-glucuronic acid (1-β-3) N-acetyl-D-glucosamine (1-β-4)]_n) that can polymerize to give a high-molecular-weight compound.⁵ In humans, native HA is internalized in stromal cells mainly through interaction with CD44 receptor and, subsequently, it is rapidly metabolized and hydrolyzed by hyaluronidase and glucosidase activity.⁶ In order to obtain a more resistant filler that is able to remain longer inside the human body, HA needs to be stabilized by a cross-linking process that leads to the formation of a viscous gel.⁷ Cross-linked HA is less soluble in water and exerts a long-standing biomechanical effect since it is slowly degraded.⁸ For this reason, in order to obtain a more effective and long-lasting result, we selected a highly cross-linked HA, that is, Variofill (Adoderm GmbH, Langenfeld, Germany), a safe and widely used cosmetic filler available in 10-ml syringes (concentration 33 mg/ml).

Variofill is produced from a 33 mg/ml solution of non-cross-linked HA (10⁶ Da). This solution undergoes extensive cross-linking with divinyl sulfone (DVS; up to 80% cross-linking; Figure 1). Afterwards the DVS is completely washed out. The highly concentrated and cross-linked HA obtained, which is characterized by a significantly higher viscosity compared to

the initial mixture, is subsequently formed into particles and stabilized to obtain a pure cross-linked HA, that is, Variofill. This method is described as new monophasic particle technology (MPT).

Aim

We tested the hypothesis that small filler drops injected through a targeted filler-based mesotherapy, would improve the cosmetic and functional appearance of the leg, especially in cases of telangiectasias without major venous insufficiency. The present study was designed to determine, for the first time, the effect of mesotherapeutic injections of HA in the areas of the skin affected by telangiectasia after sclerotherapy in patients without major venous insufficiency. The rationale of this study is to support the venous microvascular network with cross-linked HA injections in the spots, where dilated microvessels arise inducing a stronger fibroblastic framework in the interstitial tissue, avoiding dilation of capillaries.

Materials and Methods

The present study was performed at the Poliambulatorio del Secondo Parere (Modena, Italy). This study was performed according to the Helsinki Declaration and approved by the local Internal Review Board. All patients signed the informed consent before the beginning of the procedure.

Patients

A total of 46 women, affected by lower leg telangiectasia, were screened. Inclusion criteria for the present study were multiple, bilateral, and symptomatic lower leg telangiectasia without

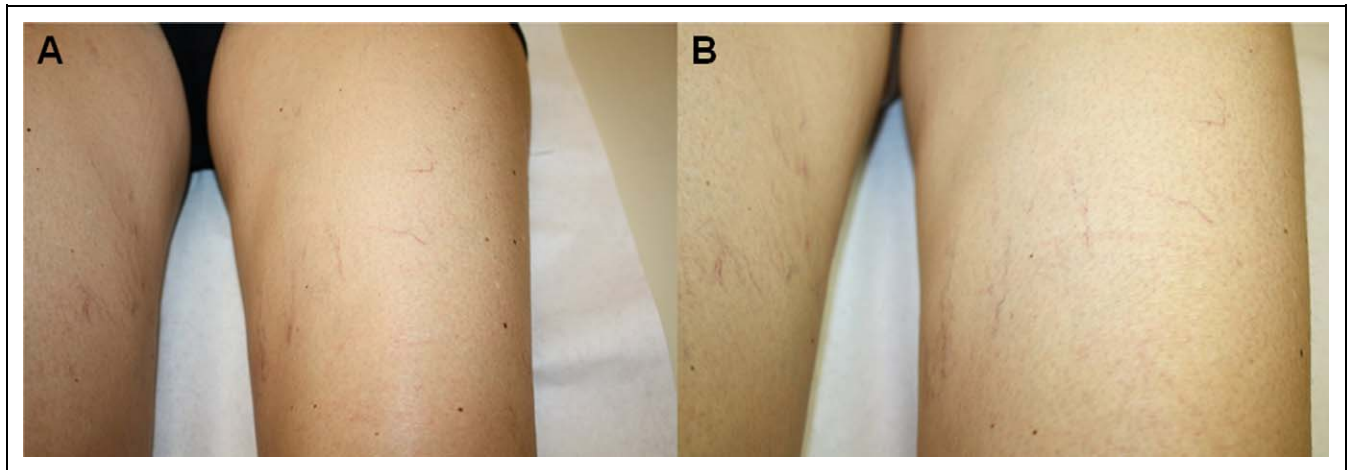


Figure 2. Patient before (A) and after (B) treatment (rated as poor improvement). Telangiectasia and capillary network dilations are still present after treatment.

major venous insufficiency. Exclusion criteria were HA and polidocanol allergy, dermatitis due to lymphovenous insufficiency, pregnancy, cutaneous dyschromia, severe renal and cardiorespiratory insufficiency, diabetes and body mass index >25 .

Intervention

All patients underwent the following protocol:

- polidocanol 1% (Aethoxysklerol, Chemische Fabrik Kreussler & Co. GmbH, Germany) capillary injections (3 sessions a month for 2 months);
- disconnection of the polidocanol 1% syringe leaving the needle in place;
- 0.1 ml cross-linked HA (Variofill, Adoderm GmbH, Langenfeld, Germany) precharged syringe introduction in the polidocanol 1% needle track;
- a total of 50 mesotherapeutic injections (0.05 ml each) on the treated skin area where an ice pack was previously applied for 4 to 5 minutes for a total of 3 sessions a month.

In case of patients displaying slight venous insufficiency, mesotherapy was concentrated around the minor refluxing venous trunks.

Outcome Evaluation/Follow-up

The following 4 parameters were analyzed: itching, paresthesia, leg heaviness, and recurring presence of ecchymosis. Patients were preliminarily submitted to echo color Doppler sonography to rule out severe saphenofemoral valve and lower limb major venous insufficiency. A follow-up visit was performed at 3 months after the end of treatment to evaluate the cosmetic and functional effects of the procedure. This was assessed by means of photographic examination conducted by 2 dermatologists for the whole duration of the study. The results, based on photographic examination, were rated as

follows: poor improvement (0%-50%), good improvement (51%-75%), and very good improvement (76%-100%). The side effects of the clinical procedure, in terms of pain, itching, paresthesia, ecchymosis and relapse of telangiectasia over the treated skin surface, as well as a persisting pigmentation in the injection spots and induced benefits related to leg heaviness, were recorded. At the end of the clinical course of treatment, patients were asked whether they were willing, if necessary, to undergo the whole procedure again so as to understand the patient's compliance with the clinical procedure.

Results

Only 20 women, aged between 19 and 64 years, (45.9 ± 2.6 [mean \pm standard error of mean (SEM)]), complied with inclusion/exclusion criteria and were included in the present investigation.

After echo color Doppler examination, 6 patients displayed a slight venous insufficiency and 3 patients displayed patent venous insufficiency. The other 11 patients did not show any venous insufficiency. Patients presented a mean of 12 ± 0.7 (mean \pm SEM; range: 6-18) areas of telangiectasia. They were distributed on the volar part of the tibial bone and on the ventromedial and posterolateral part of the thigh; vessel diameters were in the range of 0.4 to 5.0 mm. Before treatment, itching was present in 18 out of 20 patients, paresthesia in 15 out of 20 patients, ecchymosis in 16 out of 20 patients, and leg heaviness in 15 out of 20 patients. Photographic examination, at the 3-month follow-up revealed 0% to 50% improvement in 4 patients (these patients presented a relapse in telangiectasia; they reported an improvement in the treated sites, but new areas affected by telangiectasia appeared in the surrounding areas; Figure 2), 51% to 75% improvement in 3 patients (Figure 3), and 76% to 100% improvement in 13 patients (Figure 4), as determined by the 2 dermatologists involved in this investigation. At the 3-month follow-up, itching persisted only in 4 patients; paresthesia was absent in 12 patients, while 3 patients

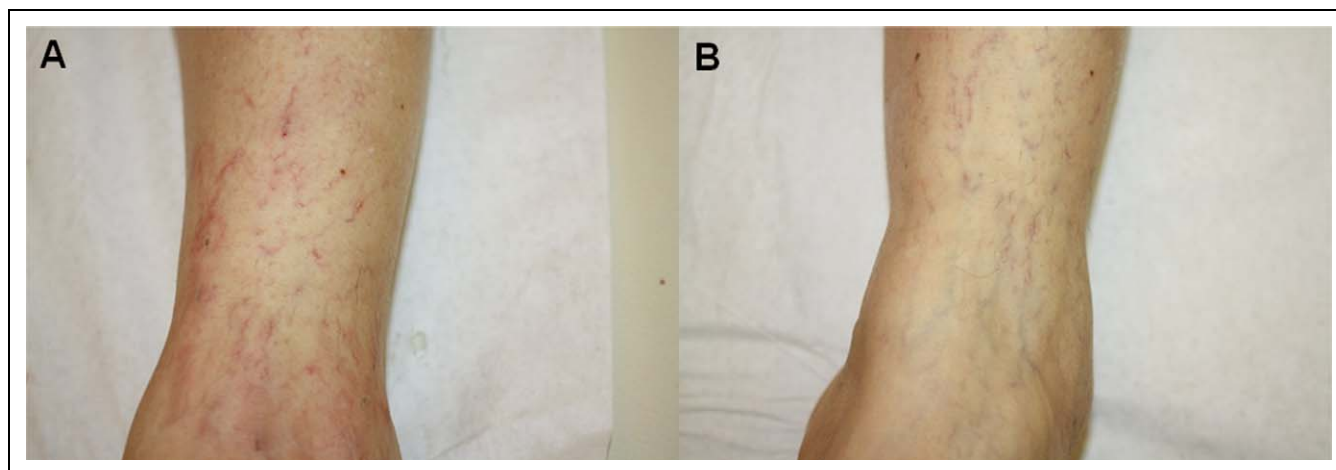


Figure 3. Patient before (A) and after (B) treatment (rated as good improvement; amelioration of the microvascular network with reduction of telangiectasia).

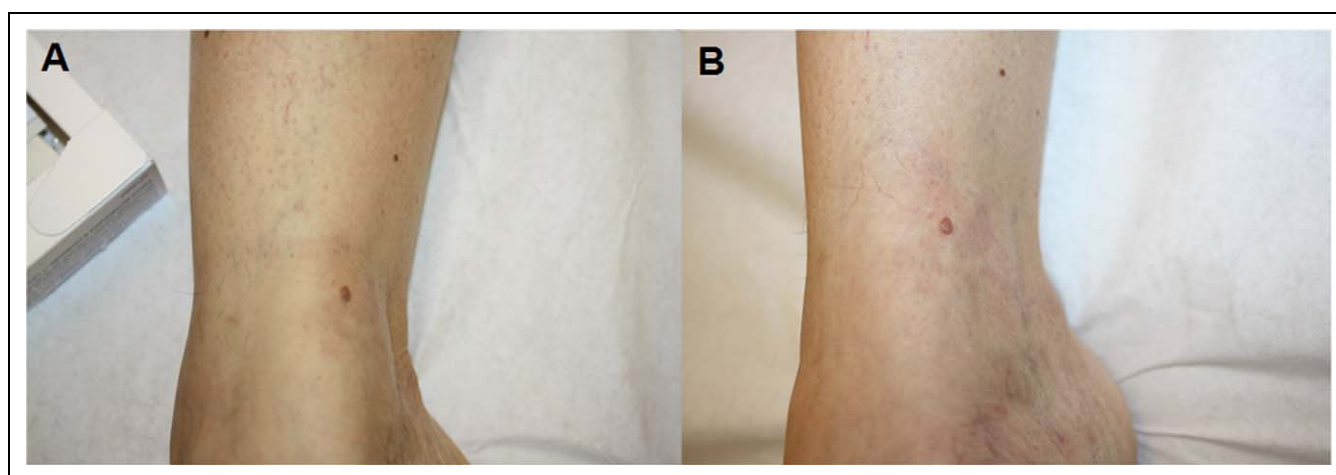


Figure 4. Patient before (A) and after (B) treatment (rated as very good improvement; disappearance of dilated subdermal microvessels).

still presented this symptom; ecchymosis was absent in all the sixteen patients; 15 patients reported a feeling of lightweight legs. No foreign body reaction was observed among the patients involved in this study. Among the 4 patients with relapsing telangiectasia, 2 patients reported pigmentation due to hemosiderin deposit in the skin at the 3-month follow-up. At the beginning of the study, these patients presented slight venous insufficiency (1 case) and patent venous insufficiency (3 cases). The slight venous insufficiency, observed at the beginning of the study, improved in 5 out of 6 patients. During the clinical procedure, all the patients manifested high compliance to continue with treatment regimen. At the end of the study, 16 out of 20 patients declared their willingness to repeat the whole clinical procedure, if necessary.

Conclusions

The present study investigated the effect of a new procedure based on a combination of HA injections and sclerotherapy for treatment of telangiectasia. This study was performed in

women, rather than in men, since for them, in our experience, lower leg telangiectasia represents a much heavier burden to bear because of the aesthetic component of the disease that makes them more enthusiastic about the idea of a new procedure. In our cohort of 20 patients, good to very good results were reported in 16 patients, as assessed by 2 dermatologists at the 3-month follow-up. Overall, a complete remission of leg heaviness and ecchymosis was observed in those patients presenting these symptoms prior to the procedure. Itching and paresthesia persisted only in 4 out of 18 and 3 out of 15 patients. According to the present preliminary study, the procedure, based on HA mesotherapeutic injections and sclerotherapy, was safe and the majority of the patients showed high compliance in repeating the entire course of treatment. These findings strongly support the use of this procedure for improving hydrophilia and elasticity of the stroma and counteracting newly formed areas of telangiectasia and relapses. However, 4 patients showed a relapse in their condition, which may be due to further hemodynamic changes of the lower leg microcirculation. Two patients reported a relevant weight gain

(5 and 6 kg, respectively) and changes in lifestyle with strong reduction in physical activity that may have negatively influenced the microcirculation.

This study emphasizes the potential role of the dermal and subcutaneous stromal tissue in supporting the microcirculatory network in a tense viscoelastic environment suitable to maintain, in the long run, the cosmetic restoration of the treated legs. In fact, in our group the 3-month follow-up showed the good persisting outcome of sclerotherapy when supported, in the treated area, by adequate mesotherapy with cross-linked HA. Furthermore, the improvement in slight venous insufficiency, observed in 5 out of 6 patients, confirms that a stronger and more elastic support of the interstitial tissue, in the HA-treated areas, can improve or even restore the physiological venous drainage. In these patients the results lasted until 3 months. On the basis of the results from the present pilot clinical study, we can outline three potential indications of cross-linked HA injection for treatment of lower leg telangiectasia: (1) HA could be used as an intermittent treatment every 3 to 6 months after sclerotherapy to reinforce the skin texture, avoiding lumen dilation, and thus preventing the worsening of symptoms and relapse of telangiectasia; (2) it might be a complementary treatment to support and maintain the capillary permanent obstruction when injected across the external capillary wall; (3) it might be indicated for treatment of early telangiectasia, when the intraluminal injection is not possible because of the extremely thin lumen. In fact, if the needle is not allowed to enter into the capillary lumen, polidocanol extravascular injection can generate postinflammatory sclerosis of the stroma, while HA injection in the interstitial space helps connective tissue to regenerate normal collagen bundles and reticulin.

In conclusion, this pilot study supports the use of HA mesotherapeutic injections following sclerotherapy for treatment of lower leg telangiectasia. We suggest that the prolonged persistence of cross-linked HA, across the microvascular venous areas, is able to induce a stronger stromal tissue, thus preventing relapse. Further controlled clinical studies, comparing the use of HA in comparison with other techniques are needed in larger cohorts of patients.

Acknowledgments

The authors contributed equally to this work. This article was not supported by grants.

Authors' Note

The authors hereby certify that all work contained in this article is original work.

Declaration of Conflicting Interests

The author(s) declared no potential conflicts of interest with respect to the research, authorship, and/or publication of this article.

Funding

The author(s) received no financial support for the research, authorship, and/or publication of this article.

References

1. Neumann HA, Kockaert MA. The treatment of leg telangiectasia. *J Cosmet Dermatol.* 2003;2(2):73-81.
2. Tessari L, Cavezzi A, Frullini A. Preliminary experience with a new sclerosing foam in the treatment of varicose veins. *Dermatol Surg.* 2001;27(1):58-60.
3. Gerard JL, Desgranges P, Becquemin JP, Desse H, Mellièrè D. Feasibility of ambulatory endovenous laser for the treatment of greater saphenous varicose veins: one-month outcome in a series of 20 outpatients. [In French]. *J Mal Vasc.* 2002;27(4):222-225.
4. Laurent TC, Fraser JR. Hyaluronan. *FASEB J.* 1992;6(7):2397-2404.
5. Colau PJ. Long-lasting and permanent fillers: biomaterial influence over host tissue response. *Plast Reconstr Surg.* 2007;119(7):2271-2286.
6. Aruffo A, Stamenkovic I, Melnick M, Underhill CB, Seed B. CD44 is the principal cell surface receptor for hyaluronate. *Cell.* 1990;61(7):1303-1313.
7. Altman RD, Akermark C, Beaulieu AD, Schnitzer T. Efficacy and safety of a single intra-articular injection of non-animal stabilized hyaluronic acid (NASHA) in patients with osteoarthritis of the knee. *Osteoarthritis Cartilage.* 2004;12(8):642-649.
8. Schiraldi C, La Gatta A, De Rosa M. *Biotechnological Production and Application of Hyaluronan.* Biopolymers. Magdy Elnashar, ed. ISBN: 978-953-307-109-1, InTech; 2010. <http://www.intechopen.com/books/biopolymers/biotechnological-production-characterization-and-application-of-hyaluronan>.