



Abdominal nodal localization of Castleman's disease: Report of a case

L.G. Greco^a, M. Tedeschi^{a,*}, S. Stasolla^a, A. Gentile^a, A. Gentile^b, D. Piscitelli^b

^a Department of Emergency and Organ Transplantation, Section of General Surgery and Liver Transplantation, University of Bari, Italy

^b Department of Pathological Anatomy, University of Bari, Italy

ARTICLE INFO

Article history:

Received 29 December 2009

Received in revised form

22 June 2010

Accepted 28 June 2010

Available online 30 July 2010

Keywords:

Castleman's disease

Abdominal localization

Castleman's disease management

Human Herpesvirus 8

ABSTRACT

Introduction: Castleman's disease (CD) is a rare benign disorder that may grow in any area where lymphoid tissue is normally present but the most frequent site is mediastinum (67%); the abdomen is rarely affected by this pathology. In the pathogenesis of CD an important role could be played by HHV-8. Diagnosis is difficult and the diagnostic certainty is obtained only by histological examination. For this disease there is no gold-standard treatment.

Case report: We report the case of a woman of 33 years of age affected by a rare form of abdominal nodal localization of Castleman's Disease for which the patient underwent surgery.

Conclusion: CD must be included in the differential diagnosis of retroperitoneal tumors even though the definitive diagnosis can only be achieved by histological and immunohistochemical examination. In the case of single location, the treatment of choice is surgical removal.

© 2010 Surgical Associates Ltd. Published by Elsevier Ltd. All rights reserved.

1. Introduction

Castleman's disease is a rare proliferative disorder of a benign nature characterized by hyperplasia of lymphoid follicles.^{1,2} The most frequent location of the CD is the chest (70%) although this pathology can theoretically affect any nodal station.² The abdomen is rarely affected by this pathology, abdominal localizations reported in the literature are: mesentery, retroperitoneum, pancreas, pelvis and rectum.³

Diagnosis is difficult and the diagnostic certainty is obtained only by histological examination. For this disease there is no gold-standard treatment.

2. Case report

A 33-year old woman with a silent pathology history, was referred to us for weight loss (about 3 kg) and epigastric pain radiated to the right side and rear in the lumbar region. The abdominal examination did not reveal anything pathological. The blood tests did not show anything at the pathological level and the tumor markers were normal, as were the results of chest X-rays. The abdominal ultrasound detected the presence in the right epigastric region a hypoechogenic image, homogeneous, round, surrounded by a hyperechogenic capsule (max diameter 31 mm),

compressing from behind the ICV, laterally the gallbladder and contracts with the head of the pancreas. Given the inconsistency in interpretation and in order to obtain more detailed information a CT scan of the abdomen was carried out and this confirmed the presence between aorta and ICV, at the level of the duodenal C knee, a formation of 3 cm oval with homogeneous enhancement similar to after injection of intravenous contrast medium and the radiologist suggested that it was a leiomyoma of the duodenal wall. In history the patient had reported repeated episodes of herpetic infection localized in the lip. The detection of the anti-HHV-8 antibodies was successful because the patient had serum antibodies against the virus.

The patient then underwent surgery of the formation. In the operating field there was nothing pathological as regards the stomach and duodenum. However, in the retroperitoneal location, below the third duodenal portion, in the paracaval site, there was a found a smooth, ovular, taught-elastic formation (Figs. 1 and 2). No retroperitoneal adenopathy was detected.

The histological examination showed that the lymph node was a neo-formation and this allowed us to make a diagnosis of Castleman's disease with vascular ialino-positive immunohistochemical reaction for CD-20 CD-3, CD-138 and Ki-67 (Figs. 3 and 4).

After a clinical course without complications, the patient was discharged and is currently in good health.

3. Discussion

Castleman's disease is a rare benign disorder first described by Castleman in 1954 in a group of patients with mediastinal lymphadenopathy.^{2,4}

* Corresponding author. Chirurgia Generale e Trapianto di Fegato, D.E.T.O., Università di Bari, Piazza Giulio Cesare 11, 70124 Bari, Italy. Tel.: +39 0805593221.

E-mail address: mictedeschi@yahoo.it (M. Tedeschi).

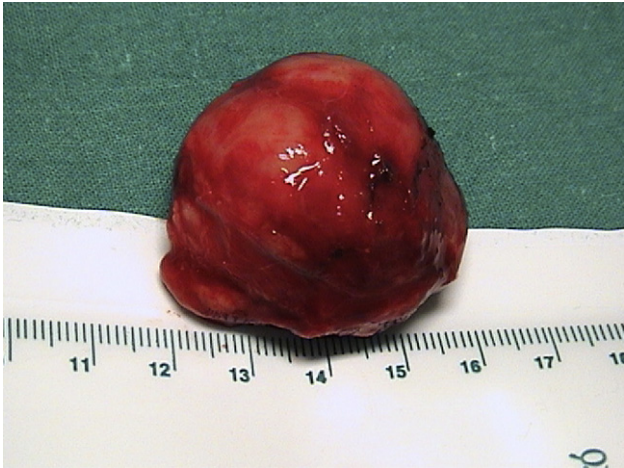

Fig. 1. Gross findings of lymph node.

The Castleman's disease may grow in any area where lymphoid tissue is normally present but the most frequent is mediastinal (67%),⁵ the abdomen is rarely affected by this pathology; abdominal localizations reported in the literature are: mesentery, retroperitoneum, pancreas, pelvis, rectum, however, being mesenteric and perinephric sites the most frequent in pelvis.³ The retroperitoneal location of the CD is extremely rare presenting only 7% of cases,⁶ usually at the left side. In the literature in fact the ratio between the right and left location is equal to 13:4.⁷ In our case the CD was localized in the right paramedian site.

Castleman's disease in the abdomen and pelvis is even rarer and should be distinguished from tuberculosis of the mesentery, lymphoma, accessory spleen, and other hypervascular lesions. From the radiological and clinical points of view, disseminated Castleman's disease may be indistinguishable from lymphoma.

Ultimately, ultrasound-guided aspiration biopsy of an enlarged lymph node or mass is recommended for histopathological diagnosis.⁸

Based on the histological features Flendring and Schillings⁹ have described two different variants of CD and a mixed form that Keller et al. subsequently defined as a form ialino vascular (HV) is the plasma cell (PC) and form plamacellulare mixed ialino vascular (HV-PC).²

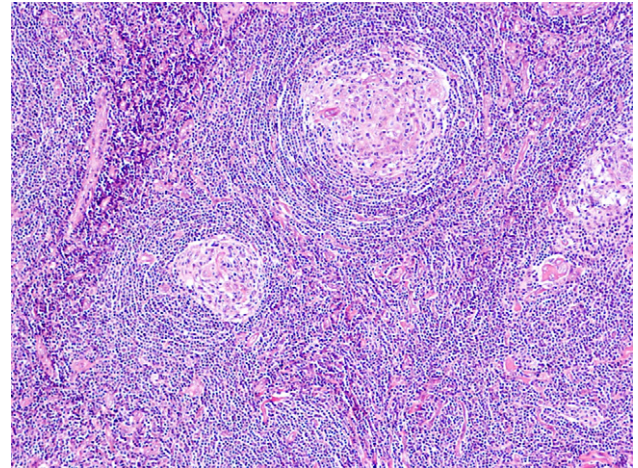


Fig. 3. Microscopic findings of lymph node.

The etiology is currently unknown but it is assumed that this disease could be a response to a chronic inflammatory process,⁴ an amartomatoso process,¹⁰ a state of immunodeficiency¹¹ or an immune disorder.¹² The Epstein-Barr Virus, Toxoplasma and *Mycobacterium tuberculosis* have been considered to be involved in the genesis of some cases of variant PC CD.^{2,12}

Several studies in animal models and humans have focused attention on the role of IL-6 in activation of the differentiation of plasma cells, the proliferative processes of the lymphoid cells¹³ and vascular endothelium and the onset of events involved in this systemic disease.¹⁰

The Human Herpes Virus 8 (HHV-8) is the causative agent of Kaposi's sarcoma in immunosuppressed subjects,¹⁴ this virus was also frequently found in HIV+ and patients suffering from CD¹⁵ and so it is possible to affirm that it can play an important role in the pathogenesis of Kaposi's sarcoma as well as the multicentric form of CD. In our case, the patient had anti-HHV-8 and also had a history of numerous reported incidents of herpetic infection, which could further support the view that this virus might be somehow involved in the pathogenesis of CD. The hypothesis that the IL-6 may play an important role in the pathogenesis of CD is supported by the fact that the HHV-8 has a gene coding for a protein similar to IL-6 (VIL-6)¹⁶ which could be responsible for the clinical-pathological anatomy typical of CD.¹⁷

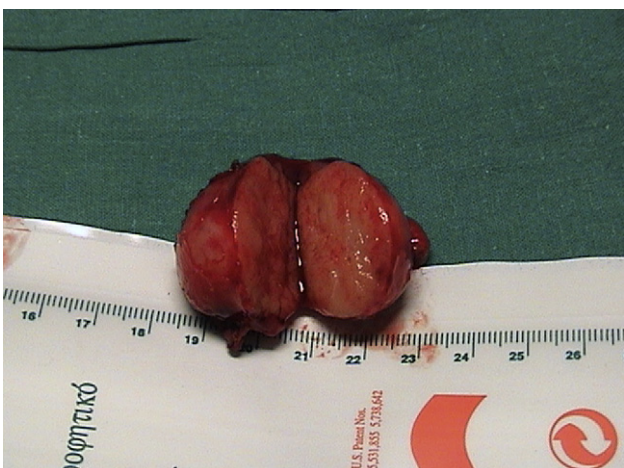

Fig. 2. Gross findings of lymph node.

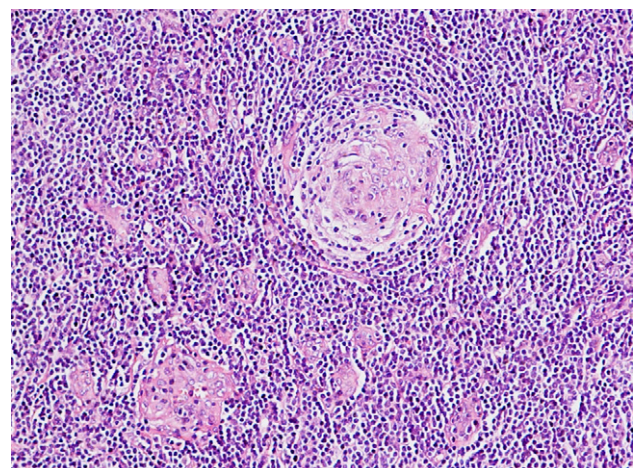


Fig. 4. Microscopic findings of lymph node.

Treatment of unicentric CD most of the times is based on resection, which offers the best chance for cure.¹⁸

In the near future, new treatment protocols for CD, such as anti-interleukin-6 receptor antibody (tocilizumab) therapy,¹⁹ will be applied.

4. Conclusion

CD must be included in the differential diagnosis of retroperitoneal tumors even though the definitive diagnosis can only be achieved by histological and immunohistochemical examination. The retroperitoneal location is rare, especially if the lesion is located on the right. In the pathogenesis of CD an important role could be played by HHV-8 whose presence could be the stimulus that causes the chronic inflammatory response in the chronic course of this CD. In the case of single location, the treatment of choice is surgical removal.

Conflict of interest statement

None to declare.

Funding

None.

Ethical approval

Yes.

References

1. Castleman B, Towne VW. Case records of the Massachusetts General Hospital: case 40011. *N Engl J Med* 1954;**250**:26–30.
2. Keller AR, Hochholzer L, Castleman B. Hyalinevascular and plasma-cell types of giant lymph node hyperplasia of the mediastinum and other locations. *Cancer* 1972;**29**:670–83.
3. Kimura T, Inoue T, Katayama K, Hirose K, Imamura Y, Yamaguchi A. Mesenteric Castleman's disease: report of a case. *Surg Today* 2002;**32**(7):651–4.
4. Castleman B, Iverson L, Menendez VP. Localised mediastinal lymph node hyperplasia resembling thymoma. *Cancer* 1956;**9**:822–30.
5. Iida E, Kohno A, Mikami T, Kumekawa H, Akimoto S, Hmano K. Mesenteric Castleman tumor. *J Comput Assist Tomogr* 1983;**7**:338–40.
6. Takihara H, Yamakawa G, Baba Y, Takahashi M, Ishihara T. Castleman disease. Unusual retroperitoneal location indistinguishable from malignant tumor in preoperative angiographic appearance. *Urology* 1983;**41**:162–4.
7. Wang R, Wang Y, Tan G. Localized Castleman's disease of the abdomen: CT and histo-pathologic correlation. *J Chin Radiol* 2002;**36**:159–62.
8. Zhang KR, Jia HM. Mesenteric Castleman disease. *J Pediatr Surg* 2008;**43**:1398–400.
9. Flendrig JA. Benign giant lymphoma: clinicopathologic correlation study. In: Clark RL, Cumley RW, editors. *The year book of cancer*. Chicago: Year Book Medical Publishers; 1970. p. 296–9.
10. Hsu S-M, Waldron JA, Xie S-S, Barlogie B. Expression of interleukin-6 in Castleman's disease. *Hum Pathol* 1993;**24**:833–9.
11. Oksenhendler E, Duarte M, Soulier J, Cacoub P, Welker Y, Cadranet J, et al. Multicentric Castleman's disease in HIV infection: a clinical and pathological study of 20 patients. *AIDS* 1996;**10**:61–7.
12. Frizzera G. Castleman's disease: more questions than answers. *Hum Pathol* 1985;**15**:202–5.
13. Palestro G, Turrini F, Pagano M, Chiusa L. Castleman's disease. *Adv Clin Path* 1999;**3**:11–22.
14. Ganem D. Human herpesvirus 8 and the biology of Kaposi's sarcoma. *Semin Virol* 1996;**7**:325–32.
15. Soulier J, Grollet L, Oksenhendler E, Cacoub P, Cazals-Hatem D, Babinet P, et al. Kaposi's sarcoma-associated herpesvirus-like DNA sequences in multicentric Castleman's disease. *Blood* 1995;**86**:1276–80.
16. Staskus KA, Sun R, Miller G, Racz P, Jaslowski A, Metroka C, et al. Cellular tropism and viral interleukin-6 expression distinguish human herpesvirus 8 involvement in Kaposi's sarcoma, primary effusion lymphoma, and multicentric Castleman's disease. *J Virol* 1999;**73**:4181–7.
17. Foussat A, Fior R, Girard T, Boue F, Wijdenes J, Galanaud P, et al. Involvement of human interleukin-6 in systemic manifestation of human herpesvirus type 8-associated multicentric Castleman's diseases. *AIDS* 1999;**13**:150–2.
18. Wang H, Wiczorek RL, Zenilman ME, Desoto-Lapaix F, Ghosh BC, Bowne WB, et al. Castleman's disease in the head of the pancreas: report of a rare clinical entity and current perspective on diagnosis, treatment, and outcome. *World J Surg Oncol* 2007;**5**:133–9.
19. Nishimoto N, Kishimoto T. Interleukin 6: from bench to bedside. *Nat Clin Pract Rheumatol* 2006;**2**(11):619–26.