



## Anti-HCV Antibodies and Hepatocellular Carcinoma

Camillo Porta, Mauro Moroni, Giuseppe Nastasi, Giorgio Ricci & Ivo Casagrande

To cite this article: Camillo Porta, Mauro Moroni, Giuseppe Nastasi, Giorgio Ricci & Ivo Casagrande (1992) Anti-HCV Antibodies and Hepatocellular Carcinoma, Upsala Journal of Medical Sciences, 97:3, 261-266, DOI: [10.3109/03009739209179300](https://doi.org/10.3109/03009739209179300)

To link to this article: <http://dx.doi.org/10.3109/03009739209179300>



Published online: 18 Jan 2010.



Submit your article to this journal [↗](#)



Article views: 13



View related articles [↗](#)

## Anti-HCV Antibodies and Hepatocellular Carcinoma *Relationship in a Medium-risk Population*

Camillo Porta, Mauro Moroni, Giuseppe Nastasi, Giorgio Ricci<sup>1</sup> and Ivo Casagrande<sup>2</sup>

*Dipartimento di Medicina Interna e Terapia Medica, Sezione di Terapia Medica, Università degli Studi di Pavia, IRCCS Policlinico San Matteo, Pavia, Italy, <sup>1</sup>Divisione de Geriatria II, Ospedale Multizonale di Monza, Monza, Italy, and <sup>2</sup>Divisione di Medicina Generale, Ospedale Civile di Tortona, Tortona, Italy*

### ABSTRACT

By means of an accurate immunoenzymatic assay, the prevalence was studied of antibodies to hepatitis C virus (HCV) in three different populations: 74 patients affected with hepatocellular carcinoma (HCC) on preexisting cirrhosis, 82 patients with liver cirrhosis but with no apparent neoplasm, and 70 control subjects, hospitalized for various conditions, of internal medicine or geriatric interest. 70.2% of HCC patients exhibited anti-HCV antibodies, versus 47.5% of cirrhotic subjects with no tumor and 7.1% of controls. Such results suggest the possible role of HCV in the etiopathogenesis of HCC, and its possible synergy with other agents - *e.g.*, hepatitis B virus, alcohol - in causing chronically injured hepatocytes to become neoplastic.

### INTRODUCTION

In the past, hepatocellular carcinoma (HCC) was thought to be a kind of tumor limited to well-defined world areas, the so-called "high-risk" regions (over 20 cases per 100,000 males a year) - *e.g.*, China, South-East Asia, Sub-Saharan Africa, (10, 13, 16). However, in the past few years, the incidence of HCC seems to be on a steady and statistically significant increase even in the countries where it was known to have medium-low incidence - *e.g.*, Mediterranean countries, Norway, Poland, Hungary, etc. - , as an 8-year survey on 37 populations from different countries has demonstrated (12).

The oncogenic role of hepatitis B virus (HBV) in the genesis of HCC has been known for quite a long time; it seems to be especially marked in the countries where HCC strikes most (1, 9), while in lower-incidence countries, HCC seems more likely to be related to HBsAg-negative cirrhosis (7, 6). Recent research by Gilliam (5) and Okuda (11) suggest non-A, non-B hepatitis viruses as the possible factors causing the development of malignancy in these cirrhotic patients. Of late, the possibility of cloning the genome of

hepatitis C virus (HCV), thus demonstrating the circulating antibodies (anti-HCV), has allowed a very high rate of non-A, non-B hepatitis cases to be characterized as hepatitis C. For instance, in Italy, over 80% of the patients diagnosed as having posttransfusional non-A, non-B hepatitis and subsequently investigated for the presence of anti-HCV antibodies, was found to be positive (8).

For this reason we studied the prevalence of anti-HCV antibodies in the serum of HCC patients and compared with that of cirrhotic patients with no HCC and with that of controls.

### PATIENTS AND METHODS

*Patients* - Seventy-four patients with proven HCC were studied; in 59 of them US diagnosis had histological confirmation, while in the extant cases (15 patients) it had been confirmed by positive arteriographic findings and by the rise of  $\alpha_1$ -fetoprotein. In all cases the lesion seemed to have originated on preexisting cirrhosis: in 21 cases (28.3%) following chronic HBV infection (HBsAg-positive cirrhosis), in 36 patients (48.6%) on post-alcoholic cirrhosis and in the extant 17 cases (22.9%) on cryptogenic cirrhosis.

A group of 82 patients with liver cirrhosis but no signs of HCC was also studied; cirrhosis was HBsAg-positive in 30 cases (35.7%), post-alcoholic in 28 (33.3%) and cryptogenic in 26 cases (30.9%).

Finally, the control group included 70 subjects - *i.e.*, patients hospitalized for different conditions, of internal medicine or geriatric interest.

Table 1. *Features of the three examined populations.*

	HCC patients (No. 74)	Cirrhotic patients with no HCC (No. 82)	Controls with no liver conditions (No. 70)
Sex	54 M - 20 F	67 M - 15 F	46 M- 24 F
Mean age	65.8	67.6	66.8
Range	60-87	61-84	58-88

*Methods* - Each patient underwent routine hematochemical tests, including liver function tests,  $\alpha_1$ -fetoprotein assay and hepatitis B markers. The serum of all patients was tested for

the presence of anti-HCV-specific antibodies in the central analysis laboratories of our hospitals, by means of the same qualitative immunoenzymatic test on the market (Ortho HCV ELISA Test System 2<sup>nd</sup> generation<sup>®</sup>, Ortho Diagnostic Systems Inc., Raritan, NJ, USA). The test consists in three subsequent phases, carried out in a microwell coated with a combination of recombinant hepatitis C virus (rHCV) antigens. In phase I, the sample under examination is diluted and incubated in the microwell; if anti-HCV is present, an antigen-antibody reaction takes place at the microwell surface. In phase II, a murine conjugated monoclonal antibody adds to the antigen-antibody complex and selectively bonds to the IgG anti-HCV antibody. In phase III, the last one, an enzymatic assay system is added, consisting of OPD and hydrogen peroxide; in the presence of the bonded conjugate, OPD oxidizes and colored product results. The shade of color, which is in direct proportion with anti-HCV concentration, is finally measured by means of a spectrophotometer.

The  $\chi^2$  test was used for the statistical analysis of the obtained data.

## RESULTS

Fifty-two of 74 HCC patients were observed to be anti-HCV positive (70.2%): the percentage is much higher than that seen in both cirrhotic patients (39 positive cases: 47.5%;  $p \leq .001$ ) and non-hepatopathic controls (5 positive cases: 7.1%;  $p \leq .001$ ).

Table 2. *Prevalence of anti-HCV antibodies in the three examined populations.*

	No. of examined patients	No. of pts. positive for anti-HCV	Statistical significance (vs. HCC)
HCC patients	74	52 (70.2%)	-
Cirrhotic patients with no HCC	82	39 (47.5%)	$p \leq .001$
Controls with no liver conditions	70	5 (7.1%)	$p \leq .001$

Thus, after analyzing the prevalence of anti-HCV antibodies in the group of HCC patients, according to the kind of associated cirrhosis, we observed that: 10 of 21 patients with HCC on preexisting post-hepatitis B cirrhosis (HBsAg positive cirrhosis) were also

anti-HCV positive (47.6%), versus 25 (of 36) cases with HCC following alcoholic cirrhosis (69.4%) and 16 (of 17) with HCC following cryptogenic cirrhosis (94.1%).

In the group of cirrhotic patients with no evidence of HCC, the prevalence of anti-HCV antibodies went as follows: 8 of 30 HBsAg-positive cirrhosis cases were positive for anti-HCV (26.6%), versus 15 (of 28) patients with alcoholic cirrhosis (53.5%) and 16 (of 26) with cryptogenic cirrhosis (61.5%).

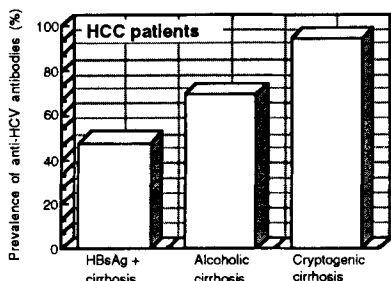


Fig. 1 - Prevalence of anti-HCV antibodies in HCC patients.

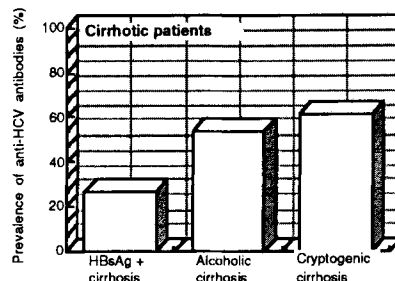


Fig. 2 - Prevalence of anti-HCV antibodies in cirrhotic patients with no evidence of HCC.

## DISCUSSION

In our study, we observed the marked prevalence of anti-HCV antibodies in HCC patients, which is in agreement with reports by other authors (3, 4).

Such prevalence (70.2%) was significantly higher than that observed in cirrhotic patients with no HCC or in the control subjects; moreover, it is much higher than the prevalence of the surface antigen of hepatitis B (HBsAg) observed in European patients with HCC (8-55%) in a number of investigations which failed to recognize the etiopathogenic role of HBV infection in HCC (2, 14, 15).

Therefore, we can at least hypothesize the etiopathogenic role of hepatitis C virus in the development of HCC in cirrhotic patients to be the same as, if not greater than, that of hepatitis B virus. The co-carcinogenic role of the two hepatitis viruses can also be hypothesized.

Relative to tumor development, the synergy is also quite likely of the viral damage induced by hepatitis C virus and the chronic damage caused by the prolonged consumption of much alcohol.

We could also confirm the former results by Okuda (11) and by Bruix et al. (3) - *i.e.*, the very high prevalence of anti-HCV antibodies in the patients with cryptogenic cirrhosis -

which may suggest a correlation between hepatitis C virus and chronic hepatopathy of unknown etiology.

To conclude, our results evidence the major role of hepatitis C virus in the development of HCC, which is likely to be increased by the associated presence of further chronic damaging factors of various kinds - *i.e.*, chemical (chronic alcohol abuse, aflatoxins) or viral (hepatitis B).

#### REFERENCES

1. Beasley, R.P.: Hepatitis B virus as the etiologic agent in hepatocellular carcinoma. Epidemiologic considerations. *Hepatology* 2 (Suppl.): 21-26S, 1982.
2. Brechot, Ch.: Hepatitis B virus (HBV) and hepatocellular carcinoma. *J Hepatol* 4: 269-279, 1987.
3. Bruix, J., Calvet, X. & Costa, J.: Prevalence of antibodies to hepatitis C virus in Spanish patients with hepatocellular carcinoma and hepatic cirrhosis. *Lancet* ii: 1004-1005, 1989.
4. Colombo, M., Choo, Q.L. & Del Ninno, E.: Prevalence of antibodies to hepatitis C virus in Italian patients with hepatocellular carcinoma. *Lancet* ii: 1006-1008, 1989.
5. Gilliam, J., Geisinger, J.R. & Richter, J.E.: Primary hepatocellular carcinoma after chronic non-A, non-B post-transfusion hepatitis. *Ann Intern Med* 101: 794-795, 1984.
6. Johnson, P.J. & Williams, R.: Cirrhosis and the aetiology of hepatocellular carcinoma. *J Hepatol* 4: 140-147, 1987.
7. Kew, M.C.: The development of hepatocellular cancer in humans. *Cancer Surv* 5: 719-739, 1986.
8. Kuo, G., Choo, Q.L. & Alter, H.J.: An assay for circulating antibodies to a major etiologic virus of human non-A, non-B hepatitis. *Science* 244: 362-364, 1989.
9. Lu, S.N., Lin, T.M. & Chen, C.J.: A case control study of primary hepatocellular carcinoma in Taiwan. *Cancer* 62: 2051-2055, 1988.
10. Muñoz, N. & Linsell, C.A.: Epidemiology of primary liver cancer. In: *Epidemiology of cancer of the digestive tract* (eds. Correa, P. & Haenszel, W.), pp. 161-195. Martin Nijhoff, The Hague, 1982.
11. Okuda, K.: Primary liver cancer. *Dig Dis Sci* 31 (Suppl.): 133-146S, 1986.
12. Saracci, R. & Repetto, F.: Time trends of liver cancer. *JNCI* 65: 241-247, 1980.
13. Tang, Z., Yang, B., Tang, C., Yu, Y., Li, Z. & Weng, H.: Evaluation of population screening for hepatocellular carcinoma. *Chinese Med J* 93: 795-799, 1980.

14. Trichopoulos, D., Day, N.E. & Kaklamani, E.: Hepatitis B virus, tobacco smoking and ethanol consumption in the etiology of hepatocellular carcinoma. *Int J Cancer* 39: 45-49, 1987.
15. Villa, E., Baldini, G.M. & Pasquinelli, C.: Risk factors for hepatocellular carcinoma in Italy. Male sex, hepatitis B virus, non-A, non-B infection and alcohol. *Cancer* 62: 611-615, 1988.
16. Waterhouse, J., Muir, C., Shanmugaratnam, K. & Powell, J. (eds.): *Cancer incidence in five continents (Vol. 6)*. International Agency for Research on Cancer, Lyon, 1982.

Address for reprints:

C. Porta, M.D.

Dipartimento di Medicina Interna e Terapia Medica,

Sezione di Terapia Medica,

Università di Pavia,

I.R.C.C.S. Policlinico "San Matteo"

I-27100 Pavia, ITALY.