

Original article

Extra-projected implants as an alternative surgical model for breast reconstruction. Implantation strategy and early results

Maurizio B. Nava, Andrea Spano, Pierfrancesco Cadenelli, Anna Colombetti, Andrea Menozzi, Angela Pennati, Giuseppe Catanuto*

Plastic Surgery Unit, Fondazione IRCCS Istituto Nazionale dei Tumori, Via Venezian 1°, 20133 Milan, Italy

Received 19 November 2007; accepted 21 January 2008

Abstract

The present study reports on patients who underwent breast reconstructions with extra-projection implants. Two-hundred and thirty-four women were treated for 238 breast reconstructions irrespectively of breast shape and size. In this series we aimed to reconstruct for all women a bilateral cosmetic medium-size breast (between 400 and 500 cc), highly projected, with a little to moderate ptosis rather than a ptotic one exactly matching the contra-lateral. This is demonstrated by volume of implants that ranged from 397 cc for ladies with small breast who received an augmentation, to 533 cc for those who side required a reduction surgery. Eighty-six percent of patients received contra-lateral procedures. Complication rate was 8.4% and 66% of reconstructions were rated as good in the patients' opinion. Extra-projection implants, coupled with contra-lateral breast surgery, provide a good aesthetic outcome and avoid myocutaneous flaps only on the basis of breast size and shape.

© 2008 Elsevier Ltd. All rights reserved.

Keywords: Breast reconstruction; Breast implants; Breast augmentation; Breast reduction; Extra-projected implants

Introduction

Breast implants for reconstructive and cosmetic purposes have greatly evolved during the last decade.¹ We moved from the original smooth semi-spheres partially filled with fluid silicone to current devices with multilayer textured envelopes and highly cohesive gel.

Multiple shapes are now available more close to the natural aspect of the female breast. For this reason prosthesis selection is based nowadays on three linear parameters (width, height, and projection on the thoracic wall) rather than simply on glandular volume.

Extra-projected implants have been introduced by the most advanced manufacturer in the last few years.² Their use for reconstructive purposes might modify surgical strategies,

increase cosmetic results and reduce the indication for autologous flaps.

Patients and methodologies

Patients diagnosed with early stage breast cancer scheduled to undergo mastectomy and reconstruction were admitted to this study irrespectively of mammary shape and dimensions. Based on morphological properties and patients' wishes, we offered either a two-stage operation or a single-stage immediate reconstruction. Women who decided to have a delayed reconstruction were also considered eligible.

All implants and expanders were provided by a single manufacturer (Allergan™, formally Inamed, Style 410 XP prosthesis and INSPIRA™ BIODIMENSIONAL tissue expanders).

The first stage of two-stage procedures and one-stage reconstructions were performed by surgical oncologists (mastectomy) and plastic surgeons. In the second stage, if a bilateral operation was required a double team of plastic surgeons was employed on the two sides.

* Corresponding author. Tel.: +39 022 390 2258; fax: +39 022 390 2602.

E-mail addresses: maurizio.nava@istitutotumori.mi.it (M.B. Nava), andrea.spano@istitutotumori.mi.it (A. Spano), giusepecatanuto@yahoo.it (G. Catanuto).

Table 1
Mean volume in comparison to contra-lateral procedure

	Overall	No contra-lateral procedures	Contra- lateral augmentation	Contra- lateral mastopexy	Contra- lateral reduction
Mean volume	456 cc	435 cc	397 cc	441 cc	533 cc

Results were evaluated in outpatient clinics by plastic surgeons at 3, 9 and 12 months, and every year after the final surgical stage. Patients were asked about their opinion on the reconstruction that was rated as good–medium–bad. Similarly, surgeons rated the breast shape and bilateral symmetry as good–medium–bad. Results were annotated in a clinical sheet and in the prospective database of our unit. In this study we reported outcome evaluation at 1 year. Photographs of patients were taken pre-operatively, post-operatively and at every visit to the outpatient clinic.

Statistical analysis of distribution in Tables 3–5 was performed using a chi-square test (level of significance $P = 0.05$).

Extra-projection implants selection and surgical strategy

Two-stage breast reconstructions

In the large majority of cases an immediate two-stage breast reconstruction was scheduled. Women candidates for mastectomy underwent joint clinical examination by plastic surgeons and surgical oncologists. The most appropriate mastectomy technique was selected (radical modified, skin sparing, etc.) as well as dimensions of temporary expanders.

A sizer tool provided by the manufacturer was employed to assist the surgeon in expander selection. Contra-lateral procedures (augmentation, reduction or mastopexy) were planned with the patient at this step to choose a correctly sized temporary prosthesis.

Expanders were placed sub-pectorally in the first stage; in the second stage the reconstructions were accomplished inserting permanent extra-projection implants after pouch reshaping and infra-mammary fold relocation.³

The selection of permanent prosthesis was based on dimensions of temporary expanders and had commonly the same width. Height was usually re-evaluated by gently compressing the contra-lateral breast against the chest wall and measuring the distance between infra-mammary fold and the superior folding line. All implants were extra-projected.

Contra-lateral procedures, although already planned at the first consultation, were discussed again at the time of final operation. Following informed consent we left the patient

Table 2
Patients' opinion on final results, and surgeons' opinion on breast shape and symmetry

	Good	Medium	Bad
Patient opinion	136 (66%)	57 (27.6%)	13 (6.3%)
Symmetry	113 (54.8%)	76 (36.8%)	17 (8.2%)
Shape	155 (75.2%)	49 (23.7%)	2 (0.97%)

Table 3
Contra-lateral procedures and patients' opinion

	Opinion				Total	$P = 0.001$
	Good	Medium	Bad	Total		
Augmentation	65 (79.2%)	17 (20.7%)	0	82		
Mastopexy	36 (65.4%)	13 (23.6%)	6 (10.9%)	55		
Reduction	43 (71.6%)	17 (28.3%)	0	60		

to choose any decision regarding surgery on the healthy side.

We offered a contra-lateral augmentation to small-breasted women. Medium-sized and ptotic breast reached symmetry with a contra-lateral mastopexy. We performed an opposite reduction in large breast reconstructions.

Steps for women who decided to have a delayed two-stage reconstruction were very similar to those described for immediate two-stage reconstructions.

One-stage immediate reconstructions

One-stage immediate reconstructions with extra-projected prosthesis were offered only to very small-breasted women who refused contra-lateral procedures. Women with large and ptotic breast were also admitted to one-stage immediate reconstruction and contra-lateral reduction in a single surgical operation that we called "skin-reducing mastectomy".⁴

After mastectomies and either one-stage or two-stage reconstructions all patients underwent adjuvant oncological treatment including radiation to chest wall and lymphatic chains whenever required.

Results

Population

Two hundred and thirty-four women with a mean age of 47 years (range 19–67 years) were found to be eligible for this study. Sixty-four women (27.4%) were smokers at the time of breast reconstruction. Two hundred and thirty-eight extra-projected implants were inserted (four bilateral procedures). The mean follow-up time was 18 months (range 12–45 months). Thirty-two (13.4%) patients were lost to follow-up, leaving 206 valuable implants.

Device widths ranged between 11.5 and 15.5 cm, corresponding to a volume between 255 cc and 685 cc and a mean volume of 456 cc. By comparison, the mean volume for contra-lateral procedures was 397 cc for augmentation,

Table 4
Contra-lateral procedures and surgeons' opinion regarding bilateral symmetry

	Symmetry				Total	$P = 0.015$
	Good	Medium	Bad	Total		
Augmentation	59 (71.9%)	23 (28%)	0	82		
Mastopexy	35 (63.6%)	15 (27.2%)	5 (9%)	55		
Reduction	31 (51.6%)	26 (43.3%)	3 (5%)	60		

Table 5
Contra-lateral procedures and implant based breast reconstruction: Comparison of two surgical models

	Augmentation	Mastopexy	Reduction	None	Total	
Nava et al. ⁴	82 (35.6%) ^a	55 (23.9%)	60 (26.8%)	33 (14.3%)	230	$P < 0.00001$
Losken et al. ⁶	150 (43%) ^a	33 (9%)	48 (14%)	118 (34%)	349	

^a The Augmentation column accounts also for cases of augmentation and mastopexy in the same operation: 12 cases in Nava et al.; 55 cases in Losken et al.

441 cc for contra-lateral mastopexies, and 533 cc for breast reduction surgeries (Table 1).

A total of 197 (84%) patients received contra-lateral procedures, including 82 augmentations, 55 mastopexies, and 60 breast reductions. No malignancies were found in the contra-lateral specimen.

Outcome

The complication rate was 9.5% (20 of 209 devices). They included 6 haematomas, 5 skin superficial necrosis, 5 skin necrosis and prosthesis extrusion (treated by debridement and implant substitution), 1 infection and implant removal, and 3 Baker Grade III contractures that required implant replacement. Sixteen patients (7.7%) received an implant replacement to improve the cosmetic result after more than 1 year.

Baker Grade IV capsular contracture was not observed in any patient. Baker Grade III capsular contracture was observed in 32 (15.5%) of 206 breasts.

Outcome evaluation at 1 year is reported for the whole population and in three subgroups subdivided according to contra-lateral technique.

One hundred and thirty-six patients (66%) at examination reported a good opinion of the result; shape and symmetry was considered good by plastic surgeons in 113 (54.8%), and 155 (75.2%), respectively (Table 2).

Sub-populations divided according to contra-lateral procedures revealed the highest rate of positive opinion in patients who underwent augmentation (74%) and the highest rate of bad opinion in those who received a mastopexy (10.4%). Similar results were reported by surgeons regarding symmetry assessment. (Tables 3 and 4).

Figs. 1–3 show the aesthetic results with extra-projection implants for breast reconstructions.

Discussion

Extra-projection, implant-based reconstructive strategy

Breast reconstructions were planned in the past with the purpose to rebuild an identical and possibly symmetrical breast mound. Several authors, for example, favoured autologous flaps that produce a natural symmetry even with

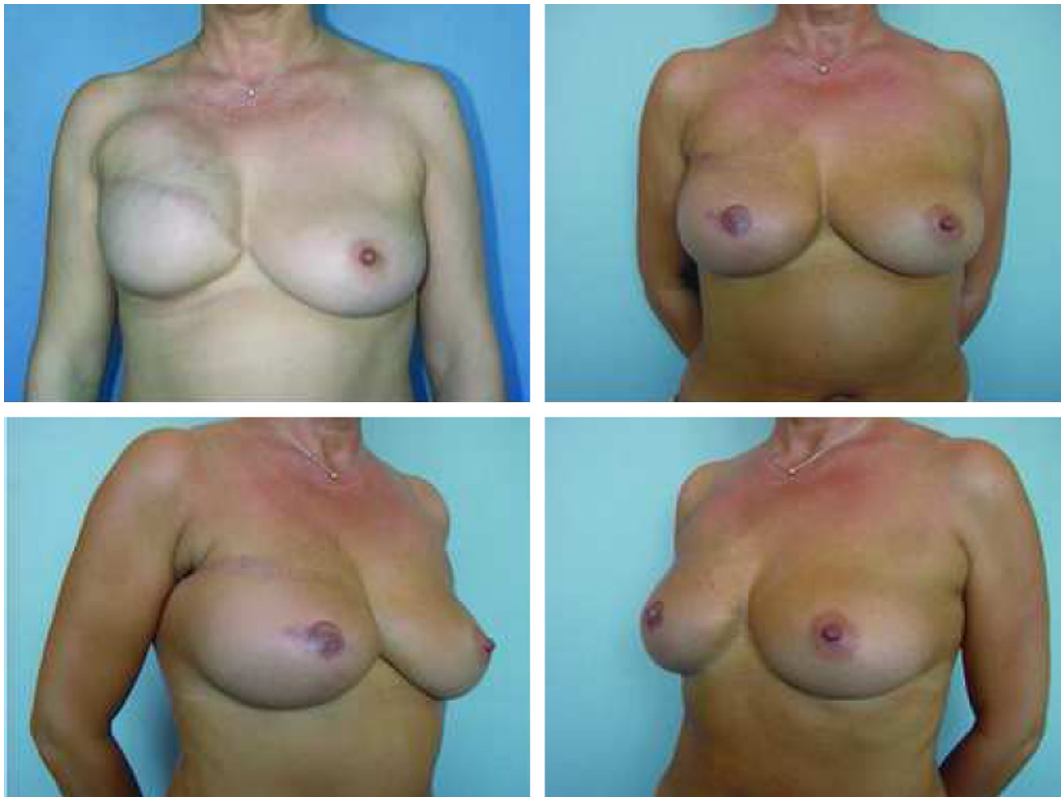

Fig. 1. Immediate two-stage breast reconstruction. One of the few cases in which youthful appearance of the contra-lateral breast can be matched without performing any contra-lateral adjustment. Above left: After expander insertion 600 cc. Above right and below: After extra-projection implant insertion and sub-mammary fold reconstruction.

a contra-lateral ptotic breast. Reconstructions with sub-pectoral implants were indicated mainly for small and medium-size glands with a moderate degree of ptosis. Operation on the healthy breast in search of symmetry were considered undesirable because of undue scarring.^{5,6}

Extra-projection devices in this study gave us the chance to modify this reconstructive predicament. In view of our results, modern implants can spare women from surgical treatments with severe biomechanical complications; they yield not only a rewarding cosmetic outcome but even a safe surgical approach.^{7–10}

In this series our reconstructive surgery aimed to create for all women a bilateral cosmetic medium-size breast (between 400 and 500 cc), highly projected, with a little to moderate ptosis rather than a ptotic one exactly matching the contra-lateral. This is demonstrated by volume of implanted prosthesis that ranged from 397 cc for women with small breast size who received an augmentation, to 533 cc for those whose healthy side required reduction surgery (Table 1).

Our approach substantially differs from that reported by Losken et al.⁶ in one of the largest series on breast reconstructions. In this study 118 of 349 (33.8%) patients did not have an intervention on the other side while on our series only 31 (13.2%) patients had no adjustments on the contra-lateral breast. Similarly, we described a higher number of contra-lateral breast

reductions (60 patients, 25.6% vs. 48, 13.8% by Losken et al.), which is due to our tendency to reconstruct with implants even larger breasts that in the past were considered suitable only for autologous flaps. Differences in distribution between the two series have proven to be highly statistically significant (Table 5).

Observation of sub-groups stratified according to opposite site operation demonstrated that the cosmetic and reconstructive purpose of this methodology is emphasized when implants are used also contra-laterally. Patient opinion in these cases was reported as good in 79.2%; on the other hand ptotic breasts, even using an effective technique such as the auto-prosthesis technique,¹¹ tend to recur with a “bad” opinion in 10.9% of the cases (Table 3).

We are aware that women who have developed breast cancer are at a higher risk of a second malignancy in the contra-lateral breast;¹² for this reason contra-lateral augmentations in this setting are still debatable. Evidence provided in the literature regarding this subject are still scarce. In healthy women it is well known that despite the diminished sensitivity of mammography with implants, augmented and non-augmented patients are diagnosed at a similar stage and have a comparable prognosis.¹³ Much longer follow-up in this study and the increased role of MRI will probably also clarify this aspect.¹⁴

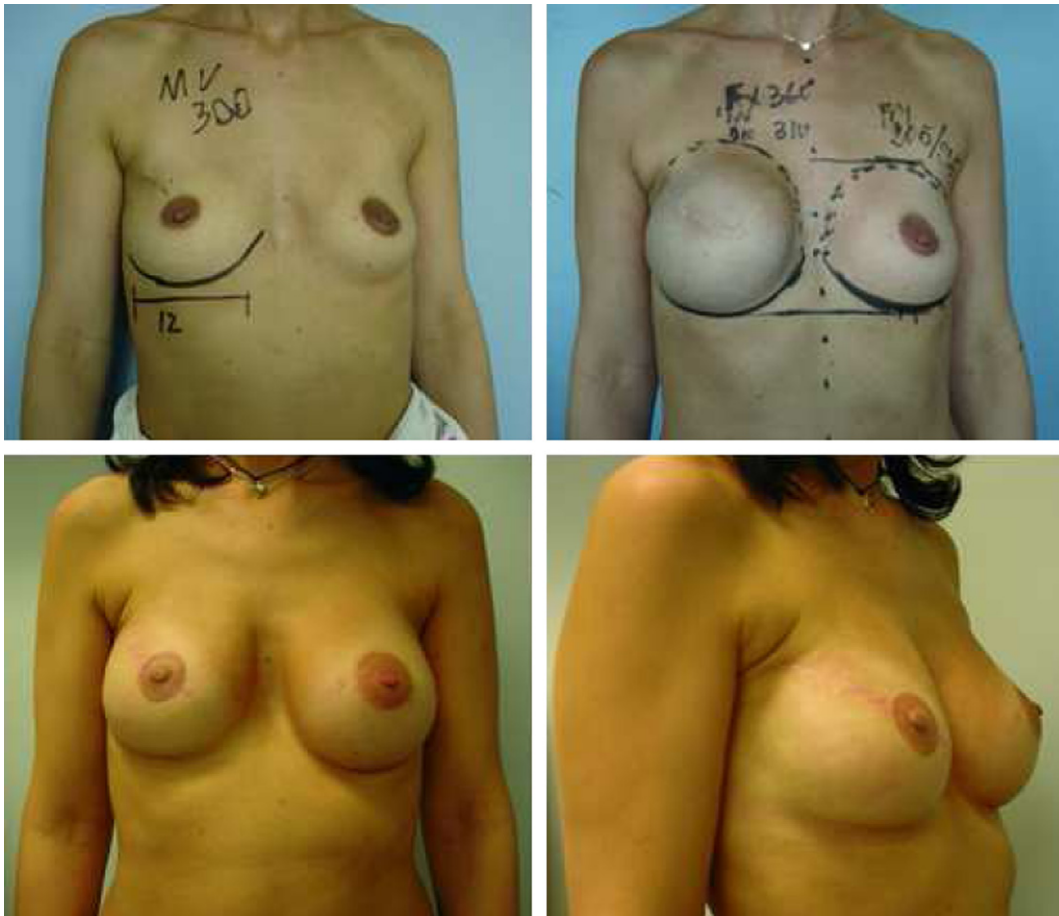


Fig. 2. Immediate two-stage breast reconstruction (above left). Small contra-lateral breast that the patient wishes to enlarge. An augmentation mastoplasty is planned on the healthy breast (above right). Below: After the second stage; extra-projection implant, sub-mammary fold reconstruction on the right side and contra-lateral breast augmentation.

Surgical sampling of the contra-lateral breast with reduction surgery could be beneficial from an oncological point of view. Petit et al.,⁸ for example, reported that in 4.6% of patients who received a contra-lateral reduction an occult synchronous carcinoma was revealed in the healthy breast. However, no malignancies were observed in the opposite breast specimen in our study, probably due to small size of the sample group. Further concerns raised in the past for large scarring on the unaffected gland are nowadays solved by improved effectiveness of breast magnetic resonance.¹⁵

In our opinion one-stage procedures lead to acceptable results only in a small sub-set of patients: young women with very small breasts not wishing any contra-lateral procedure and large-breasted women in which a single-stage “skin-reducing mastectomy” yields satisfying results with symmetrical scarring.

The second surgical operation in a two-stage approach, although causing some discomfort, greatly enhances the final results. It also provides an appropriate expansion to the lower pole of the breast and allows for infra-mammary fold reshape.¹⁶ For these reasons, only eight patients in our series were considered to be eligible for reconstruction in a single operation.

Outcome of implant-based reconstructions

Few investigators have reported on the outcome of two-stage expander/implant reconstructions. Ramon et al.¹⁷ and Castello et al.¹⁸ evaluated aesthetic results in small populations of 52 and 49 patients, respectively. In the Ramon et al. study, 75% of women obtained a good to excellent evaluation. In the Castello et al. study, a 6.9 average aesthetic score on a 10-point scale was achieved. More recently Cordeiro et al.^{19,20} reported on a series of 315 two-stage reconstructions with a 90% good-to-excellent aesthetic result at a mean follow-up of 3 years. Our findings are consistent with these studies.

To our knowledge, there has been a single published study that investigated the use of extra-projection prostheses in two-stage reconstructions. Delgado et al.² implanted 102 patients with Allergan Style 410 XP devices, as well as similar products from different manufacturers. The patient satisfaction results are comparable to those reported in our series at the 1-year follow up.

Capsular contracture and implant replacement were also investigated. Thirty-two (13.4%) of patients in the Delgado et al. study² developed a Baker Grade III after a mean follow-up of 16 months. In our series, 15.5% of the patients developed

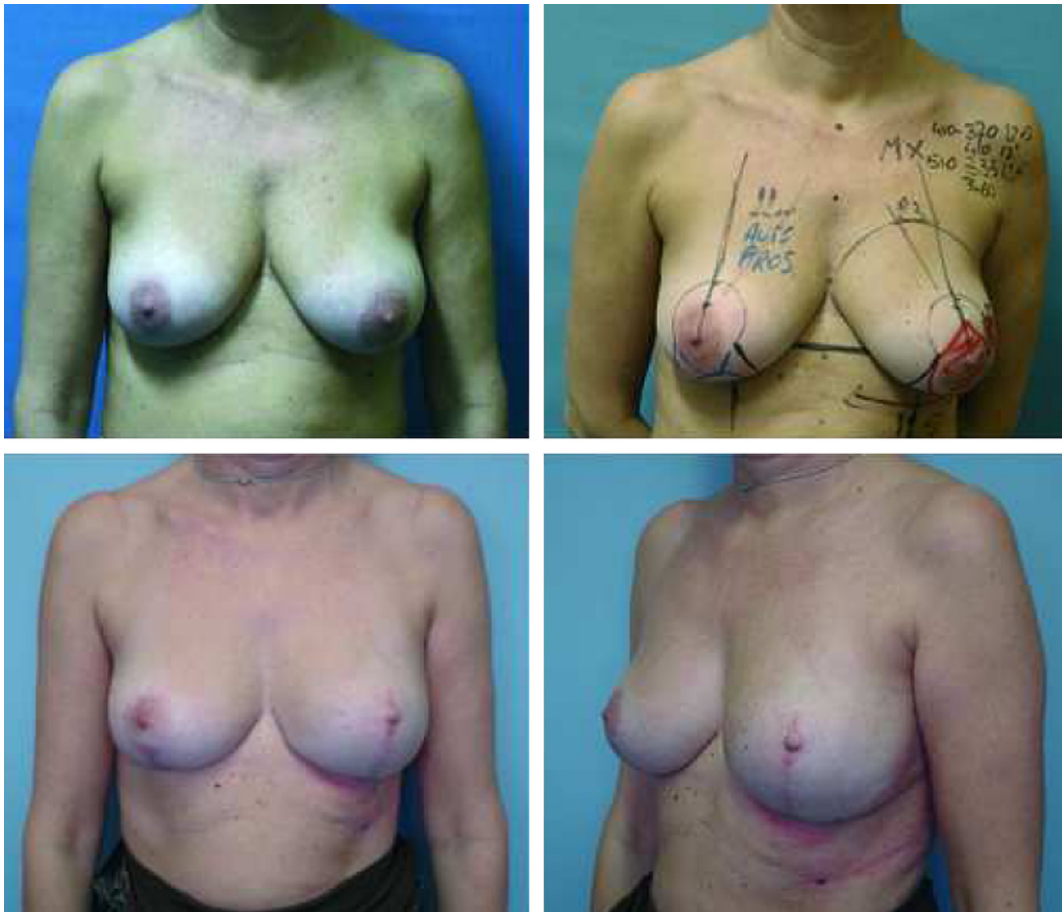

Fig. 3. Immediate one-stage breast reconstruction (skin reducing mastectomy). Large and ptotic breast needs to be reduced and lifted (above left). A reduction mastectomy with autoprosthesis modified technique is planned contra-laterally (above right). Below: After mastectomy and extra-projection implant insertion on the left side and reduction mastectomy on the right side.

a Grade III capsular contracture; no Grade IV contractures were observed. In the Clough et al.²¹ and Cordeiro et al.^{19,20} studies of reconstruction patients, the rate of pathological (Grade III and IV) capsular contracture was 15.5%.

Implant replacement may be necessary in reconstructions, as well as in aesthetic procedures. We reported in this study a high implant replacement rate (7.7%); this can be due to our decision to pursue effective cosmetic appearance with short, multiple reconstructive procedures (implant replacement and total capsulectomy) rather than performing challenging and expensive autologous flaps.

As a result of this study “the medium size/implant based cosmetic model for breast reconstructions” allowed us to restrict indication for autologous flaps to patients who underwent or were scheduled to receive radiation therapy. For these women we currently prefer to avoid large myocutaneous flaps in favour of less invasive free deep inferior epigastric perforator (DIEP) flaps.

The disadvantage of implant-based procedures is that good results are not always long lasting. Positive results of this study need to be validated with much longer follow-up to assess capsular contracture and weight changes over the years. Oncological effects of increased surgical aggressiveness on the contra-lateral breast will be also assessed.

Conclusion

The extra-projected breast reconstruction strategy has been tested in this study.

Modern breast reconstruction techniques should be used to rebuild cosmetic appearance rather than strive to obtain complex symmetries with a contra-lateral ptotic breast. Extra-projection devices, possibly coupled with contra-lateral adjustment, extend the indication of implant-based reconstructions virtually to all women irrespective of breast size and shape. Following these improvements, the future will probably reserve a narrow role for autologous flaps, especially in the field of radio-treated patients. Further refinements are awaited from new regenerative tissue technologies with the purpose of reducing capsular contracture rates and to increase prosthesis compatibility with radiation treatments.²² Much longer follow-up is awaited to confirm the positive results that we have reported.

Conflict of interest statement

None declared.

Acknowledgements

We would like to acknowledge Mrs Luisa Morandi and Marcantonio Caltabiano, Ph.D., for data collection and statistical analysis.

References

1. Wickman M, Johansson O, Olenius M, Forslind B. A comparison of the capsules around smooth and textured silicone prostheses used for breast

reconstruction. A light and electron microscopic study. *Scand J Plast Reconstr Surg Hand Surg* 1993;**27**:15–22.

2. Delgado JM, Martinez-Mendez JR, de Santiago J, Hernandez-Cortes G, Casado C. Immediate breast reconstruction (IBR) with direct, anatomic, extra-projection prostheses: 102 cases. *Ann Plast Surg* 2007;**58**:99–104.
3. Nava M, Quattrone P, Riggio E. Focus on the breast fascial system: A new approach for inframammary fold reconstruction. *Plast Reconstr Surg* 1998;**102**:1034–45.
4. Nava MB, Cortinovis U, Querci della Rovere G, et al. Skin-reducing mastectomy. *Plast Reconstr Surg* 2006;**118**:603–10.
5. Carlson GW, Bostwick 3rd J, Styblo TM, et al. Skin-sparing mastectomy. Oncologic and reconstructive considerations. *Ann Surg* 1997;**225**:570–5.
6. Losken A, Carlson GW, Bostwick 3rd J, Jones GE, Culbertson JH, Schoemann M Trends in unilateral breast reconstruction and management of the contralateral breast: The Emory experience. *Plast Reconstr Surg* 2002;**110**:89–97.
7. Martino G, Godard H, Nava M, Benson J. Breast reconstruction with myocutaneous flaps: Biomechanical aspects. In: della Rovere GQ, Benson JR, Breach N, Nava M, editors. *Oncoplastic and reconstructive surgery of the breast*. London: Taylor & Francis; 2004. p. 141–9.
8. Petit JY, Rietjens M, Contesso G, Bertin G, Gilles R. Contralateral mastoplasty for breast reconstruction: A good opportunity for glandular exploration and occult carcinomas diagnosis. *Ann Surg Oncol* 1997;**4**:511–5.
9. Petit JY, Rietjens M, Garusi C, et al. Abdominal complications and sequelae after breast reconstruction with pedicled TRAM flap: is there still an indication for pedicled TRAM in the year 2003? *Plast Reconstr Surg* 2003;**112**:1063–5.
10. Spear SL, Hess CL. A review of the biomechanical and functional changes in the shoulder following transfer of the latissimus dorsi muscles. *Plast Reconstr Surg* 2005;**115**:2070–3.
11. Ribeiro L, Accorsi A, Marca-Pessoa M. Creation and evolution of 30 years of the inferior pedicle in reduction mammoplasties. *Plast Reconstr Surg* 2002;**110**:960–70.
12. Broet P, de la Rochefordiere A, Scholl SM, et al. Contralateral breast cancer: annual incidence and risk parameters. *J Clin Oncol* 1995;**13**:1578–83.
13. Handel N, Silverstein MJ. Breast cancer diagnosis and prognosis in augmented women. *Plast Reconstr Surg* 2006;**118**(3):587–93. discussion 594–6.
14. Herborn CU, Marincek B, Ermann D, et al. Breast augmentation and reconstructive surgery: MR imaging of implant rupture and malignancy. *Eur Radiol* 2002;**12**:2198–206.
15. Preda L, Villa G, Rizzo S, et al. Magnetic resonance mammography in the evaluation of recurrence at the prior lumpectomy site after conservative surgery and radiotherapy. *Breast Cancer Res* 2006;**8**:R53.
16. Nava M, Bonavita M, Arioli N, et al. In: della Rovere GQ, Benson JR, Breach N, Nava M, editors. *Oncoplastic and reconstructive surgery of the breast*. London: Taylor & Francis; 2004. p. 204.
17. Ramon Y, Ullmann Y, Moscona R, et al. Aesthetic results and patient satisfaction with immediate breast reconstruction using tissue expansion: A follow-up study. *Plast Reconstr Surg* 1997;**99**:686–91.
18. Castello JR, Garro L, Najera A, Mirelis E, Sanchez-Olaso A, Barros J. Immediate breast reconstruction in two stages using anatomical tissue expansion. *Scand J Plast Reconstr Surg Hand Surg* 2000;**34**:167–71.
19. Cordeiro PG, McCarthy CM. A single surgeon’s 12-year experience with tissue expander/implant breast reconstruction: Part II. An analysis of long-term complications, aesthetic outcomes, and patient satisfaction. *Plast Reconstr Surg* 2006;**118**:832–9.
20. Cordeiro PG, McCarthy CM. A single surgeon’s 12-year experience with tissue expander/implant breast reconstruction: Part I. *A prospective analysis of early complications* *Plast Reconstr Surg* 2006;**118**:825–31.
21. Clough KB, O’Donoghue JM, Fitoussi AD, Nos C, Falcou MC. Prospective evaluation of late cosmetic results following breast reconstruction: I. Implant reconstruction. *Plast Reconstr Surg* 2001;**107**:1702–9.
22. Rigotti G, Marchi A, Galie M, et al. Clinical treatment of radiotherapy tissue damage by lipoaspirate transplant: a healing process mediated by adipose-derived adult stem cells. *Plast Reconstr Surg* 2007;**119**(5):1409–22. discussion 1423–4.