

Results Of 1864 participants, 115 (6.17%) had endometrial (n=99) or other pelvic malignancies (cervix-7, ovary-3, leiomyosarcoma-2, bladder-1, colorectal-2, metastatic pancreatic-1). The sensitivity and specificity of urogenital cytology for endometrial or any pelvic cancer detection were 80.8% (95% CI:71.7–88.0%) and 92.6% (95% CI:91.2–93.8%), and 80.0% (95% CI:71.5–86.9%) and 92.6% (95% CI:91.2–93.8%), respectively. The negative predictive value was 98.8% (95% CI:98.2–99.3%) for endometrial cancer detection and 98.6% (95% CI:97.9–99.1%) for any pelvic cancer detection. Of the 19 endometrial cancers missed by urogenital cytology, 2 (10.5%) had high-grade histology and 1 (5.3%) was \geq stage-II, meaning that cytology detected 95.8% of aggressive histology and 96.4% of locally advanced/metastatic cases. Seventeen of the missed cases (84.2%) were identified following unblinded cytology review of the sample, suggesting that natural tumour shed is ubiquitous in symptomatic endometrial cancer patients but current technology limits its clinical application.

Conclusion This novel endometrial cancer detection tool holds great promise. Artificial intelligence solutions to screen cytology slides for rare malignant cells may improve its diagnostic accuracy.

2022-RA-610-ESGO

RADIOMICS AND TRANSVAGINAL ULTRASOUND IN ADNEXAL MASSES: IS THE NEXT FUTURE OF DIAGNOSTICS HERE?

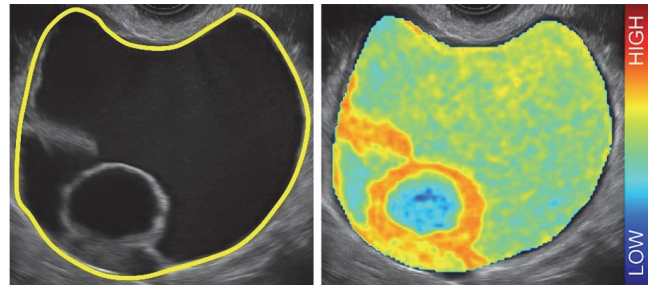
¹Valentina Chiappa, ²Matteo Interlenghi, ²Christian Salvatore, ³Robert Fruscio, ⁴Simone Ferrero, ⁵Federica Rosati, ⁶Lucia de Meis, ⁷Martino Rolla, ¹Umberto Leone Roberti Maggiore, ⁸Silvia Ficarelli, ¹Chiara Coco, ¹Ludovica Spanò Bascio, ²Isabella Castiglioni, ¹Francesco Raspagliesi. ¹Fondazione IRCCS Istituto Nazionale dei Tumori, Milano, Italy; ²DeepTrace Technologies S.R.L., Milan, Italy; ³Università degli Studi Milano-Bicocca, Monza, Italy; ⁴Irccs Ospedale Policlinico San Martino, Genova, Italy; ⁵Ospedale Infermi di Rimini, Rimini, Italy; ⁶IRCCS Policlinico di Sant'Orsola, Bologna, Italy; ⁷Ospedale Maggiore di Parma, Parma, Italy; ⁸Spedali Civili di Brescia, Brescia, Italy

10.1136/ijgc-2022-ESGO.154

Introduction/Background Multicenter prospective clinical validation of the radiomic machine learning model (TRACE4OC) applied to transvaginal ultrasound (US) in predicting the risk of malignancy of adnexal masses.

Methodology From a multicenter prospective consecutive series of women scheduled for surgery of adnexal masses, we collected and evaluated, fully blinded, 230 preoperative US images of adnexal masses with the TRACE4OC radiomic model previously developed according to the International Biomarker Standardization Initiative guidelines, trained and externally validated on a retrospective study of 274 US images of adnexal masses using histopathology as reference standard. Figure 1 shows the distribution of a radiomic texture feature (entropy of the co-occurrence matrix of gray levels) in an ovarian cystic malignant mass (a mucinous borderline tumor).

Results TRACE4OC model showed 91.3% accuracy, 99.0% sensitivity, 86.4% specificity when tested on the prospective multicentric external datasets of 230 masses (resulting into 90 malignant and 140 benign lesions at final histology), achieving 82.4% positive predictive value (PPV). The model shows a high correlation with final histology (Pearson r: 0.8425 (95% CI: 0.800–0.876); $p < 0.001$). The discrepancy was 0.473 ((SD: 0.50) 95%CI: 0.408, 0.538).



Abstract 2022-RA-610-ESGO Figure 1

Conclusion The radiomic machine learning model can support clinicians in the diagnostic process of benignancy versus malignancy for adnexal masses, providing a strong reduction of the definite surgery rate for benign lesions still warranting very high sensitivity.

2022-RA-614-ESGO

THE ROLE OF ULTRASOUND GUIDED BIOPSY IN WOMEN WITH PELVIC MASS SUSPECTED OF GYNECOLOGIC MALIGNANCY

Tufan Oge, Mehmet Copuroglu, Omer Tarik Yalcin. *Obstetrics and Gynecology, Eskisehir Osmangazi University, Eskisehir, Turkey*

10.1136/ijgc-2022-ESGO.155

Introduction/Background Ultrasound-guided biopsy is a reliable and effective technique for obtaining tissue samples. It is commonly used for different types of tumors, such as breast and prostate cancers to accelerate the treatment process. Our aim is to evaluate the indications, adequacy, and safety of transvaginal ultrasound-guided biopsy in women with pelvic lesions suspected of gynecologic malignancy.

Methodology We reviewed the medical records of 90 patients who had undergone transvaginal or transabdominal ultrasound-guided biopsy at the division of gynecologic oncology between 2012–2022. Patients who have suspected ovarian malignancy but are not suitable for optimal debulking surgery, or the origin and/or nature of the tumor was unclear and further management required histological verification.

Results Two patients gave up the treatment process and 88 women were analyzed. Of the patients, 55 and 33 underwent transabdominal and transvaginal biopsy respectively. Biopsy material was found to be sufficient in 85 of 88 cases. Histopathological examinations revealed primary ovarian tumor in 58 (68%) cases. Tuberculosis was found to be the second most common disease (n=12, 14%). Metastatic tumors and tuba ovarian abscess was found to be in 10 (12%) and 5 (6%) patients respectively. No major complications occurred.

Conclusion Ultrasound-guided biopsy via abdomen and/or vagina is a minimally invasive method to obtain adequate material for histological diagnosis and management of adnexal mass and could avoid unnecessary surgical procedures in selected patients.