

Respiratory epithelial adenomatoid hamartoma: Minimally invasive surgery of an endoscopic and radiological finding in maxillary sinus mimicking an inverted papilloma

S. Pavaci^{a,*}, F. Tortorella^a, A. Vecchione^b, L. Di Rienzo Businco^a

^a Minimally Invasive Otorhinolaryngological Surgery Unit, Institute of Medicine and Science, CONI SportLab, Rome, Italy

^b Pathology Unit, Department of Clinical and Molecular Medicine, Sant'Andrea Hospital, Sapienza University, Rome, Italy

ARTICLE INFO

Keywords:

Nasal polyps
Maxillary sinus
Hamartoma
Sinusal tract
Respiratory epithelial adenomatoid hamartoma (REAH)

ABSTRACT

Introduction: Respiratory epithelial adenomatoid hamartoma (REAH) is a benign entity characterized by an abnormal proliferation of glandular tissue surrounded by a thick eosinophilic basement membrane within ciliated respiratory epithelium with no evidence of atypical or metaplastic changes in the squamous cells.

Case report: An 84 years patient, non-smoker, with in treatment hypertension and depression reported a 3-month history of progressive right nasal obstruction, mucopurulent rhinorrhea, unilateral purulent post-nasal discharge and unilateral anosmia. Endoscopy showed a polypoidal masse, with no presence of nasal polyposis. The lesion, originating from the maxillary sinus, arose from middle meatus and extended inferiority up to the inferior turbinate. During an endoscopic minimally-invasive surgical procedure, we performed the complete excision of the whole lesion, through the use of micro-instruments and debrider technology. The patient underwent regular check-up after 3, 6 and 12 months: endoscopic and radiological evaluation showed no relapse of the disease.

Conclusion: Although REAH is a neoplastic pathology, the intrinsic characteristics of benignity and the typical limited and non-infiltrating diffusion allow a minimally invasive and conservative surgical approach without evidence of recurrence.

Introduction

The term “hamartoma” was introduced by Albrecht in 1904 to distinguish between true neoplasms and tumor-like lesions. Hamartoma is a mass of disorganized but mature specialized cells or tissue indigenous to the particular site. They are usually asymptomatic but can present as well-circumscribed masses that do not possess specific diagnostic histologic features, and diagnosis is, therefore, difficult. In contrast to many other benign or malignant lesions, the diagnosis of hamartoma can easily be missed [1]. This term is now used to designate a focal overgrowth of mature normal cells and tissues at sites of identical cellular composition. Although hamartomas have been described as occurring throughout the body, they are rare in the upper aerodigestive tract [2]. Respiratory epithelial adenomatoid hamartoma (REAH) was first described in 1995 by Wenig and Heffner in a series of 31 cases. REAH is a benign entity characterized by an abnormal proliferation of glandular tissue surrounded by a thick eosinophilic basement membrane within ciliated respiratory epithelium with no evidence of atypical or

metaplastic changes in the squamous cells. Diagnostic misinterpretations may result in untoward surgical intervention. Limited but complete surgical resection is the treatment of choice, following which there are no instances of recurrent disease [3].

In this case report, we described a rare upper-airway localization of REAH in the right maxillary sinus as a possible cause of monolateral nasal obstruction in a patient with chronic rhinosinusitis, otherwise asymptomatic.

Case report

A gentleman of 84 years, coming to our observation with a 3-month history of progressive right nasal obstruction. The patient was a non-smoker and had a history of hypertension and depression, treated with the regular medications. The ENT visit the patient reported the following symptoms: right nasal obstruction, mucopurulent rhinorrhea, unilateral purulent post nasal discharge, unilateral anosmia. He denied epistaxis. In the right nasal cavity, anterior rhinoscopy and endoscopy

* Corresponding author.

E-mail address: silpavaci@yahoo.it (S. Pavaci).

showed a polypoidal masse without the presence of nasal polyposis, arising from middle meatus, extending inferiority up to the inferior turbinate, which also appeared hypertrophic. The visible part to the mass was firm with a smooth and non-tender surface and did not bleed on touch on probe test.

The lesion had already been identified in a recent magnetic resonance imaging (MRI), performed by the patient in order to check up an aneurysmal dilatation of the anterior communicating artery. The mass had a cerebriform appearance in the right maxillary sinus, completely occupied by a share of solid tissue, which juts out at the level of the right nasal choana (Fig. 1 a, b, c, d). Moving posteriorly towards the nasopharynx after gadolinium administration, this tissue appeared to be characterized by a widespread enhancement and therefore it needed ENT assessment. During our evaluation and observing the localization of the lesion, the first suspicion was that of inverted papilloma. Inverted papilloma are locally aggressive and may cause thinning and bowing of bone. CT and MRI often shows focal underlying osseous sclerosis at the origin of the inverted papilloma. Therefore, although inverted papilloma are lobular masses that grow centrifugally, they have distinguishing bony features from REAH. In fact, in our case we observed a remodeling at the level of the maxillary ostium with extension of the mass in correspondence with the nasal cavity but no bone erosion.

Management

We planned to perform an endoscopic minimally-invasive surgical procedure (FESS-functional endoscopic sinus surgery), to treat both the lesion and the chronic rhinosinusitis. The use of micro-instruments (Storz, Tuttlingen, Germany) and debriider technology (Medtronic, Jacksonville, USA) with straight and angled blades allowed us the

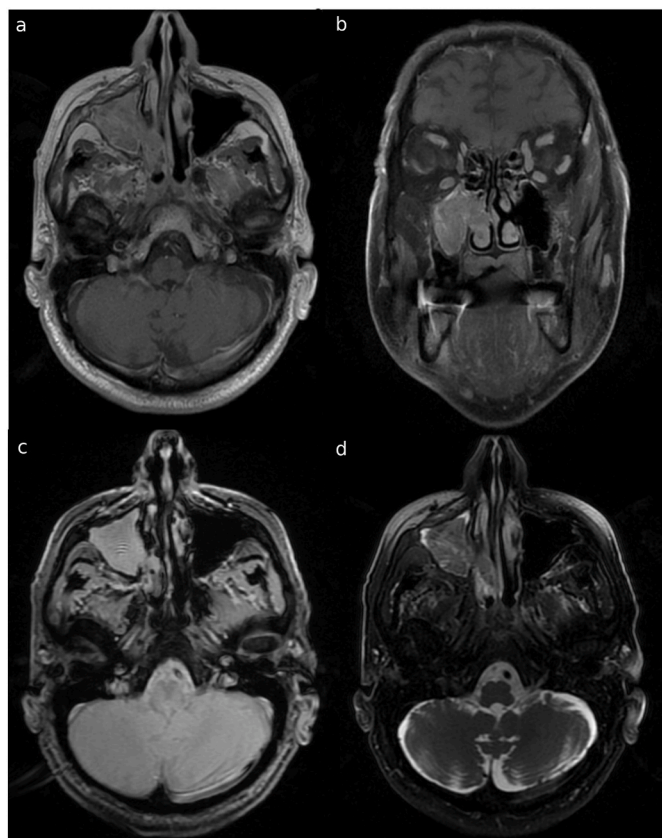


Fig. 1. MRI of maxillary sinus showing the presence of a pathological soft tissue extending into the right nasal choana with no intra-cranial extension, showing intermediate signal intensity on T1 sequence (a: axial, b:coronal, c: axial, d: axial).

complete excision of the whole lesion and the reduction of middle and inferior turbinate hypertrophy with quantic molecular resonance wand (Telea, Sandrigo, Italy). The performed surgery did not present any complications. The patient returned to the control visit after 3, 6 and 12 months and he presented a stable restored nasal airflow with no signs of rhinosinusitis; moreover the endoscopic (Fig. 2 a, b) and radiological evaluation showed no relapse of the disease.

Pathology

Histological examination revealed that the lesion was composed of well-formed, branching glands of various sizes covered with pseudo-stratified ciliated respiratory epithelial cells separated by stromal tissue. The surface of the lesion, lined with ciliated respiratory epithelium in a direct continuity with some of the glands, created a tubular appearance with elongated invaginations into the underlying loose myxoid lamina propria (Fig. 3 a). Cystic glands containing eosinophilic material were found. A characteristic finding was stromal hyalinization with a thick eosinophilic basement membrane covering the glands (Fig. 3 b). Other abnormal features included stromal edema, seromucinous glands proliferation, increased vascularity and a mixed acute and chronic inflammatory infiltrate.

The differential diagnosis of REAH in para-nasal sinus includes inverted papilloma, and adenocarcinoma. The inverted papilloma is composed of papillary fronds with a delicate fibrovascular core covered by multiple layers of epithelial cells, most often of squamous or transitional cells, in contrast to the REAH, which shows adenomatoid structures lined by a single layer of ciliated columnar epithelium. Sino-nasal low-grade adenocarcinoma may produce an architectural pattern mimicking that seen in REAH. However, adenocarcinoma can be distinguished from REAH by the presence of numerous uniform small glands or acini arranged in a back-to-back pattern, cellular pleomorphism, atypical mitoses, keratin pearls, loss of basement membranes and stromal invasion associated with an inflammatory-desmoplastic response [4].

Discussion

Over 80% of the patients with REAH are males, age ranging from the third to the ninth decade of life, with a median age in the 6th decade [3, 5]. In our patient, there was no relationship to any specific aetiological agent and no correlation with tobacco or alcohol abuse. Presenting symptoms were vague and non-specific, often including nasal respiratory obstruction, nasal stuffiness, epistaxis, rhinorrhea and allergy-like symptoms.

In contrast to other neoplasms, hamartomas do not have the capability of a continuous unimpeded growth [3]. They are, therefore, self-limiting and, in general, they have no malignant potential and no tendency to regress spontaneously. Differential diagnosis is based on the fact that inverted papilloma, encephaloceles, carcinomas, and esthesioneuroblastomas are generally associated with skull-base defects or erosion, differentiating them from REAH that is rather characterized by bony expansion [6].

The definitive treatment for REAH is a simple surgical excision while the other diagnoses require more complex surgical excision. Another favorable characteristic of REAH is that complete excision is curative, leading to an excellent prognosis. Some cases have been followed for as many as 5 years post excision without evidence of recurrence [7].

REAHs are uncommon in the head and neck, but the majority of the cases that develop in this region are located in the posterior nasal septum. The isolate involvement of the maxillary sinus is quite rare with only two other cases reported. In one of these, the lesion was discovered during the course of a dental X-ray, as a periapical radiolucency mimicking a dental granuloma and apical periodontal cyst with no evidence of the typical sinus symptoms being apparent [8]. In the other case report in literature, only non specific symptoms were present, like

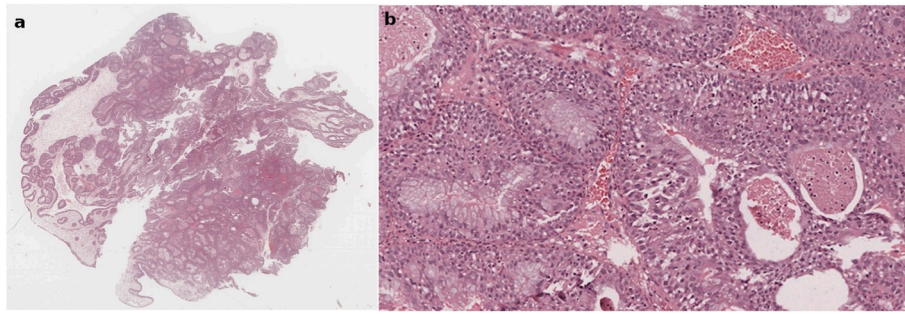


Fig. 2. Nasal endoscopy, a: appearance and extension of the lesion in the nasal cavity; b: appearance and extension of the lesion after minimally invasive treatment.

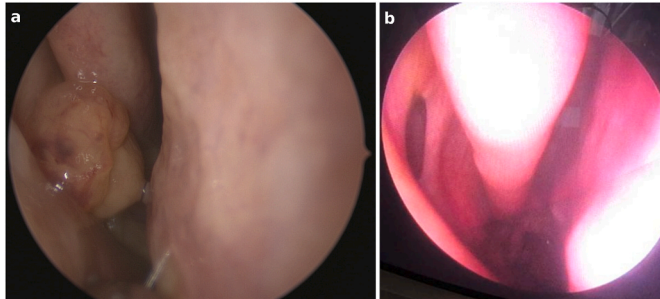


Fig. 3. a: lesion, lined with ciliated respiratory epithelium in a direct continuity with some of the glands, creates a tubular appearance with elongated invaginations; b: presence of stromal hyalinization with a thick eosinophilic basement membrane covering the glands.

unilateral nasal obstruction, rhinorrhea and headache [9].

The most common identified site of occurrence is the nasal cavity, specifically the posterior septum, with no right or left side predilection and often involves both nasal cavities. Nasopharynx and lateral nasal wall are also common site of occurrence of REAH, indeed in cranial part of the nasal cavity significantly enlarges the width of the olfactory cleft, and in patients with bilateral disease, this difference is important in the differential diagnosis with nasal polyposis [10].

Conclusions

Even if a preliminary observation of REAHs could suggest for a simple nasal monolateral flogistic polyposis, a more careful rhinosinusal endoscopy reveals a slight dishomogeneity of tissue consistency and color, when compared with a benign inflammatory polyp. On the other side, the knowledge of these lesions as a potential diagnosis before surgical excision may help to prevent an overly aggressive surgical procedure with greater risk for complications, such as CSF leak and anosmia [6]. In fact, although REAH is a neoplastic pathology, the intrinsic characteristics of benignity and the limited and non-infiltrating

diffusion typical of these masses, however, allow a minimally invasive and conservative surgical approach, already applied in the treatment of polypoid rhinosinusitis.

Ethical statement

The patient's consent was signed, both intraoperative and endoscopic photos that the patient gave his consent to. We respected the patient's privacy.

Declaration of competing interest

The authors declare that they have no known competing financial interests or personal relationships that could have appeared to influence the work reported in this paper.

References

- [1] Albrecht E. Ueber hamartome. *Verh Dtsch Ges Pathol* 1904;7:153–7.
- [2] Sangoi AR, Berry G. Respiratory epithelial adenomatoid hamartoma: diagnostic pitfalls with emphasis on differential diagnosis. *Adv Anat Pathol* 2007;14:11–6.
- [3] Wenig BM, Heffner DK. Respiratory epithelial adenomatoid hamartomas of the sinonasal tract and nasopharynx: a clinicopathologic study of 31 cases. *Ann Otol Rhinol Laryngol* 1995;104:639–45.
- [4] Marin LG, Trombitas V, Albu S. A case of respiratory epithelial adenomatoid hamartoma. *Chirurgia (Bucur)* 2013 Nov-Dec;108(6):904–6.
- [5] Endo R, Matsuda H, Takahashi M, Hara M, Inaba H, Tsukuda M. Respiratory epithelial adenomatoid hamartoma in the nasal cavity. *Acta Otolaryngol* 2002;122:398–400.
- [6] Hawley KA, Ahmed M, Sindwani R. CT findings of sinonasal respiratory epithelial adenomatoid hamartoma: a closer look at the olfactory clefts. *AJNR Am J Neuroradiol* 2013 May;34(5):1086–90.
- [7] Fitzhugh VA, Mirani N. Respiratory epithelial adenomatoid hamartoma: a review. *Head Neck Pathol* 2008;2(3):203–8.
- [8] Kessler P, Unterman B. Respiratory epithelial adenomatoid hamartoma of the maxillary sinus presenting as a periapical radiolucency: a case report and review of the literature. *Oral Surg Oral Med Oral Pathol Oral Radiol Endod* 2004;97:607–12.
- [9] Himi Y, Yoshizaki T, Sato K, Furukawa M. Respiratory epithelial adenomatoid hamartoma of the maxillary sinus. *J Laryngol Otol* 2002;116:317–8.
- [10] Nguyen DT, Nguyen-Thi PL, Gauchotte G, Arous F, Vignaud JM, Jankowski R. Predictors of respiratory epithelial adenomatoid hamartomas of the olfactory clefts in patients with nasal polyposis. *Laryngoscope* 2014 Nov;124(11):2461–5.