

# Late diagnosis of pheochromocytoma in pregnancy with poor fetal outcome

Gauri Bapayeva<sup>1,2</sup>, Milan Terzic<sup>1,2,3</sup>, Karlygash Togyzbayeva<sup>1</sup>, Aigerim Bekenova<sup>2</sup>, Sanja Terzic<sup>2</sup>, Simone Garzon<sup>4</sup>, Giovanni Falzone<sup>5</sup>, Botagoz Aitbayeva<sup>1</sup>

## SUMMARY

*Pheochromocytomas are rare tumors producing catecholamines that could be a cause of secondary hypertension. On that basis, pheochromocytoma can occur as an extremely rare cause of hypertension in pregnancy and if diagnosed late can lead to adverse maternal-fetal outcome. In this case report we describe a case of pheochromocytoma affected pregnancy with poor fetal outcome. A 27-year-old pregnant woman was admitted for severe pre-eclampsia due to pre-gestational hypertension that was diagnosed during the first trimester. Due to high and uncontrolled maternal blood pressure and the worsened maternal-fetal condition after the admission induction of fetal lung maturity and emergency cesarean section were performed, but with poor fetal outcome. Later, an adrenal gland mass was identified using abdominal ultrasound and confirmed by computed tomography. After surgical adrenalectomy blood pressure of the patient was normalized. Pheochromocytoma should be considered as a possible cause of hypertensive disorder during pregnancy, particularly in cases of severe and unresponsive hypertension in order to provide for timely and appropriate treatment.*

**KEY WORDS:** Pheochromocytoma, Pregnancy, Hypertension, intrauterine growth restriction, Maternal-fetal outcome

## INTRODUCTION

Pheochromocytomas are rare tumors characterized by the production of catecholamines that could very rarely be a cause of secondary hypertension in the general population (1). Because pregnancy is characterized by significant body changes and can result in diverse obstetrics pathologies the diagnosis and treatment of non-obstetrics diseases that require specialized expertise can be challenging, especially in high-risk conditions (2–9). During pregnancy the diagnosis of pheochromocytoma or paraganglioma is extremely rare, occurring in 0.007% of all pregnancies (10) due to clinical presentation that can be similar to other severe but more frequent forms of hypertensive complications in pregnancy (11). Nevertheless, in case of delayed diagnosis a lethal outcome for both mother and fetus is possible (12–14). Indeed, according to recent reports, timely diagnosis and proper management can reduce maternal and fetal mortality and morbidity to less than 5% and 15%, respectively (15,16). Therefore, pheochromocytoma should be considered in cases of new onset of severe hypertension, particularly if it occurs before the 20th gestational week or if blood pressure is unstable and/or associated with headaches, palpitations and diaphoresis (17,18). Unfortunately, the proper diagnosis is often delayed, and the risk for antenatal and perinatal fetal mortality is high (12–14).

Based on the rarity of this condition, this article presents a case of pheochromocytoma diagnosed during the late pregnancy and resulting in poor fetal outcome. This case report was reported conforming to the Consensus-based Clinical Case Reporting (CARE) guidelines, available through Enhancing the Quality and Transparency of Health Research (EQUATOR) network. Patient signed informed consent to allow data collection in order to conduct research and publication of the case.

## CASE PRESENTATION

A 27-year-old woman in her first pregnancy (gravida 1, para 0) was referred to the clinic at the 27th week of gestation due to severe

hypertension and headache, with a diagnosis of severe pre-eclampsia due to pre-gestational hypertension.

The women had a negative history of disease or surgery before pregnancy. Nevertheless, at the first trimester control (at 8–9th gestational week) pre-gestational hypertension was diagnosed due to high blood pressure (140/90 mmHg). Therefore, a medical therapy with methyldopa and acetylsalicylic acid was started. With the ongoing of pregnancy, hypertension became severe and poorly controlled by therapy with blood pressure values up to 180/100 mmHg. Serial ultrasound evaluations of umbilical arteries and fetus showed the development of increased placental vascular resistance and intrauterine growth restriction (IUGR). Due to the severe symptomatic hypertension, the woman was hospitalized. The presence of protein in urine posed the diagnosis of severe pre-eclampsia due to pre-gestational hypertension. On admission, patient's blood pressure was 160/100 mmHg, and there were no signs of possible pre-term delivery. Detailed ultrasound scan showed critical utero-placental blood flow insufficiency, confirming severe IUGR and oligohydramnios. Due to the development of an unstable hemodynamic status despite the ongoing intensive antihypertensive therapy (methyldopa, metoprolol, and magnesium sulfate), the patient was transferred to intensive care unit. All blood analyses results were within normal range. Because maternal and fetal conditions showed no need for emergent pregnancy termination, corticosteroids were prescribed (two doses of 12 mg i.m., one every 24 h) for the induction of fetal lung maturity. The day after, umbilical arterial Doppler blood flow showed end-diastolic block with reverse flow, and patient's condition worsened with uncontrolled blood pressure (up to 200/140 mmHg) and vomiting. Therefore, an emergency cesarean section was performed to terminate the pregnancy. Unfortunately, fetus was extracted from uterine cavity without vital signs, and its resuscitation was unsuccessful.

Due to the persistence of high blood pressure detailed abdominal ultrasound scan of the patient revealed a mass in the left adrenal gland region. Computed tomography (CT) confirmed the lesion and posed the

Arch Oncol 2020

Published Online

March 6, 2020

<https://doi.org/10.2298/AOO191012002B>

<sup>1</sup> Department of Obstetrics and Gynecology, Mother and Child Health National Research Center, University Medical Center, Astana, Kazakhstan

<sup>2</sup> Department of Medicine, Nazarbayev University, School of Medicine, Astana, Kazakhstan

<sup>3</sup> Department of Obstetrics, Gynecology and Reproductive Sciences, University of Pittsburgh, School of Medicine, Pittsburgh, Pennsylvania, USA

<sup>4</sup> Department of Obstetrics and Gynecology, Filippo Del Ponte Hospital, University of Insubria, Varese, Italy

<sup>5</sup> Obstetrics and Gynecology Unit, Umberto I Hospital, Enna, Italy

**Correspondence to:**

Giovanni Falzone

E-mail: [gio.falzone@alice.it](mailto:gio.falzone@alice.it)

Received 2019-10-12

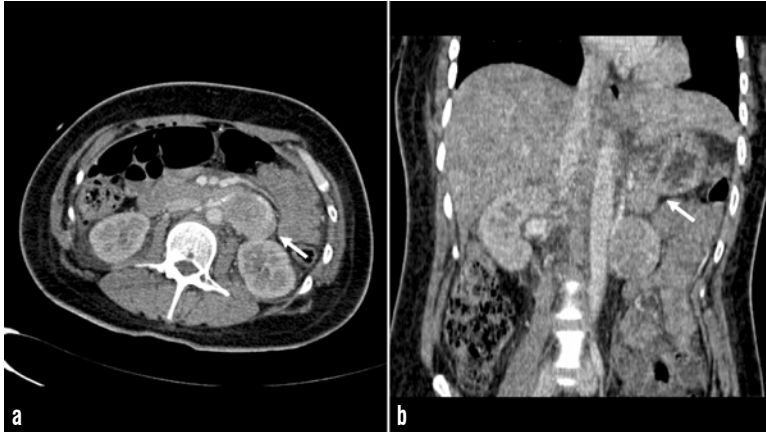
Received in revised form 2020-01-09

Accepted 2020-02-10



This work is licensed under a Creative Commons Attribution 4.0 license

suspicion on pheochromocytoma (Figure 1). Therefore, the woman was referred to the oncology unit where she underwent laparotomy surgery and the excision of the tumor. Histological examination confirmed the suspected diagnosis of pheochromocytoma. After surgery, patient recovered and her blood pressure was normalized.



**Figure 1.** Computed tomography performed without contrast enhancement in transversal (a) and coronal (b) section. A mass of 4.9 cm (maximum diameter) was identified in the left adrenal gland region (white arrows)

## DISCUSSION

During pregnancy differential diagnosis of numerous conditions represents a basis for appropriate patient management (19–21). Pheochromocytoma and paraganglioma are two neuroendocrine tumors of adrenal glands, derived from adrenal chromaffin cells and extra-adrenal paraganglioma that can be the cause of severe secondary hypertension during pregnancy (13,14,22). This clinical condition is life-threatening for both mother and fetus, particularly in case of late diagnosis (11). Indeed, in this case diagnosis was set too late resulting in in utero death due to the deleterious effects of catecholamines on the utero-placental circulation causing chronic intrauterine hypoxia and IUGR.

During pregnancy, the persistent and severe vasoconstriction due to the effect of catecholamines released by pheochromocytoma leads to alteration of placental blood flow with increased placental vascular resistance and IUGR of the fetus. Moreover, the acute high blood pressure crisis, can cause acute placental and maternal complications (12–14). Unfortunately, all these signs and symptoms are not unusual complications in pregnancy and can simulate a severe preeclampsia (11).

The management of pheochromocytoma is based on the surgical removal of the hormonally active mass (15). Therefore, the diagnosis and the identification of the lesion is mandatory to treat the disease. As reported in our case, abdominal ultrasound with the identification of adrenal mass is one of the first steps for the pheochromocytoma diagnosis. Ultrasound is usually followed by CT or magnetic resonance imaging (MRI) to confirm the lesion and plan the surgery (23). Nevertheless, identification of adrenal mass in pregnancy can be difficult by ultrasounds due to the enlargement of uterus and other first level evaluation diagnostic approaches should be considered like MRI or CT (12–14). The abnormal production of catecholamines can lead to increase of plasma and urinary catecholamine metabolites such as nor-metadrenaline (NMA) and metadrenaline (MA). The assessment of these metabolites in urines and plasma has been proposed as a biochemical screening with high sensitivity and specificity

for the pheochromocytoma that may represent a useful tool in pregnancy (14,24).

Moreover, because the surgical removal of the pheochromocytoma can be hard to perform in pregnant women the termination of pregnancy could be necessary (15). In cases where pheochromocytoma is diagnosed in the later weeks of gestation, elective cesarean section could be performed followed by adrenalectomy (16). Therefore, it is of paramount importance to make diagnosis of pheochromocytoma as early as possible (18), although minimally invasive approach to the retroperitoneum could allow to preserve pregnancy (23,25).

Moreover, early diagnosis is of paramount importance because administration of corticosteroids could have a detrimental effect on maternal-fetal condition. As highlighted by current guidelines related to pheochromocytoma and paraganglioma management the introduction of corticosteroids can trigger adverse reaction and precipitate a crisis (17), although patients receive this medication in order to achieve fetal lung maturation. The consequence of this can be the rise of patient's blood pressure, followed by alteration of placental blood flow and immediate demand for emergency cesarean delivery as it was showed in this case. Noteworthy, intraoperative management of hypertension is challenging for anesthesiologist, and administration of both  $\alpha$ - and  $\beta$ -blockers is required (23). Therefore, the first step is to set the diagnosis. Clinicians must consider the pheochromocytoma as a possible cause of severe hypertensive disorder during pregnancy, particularly in cases with extremely elevated blood pressure poorly controlled by antihypertensive drugs. In case of pheochromocytoma during pregnancy, clinicians should avoid use of corticosteroids to induce fetal lung maturity, since it may cause further exacerbation of patient's blood pressure levels. Adequate surgical management based on gestational age should be performed as soon as possible.

## Declaration of interests

Authors declare no conflicts of interest.

## REFERENCES

- 1 Prosperi Porta R, Lalle M, Calzolari E, et al. Fetal Pheochromocytoma in Pregnancy. Case Report. *Ital J Gynaecol Obstet* 1996;4:162–164.
- 2 Periti E, Cordisco A, Lozza V, et al. The impact of the combined test on the first trimester as a method of screening for trisomies 21,18, 13 and other chromosomal abnormalities. Experience of a single Italian fetal medicine unit on 12618 consecutive pregnancies. *Ital J Gynaecol Obstet* 2017;29:23–29.
- 3 Vitale SG, Padula F, Gulino FA. Management of uterine fibroids in pregnancy: recent trends. *Curr Opin Obstet Gynecol* 2015;27:432–437.
- 4 Cacciottola L, Solima E, Trojano G, et al. Management of adnexal masses during the third trimester of pregnancy: a case report in twin-pregnancy and review of the literature. *Ital J Gynaecol Obstet* 2016;28:36–40.
- 5 Chiofalo B, Laganà AS, Vaiarelli A, et al. Do miRNAs Play a Role in Fetal Growth Restriction? A Fresh Look to a Busy Corner. *BioMed Res Int* 2017;2017:6073167.
- 6 Laganà AS, Vitale SG, Sapia F, et al. miRNA expression for early diagnosis of preeclampsia onset: hope or hype? *J Matern Fetal Neonatal Med* 2018;31:817–821.
- 7 Lykke JA, Langhoff-Roos J, Sibai BM, et al. Hypertensive pregnancy disorders and subsequent cardiovascular morbidity and type 2 diabetes mellitus in the mother. *Hypertens Dallas Tex* 1979 2009;53:944–951.

- 8 Laganà AS, Giordano D, Loddo S, et al. Decreased Endothelial Progenitor Cells (EPCs) and increased Natural Killer (NK) cells in peripheral blood as possible early markers of preeclampsia: a case-control analysis. *Arch Gynecol Obstet* 2017;295:867–872.
- 9 Salman H, Shah M, Ali A, et al. Assessment of Relationship of Serum Neurokinin-B Level in the Pathophysiology of Pre-eclampsia: A Case–Control Study. *Adv Ther* 2018;35:1114–1121.
- 10 Biggar MA, Lennard TWJ. Systematic review of pheochromocytoma in pregnancy. *Br J Surg* 2013;100:182–190.
- 11 Kim HJ, Yang SH, Yang SH, et al. Extra-adrenal paraganglioma masquerading as severe preeclampsia. *Obstet Gynecol Sci* 2018;61:520–523.
- 12 Giampaolino P, Della Corte L, Formisano C, et al. Successful management of a third-trimester pregnancy complicated by pheochromocytoma: case report. *Gynecol Endocrinol Off J Int Soc Gynecol Endocrinol* 2018;34:1016–1018.
- 13 Wing LA, Conaglen J V, Meyer-Rochow GY, et al. Paraganglioma in Pregnancy: A Case Series and Review of the Literature. *J Clin Endocrinol Metab* 2015;100:3202–3209.
- 14 Lenders JWM, Duh Q-Y, Eisenhofer G, et al. Pheochromocytoma and paraganglioma: an endocrine society clinical practice guideline. *J Clin Endocrinol Metab* 2014;99:1915–1942.
- 15 Sarathi V, Lila AR, Bandgar TR, et al. Pheochromocytoma and pregnancy: a rare but dangerous combination. *Endocr Pract Off J Am Coll Endocrinol Am Assoc Clin Endocrinol* 2010;16:300–309.
- 16 Ghalandarpour-Attar SN, Ghalandarpour-Attar SM, Borna S, et al. A rare presentation of pheochromocytoma in pregnancy: a case report. *J Med Case Reports* 2018;12:37.
- 17 Langton K, Gruber M, Masjkur J, et al. Hypertensive crisis in pregnancy due to a metamorphosing pheochromocytoma with postdelivery Cushing's syndrome. *Gynecol Endocrinol Off J Int Soc Gynecol Endocrinol* 2018;34:20–24.
- 18 van der Weerd K, van Noord C, Loeve M, et al. Endocrinology in Pregnancy: Pheochromocytoma in pregnancy: case series and review of literature. *Eur J Endocrinol* 2017;177:R49–R58.
- 19 Vitale SG, Laganà AS, Muscatello MRA, et al. Psychopharmacotherapy in Pregnancy and Breastfeeding. *Obstet Gynecol Surv* 2016;71:721–733.
- 20 Breathnach FM, Malone FD, Lambert-Messerlian G, et al. First- and Second-Trimester Screening: detection of aneuploidies other than Down syndrome. *Obstet Gynecol* 2007;110:651–657.
- 21 Abuhamad A. Three-dimensional ultrasound with color Doppler imaging of an umbilical cord true knot. *Ultrasound Obstet Gynecol* 2014;43:360–360.
- 22 Björklund P, Backman S. Epigenetics of pheochromocytoma and paraganglioma. *Mol Cell Endocrinol* 2018;469:92–97.
- 23 Davison AS, Jones DM, Ruthven S, et al. Clinical evaluation and treatment of pheochromocytoma. *Ann Clin Biochem* 2018;55:34–48.
- 24 Pacak K, Eisenhofer G, Ahlman H, et al. Pheochromocytoma: recommendations for clinical practice from the First International Symposium. October 2005. *Nat Clin Pract Endocrinol Metab* 2007;3:92–102.
- 25 Garzon S, Raffaelli R, Montin U, et al. Primary hepatic pregnancy: report of a case treated with laparoscopic approach and review of the literature. *Fertil Steril* 2018;110:925–931.e1.