

An optical coherence tomography-based grading of diabetic maculopathy proposed by an international expert panel: The European School for Advanced Studies in Ophthalmology classification

European Journal of Ophthalmology
1–11

© The Author(s) 2019

Article reuse guidelines:

sagepub.com/journals-permissions

DOI: 10.1177/1120672119880394

journals.sagepub.com/home/ejo



Giacomo Panozzo¹, Maria Vittoria Cicinelli² , Albert J Augustin³,
Maurizio Battaglia Parodi² , José Cunha-Vaz⁴, Giuseppe Guarnaccia⁵,
Laurent Kodjikian⁶, Lee Merrill Jampol⁷, Anselm Jünemann⁸, Paolo Lanzetta⁹ ,
Anat Löwenstein¹⁰, Edoardo Midena¹¹, Rafael Navarro¹², Giuseppe Querques² ,
Federico Ricci¹³, Ursula Schmidt-Erfurth¹⁴, Rufino Martins da Silva¹⁵,
Sobha Sivaprasad¹⁶, Monica Varano¹⁷, Gianni Virgili¹⁸ and Francesco Bandello²

Abstract

Aims: To present an authoritative, universal, easy-to-use morphologic classification of diabetic maculopathy based on spectral domain optical coherence tomography.

Methods: The first draft of the project was developed based on previously published classifications and a literature search regarding the spectral domain optical coherence tomography quantitative and qualitative features of diabetic maculopathy. This draft was sent to an international panel of retina experts for a first revision. The panel met at the European School for Advanced Studies in Ophthalmology headquarters in Lugano, Switzerland, and elaborated the final document.

Results: Seven tomographic qualitative and quantitative features are taken into account and scored according to a grading protocol termed TCED-HFV, which includes foveal thickness (T), corresponding to either central subfoveal thickness or macular volume, intraretinal cysts (C), the ellipsoid zone (EZ) and/or external limiting membrane (ELM) status (E), presence of disorganization of the inner retinal layers (D), number of hyperreflective foci (H), subfoveal fluid (F), and vitreoretinal relationship (V). Four different stages of the disease, that is, early diabetic maculopathy, advanced diabetic maculopathy, severe diabetic maculopathy, and atrophic maculopathy, are based on the first four variables, namely the T, C, E, and D. The different stages reflect progressive severity of the disease.

¹Istituto Clinico Sant'Anna, Brescia, Italy

²Department of Ophthalmology, San Raffaele Scientific Institute, Vita-Salute San Raffaele University, Milan, Italy

³Department of Ophthalmology, Staetisches Klinikum Karlsruhe, Karlsruhe, Germany

⁴Association for Innovation and Biomedical Research on Light and Image (AIBILI), University of Coimbra, Coimbra, Portugal

⁵European School of Advanced Studies in Ophthalmology, Lugano, Switzerland

⁶Service d'Ophthalmologie, Hôpital de la Croix-Rousse, CHU de LYON, Hospices Civils de Lyon & Université de Lyon I, Lyon, France

⁷Department of Ophthalmology, Feinberg School of Medicine, Northwestern University, Chicago, IL, USA

⁸Department of Ophthalmology, Rostock University Medical Center, Rostock, Germany

⁹Istituto Europeo di Microchirurgia Oculare (IEMO), University of Udine, Udine, Italy

¹⁰Division of Ophthalmology, Tel Aviv Medical Center, Tel Aviv, Israel

¹¹Department of Ophthalmology, University of Padova, Padova, Italy

¹²Istituto de Microcirurgia Ocular, Barcelona, Spain

¹³UOSD Patologie Retiniche, Policlinico Tor Vergata, University Tor Vergata, Rome, Italy

¹⁴Vienna Clinical Trial Center (VTC), Department of Ophthalmology and Optometry, Medical University of Vienna, Vienna, Austria

¹⁵Department of Ophthalmology, Centro Hospitalar e Universitário de Coimbra (CHUC), Coimbra, Portugal

¹⁶NIHR Biomedical Research Centre, Moorfields Eye Hospital, London, UK

¹⁷IRCCS Fondazione G.B. Bietti per lo Studio e la Ricerca in Oftalmologia, Rome, Italy

¹⁸Azienda Ospedaliero-Universitaria Careggi, Florence, Italy

Corresponding author:

Giacomo Panozzo, Istituto Clinico Sant'Anna, Via del Franzone, 31, 25127 Brescia BS, Italy.

Email: g.panozzo@iol.it

Conclusion: A novel grading system of diabetic maculopathy is hereby proposed. The classification is aimed at providing a simple, direct, objective tool to classify diabetic maculopathy (irrespective to the treatment status) even for non-retinal experts and can be used for therapeutic and prognostic purposes, as well as for correct evaluation and reproducibility of clinical investigations.

Keywords

Classification, consensus, diabetic macular edema, diabetic maculopathy, optical coherence tomography, vitreomacular interface

Date received: 04 July 2019; accepted: 15 September 2019

Introduction

Diabetes, currently affects 415 million people worldwide, and the number is projected to increase to 750 million by 2030.¹ The prevalence of diabetic retinopathy and diabetic macular edema (DME) is expected to increase as well.² DME represents the main cause of visual impairment in diabetic patients, and approximately 50% of patients with DME lose two or more lines of visual acuity within 2 years if left untreated.³

At present, fluorescein angiography (FA) and spectral domain optical coherence tomography (SD-OCT) represent the techniques of choice for assessment and follow-up of diabetic maculopathy (DM).⁴ In particular, SD-OCT offers both quantitative and qualitative information in a non-invasive and repeatable way,^{5,6} and provides the central subfoveal thickness (CST), which has been widely used both in randomized clinical trials (RCTs) and in clinical practice.⁷ The state of the ellipsoid zone (EZ) and the external limiting membrane (ELM), the presence of hyperreflective intraretinal foci (HF),⁸ the features of the vitreoretinal interface,⁹ the presence of subfoveal fluid (SF),¹⁰ the size of intraretinal cysts,¹⁰ and the occurrence of disorganization of the inner retinal layers (DRIL), alone or in different combinations have been used to categorize DME.¹¹

Despite attempts to classify DME according to its location (center- vs non-center-involving),¹² extent (focal vs diffuse),¹³ or nature (vasogenic vs non-vasogenic),^{14,15} a morphologic categorization of the disease, including all its relevant features visible on SD-OCT is missing.

An international panel of experts elaborated and here proposes a SD-OCT-based classification, centered on standard figures, which considers specific morphologic features and quantitative indices of the entire spectrum of macular involvement in diabetic retinopathy, globally referred as DM.

Methods

A Pubmed-based research was carried out by the first author (G.P.) using the keywords “diabetic macular edema,” “diabetic maculopathy,” “classification,” and “optical coherence tomography.” All reports published in

English up to January 2019, including those available online prior to publication, were reviewed. The project was based on previously conducted studies and did not contain any direct involvement of human or animal participants; therefore, ethical approval was not necessary.

The first draft of this DM classification was elaborated and sent for review to an international panel of experts with recognized and long-standing experience in medical retina and SD-OCT technology. The document was modified according to the experts' comments and the panel was invited to participate to a consensus meeting, held at the European School of Advanced Studies in Ophthalmology (ESASO) headquarters in Lugano (Switzerland) on 30 March 2019, to discuss and finalize the definitive classification.

Method of acquisition

The classification was based on structural SD-OCT figures, meant to be used as references for the grading system.

All the SD-OCT were acquired using a high-resolution scan (length of 9 mm or more) with the modalities “raster scan” and/or “radial scan” centered to the foveola. The grade was judged from the scan crossing the foveola with the worse morphology or, in case of media opacities, with the best visibility of the retinal structures. In case of retinal signal “shadowing,” due to vitreous hemorrhages, hard exudates, or microaneurysms, the grade was judged from the scan crossing the foveola with the least shadowing.

Quantitative measurement

Normative retinal Early Treatment Diabetic Retinopathy Study (ETDRS) maps available in every SD-OCT machine were used as reference and provided quantitative measurement of the CST and the macular volume (MV) in the 500- μ m-radius ETDRS ring centered to the foveola.

The images shown at the consensus conference and reported in this article were obtained through the Spectralis® SD-OCT (Heidelberg Engineering, Vista, CA, USA), using the six-radial scans, centered at the fovea at equally spaced angular orientations. The in-built Spectralis® software automatically provided the CST and MV for each of the nine

subfields of the inner, intermediate, and outer rings (with a diameter of 1, 2.22, and 3.45 mm, respectively); normal range for the CST in the 1-mm-diameter ring was considered 225–315 μm .¹⁶ Conversely, the MV normal range in the 1-mm-diameter ring was considered 0.17–0.26 mm^3 .¹⁷

Qualitative parameters

Morphologic parameters on the SD-OCT scans were considered an integral, essential part of each stage; they included: (1) the size of the intraretinal cysts; (2) the visibility of ELM at the fovea; (3) the visibility of EZ at the fovea; (4) the presence of DRIL; (5) the presence of SF; (6) the presence and the number of HF; and (7) the vitreoretinal relationship.

Intraretinal cysts were defined as round, minimally reflective spaces within the neurosensory retina, located in the outer nuclear layer, inner nuclear layer, or ganglion cell layer. Cysts' size was graded using the figures as references, considering the dimension of the largest intraretinal cyst identifiable on the scan.

Absence of the EZ and/or the ELM was defined as a complete loss of foveal reflectivity at this level, identified as the first and the second hyperreflective bands of the four outermost layers on OCT, respectively. These layers were categorized as disrupted if they were not perfectly discernible, but still partially visible in the fovea; if EZ was nongradable (N/G) due to the presence of SF, ELM only was considered.

DRIL was defined as the loss of clear demarcation between the ganglion cell–inner plexiform layer complex, the inner nuclear layer, and the outer plexiform layer in the central fovea. SF was identified by subfoveal neurosensory hyporeflective detachment, due to fluid accumulation between the retina and the retinal pigment epithelium line; SF could be isolated or associated with any stage of DM. Patients were classified into two dichotomic groups according to the presence of DRIL and SF (yes/no). HFs were manually counted in each scan. Only HFs with the following morphologic characteristics were evaluated, in order to exclude hard exudates and microaneurysms from the analysis: (1) reflectivity similar to that of nerve fiber layer; (2) absence of back-shadowing; and (3) $<30\ \mu\text{m}$ diameter. All scans were divided into two groups (high HF/low HF) based on the average number of HF, using the arbitrary number of 30 as a cut-off value.

The vitreomacular relationship was classified according to a simplified version of the International Vitreomacular Traction Study Group classification.¹⁸ Complete posterior vitreous detachment (PVD) was defined as no residual vitreoretinal adhesion, demonstrated by a scan including the optic disk; if the optic disk was not visualized, the scan was labeled as absence of any visible adhesion or traction between vitreous cortex and retina, as complete PVD was not evident. In case of single or multiple points of residual

vitreoretinal adhesion, without influence on retinal profile (no traction), the scan was labeled as incomplete posterior vitreous detachment (IVD). Vitreomacular traction (VMT) was identified as residual macular vitreous attachment exerting antero-posterior traction, while epiretinal membrane (ERM) was defined as evidence of epiretinal tissue adhering to the macular surface, irrespective of the effect on the underlying retina.

Results

Preliminary definitions

DM included all the phenotypes of macular involvement in diabetic retinopathy irrespective to the presence of macular thickening. DME was identified by accumulation of intra and/or subretinal fluid in the macular area associated with retinal thickening on OCT.

The classification was designed for center-involving edema, that is, retinal thickening and/or intraretinal cysts and/or neurosensory retinal detachment involving the first ring of the ETDRS macular map. Furthermore, it was valid for both naïve and treated eyes, irrespective of the nature of the treatment. Prior focal or grid macular laser was also acceptable, as the status of the EZ/ELM was assessed only subfoveally (and laser spots were presumed not to be localized under the fovea).

SD-OCT grading system of diabetic maculopathy

Seven parameters were considered: foveal thickness (T), corresponding to either CST or MV, the size of intraretinal cysts (C), the EZ and/or ELM status (E), DRIL (D), hyperreflective foci (H), subfoveal fluid (F), and vitreoretinal relationship (V) (Table 1). The acronym can be easily memorized as “To Classify Edema Discerning Hidden Functional Variables.”

SD-OCT Staging of diabetic maculopathy

Four different stages of disease, that is, early DM (Figure 1), advanced DM (Figure 2), severe DM (Figure 3), and atrophic maculopathy (Figure 4), were discerned based on the first four variables (Table 2).

Each stage was additionally described according to the presence of the variables described in Table 3 (Figure 5).

Discussion

The recent innovations in OCT technology, with its high-resolution of retinal images, have contributed to advancements in our understanding of the pathophysiology of DM. As a result, there is a need to further classify the disease based upon not only the location of the retinal thickening,

Table 1. Spectral domain optical coherence tomography grading system of diabetic maculopathy.

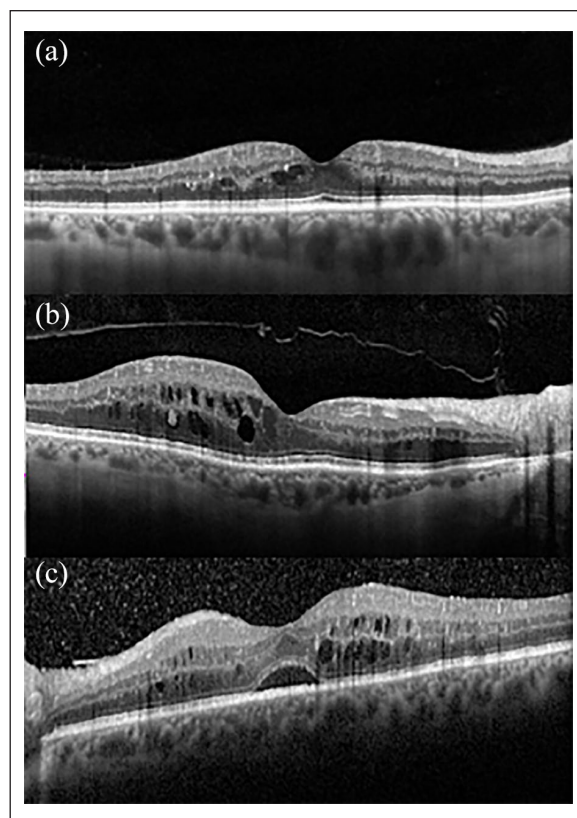
Thickening (T)	
0	Less than 10% increase above upper normal values
1	More than 10% but less than 30% increase above upper normal values
2	More than 30% increase above upper normal values
Cysts (C)	
0	Absent
1	Mild
2	Moderate
3	Severe
EZ and/or ELM status (E)	
0	Intact
1	Disrupted
2	Absent
DRIL (D)	
0	Absent
1	Present
Hyperreflective foci (H)	
0	Less than 30 in number
1	More than 30 in number
Subretinal fluid (F)	
0	Absent
1	Present
Vitreoretinal relationship (V)	
0	Absence of any visible adhesion or traction between vitreous cortex and retina
1	IVD
2	PVD
3	VMT
4	ERM

EZ: ellipsoid zone; ELM: external limiting membrane; DRIL: disorganization of the inner retinal layers; IVD: incomplete posterior vitreous detachment; PVD: posterior vitreous detachment; VMT: vitreomacular traction; ERM: epiretinal membrane.

as first proposed by the ETDRS,¹⁹ but also features associated with differing severities, response to treatment, and visual prognosis.

Several groups have proposed DM classifications,²⁰ often combining quantitative measurements and qualitative microstructural alterations of the outer retina, the inner retina, and the vitreoretinal interface (Table 4).

Quantitation of the CST, the central foveal thickness (CFT), the central retinal thickness (CRT) and the central macular thickness (CMT), have been used to evaluate disease activity, progression, and treatment response in RCTs as well as real-life.²⁹ However, evidence has shown only a weak correlation between these values and both baseline and final outcomes, especially at long-term follow-up.³⁰ A sub-analysis of the RIDE and RISE trials including patients

**Figure 1.** Early diabetic maculopathy.

(a) Small cystoid spaces involving the temporal side of the fovea. All retinal layers are visible and intact. The retinal profile is not altered; central subfoveal thickness and macular volume are within normal values. The TCED-HFV grading is T=1; C=1; E=0; D=0; H=0; F=0; V=0. (b) Multiple perifoveal cystoid spaces in the outer nuclear layer, the outer plexiform layer, and the inner nuclear layer, with mild thickening of the temporal side of the macula. Incomplete vitreous detachment with hyaloid still attached at the optic disk is discernible. Hyperreflective foci are more than 30 in number. The TCED-HFV grading is T=1; C=2; E=0; D=0; H=1; F=0; V=1. (c) Mild macular edema with preserved retinal profile, cystoid spaces in the outer plexiform layer and the inner nuclear layer. The ellipsoid zone is not gradable due to subfoveal fluid, but the external limiting membrane is normal; an initial epiretinal membrane is recognizable nasally to the fovea. Hyperreflective foci are more than 30 in number. The TCED-HFV grading is T=1; C=2; E=0; D=0; H=1; F=1; V=4.

with non-significant CFT modifications after anti-vascular endothelial growth factor (VEGF) therapy showed visual acuity gains and DR improvement similar to those who had immediate retinal thinning.³¹ Bressler and associates demonstrated that the proportion of patients with chronic persistent macular edema gaining at least 10 letters from baseline to 24 weeks was similar to patients with a dry macula, irrespective of the therapeutic agent administered.³² Patients with visual acuity of 20/40 or better who were enrolled in the bevacizumab arm of the Protocol T experienced the same amount of functional gain as the subjects treated with the other two anti-VEGF drugs, even though the retina remained thicker.³³

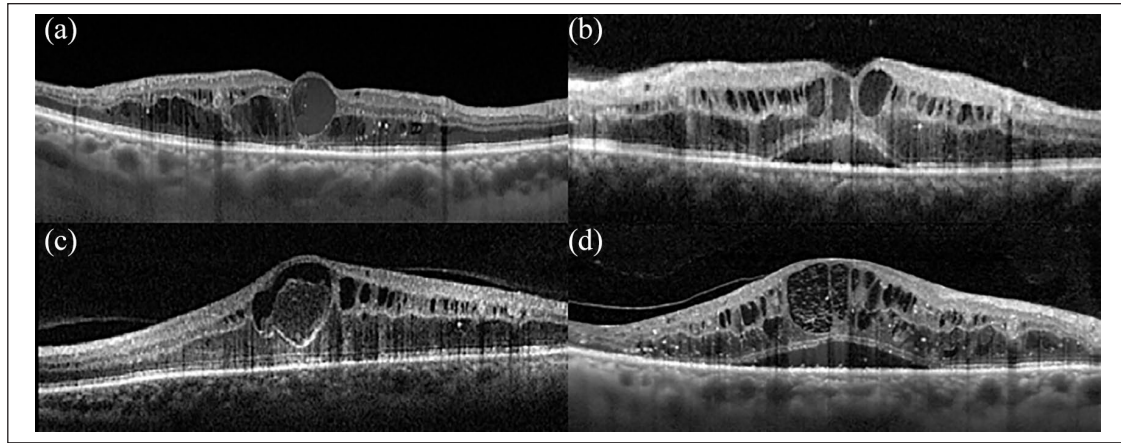


Figure 2. Advanced diabetic maculopathy.

(a) Cystoid spaces in the outer nuclear layer, the outer plexiform layer, and the inner nuclear layer, with thickening of the retina and central macrocyst. Diffuse hyperreflective foci and a subfoveal damaged ellipsoid zone. The vitreous cortex is not discernible. The TCED-HFV grading is T=2; C=3; E=1; D=0; H=1; F=0; V=0. (b) Intermediate cystoid spaces in the macula. The ellipsoid zone is not gradable but the external limiting membrane is disrupted subfoveally. The segmentation of the internal retinal layers is still visible. Absence of any visible adhesion or traction is discernible. The TCED-HFV grading is T=2; C=2; E=1; D=0; H=0; F=1; V=0. (c) A large pseudocyst in the fovea with cystoid spaces in the parafoveal area. The ellipsoid zone and the external limiting membrane are damaged subfoveally. The segmentation of the internal retinal layers is preserved, while partial vitreous detachment is visualizable. The TCED-HFV grading is T=2; C=3; E=1; D=1; H=0; F=0; V=1. (d) Large cystoid spaces in the outer nuclear layer, the outer plexiform layer, and the inner nuclear layer with a shallow subfoveal detachment. Diffuse hyperreflective foci, non-gradable ellipsoid zone, but discontinuous external limiting membrane. Inner retinal segmentation is visible. Vitreous is slightly elevated at the temporal side and still attached centrally (the *bursa premacularis* is recognizable). The TCED-HFV grading is T=2; C=3; E=1; D=0; H=1; F=1; V=1.

Additional information is available from the presence and the pattern of other qualitative features; in this study, the size of intraretinal cysts, the presence of DRIL, the number of HF, the occurrence of SF, and vitreoretinal alterations have been evaluated. The location and the size of intraretinal cysts have been correlated not only with the visual acuity at baseline,³⁴ but also with the anatomic response to treatment and improvement in macular function over the course of intravitreal anti-VEGF therapy.³⁵ There have been limited attempts to classify DME on the basis of the characteristics of intraretinal cysts. Koleva-Georgieva and Sivkova subdivided DME into mild, moderate, and severe according to the size of cystoid spaces,²⁵ while Panozzo et al. have first hypothesized that severe DME might correspond to chronic, late-stage exudative disease, and must be differentiated from advanced typical petaloid edema.²² Helmy and Atta Allah then confirmed that the size and the appearance of the cysts might have different origins.²⁶ Large coalescent macrocysts in severe, long-standing disease may characterize retinal cystoid degeneration (RCD), an end-stage phenotype described in chronic diseases including central serous chorioretinopathy,³⁶ age-related macular degeneration,³⁷ and idiopathic macular telangiectasia,³⁸ and has been histopathologically correlated with Müller cell dysfunction or necrosis.³⁹ It has been showed intraretinal cysts located in the inner nuclear layer (INL) to be more responsive to either anti-VEGF or corticosteroids than fluid accumulation in the outer nuclear layer (ONL).⁴⁰ Nevertheless, we intentionally did not introduce a further categorization based on the intraretinal

location of the cysts; our morphologic classification was aimed to be simple and directly accessible even for the non-retinal expert. We deemed that more detailed subgrouping of retinal morphology might add complexity to the overall categorizing structure.

Since the introduction of SD-OCT, it is possible to assess the integrity of the outer retinal layers, visualized as the four outermost hyperreflective bands on structural B-scan, as well of the inner retinal layers. The extent of damage of the EZ, corresponding to the photoreceptor ellipsoid, and the ELM layer, corresponding to the *adherens* junctions between the Müller cells and photoreceptor pedicles, has been correlated with the functional outcome in previous studies.⁴¹ Maheshwary et al. had previously demonstrated a strong relationship between visual acuity and foveal photoreceptor layer damage (intended as the percent disruption of the EZ line on SD-OCT) in eyes with DM, regardless the nature of previous treatments.⁴² Abnormalities in the EZ OCT reflectivity have been found in patients with non-proliferative DR on both transversal and *en face* slab reconstructions, suggesting this might be a hallmark of neuronal damage secondary to hyperglycemia.^{43,44} Interestingly, EZ layer interruption seems to correlate to early microvascular impairment at the level of both the retina and the choroid and choriocapillaris.^{44,45}

As the ELM status is also related to visual acuity, we considered the ELM status only in the presence of SF or ungradable EZ.⁴⁶ Similarly, the disorganization of the inner retinal structure on OCT, known as DRIL, with anatomical disruption of the visual pathway, has been

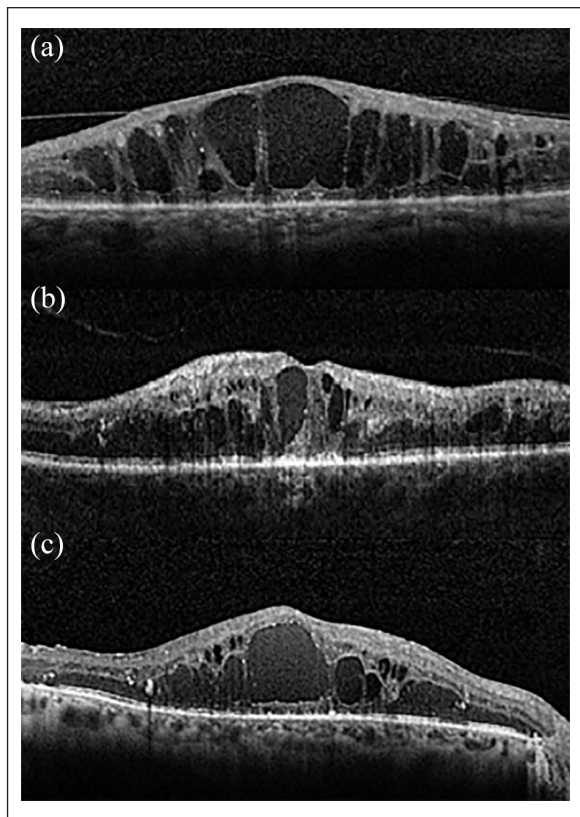


Figure 3. Severe diabetic maculopathy.

(a) Multiple central coalescent macrocysts in the outer nuclear layer, the outer plexiform layer, and the inner nuclear layer with disorganization of the inner retinal layers (DRIL). The external limiting membrane and the ellipsoid zone are absent under the fovea. Posterior hyaloid is visible and minimally detached. The TCED-HFV grading is T=2; C=3; E=2; D=1; H=0; F=0; V=1. (b) Central macrocyst surrounded by large cystoid spaces involving the outer nuclear layer, the outer plexiform layer, and the inner nuclear layer. Severe DRIL and a few hyperreflective foci. The external limiting membrane and the ellipsoid zone are absent under the fovea; incomplete vitreous detachment is present. The TCED-HFV grading is T=2; C=3; E=2; D=1; H=0; F=0; V=1. (c) Central macrocyst and multiple large cysts surrounded by a few hyperreflective foci. The external limiting membrane and the ellipsoid zone are not discernible subfoveally. Retinal inner layers are damaged but still visible (no DRIL), while vitreoretinal relationship is normal. The TCED-HFV grading is T=2; C=3; E=2; D=0; H=1; F=0; V=0.

correlated with macular ischemia and a worse visual outcome.^{47,48}

The presence of HF, also called hyperreflective spots or dots, is presumed to be a biomarker of local inflammation in different retinal diseases, including exudative age-related macular degeneration, angioid streaks, and vitreoretinal pathology. We considered only HF with $<30\ \mu\text{m}$ diameter, reflectivity similar to nerve fiber layer, and absence of back-shadowing; these characteristics should be more specific for clusters of activated intraretinal microglia rather than other hyperreflective focal intraretinal lesions, such as hard exudates or microaneurysms.⁴⁹ The clinical and therapeutic importance of HF is still controversial. Zur et al.⁴⁵ and Chatziralli et al.,⁵¹ independently, found that the presence of HF was inversely correlated with the final visual acuity in eyes treated with intravitreal steroids.^{45,46} Conversely, Hwang et al.⁵² reported that a larger number of HF were associated with a better outcome in eyes treated with dexamethasone. Further studies, assessing the accuracy and the repeatability of this classification in a therapeutic setting would clarify this point.

Accumulation of SF is thought to be either a sign of disruption of the external retinal-blood barrier, secondary to damage in the tight junctions of the retinal pigment epithelium (RPE) or insufficient fluid removal by an impaired RPE pump.⁵³ The presence of SF has been associated with reduced retinal sensitivity.⁵⁴ Its presence is predictive of better treatment response but poorer final vision after anti-VEGF injections.¹⁰

We propose a grading of DM in 4 different disease stages, which reflects progressive severity of the disease. Early DM was defined by the presence of small intraretinal cysts associated with well-recognizable and detectable inner retinal layers, EZ, and ELM, and increase in CST and/or MV less than 30% of maximum normal values. This stage of the disease often corresponds to good visual acuity and a shorter duration of hyperglycemic state. However, it might be a problem in patients undergoing cataract surgery. The effect of surgery on pre-existing DM is not clear. Several studies suggest that cataract surgery is

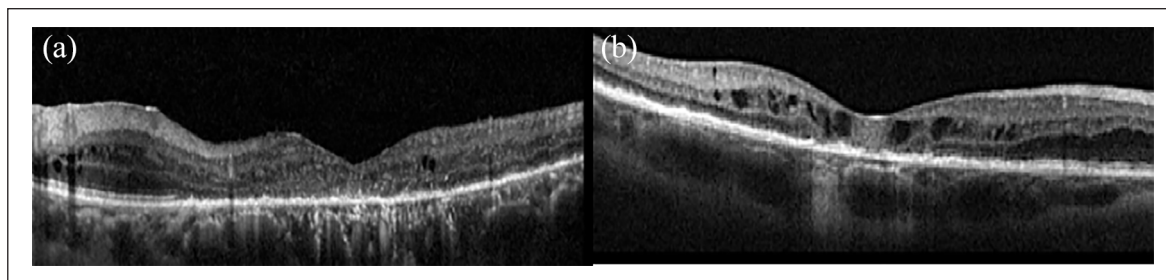


Figure 4. Atrophic diabetic maculopathy.

(a) Central retinal thinning with disorganization of the inner retinal layers (DRIL). The external limiting membrane and the ellipsoid zone are not discernible subfoveally, and the retinal pigment epithelium is atrophic. Thickness and volume are below normal values; some residual parafoveal microcysts and peripheral cystoid spaces are visible. The TCED-HFV grading is T=0; C=1; E=2; D=1; H=1; F=0; V=0. (b) Central retinal thinning with DRIL. The external limiting membrane and the ellipsoid zone are not distinguishable subfoveally, and the retinal pigment epithelium is irregular and focally atrophic. Thickness and volume are below normal values, but some intraretinal moderate cysts are present. The TCED-HFV grading is T=0; C=1; E=2; D=1; H=0; F=0; V=0.

Table 2. Staging of diabetic maculopathy (DM) according to the different combinations of the first four variables: thickening (T), cysts (C), EZ and ELM status (E), and DRIL (D).

Stage	T	C	E and/or D
Early DM (Figure 1)	T1	C1	E0 and D0
	T1	C2	E0 and D0
Advanced DM (Figure 2)	T1	C1	E1 and D0 or D1
	T1	C2	E1 and D0 or D1
	T2	C1	E0 and D0 or D1
	T2	C1	E1 and D0 or D1
	T2	C2	E0 and D0 or D1
	T2	C2	E1 and D0 or D1
	T2	C3	E0 and D0 or D1
Severe DM (Figure 3)	T2	C3	E1 and D0 or D1
	T1	C1	E2 and D0 or D1
	T1	C2	E2 and D0 or D1
	T2	C1	E2 and D0 or D1
	T2	C2	E2 and D0 or D1
Atrophic maculopathy (Figure 4)	T2	C3	E2 and D0 or D1
	T0	C0	E2 and D0 or D1
	T0	C1	E2 and D0 or D1
	T0	C2	E2 and D0 or D1

EZ: ellipsoid zone; ELM: external limiting membrane; DRIL: disorganization of the inner retinal layers; DM: diabetic maculopathy.

Table 3. Adjunctive features of each stage of diabetic maculopathy.

Hyperreflective foci (H)	Less than 30	H0
	More than 30	H1
Subretinal fluid (F)	Absent	F0
	Present	F1
Vitreoretinal relationship (V)	Absence of any visible adhesion or traction	V0
	IVD	V1
	PVD	V2
	VMT	V3
	ERM	V4

IVD: incomplete posterior vitreous detachment; PVD: posterior vitreous detachment; VMT: vitreomacular traction; ERM: epiretinal membrane.

a risk factor for occurrence or worsening of macular edema.^{55,56} However, real-life studies have reported milder consequences of uneventful procedure on the macular status for eyes featuring early-stage disease.⁵⁷ A prospective Spanish study on 132 eyes revealed similar rate of occurrence of macular edema comparing eyes undergoing phacoemulsification and fellow control eyes. Similarly, a multicenter national DR database from UK estimated a relatively low rate of developing treatment-requiring DM after cataract surgery in patients with mild disease.⁵⁸

A few reports on the effects of intravitreal steroids or anti-VEGF in preventing post-surgical visual loss have

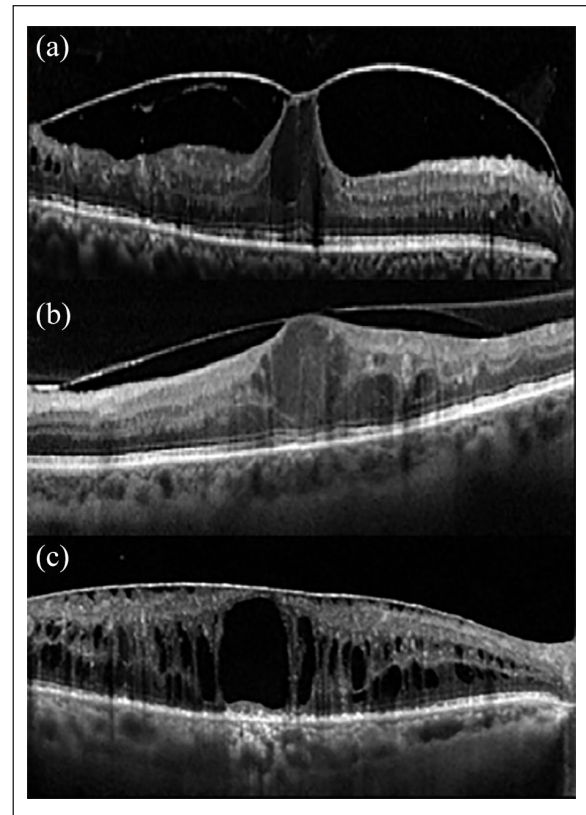


Figure 5. Vitreoretinal relationships associated with the spectrum of diabetic maculopathy.

(a) A typical gull-wing appearance associated with vitreomacular traction and advanced diabetic macular edema. The entity of traction and the isolated presence of cystoid spaces below the vitreoretinal adherence, may suggest a “pure” tractional etiology. (b) Vitreomacular traction with diffuse cystoid spaces associated with advanced diabetic macular edema. In this case, a mixed etiology (tractional and non-tractional) is likely. (c) Severe macular edema with taut epiretinal membrane. The external limiting membrane and the ellipsoid zone are absent subfoveally.

been published.^{59,60} The better categorization of this initial stage of DM might improve the similarity of the patients included in these trials. Early DM may also represent the eyes studied in the recent Protocol V of DRCR Network.⁶¹

We propose a distinction between advanced and severe DM, both characterized by macrocysts and/or multiple intraretinal cystoid spaces and a CST above 30% of maximum normal values but differing in the EZ/ELM state. While in the former, the EZ/ELM may be compromised but still visible and inner retinal layers segmentation is generally preserved. In the latter subtype, the inner retinal segmentation and/or EZ/ELM are mostly undetectable. The two categories may differ considerably in treatment response and visual outcome and should be distinguished.

Finally, the ESASO classification includes macular atrophy as a stage of DM. Macular atrophy is characterized by complete disruption of the outermost retinal layers (EZ/

Table 4. Morphological grading classification of diabetic macular edema based on optical coherence tomography (OCT).

Authors	Year	Participants	Technology	Parameters and subclasses	Considerations
Otani et al. ²¹	1999	59 eyes of 42 patients	TD-OCT	Tomographic fluid distribution: <ul style="list-style-type: none"> • Type 1 = sponge-like retinal swelling. • Type 2 = cystoid macular edema. • Type 3 = serous retinal detachment. 	BCVA moderately correlated with retinal thickness regardless of different tomographic features
Panozzo et al. ²²	2004	1200 eye	TD-OCT	Retinal thickness (>210, >230, >290 μm at fixation point, central zone, and perifoveal area, respectively). Extension. Volume ($\geq 8.0 \text{ mm}^3$). Morphology (simple, cystoid mid/intermediate/severe, neuroepithelial detachment). Vitreous traction (absent, no retinal distortion, retinal distortion, antero-posterior traction).	Severe cystoid macular edema corresponds to chronic, late-stage DME associated with profound visual loss
Kang et al. ²³	2004	145 eyes of 91 patients	TD-OCT	Location and morphology: <ul style="list-style-type: none"> • Type 1 = thickening of the fovea with homogeneous optical reflectivity throughout the whole layer of the retina. • Type 2 = thickening of the fovea with markedly decreased optical reflectivity in the outer retinal layer. • Type 3 = thickening of the fovea with subfoveal fluid accumulation and distinct outer border of detached retina. • Type 3A: without vitreofoveal traction. • Type 3B: with vitreofoveal traction. 	Type 1 correlated with focal leakage on fluorescein angiography and associated with better BCVA
Kim et al. ²⁴	2006	164 eyes of 119 patients	TD-OCT	Location and morphology: <ul style="list-style-type: none"> • Diffuse retinal thickening. • Cystoid macular edema. • Posterior hyaloidal traction. • Serous retinal detachment. • Traction retinal detachment. 	Cystoid macular edema and posterior hyaloidal traction without traction retinal detachment associated with worse vision
Koleva-Georgieva et al. ²⁵	2008	141 eyes of 74 patients	SD-OCT	Macular thickness and retinal morphology: <ul style="list-style-type: none"> • Type 1 = early, CMT > normal + 2SD. • Type 2 = simple. • Type 3 = cystoid. • Type 3A, mild: cystoid spaces with horizontal diameter < 300 μm. • Type 3B, intermediate: cystoid spaces with horizontal diameter 300–599 μm. • Type 3C, severe: cystoid spaces with horizontal diameter $\geq 600 \mu\text{m}$, or large confluent cavities like retinoschisis. • Type 4 = serous macular detachment. 	Good correlation between size of cystoid spaces, retinal thickness, and visual acuity
Helmy et al. ²⁶	2013	104 eyes of 86 patients	SD-OCT	Height of cyst with respect to CMT <ul style="list-style-type: none"> • CME I = cysts less than 30%. • CME II = cysts between 30% and 60%. • CME III = cysts between 60% and 90%. • CME IV = cyst more than 90%. • Each grade subdivided into A–D if none, ELM, IS/OS, or both ELM and IS/OS disruption was present, respectively 	Degree of ELM and IS/OS layers disruption correlated with CME stage
Bolz et al. ²⁷	2014	56 eyes of 40 patients	SD-OCT and FA	S = subretinal fluid. A = area of retinal thickening. V = vitreoretinal abnormalities. E = etiology of leakage (focal, non-focal, ischemic, atrophic).	Ischemic DME (43.6%) and atrophic DME (5.8%) subtypes first described

(Continued)

Table 4. (Continued)

Authors	Year	Participants	Technology	Parameters and subclasses	Considerations
Reznicek et al. ²⁸	2016	39 eyes of 30 patients	SD-OCT and FA	S=subretinal fluid. A=area of retinal thickening. V=vitreoretinal abnormalities. E=etiology of leakage (focal vs non-focal).	The “E”-factor (focal etiology vs non-focal) associated with better BCVA before therapy and over the course of treatment with anti-VEGF
Parodi et al. ¹⁵	2016	201 eyes of 177 patients	SD-OCT	<ul style="list-style-type: none"> • Vasogenic=DME with vascular dilation. • Non-vasogenic=DME without vascular dilation. • Tractional. • Mixed. 	Tractional DME observed especially with CRT > 400 μm. Internal and external cysts and hard exudates predominantly found in vasogenic DME

TD-OCT: time domain-OCT; BCVA: best-corrected visual acuity; DME: diabetic macular edema; SD-OCT: spectral domain-OCT; CMT: central macular thickness; CME: cystoid macular edema; SD: standard deviation; ELM: external limiting membrane; IS/OS: internal segment-outer segment; VEGF: vascular endothelial growth factor; FA: fluorescein angiography; CRT: central retinal thickness.

ELM) and DRIL; macular thickness might be below, within, or slightly above the normal values, if small degenerative cysts persist in the inner retinal layers. Macular atrophy is generally secondary to long-standing macular edema. Only a few authors have evaluated atrophic DM. Bolz et al.⁵⁷ introduced atrophic edema in the SAVE protocol, as the result of retinal cystoid degeneration due to degeneration of Müller cells and/or disruption of the photoreceptor integrity in the central subfield. However, the authors included only eyes with macular thickening on OCT, excluding those without macular edema. Moreover, the authors divided “ischemic DME” and “atrophic DME” in two separate categories; as disruption in the horizontal layers’ integrity (namely, DRIL) has been interpreted as an indirect sign of retinal ischemia and loss of normal vasculature in resolved macular edema, we found it more appropriate to merge the two groups.⁶²

We present the classification based solely on selected morphologic parameters. We recognize that other structural features, as choroidal thickness (CT), or clinical factors, as baseline visual acuity, age at baseline, local and systemic co-morbidities, features on fundus photography, may influence the different aspects of DM.⁶³ For instance, a recent report has analyzed the differential CT in different stages of DR, finding a progressive thinning towards more advanced stages of disease.⁶⁴ In addition, integration of new-generation OCT, the swept-source devices capable of imaging the retina and the choroid, and other diagnostic techniques gathering information on the perfusion status of the periphery and the macula, namely widefield FA and, more recently, OCT angiography, will provide a more precise definition of the grade of ischemia in the different stages of DM (not included in our classification at the present moment).

In conclusion, we propose a novel grading system of DM, classifying the phenotypes of macular involvement based on definitions, grading, and standard OCT figures, including also patients without retinal thickening. In this

grading protocol, whose acronym TCED-HFV can be easily memorized as “To Classify Edema Discerning Hidden Functional Variables,” each of the features evaluated can be combined with the others, achieving four clinical stages. The strength of the present classification is its simplicity; it is intended to be kept as a reference for immediate DM grading.

The value of the present classification and its predictive role in treatment planning and functional prognosis must be established with multicentric larger trials.

Authors’ contributions

All the authors contributed to the conception or design of the work, the acquisition, analysis and interpretation of data, drafting the work, revising it critically for important intellectual content and gave final approval of the version to be published.

Declaration of conflicting interests

The author(s) declared no potential conflicts of interest with respect to the research, authorship, and/or publication of this article.

Funding


The author(s) received no financial support for the research, authorship, and/or publication of this article.

ORCID iDs

Maria Vittoria Cicinelli  <https://orcid.org/0000-0003-2938-0409>

Maurizio Battaglia Parodi  <https://orcid.org/0000-0002-0385-7961>

Paolo Lanzetta  <https://orcid.org/0000-0003-3746-141X>

Giuseppe Querques  <https://orcid.org/0000-0002-3292-9581>

References

1. Rathmann W and Giani G. Global prevalence of diabetes: estimates for the year 2000 and projections for 2030. *Diabetes Care* 2004; 27: 2568–2569.

2. Zhang X, Saaddine JB, Chou CF, et al. Prevalence of diabetic retinopathy in the United States, 2005-2008. *J Am Med Assoc* 2010; 304(6): 649–656.
3. Sabanayagam C, Yip W, Ting DS, et al. Ten emerging trends in the epidemiology of diabetic retinopathy. *Ophthalmic Epidemiol* 2016; 23: 209–222.
4. Virgili G, Menchini F, Casazza G, et al. Optical coherence tomography (OCT) for detection of macular oedema in patients with diabetic retinopathy. *Cochrane Database Syst Rev* 2015; 1: CD008081.
5. Patrao NV, Antao S, Egan C, et al. Real-World Outcomes of ranibizumab treatment for diabetic macular edema in a United Kingdom national health service setting. *Am J Ophthalmol* 2016; 172: 51–57.
6. Cho YJ, Lee DH and Kim M. Optical coherence tomography findings predictive of response to treatment in diabetic macular edema. *J Int Med Res* 2018; 300060518798503.
7. Sanchez-Tocino H, Alvarez-Vidal A, Maldonado MJ, et al. Retinal thickness study with optical coherence tomography in patients with diabetes. *Invest Ophthalmol Vis Sci* 2002; 43: 1588–1594.
8. Vujosevic S, Berton M, Bini S, et al. Hyperreflective retinal spots and visual function after anti-vascular endothelial growth factor treatment in center-involving diabetic macular edema. *Retina* 2016; 36: 1298–1308.
9. Yoon D, Rusu I and Barbazetto I. Reduced effect of anti-vascular endothelial growth factor agents on diabetics with vitreomacular interface abnormalities. *Int Ophthalmol* 2014; 34: 817–823.
10. Gerendas BS, Prager S, Deak G, et al. Predictive imaging biomarkers relevant for functional and anatomical outcomes during ranibizumab therapy of diabetic macular oedema. *Br J Ophthalmol* 2018; 102: 195–203.
11. Radwan SH, Soliman AZ, Tokarev J, et al. Association of disorganization of retinal inner layers with vision after resolution of center-involved diabetic macular edema. *JAMA Ophthalmol* 2015; 133: 820–825.
12. Scott IU, Danis RP, Bressler SB, et al. Effect of focal/grid photocoagulation on visual acuity and retinal thickening in eyes with non-center-involved diabetic macular edema. *Retina* 2009; 29: 613–617.
13. Browning DJ, Altaweel MM, Bressler NM, et al. Diabetic retinopathy clinical research Network. Diabetic macular edema: what is focal and what is diffuse? *Am J Ophthalmol* 2008; 146: 649–655.
14. Schmidt-Erfurth U, Garcia-Arumi J, Bandello F, et al. Guidelines for the management of diabetic macular edema by the European Society of Retina Specialists (EURETINA). *Ophthalmologica* 2017; 237: 185–222.
15. Parodi Battaglia M, Iacono P, Cascavilla M, et al. A Pathogenetic classification of diabetic macular edema. *Ophthalmic Res* 2018; 60: 23–28.
16. Grover S, Murthy RK, Brar VS, et al. Normative data for macular thickness by high-definition spectral-domain optical coherence tomography (spectralis). *Am J Ophthalmol* 2009; 148: 266–271.
17. Murthy RK, Diaz M, Chalam KV, et al. Normative data for macular volume with high-definition spectral-domain optical coherence tomography (Spectralis). *Eur J Ophthalmol* 2015; 25: 546–551.
18. Duker JS, Kaiser PK, Binder S, et al. The International Vitreomacular Traction Study Group classification of vitreomacular adhesion, traction, and macular hole. *Ophthalmology* 2013; 120: 2611–2619.
19. Kinyoun J, Barton F, Fisher M, et al. Detection of diabetic macular edema. Ophthalmoscopy versus photography—early treatment diabetic retinopathy study report number 5. The ETDRS research group. *Ophthalmology* 1989; 96: 746–750.
20. Ruia S, Saxena S, Gemmy Cheung CM, et al. Spectral domain optical coherence tomography features and classification systems for diabetic macular edema: a review. *Asia Pac J Ophthalmol (Phila)* 2016; 5: 360–367.
21. Otani T, Kishi S and Maruyama Y. Patterns of diabetic macular edema with optical coherence tomography. *Am J Ophthalmol* 1999; 127: 688–693.
22. Panozzo G, Parolini B, Gussone E, et al. Diabetic macular edema: an OCT-based classification. *Semin Ophthalmol* 2004; 19: 13–20.
23. Kang SW, Park CY and Ham DI. The correlation between fluorescein angiographic and optical coherence tomographic features in clinically significant diabetic macular edema. *Am J Ophthalmol* 2004; 137: 313–322.
24. Kim BY, Smith SD and Kaiser PK. Optical coherence tomographic patterns of diabetic macular edema. *Am J Ophthalmol* 2006; 142: 405–412.
25. Koleva-Georgieva DN and Sivkova NP. Types of diabetic macular edema assessed by optical coherence tomography. *Folia Med (Plovdiv)* 2008; 50: 30–38.
26. Helmy YM and Atta Allah HR. Optical coherence tomography classification of diabetic cystoid macular edema. *Clin Ophthalmol* 2013; 7: 1731–1737.
27. Bolz M, Lammer J, Deak G, et al. SAVE: a grading protocol for clinically significant diabetic macular oedema based on optical coherence tomography and fluorescein angiography. *Br J Ophthalmol* 2014; 98: 1612–1617.
28. Reznicek L, Bolz M, Garip A, et al. Evaluation of the new “SAVE” protocol in diabetic macular edema over the course of Anti-VEGF treatment. *Curr Eye Res* 2016; 41: 1082–1086.
29. Boyer DS, Nguyen QD, Brown DM, et al. Outcomes with as-needed ranibizumab after initial monthly therapy: long-term outcomes of the phase III RIDE and RISE trials. *Ophthalmology* 2015; 122: 2504–2513.
30. Deak GG, Schmidt-Erfurth UM, Jampol LM, et al. Correlation of central retinal thickness and visual acuity in diabetic macular edema. *JAMA Ophthalmol* 2018; 136: 1215–1216.
31. Pieramici DJ, Wang PW, Ding B, et al. Visual and anatomic outcomes in patients with diabetic macular edema with limited initial anatomic response to ranibizumab in RIDE and RISE. *Ophthalmology* 2016; 123: 1345–1350.
32. Bressler NM, Beaulieu WT, Glassman AR, et al. Persistent macular thickening following intravitreal aflibercept, bevacizumab, or ranibizumab for central-involved diabetic macular edema with vision impairment: a secondary analysis of a randomized clinical trial. *JAMA Ophthalmol* 2018; 136: 257–269.
33. Wells JA, Glassman AR, Ayala AR, et al. Aflibercept, bevacizumab, or ranibizumab for diabetic macular edema: two-year

- results from a comparative effectiveness randomized clinical trial. *Ophthalmology* 2016; 123: 1351–1359.
34. Deak GG, Bolz M, Ritter M, et al. A systematic correlation between morphology and functional alterations in diabetic macular edema. *Invest Ophthalmol Vis Sci* 2010; 51: 6710–6714.
 35. Reznicek L, Cserhati S, Seidensticker F, et al. Functional and morphological changes in diabetic macular edema over the course of anti-vascular endothelial growth factor treatment. *Acta Ophthalmol* 2013; 91: e529–e536.
 36. Iida T, Yannuzzi LA, Spaide RF, et al. Cystoid macular degeneration in chronic central serous chorioretinopathy. *Retina* 2003; 23: 1–7.
 37. Cohen SY, Dubois L, Nghiem-Buffer S, et al. Retinal pseudocysts in age-related geographic atrophy. *Am J Ophthalmol* 2010; 150: 211–217.
 38. Wu L. Multimodality imaging in macular telangiectasia 2: a clue to its pathogenesis. *Indian J Ophthalmol* 2015; 63: 394–398.
 39. Barthelmes D, Sutter FK and Gillies MC. Differential optical densities of intraretinal spaces. *Invest Ophthalmol Vis Sci* 2008; 49: 3529–3534.
 40. Karst S, Mitsch C, Scholda C, et al. Detailed analysis of retinal morphology in patients with diabetic macular edema (DME) randomized to ranibizumab or triamcinolone treatment – reply to the letter to the editor. *Graefes Arch Clin Exp Ophthalmol* 2018; 256: 1039–1040.
 41. Das R, Spence G, Hogg RE, et al. Disorganization of inner retina and outer retinal morphology in diabetic macular edema. *JAMA Ophthalmol* 2018; 136: 202–208.
 42. Maheshwary AS, Oster SF, Yuson RM, et al. The association between percent disruption of the photoreceptor inner segment-outer segment junction and visual acuity in diabetic macular edema. *Am J Ophthalmol* 2010; 150: 63–67.
 43. Toprak I, Yildirim C and Yaylali V. Impaired photoreceptor inner segment ellipsoid layer reflectivity in mild diabetic retinopathy. *Can J Ophthalmol* 2015; 50: 438–441.
 44. Borrelli E, Palmieri M, Viggiano P, et al. Photoreceptor damage in diabetic choroidopathy. *Retina* 2019.
 45. Scarinci F, Nesper PL and Fawzi AA. Deep retinal capillary nonperfusion is associated with photoreceptor disruption in diabetic macular ischemia. *Am J Ophthalmol* 2016; 168: 129–138.
 46. Ito S, Miyamoto N, Ishida K, et al. Association between external limiting membrane status and visual acuity in diabetic macular oedema. *Br J Ophthalmol* 2013; 97: 228–232.
 47. Grewal DS, Hariprasad SM and Jaffe GJ. Role of disorganization of retinal inner layers as an optical coherence tomography biomarker in diabetic and uveitic macular edema. *Ophthalmic Surg Lasers Imaging Retina* 2017; 48: 282–288.
 48. Moein HR, Novais EA, Rebhun CB, et al. Optical coherence tomography angiography to detect macular capillary ischemia in patients with inner retinal changes after resolved diabetic macular edema. *Retina* 2017.
 49. Vujosevic S, Bini S, Torresin T, et al. Hyperreflective retinal spots in normal and diabetic eyes: B-scan and en face spectral domain optical coherence tomography evaluation. *Retina* 2017; 37: 1092–1103.
 50. Zur D, Igllicki M, Busch C, et al. OCT biomarkers as functional outcome predictors in diabetic macular edema treated with dexamethasone implant. *Ophthalmology* 2018; 125: 267–275.
 51. Chatziralli I, Theodosiadis P, Parikakis E, et al. Dexamethasone intravitreal implant in diabetic macular edema: real-life data from a prospective study and predictive factors for visual outcome. *Diabetes Ther* 2017; 8: 1393–404.
 52. Hwang HS, Chae JB, Kim JY, et al. Association between hyperreflective dots on spectral-domain optical coherence tomography in macular edema and response to treatment. *Invest Ophthalmol Vis Sci* 2017; 58: 5958–5967.
 53. Gupta A, Raman R, Mohana K, et al. Communications between intraretinal and subretinal space on optical coherence tomography of neurosensory retinal detachment in diabetic macular edema. *Oman J Ophthalmol* 2013; 6: 183–188.
 54. Vujosevic S, Torresin T, Berton M, et al. Diabetic macular edema with and without subfoveal neuroretinal detachment: two different morphologic and functional entities. *Am J Ophthalmol* 2017; 181: 149–155.
 55. Benson WE, Brown GC, Tasman W, et al. Extracapsular cataract extraction with placement of a posterior chamber lens in patients with diabetic retinopathy. *Ophthalmology* 1993; 100: 730–738.
 56. Jaffe GJ, Burton TC, Kuhn E, et al. Progression of non-proliferative diabetic retinopathy and visual outcome after extracapsular cataract extraction and intraocular lens implantation. *Am J Ophthalmol* 1992; 114: 448–456.
 57. Romero-Aroca P, Fernandez-Ballart J, Almena-Garcia M, et al. Nonproliferative diabetic retinopathy and macular edema progression after phacoemulsification: prospective study. *J Cataract Refract Surg* 2006; 32: 1438–1444.
 58. Denniston AK, Chakravarthy U, Zhu H, et al. The UK Diabetic Retinopathy Electronic Medical Record (UK DR EMR) Users Group, Report 2: real-world data for the impact of cataract surgery on diabetic macular oedema. *Br J Ophthalmol* 2017; 101: 1673–1678.
 59. Lim LL, Morrison JL, Constantinou M, et al. Diabetic macular edema at the time of cataract surgery trial: a prospective, randomized clinical trial of intravitreal bevacizumab versus triamcinolone in patients with diabetic macular oedema at the time of cataract surgery – preliminary 6 month results. *Clin Exp Ophthalmol* 2016; 44: 233–242.
 60. Calvo P, Ferreras A, Al Adel F, et al. Effect of an intravitreal dexamethasone implant on diabetic macular edema after cataract surgery. *Retina* 2018; 38: 490–496.
 61. Baker CW, Glassman AR, Beaulieu WT, et al. Effect of initial management with aflibercept vs laser photocoagulation vs observation on vision loss among patients with diabetic macular edema involving the center of the macula and good visual acuity: a randomized clinical trial. *J Am Med Assoc* 2019.
 62. Moein HR, Novais EA, Rebhun CB, et al. optical coherence tomography angiography to detect macular capillary ischemia in patients with inner retinal changes after resolved diabetic macular edema. *Retina* 2018; 38: 2277–2284.
 63. Bressler SB, Qin H, Beck RW, et al. Factors associated with changes in visual acuity and central subfield thickness at 1 year after treatment for diabetic macular edema with ranibizumab. *Arch Ophthalmol* 2012; 130: 1153–1161.
 64. Lains I, Talcott KE, Santos AR, et al. Choroidal thickness in diabetic retinopathy assessed with swept-source optical coherence tomography. *Retina* 2018; 38: 173–182.