

Mandibular distraction osteogenesis with a small semiburied device in neonates: Report of 2 cases

Bruno Brevi, MD; Francesco Laganà, MD; Fabio Piazza, MD; Enrico Sesenna, MD, DMD

Abstract

Distraction osteogenesis has recently assumed an important role in the correction of craniofacial anomalies, particularly for the treatment of potentially life-threatening, deformity-associated upper airway obstruction and respiratory dysfunction in neonates. Such deformities include Treacher Collins syndrome, Goldenhar's syndrome, Nager's syndrome, temporomandibular joint ankylosis, and Pierre Robin sequence. These conditions frequently require a tracheostomy to maintain airway patency. We report our experience with using mandibular distraction as a valid alternative to tracheostomy. Minimally invasive surgery is possible with small semiburied devices.

Introduction

Bone lengthening by distraction is not a new concept. Surgeons were using it on the lower extremities as far back as the turn of the 20th century.¹⁻⁴ In 1989, Ilizarov and colleagues defined the biologic bases of distraction osteogenesis, and bone lengthening became a reliable procedure with predictable and reproducible results.^{5,6} In 1973, Snyder et al described the distraction technique for elongating the mandible in an experimental dog model.⁷ In 1990, Karp et al reported new bone formation at the elongated site.⁸

Distraction osteogenesis has recently assumed an important role in the correction of craniofacial anomalies, particularly for the treatment of potentially life-threatening, deformity-associated upper airway obstruction and respiratory dysfunction in neonates. Such deformities include Treacher Collins syndrome, Goldenhar's syndrome,

Nager's syndrome, temporomandibular joint ankylosis, and Pierre Robin sequence. Upper airway obstruction can lead to episodes of asphyxia and result in cor pulmonale, neurologic disorders, and sudden infant death.⁹

The management of upper airway obstruction is based on either (1) conservative methods (prone position, nasopharyngeal tube) or (2) surgery involving pulling the tongue base forward, hyomandibulopexy, subperiosteal release of the floor of the mouth, tracheostomy, and distraction osteogenesis. Many affected patients require a tracheostomy.¹⁰ The decision to perform a tracheostomy on a neonate requires a long-term commitment; according to one report, the average age at decannulation was 3.1 years.¹¹

In this article, we describe the cases of 2 neonates with syndromic Pierre Robin sequence who experienced feeding difficulties and severe upper airway obstruction. In both cases, we were able to avoid tracheostomy by performing a bilateral mandibular distraction.

Case reports

Surgical technique. Both infants underwent distraction with a Brevi-Sesenna distractor (Cizeta Surgical Products; Bologna, Italy). Two small semiburied lengthening devices were applied to the mandibular distraction sites. Each device is made up of two stainless-steel components connected to each other by an activation screw (figure 1). The device's two footplates are malleable enough to allow for complete contact with a bony surface.

A distractive force was applied to the activation screw through a universal joint driven by a transcutaneous barrel. In these particular procedures, the device applied traction along a plane parallel to the mandibular body. An osteotomy was performed via a transcutaneous approach in the manner described by Risdon.¹² The external corticotomy was extended diagonally from the posterior edge of the alveolar ridge to the gonial angle, with attention paid to the dental buds. A series of holes parallel to the external corticotomy was made in the internal cortical layer to weaken it, as care was taken to avoid the inferior alveolar nerve. The device

From the Department of Maxillofacial Surgery (Dr. Brevi, Dr. Laganà, and Dr. Sesenna) and the Department of ENT, Otolaryngology, Neurotology, and Skull Base Surgery (Dr. Piazza), University of Parma, Italy.

Reprint requests: Fabio Piazza, MD, Department of ENT, Otolaryngology, Neurotology, and Skull Base Surgery, University of Parma, Ospedale Maggiore, Via Gramsci 14, 43100 Parma, Italy. Phone: 39-0521-703-189; fax: 39-0521-290-157; e-mail piazzafabio@hotmail.com

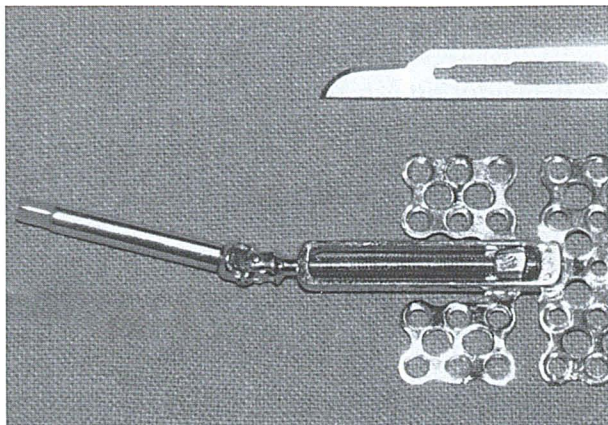


Figure 1. The Brevi-Sesenna distractor can lengthen the mandible as much as 15 mm.

was positioned with the use of four cortical screws, each 1.5 mm in length. Once the osteotomy was completed by rotating an osteotome, the distractor was stabilized. The same procedure was performed on the contralateral side. The wound margins were approximated with interrupted suture in the plane of dissection. Two cutaneous incisions in the chin area allowed for insertion of the transcutaneous barrel. In both patients, the distractors were firmly attached to the bone surface, the device-bone complex was completely stable, and the bone callus appeared to be of good quality with hyperplastic features.

Distraction was initiated 24 hours after the surgical procedure and continued at a rate of 1 mm/day for 15 days. At that point, the device's maximum extension (15 mm) was reached. Both distractors were removed 5 weeks after maximum extension had been attained. The same surgical incisions were used for removal.

Patient 1. A 20-day-old boy was referred to our attention with a diagnosis of syndromic Pierre Robin sequence. Five days before admission to our department, the patient had experienced frequent episodes of respiratory dysfunction accompanied by oxygen desaturation and bradycardia.

On physical examination, micrognathia and upper airway obstruction caused by glossoptosis were noted. Videendoscopy detected neither nasal nor rhinopharyngeal obstruction, and so a nasopharyngeal tube was placed to assure ventilation. The patient's clinical course worsened during the following days, and surgery was planned. At 1 month of age, he underwent bilateral mandibular distraction.

Eight days postoperatively, the patient was able to breathe without the nasopharyngeal tube. After 15 days, he resumed oral feeding and a normal diet. After distraction had reached its maximum length of 15 mm, the competence of the lips appeared to be good and the overall aesthetic appearance was one of slight prognathia.

At the 1-year follow-up, no signs or symptoms of respiratory distress were present. The aesthetic appearance was good, and visible scarring was minimal.

Patient 2. A newborn boy was referred to our attention following diagnostic ultrasonography of a cleft palate. The patient had severe mandibular hypoplasia and clefting of the hard palate, and he was diagnosed with syndromic Pierre Robin sequence (figure 2, A).

A nasopharyngeal tube was placed because the patient was not able to maintain an airway while asleep, and oxygen desaturation occurred on room air when he was awake. A preoperative sleep study was not possible. Physical examination revealed micrognathia and upper airway obstruction caused by ptosis of the tongue base. Videendoscopy detected neither nasal nor rhinopharyngeal obstruction. At the age of 8 days, the patient underwent bilateral mandibular distraction (figure 2, B).

Within a few days postoperatively, the patient was able to breathe without the nasopharyngeal tube. He did not experience difficulty with airway maintenance or oxygen saturation while awake, and there was no clinical evidence of apnea when he was asleep.

At the 6-month follow-up, no subjective or objective evidence of sleep apnea was present, and the appearance of the mandible was nearly normal (figure 2, C).

Discussion

Ilizarov's concept of bone regeneration was based on the idea that when a traction force is applied across an osteotomy line, new bone is generated along this force line.⁵ Ilizarov pointed out the relationships between distraction rate and ossification of the callus, and he empirically established that the correct amount of distraction would be approximately 1 mm/day.⁵

In order to achieve successful bone elongation, the stability of the distraction system must be maintained. Destabilization of the bone-device complex sometimes results in procedure failure. Ilizarov emphasized the necessity of respecting soft tissues and periosteum to preserve osteoprogenitor function and to provide good bone vascularization.⁶

A series of technical problems arise during distraction osteogenesis in neonates because of the dimensions and ossification of the mandible. Pin-loosening is a common complication during treatment of children younger than 2 years.^{13,14} In our previous experience (unpublished data), 2 children—a 4-month-old and a 2-year-old—underwent mandibular distraction with an external three-dimensional distraction device (Multi-Guide; Leibinger Micro Implants; Freiburg, Germany). In the younger patient, two pins on the same side became loose and were lost at the end of the distraction step. As a result, we were forced to remove the distractor. On the contralateral side, the device

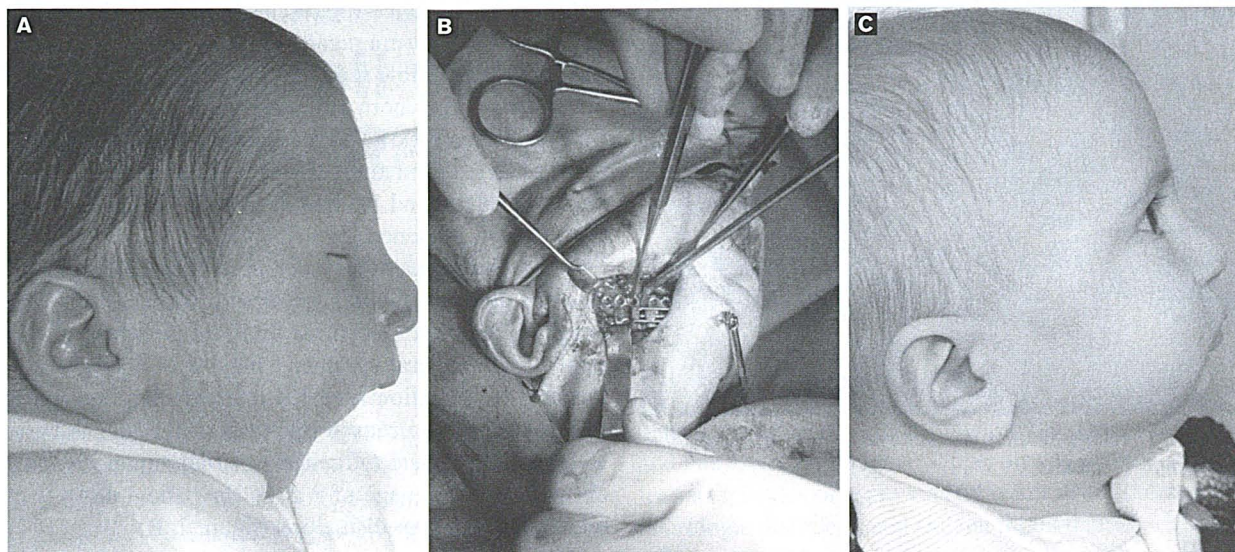


Figure 2. Patient 2. Photographs document this case preoperatively (A), intraoperatively (B), and postoperatively (C).

maintained its stability until satisfactory ossification of the callus occurred.

Another consideration in patients younger than 2 years is the way in which the stability of the system is influenced by biologic features of bone and the mechanical characteristics of the device; the biologic features are predictable but not modifiable, and the mechanical characteristics are variable. A system made up of an external device applied to the mandible is roughly comparable to a fixed-end system in which a beam (the pin) is locked into the mandible. From a mechanical perspective, six forces act on the pin. The system is stable only if the sum of opposing forces equals zero (figure 3). The system can be stabilized by acting on the load forces, reducing the mass of the distractor, and shortening the pin. A major reduction in the length of the pin can be achieved when the distractor device is placed on the bone surface, as happens with the Brevi-Sesenna device. Moreover, compared with other devices, the load force applied by the Brevi-Sesenna distractor is spread among the four screws and distributed over a larger mandibular surface.

$$\sum F = F_r - F_l = 0$$

$$\sum M = -Ma + F_l b = 0$$

Key: F = force; F_r = constraint reaction force due to the mandible; F_l = load force; M = moment; Ma = fixing moment; b = pin length

Figure 3. Formulae represent the balance equations of the bone-device complex.

Miniaturization of a distractor reduces its mass but requires simplifying it so that only unidirectional distraction is possible.

The goal of distraction is to lengthen the mandible sagittally in order to enlarge the upper airway space. The Brevi-Sesenna device allows for excellent management of upper airway obstruction secondary to mandibular hypoplasia in neonates. In our experience, overcorrection is necessary to obtain maximal enlargement of the upper airway space. Moreover, overcorrection reduces the long-term underdevelopment of the mandible that is commonly seen in these patients.

Placing an internal device via a skin incision allows for proper wound healing with minimal scarring. There is also good patient acceptance of the device during the consolidation phase because there are no external components.

Even though our surgical experience is still limited, we agree with other authors¹⁵ that in selected cases, the use of small semiburied distractors provides surgeons with an opportunity to avoid tracheostomy in neonates. In our experience, distraction osteogenesis applied to the mandible is associated with far fewer complications than is tracheostomy during the treatment of severe upper airway obstruction secondary to craniofacial malformation. The semiburied device is effective in precluding the need for tracheostomy in neonates.

References

1. Codivilla A. On the means of lengthening, in the lower limbs, the muscles and tissues which are shortened through deformity. 1904. Clin Orthop Relat Res 1994;(301):4-9.
2. Abbott LC. The operative lengthening of the tibia and fibula. J Bone Joint Surg 1927;9:128-52.

3. Ilizarov GA, Smelyshev NN. [Lengthening of the femur with simultaneous closed arthrodesis of the hip joint]. *Ortop Travmatol Protez* 1972;33:62-8.
4. De Bastiani G, Aldegheri R, Renzi-Brivio L, Trivella G. Limb lengthening by callus distraction (callotasis). *J Pediatr Orthop* 1987;7:129-34.
5. Ilizarov GA. The tension-stress effect on the genesis and growth of tissues: Part I. The influence of stability of fixation and soft-tissue preservation. *Clin Orthop Relat Res* 1989;(238):249-81.
6. Ilizarov GA. The tension-stress effect on the genesis and growth of tissues: Part II. The influence of the rate and frequency of distraction. *Clin Orthop Relat Res* 1989;(239):263-85.
7. Snyder CC, Levine GA, Swanson HM, Browne EZ Jr. Mandibular lengthening by gradual distraction. Preliminary report. *Plast Reconstr Surg* 1973;51:506-8.
8. Karp NS, Schreiber JS, Thorne CH, McCarthy JG. Membranous bone lengthening: A serial histologic study. *Plastic Surgery Forum* 1990;13:113.
9. Molina F, Ortiz Monasterio F. Mandibular elongation and remodeling by distraction: A farewell to major osteotomies. *Plast Reconstr Surg* 1995;96:825-40.
10. Benjamin B, Walker P. Management of airway obstruction in the Pierre Robin sequence. *Int J Pediatr Otorhinolaryngol* 1991;22:29-37.
11. Tomaski SM, Zalzal GH, Saal HM. Airway obstruction in the Pierre Robin sequence. *Laryngoscope* 1995;105:111-14.
12. Ivy RH. E. Fulton Risdon (1880-1968). *Plast Reconstr Surg* 1969;44:214-16.
13. Morovic CG, Monasterio L. Distraction osteogenesis for obstructive apneas in patients with congenital craniofacial malformations. *Plast Reconstr Surg* 2000;105:2324-30.
14. Denny A, Kalantarian B. Mandibular distraction in neonates: A strategy to avoid tracheostomy. *Plast Reconstr Surg* 2002;109:896-904.
15. Denny AD, Talisman R, Hanson PR, Recinos RF. Mandibular distraction osteogenesis in very young patients to correct airway obstruction. *Plast Reconstr Surg* 2001;108:302-11.

Recommended by over 1,000 ENTs

CLINICAL STUDIES HAVE SHOWN BOTH GINKGO BILOBA EXTRACT AND CHELATED ZINC EFFECTIVE IN REDUCING TINNITUS.

- » Hostein N. Ginkgo special extract Egb 761 in tinnitus therapy. A survey of results of completed clinical trials. *Fortschr Med Orig.* 11;118(4):157-64, 2001 Jan. Review.
- » Meyer B. Multicenter randomized double-blind drug vs. placebo study of the treatment of tinnitus with Ginkgo biloba extract. *Presse Med.* 15(31):1562-4, 1986 Sep 25.
- » Morgenstern C, Biermann E. The efficacy of Ginkgo special extract Egb 761 in patients with tinnitus. *Int J Clin Pharmacol Ther.* 40(5):188-97, 2002 May.
- » Arda HN, et al. The role of zinc in the treatment of tinnitus. *Otol Neurotol.* 24(1):86-9, 2003 Jan.



ARCHES TINNITUS RELIEF FORMULA®

MICHAEL SEIDMAN, MD, FACS

authority on tinnitus and conditions of the inner ear states:

"IT HAS BEEN MY EXPERIENCE in treating tinnitus with Arches Tinnitus Relief Formula that 10% enjoy a complete reduction of symptoms, 10% experience no change, and 80% receive some degree of relief from their symptoms, varying by individual. I recommend Arches Tinnitus Relief Formula to many of my patients* and advise them to take two capsules in the morning and again in the evening and continue this dosage for 100 days before determining the degree of relief Arches Tinnitus Relief Formula will provide."

Dr. Seidman is the Medical Director of Arches and has a small financial interest in the company.

TINNITUS RELIEF IS UNDER THE ARCH
CALL FOR A FREE PHYSICIAN'S BOOKLET
PLUS CD WITH 35 CLINICAL STUDIES, C OF A, & MORE...

TOLL FREE 800-350-9631

email: admin@archesnps.com www.tinnitusformula.com



Arches Tinnitus Formulas

*Certain people should exercise caution before taking Ginkgo biloba extract. Those taking prescription anticoagulants should consult their physician before use. Discontinue use two weeks prior to any surgical procedure.

