



## Upfront HIPEC and bevacizumab-containing adjuvant chemotherapy in advanced epithelial ovarian cancer

Ida Paris, Stefano Cianci, Giuseppe Vizzielli, Anna Fagotti, Gabriella Ferrandina, Salvatore Gueli Alletti, Barbara Costantini, Francesco Cosentino, Ettore Capoluongo, Mariangela Pasqualoni & Giovanni Scambia

To cite this article: Ida Paris, Stefano Cianci, Giuseppe Vizzielli, Anna Fagotti, Gabriella Ferrandina, Salvatore Gueli Alletti, Barbara Costantini, Francesco Cosentino, Ettore Capoluongo, Mariangela Pasqualoni & Giovanni Scambia (2018): Upfront HIPEC and bevacizumab-containing adjuvant chemotherapy in advanced epithelial ovarian cancer, International Journal of Hyperthermia, DOI: [10.1080/02656736.2018.1503346](https://doi.org/10.1080/02656736.2018.1503346)

To link to this article: <https://doi.org/10.1080/02656736.2018.1503346>



© 2018 The Author(s). Published with license by Taylor & Francis Group, LLC.



Published online: 09 Oct 2018.




Submit your article to this journal [↗](#)



View Crossmark data [↗](#)

## Upfront HIPEC and bevacizumab-containing adjuvant chemotherapy in advanced epithelial ovarian cancer

Ida Paris<sup>a</sup>, Stefano Cianci<sup>a</sup> , Giuseppe Vizzielli<sup>a</sup>, Anna Fagotti<sup>b</sup>, Gabriella Ferrandina<sup>b</sup>, Salvatore Gueli Alletti<sup>a</sup>, Barbara Costantini<sup>a</sup>, Francesco Cosentino<sup>a</sup>, Ettore Capoluongo<sup>c</sup>, Mariangela Pasqualoni<sup>a</sup> and Giovanni Scambia<sup>b</sup>

<sup>a</sup>Department of Women's and Children's Health, Fondazione Policlinico Universitario A. Gemelli IRCCS, Rome, Italy; <sup>b</sup>Department of Women's and Children's Health, Fondazione Policlinico Universitario A. Gemelli IRCCS and Università Cattolica, Rome, Italy; <sup>c</sup>Department of Clinical Chemistry, Fondazione Policlinico Universitario A. Gemelli IRCCS and Università Cattolica, Rome, Italy

### ABSTRACT

**Introduction:** In advanced epithelial ovarian cancer patients, the standard of care is primary debulking surgery, followed by first-line chemotherapy often with bevacizumab addition. In this context, some experiences have shown that a comprehensive treatment approach to surgery combined with hyperthermic intraperitoneal chemotherapy (HIPEC) could improve the prognosis.

**Objective:** This is a study aimed to explore the feasibility of primary debulking surgery and HIPEC upfront followed by first-line therapy with bevacizumab.

**Study Design:** Phase II monocentric, open label, non-randomised and single-arm study. Forty patients affected by advanced ovarian cancer submitted to primary debulking surgery with HIPEC were enrolled in the study. After surgery, all patients underwent systemic chemotherapy with bevacizumab addition.

**Results:** Complete cytoreduction (RT = 0) was achieved in all cases. Treatment-related early complications were observed in 23 patients and in 15 cases were G1–G2. Major complications were reported in 8 patients. No postoperative death was recorded.

Subsequent chemotherapy was administered in all cases. Median time between surgery and first cycle of chemotherapy was 42 days (range 30–76). Concomitant bevacizumab was administered in 34 patients (85%). Maintenance with bevacizumab was feasible in 33 patients (82.5%) and its withdrawal was necessary for 1 patient (2.5%) due to G3 hypertension.

**Conclusion:** Our data suggest that HIPEC can be safely introduced in the upfront therapy of advanced ovarian cancer.

### ARTICLE HISTORY

Received 13 July 2018

Accepted 17 July 2018

### KEYWORDS

Bevacizumab; chemotherapy; ovarian cancer; HIPEC; loco-regional treatment

### Introduction

In advanced epithelial ovarian cancer (AEOC) patients, the standard of care is primary debulking surgery (PDS), aimed to reach completeness of cytoreduction, followed by first-line chemotherapy with carboplatin and paclitaxel [1]. For patients in stage IIIc/IV that are not ideal candidates for PDS, the treatment that has recently gained acceptance is a combination of neoadjuvant chemotherapy followed by interval debulking surgery (IDS) [2–5].

Modifications to the carboplatin–paclitaxel regimen, including extension of front-line agents, high-dose chemotherapy, immunotherapy, biological therapy and single-agent paclitaxel, have made limited improvements to survival rates. At present, the only treatment that has prolonged progression-free survival (PFS) is the addition of anti-VEGF monoclonal antibody bevacizumab to carboplatin–paclitaxel, as reported in the ICON7 and GOG-0218 phase 3 studies [6,7]. Therefore, there is still a significant unmet need in the first-line therapy for ovarian cancer.

In this context, some experiences have shown that a comprehensive treatment approach of surgery combined with

hyperthermic intraperitoneal chemotherapy (HIPEC) could be able to improve the prognosis of AEOC as reported in few clinical studies [8–17]. Despite the established rationale and these encouraging results, a certain degree of skepticism still surrounds HIPEC in AEOC, involving inherent potential morbidity and the paucity of randomized data confirming its theoretical advantage. Moreover, the literature on HIPEC safety and efficacy in combination with bevacizumab is very less and therefore needs to be better investigated. Based on these considerations, we conducted a phase II monocentric, open label, non-randomized and single-arm study aimed to explore the feasibility of PDS and HIPEC upfront followed by first-line therapy with bevacizumab, as GOG-0218 schedule [7].

### Materials and methods

This prospective phase II monocentric, open label, non-randomised and single-arm study was conducted at Division of Gynecologic Oncology of Agostino Gemelli Foundation

**CONTACT** Giovanni Scambia  [giovanni.scambia@policlinicogemelli.it](mailto:giovanni.scambia@policlinicogemelli.it)  Department of Women's and Children's Health, Policlinico Agostino Gemelli Foundation University Hospital, Rome 00168, Italy

© 2018 The Author(s). Published with license by Taylor & Francis Group, LLC.

This is an Open Access article distributed under the terms of the Creative Commons Attribution License (<http://creativecommons.org/licenses/by/4.0/>), which permits unrestricted use, distribution, and reproduction in any medium, provided the original work is properly cited.

University Hospital in Rome, from February 2015 to February 2016 and was approved by our IRB (protocol n. 0115/2015). Informed consent was obtained from all subjects. The diagnosis was obtained at frozen section during surgery.

All enrolled patients underwent pre-operative evaluation by CT scan, pelvic ultrasound and tumor markers. Major criteria to abort PDS were the Poorest Eastern Cooperative Oncology Group performance status (i.e., ECOG-PS  $>2$ ) and/or higher American Society of Anesthesiology score (i.e., ASA  $>2$ ). According to previously published data [18], all patients were submitted to Staging-LPS in order to evaluate and quantify peritoneal dissemination of the tumor through a scoring system (i.e., PIV) [19], and only patients with a score  $<8$  were included in the final analysis.

The inclusion criteria were as follows: age between 18 years and  $<70$  years; Fagotti Score [19]  $<8$ ; FIGO stage at least IIIB; ECOG-PS  $\leq 2$  [20]; life expectancy of at least 3 months; normal cardiac, hepatic, respiratory and bone marrow functions (creatinine clearance  $>60 \mu\text{L}/\text{min}$  according to Cockcroft formula [21], absolute neutrophil count  $>1500/\mu\text{l}$ , a platelet count  $>150\,000/\mu\text{l}$ , bilirubin levels and creatinine  $<1.5$  times upper the range); optimal primary cytoreduction achieved (CC-0, CC-1) and signed informed consent form.

The exclusion criteria were as follows: FIGO stage less than IIIB; coexistence of other oncologic disease; body mass index (BMI)  $>30 \text{ kg}/\text{m}^2$ ; active infection or general conditions that could interfere with treatment (vasculopathy, autoimmune disorders and diabetes); refusal to sign the informed consent form; previous recipient of chemotherapy treatment; distant (extra-abdominal) unresectable metastases and bowel obstruction.

The patients who met inclusion criteria, and that were considered suitable for PDS at Staging-LPS, underwent mono/bilateral adnexectomy or peritoneal biopsy to confirm the diagnosis of ovarian cancer at frozen section. If the diagnosis of ovarian cancer was confirmed, the patient was submitted to PDS with the aim to achieve complete cytoreduction (RT=0). The completeness of cytoreduction (CC) was assessed using a score ranging from 0 to 3 (CC-0 indicates no residual tumor; CC-1 indicates nodules  $<0.25 \text{ mm}$ ; CC-2 indicates nodules between 0.25 and 2.5 cm in diameter and CC-3 indicates nodules  $>2.5 \text{ cm}$ ). After completion of cytoreduction, four drains were positioned in the four abdominal quadrants. HIPEC perfusion was performed with closed technique, and the abdomen was carefully re-explored after HIPEC completion. All patients received intraperitoneal cisplatin  $75 \text{ mg}/\text{m}^2$  at the temperature of  $41.5^\circ\text{C}$  for 60 min immediately after PDS. All patients underwent systemic adjuvant chemotherapy with bevacizumab according to international guidelines [1]. Physical examination, thoracic/abdominal CT scan and Ca 125 serum level assessment were all performed every 3 months during the first 2 years and every 6 months thereafter. Primary platinum-free interval (PFI) was defined as the time elapsed between the end of carboplatin treatment and first recurrence. Data are given as median and range. Categorical variables are reported as absolute values and percentage.

## Statistical analysis

The sample size was quantified based on previous studies reporting a pooled rate of postoperative major (G3–G4) complications ranging between 45% and 98% [22] disabling an early ( $<40$  days) start to adjuvant chemotherapy (ICON 7). Based on the minimax 2-stage design by Simon [23], we tested the null hypothesis that the true rate of an early start to the administration of chemotherapy with bevacizumab after PDS and HIPEC could reach clinically relevant alternative of 85%, using an alpha-error of 0.05 and a beta-error of 0.2.

Thus, the first step was planned to include 31 patients; if  $>25$  (80%) women started adjuvant chemotherapy with bevacizumab before 40 days, the study would enroll an additional 5 patients up to a total number of 36 patients. Considering a dropout rate of 10%, at least 40 cases were planned to be enrolled.

PFS was calculated from the date of diagnosis to progression of disease or the date last seen while overall survival (OS) was calculated from the date of diagnosis to the date of death of disease or the date of the last follow-up. Data analysis was performed using the NCSS statistical software program, version 11.0 (NCSS Statistical Software, Kaysville, UT) was used.

## Results

Forty patients were prospectively enrolled. Patients' characteristics are shown in Table 1. The details of PDS and HIPEC procedures are shown in Table 2. Median surgical complexity score (SCS) was 3 (range: 2–3). Complete cytoreduction (RT=0) was achieved for all cases. Median operative time was 480 min (range: 360–740) and median Cisplatin dose was 126.5 (100–148). Median postoperative hospital stay was 8 days (range: 5–30). Diaphragm peritonectomy were performed in 67.5% while diaphragm resection in 7.5% of cases. Splenectomy was performed in 75% and 30% of patients, respectively. Pelvic/lombo aortic lymphadenectomy were performed in 62.5% of cases only when metastatic lymph nodes were detected. Treatment-related early complications were observed in 23 patients and in 15 cases were G1–G2. Major complications consisting of pleural effusion requiring drain and bowel anastomosis dehiscence were reported in five and three patients, respectively. Late complications were mild and related to kidney failure (Table 2). No postoperative death was recorded.

Subsequent chemotherapy was administered (Table 3) in 100% of cases (40 patients). Median time between surgery and the first cycle of chemotherapy was 42 days (range 30–76). Concomitant bevacizumab was administered in 34 patients (85%). Maintenance with bevacizumab was feasible in 33 patients (82.5%) and its withdrawal was necessary for 1 patient (2.5%) due to hypertension G3. Six out of 40 patients (15%) were not treated with bevacizumab for the following reasons: four patients experienced proteinuria and kidney failure G2 after HIPEC; one patient developed central venous

**Table 1.** Patients' characteristics.

Variables	
<b>All cases</b>	40
<b>Age (Median) (range)</b>	51.5 (32–70)
<b>BMI (Median) (range)</b>	23 (18–35)
<b>PS-ECOG (Median) (range)</b>	0 (0–1)
<b>Histology (N) (%)</b>	
Serous	35 (87.5%)
Endometrioid	2 (5.0%)
Clear cell	1 (2.5%)
<b>Stage (N) (%)</b>	
IIIC	38 (95.0%)
IIIB	2 (5.0%)
Undifferentiated	2 (5.0%)
<b>Grade (N) (%)</b>	
2	3 (7.5%)
3	37 (92.5%)
<b>PIV (LPS) (Median) (range)</b>	4 (2–6)
<b>PIV (LPT) (Median) (range)</b>	4 (2–8)

**Table 2.** Perioperative outcomes.

Variables	N (%)
<b>Surgical procedures</b>	
Hysterectomy	37 (92.5)
BSO	40 (100)
PL/LA lymphadenectomy <sup>a</sup>	25 (62.5)
Omentectomy	40 (100)
Appendectomy	14 (35.0)
LB resection	23 (57.5)
B resection	4 (10.0)
Diaphragm resection	3 (7.5)
Diaphragm peritonectomy	27 (67.5)
Splenectomy	12 (30.0)
Others	15 (37.5)
<b>RT = 0</b>	40 (100)
<b>SCS<sup>b</sup> (median) (range)</b>	3 (2–3)
<b>Surgical time (min) (median) (range)</b>	480 (360–740)
<b>Temperature inflow (median) (range)</b>	41.5 (41.5–43.5)
<b>Cisplatin dose (median) (range)</b>	126.5 (100–148)
<b>EBL (median) (range)</b>	600 (100–2500)
<b>Blood transfusion</b>	17 (42.5)
<b>Early complications</b>	23 (57.5)
G1–G2	15 (37.5)
G3*	5 (12.5)
G4**	3 (7.5)
<b>Late complications</b>	
G1	2 (5)***
G2	2 (5)***
G3	0
G4	0
<b>Hospital stay (median) (range)</b>	8 (5–30)

<sup>a</sup>[https://www.nccn.org/professionals/physician\\_gls/pdf/ovarian.pdf](https://www.nccn.org/professionals/physician_gls/pdf/ovarian.pdf).

<sup>b</sup>Surgical complexity score (SCS).

\*Pleural effusion (requiring drain).

\*\*Re-laparotomy (bleeding, bowel anastomosis dehiscence).

\*\*\*Two kidney failure, two kidney failure.

thrombosis and one patient showed a poor performance status after HIPEC (ECOG 2).

At the time of this analysis, with a median follow-up of 25 months (range 5–40), the progression of disease occurred in seven patients (six peritoneal progressions and one lung/mediastinum metastasis). At present, 37 patients remain alive (Figure 1).

## Discussion

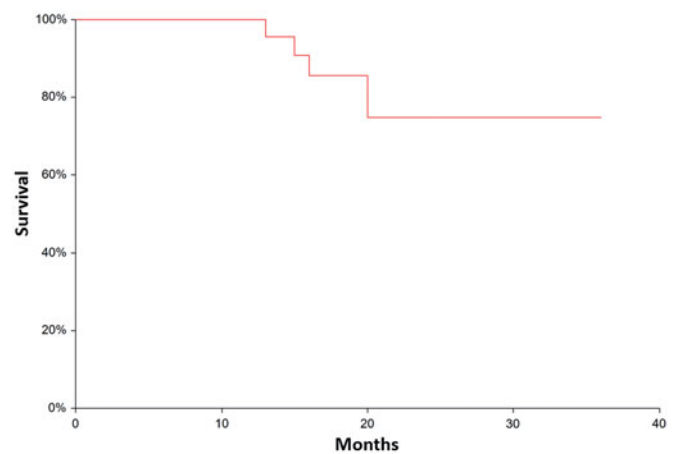
Primary debulking surgery followed by chemotherapy is the cornerstone of AEOC treatment. The addition of the biological anti-angiogenic agent bevacizumab to standard

**Table 3.** Adjuvant treatment details.

Variables	N (%)
<b>All cases</b>	40
<b>Chemotherapeutic details</b>	
CDDP + Taxol + Bevacizumab	34 (85.0)
Bevacizumab concomitant courses (median) (range)	5 (1–6)
Bevacizumab maintenance	33 (82.5)
Bevacizumab withdrawal	1 (2.5)*
No bevacizumab administration	6 (15.0)**
<b>Hematological toxicity</b>	
Neutropenia G2	3 (7.5)
Neutropenia G3–G4	20 (50.0)
Anemia G3	2 (5.0)
Thrombocytopenia G3–G4	1 (2.5)
<b>Non-hematological toxicity</b>	
Hypertension G2–G3	3 (7.5)
Peripheral neuropathy G2	3 (7.5)

\*Only one cycle for hypertension G3.

\*\*Four patients did not receive bevacizumab due to kidney failure G2 after PDS + HIPEC; the other two patients had DVT.



**Figure 1.** Overall survival in ovarian cancer patients treated with PDS and HIPEC.

chemotherapy resulted in a prolongation of PFS, suggesting that the combination of carboplatin, paclitaxel and bevacizumab may become the new standard in the first-line treatment of AEOC [24]. However, survival [2,3] results in ovarian cancer remain largely unsatisfactory. In this context, HIPEC has been proposed as a promising strategy based on several theoretical reasons: (i) i.p. chemotherapy is certainly effective in the management of AEOC, as reported in several randomized clinical trials [7]; (ii) hyperthermia has proved to enhance cytotoxicity of platinum compounds [25] and (iii) starting chemotherapy at surgery virtually avoids any delay in chemotherapy. This last reason could be particularly significant because it has been demonstrated that a delay of 7 days in beginning chemotherapy resulted in an 8.7% increase of mortality in patients with complete surgical debulking [26].

In our study, we have found that PDS with HIPEC is feasible and can be combined with the most active primary therapy presently available in AEOC, i.e., carbo-taxol bevacizumab. Despite the aggressive surgical procedures performed, toxicity was mild and easily managed (20% of G3–G4 morbidity) with a median hospital stay of 8 days. This result is relevant because the risk of increased postoperative complications after primary debulking surgery and

carboplatin-paclitaxel-bevacizumab adjuvant chemotherapy was raised as a potential issue in the management of AEOC based also on experiences in colorectal cancer treatment. Interestingly, as reported by Duska et al. [27] the addition of bevacizumab to conventional first-line regimen does not imply an increased risk of readmission or postoperative complications. As the subgroup of patients experiencing multiple readmissions ( $\geq 2$ ) only accounted for around 3% of the entire population, the use of bevacizumab seems to be detrimental. Furthermore, the paper by Duska et al. [27] is also highly valuable to identify the correct time-interval between primary cytoreductive surgery and adjuvant chemotherapy. In particular, given the observation that patients readmitted within 40 days of surgery had a significantly shorter interval from surgery to chemotherapy initiation (22 versus 32 days,  $p < .0001$ ), 40 days seems to be the gold-standard time-interval to be respected prior to starting adjuvant carboplatin-paclitaxel-bevacizumab chemotherapy. In our series, the median time to start chemotherapy of 42 days suggests that HIPEC addition does not influence the ideal time to start chemotherapy.

As far as the combination of HIPEC and bevacizumab in ovarian cancer, our data are consistent with the recent paper by Gouy et al. [28] which demonstrated that bevacizumab maintenance treatment could be safely completed on around one-third of patients, with six cycles of carboplatin-paclitaxel-chemotherapy followed by IDS and HIPEC. Interestingly, this percentage is completely in line with results from the GOG-0218 and ICON-7 trial, suggesting that even an aggressive multimodal approach combining neoadjuvant chemotherapy (NACT), IDS and HIPEC does not affect the chance of successfully complete bevacizumab-maintenance therapy without enhanced toxicities [6,7].

At present, there is still no consensus in the actual indication to perform HIPEC in ovarian cancer. Despite several studies seems suggest a benefit of HIPEC treatment in ovarian cancer and new technologies are now available [29], no conclusions can yet be drawn. This is due to several limitations and biases of the studies available, which consist of small single institution and not homogeneous series utilizing different drug dosage/schedule and time of exposure in different clinical settings. Recent results of a randomized phase III study suggested that HIPEC at IDS might improve survival of patients undergoing neoadjuvant chemotherapy [8].

Moreover, while waiting for the conclusion of several other randomized trials currently in progress (HORSE NCT01539785, CHORINE NCT01628380 and MMC 2014 NCT02124421), one RCT [8] and one case-control [13] study suggest a potential role of HIPEC in the improvement of patient prognosis at Interval debulking surgery and recurrent ovarian cancer, respectively. Finally, in a recent systematic review and meta-analysis of 37 studies in ovarian cancer by Huo et al. [22], the combination of HIPEC with cytoreductive surgery plus adjuvant chemotherapy, showed significantly better survival compared with cytoreductive surgery plus adjuvant chemotherapy alone. The improved results were reported both for upfront and recurrent settings.

Furthermore, the benefit of HIPEC would continue for 2–8 years after the procedure.

In conclusion, our data suggest that HIPEC can be safely introduced in the upfront therapy of AEOC consisting of primary debulking surgery and carbo-taxol-bevacizumab chemotherapy. On this basis, phase III randomized studies will now be needed to evaluate the prognostic impact of HIPEC in ovarian cancer management.

## Disclosure statement

No potential conflict of interest was reported by the authors.

## Funding

This work was supported by Actagroup srl.

## ORCID

Stefano Cianci  <http://orcid.org/0000-0002-0548-9891>

## References

- [1] Ledermann JA, Raja FA, Fotopoulou C, et al. Newly diagnosed and relapsed epithelial ovarian carcinoma: ESMO Clinical Practice Guidelines for diagnosis, treatment and follow-up. *Ann Oncol.* 2013;24(Suppl 6):vi24–vi32. Available from: [http://www.esmo.org/Guidelineshttp://www.nccn.org/professionals/physician\\_gls/pdf/ovarian.pdf](http://www.esmo.org/Guidelineshttp://www.nccn.org/professionals/physician_gls/pdf/ovarian.pdf)
- [2] Aletti GD, Dowdy SC, Gostout BS, et al. Aggressive surgical effort and improved survival in advanced-stage ovarian cancer. *Obstet Gynecol.* 2006;107:77–85.
- [3] Bristow RE, Tomacruz RS, Armstrong DK, et al. Survival effect of maximal cytoreductive surgery for advanced ovarian carcinoma during the platinum era: a meta-analysis. *JCO.* 2002;20:1248.
- [4] Tozzi R, Giannice R, Cianci S, et al. Neo-adjuvant chemotherapy does not increase the rate of complete resection and does not significantly reduce the morbidity of Visceral-Peritoneal Debulking (VPD) in patients with stage IIIC-IV ovarian cancer. *Gynecol Oncol.* 2015;138:252–258.
- [5] Gueli Alletti S, Vizzielli G, Lafuenti L, et al. Single-institution propensity-matched study to evaluate the psychological effect of minimally invasive interval debulking surgery vs standard laparotomic treatment: from body to mind and back. *J Minim Invasive Gynecol.* 2018;25:816–822.
- [6] Oza AM, Cook AD, Pfisterer J, et al. Standard chemotherapy with or without bevacizumab for women with newly diagnosed ovarian cancer (ICON7): overall survival results of a phase 3 randomised trial. *Lancet Oncol.* 2015;16:928–936.
- [7] Monk BJ, Huang HQ, Burger RA, et al. Patient reported outcomes of a randomized, placebo-controlled trial of bevacizumab in the front-line treatment of ovarian cancer: a Gynecologic Oncology Group Study. *Gynecol Oncol.* 2013;128:573–578.
- [8] Driel WJ, Koole SN, Sikorska K, et al. Hyperthermic intraperitoneal chemotherapy in ovarian cancer. *N Engl J Med.* 2018;378:230–240.
- [9] Ryu KS, Kim JH, Ko HS, et al. Effects of intraperitoneal hyperthermic chemotherapy in ovarian cancer. *Gynecol Oncol.* 2004;94:325–332.
- [10] Deraco M, Kusamura S, Virzi S, et al. Cytoreductive surgery and hyperthermic intraperitoneal chemotherapy as upfront therapy for advanced epithelial ovarian cancer: multi-institutional phase-II trial. *Gynecol Oncol.* 2011;122:215–220.



- [11] Di Giorgio A, Naticchioni E, Biacchi D, et al. Cytoreductive surgery (peritonectomy procedures) combined with hyperthermic intraperitoneal chemotherapy (HIPEC) in the treatment of diffuse peritoneal carcinomatosis from ovarian cancer. *Cancer*. 2008;113:315–325.
- [12] Chua TC, Robertson G, Liauw W, et al. Intraoperative hyperthermic intraperitoneal chemotherapy after cytoreductive surgery in ovarian cancer peritoneal carcinomatosis: systematic review of current results. *J Cancer Res Clin Oncol*. 2009;135:1637–1645.
- [13] Fagotti A, Costantini B, Petrillo M, et al. Cytoreductive surgery plus HIPEC in platinum-sensitive recurrent ovarian cancer patients: a case-control study on survival in patients with two year follow-up. *Gynecol Oncol*. 2012;127:502–505.
- [14] Petrillo M, De Iaco P, Cianci S, et al. Long-term survival for platinum-sensitive recurrent ovarian cancer patients treated with secondary cytoreductive surgery plus hyperthermic intraperitoneal chemotherapy (HIPEC). *Ann Surg Oncol*. 2016;23:1660–1665.
- [15] Fagotti A, Paris I, Grimalizzi F, et al. Secondary cytoreduction plus oxaliplatin-based HIPEC in platinum-sensitive recurrent ovarian cancer patients: a pilot study. *Gynecol Oncol*. 2009; 113:335–340.
- [16] Fagotti A, Costantini B, Vizzielli G, et al. HIPEC in recurrent ovarian cancer patients: morbidity-related treatment and long-term analysis of clinical outcome. *Gynecol Oncol*. 2011;122:221–225.
- [17] Fagotti A, Costantini B, Gallotta V, et al. Minimally invasive secondary cytoreduction plus HIPEC versus open surgery plus HIPEC in isolated relapse from ovarian cancer: a retrospective cohort study on perioperative outcomes. *J Minim Invasive Gynecol*. 2015;22:428–432.
- [18] Vizzielli G, Costantini B, Tortorella L, et al. A laparoscopic risk-adjusted model to predict major complications after primary debulking surgery in ovarian cancer: A single-institution assessment. *Gynecol Oncol*. 2016;142:19–24.
- [19] Fagotti A, Ferrandina G, Fanfani F, et al. A laparoscopy-based score to predict surgical outcome in patients with advanced ovarian carcinoma: a pilot study. *Ann Surg Oncol*. 2006;13:1156–1161.
- [20] Oken MM, Creech RH, Tormey DC, et al. Toxicity and response criteria of the Eastern Cooperative Oncology Group. *Am J Clin Oncol*. 1982;5:649–655.
- [21] Cockcroft DW, Gault MH. Prediction of creatinine clearance from serum creatinine. *Nephron*. 1976;16:31–41.
- [22] Huo YR, Richards A, Liauw W, et al. Hyperthermic intraperitoneal chemotherapy (HIPEC) and cytoreductive surgery (CRS) in ovarian cancer: a systematic review and meta-analysis. *Eur J Surg Oncol*. 2015;41:1578–1589.
- [23] Simon R. Optimal two-stage designs for phase II clinical trials. *Control Clin Trials*. 1989;10:1–10.
- [24] Karam A, Ledermann JA, Kim JW, et al. Fifth Ovarian Cancer Consensus Conference of the Gynecologic Cancer InterGroup: first-line interventions. *Ann Oncol*. 2017;28:711–717.
- [25] Issels RD. Hyperthermia adds to chemotherapy. *Eur J Cancer*. 2008;44:2546–2554.
- [26] Mahner S, Eulenburger C, Staehle A, et al. Prognostic impact of the time interval between surgery and chemotherapy in advanced ovarian cancer: analysis of prospective randomised phase III trials. *Eur J Cancer*. 2013;49:142–149.
- [27] Duska LR, Java JJ, Cohn DE, et al. Risk factors for readmission in patients with ovarian, fallopian tube, and primary peritoneal carcinoma who are receiving front-line chemotherapy on a clinical trial (GOG 218): an NRG oncology/gynecologic oncology group study (ADS-1236). *Gynecol Oncol*. 2015;139:221–227.
- [28] Gouy S, Ferron G, Glehen O, et al. Results of a multicenter phase I dose-finding trial of hyperthermic intraperitoneal cisplatin after neoadjuvant chemotherapy and complete cytoreductive surgery and followed by maintenance bevacizumab in initially unresectable ovarian cancer. *Gynecol Oncol*. 2016;142:237–242.
- [29] Cianci S, Vizzielli G, Fagotti A, et al. A novel HIPEC technique using hybrid CO<sub>2</sub> recirculation system: intra-abdominal diffusion test in a porcine model. *Updates Surg*. 2018. DOI:10.1007/s13304-018-0557-x