



POINT OF VIEW

How to map persistent atrial fibrillation and increase efficacy of ablation therapy



Carlo Pappone

I.R.C.C.S. Policlinico San Donato, Milan, Italy

Available online 9 November 2017

During the last decade trans-catheter ablation of atrial fibrillation (AF) represented a valid alternative to pharmacologic treatment in symptomatic patients with refractory AF. Most trials addressed patients with paroxysmal AF and preserved left ventricular ejection fraction (LVEF). The results have confirmed trans-catheter ablation as very effective in reducing the arrhythmia recurrence. Unfortunately, many other patients, particularly those with chronic heart failure, are affected with persistent AF, which may be frequently refractory to pharmacologic and/or electrical cardioversion. The many studies available in the literature for patients with persistent AF, substantiate that the success of the ablation procedure (pulmonary veins isolation with or without substrate extension) is highly variable and inferior to the results reported for paroxysmal AF.

The wide variability of the results could stem from several factors, such as different ablation techniques, arrhythmia duration, structural heart disease, age, sex, and/or operator experience. Our data published in 2006 in *New England Journal of Medicine* demonstrated, for the first time, that our technique (CPVA), not limited to pulmonary vein isolation, was superior to amiodarone in patients with chronic AF. The demonstration that the ablation technique was able to reestablish stable sinus rhythm in patients with chronic AF should not be underestimated, considering the significant socio-economic advantages deriving from a sharp

reduction of hospitalization and mortality, particularly in patients with heart failure. In fact, reestablishing stable sinus rhythm improves left ventricular function, exercise tolerance, symptoms and quality of life in an increasing aging population.

During the last three years we have created a dedicated software which allows, with tridimensional electro-anatomic mapping, to identify one or more areas, defined as "rotors", which individually and simultaneously, like a small gyration, unload regular sequential electrical impulses at very high velocity, able to sustain and perpetuate the arrhythmia in time. In patients with paroxysmal AF the rotors are usually localized in a highly variable number around the pulmonary veins. In patients with persistent AF the "rotors", could localize everywhere, even in the right atrium, and once localized with echography, they are sequentially ablated starting from the faster and more regular (Figure 1). During radiofrequency release, it is often noted a lengthening of the cycle before return to sinus rhythm. The procedural time, including mapping and ablation, are not long, but often exceed 60 minutes regardless the type of AF. When the presence of the "rotors" is the mechanism for persistent AF, regardless its clinical presentation, their identification and elimination may represent the true target of every ablation technique (Figure 1). In our experience, based on 500 patients with chronic persistent AF, the number of "rotors" varies considerably both in number and in location, and their complete elimination is associated with return to sinus rhythm in almost all patients, 80% of

E-mail address: carlo.pappone@grupposandonato.it

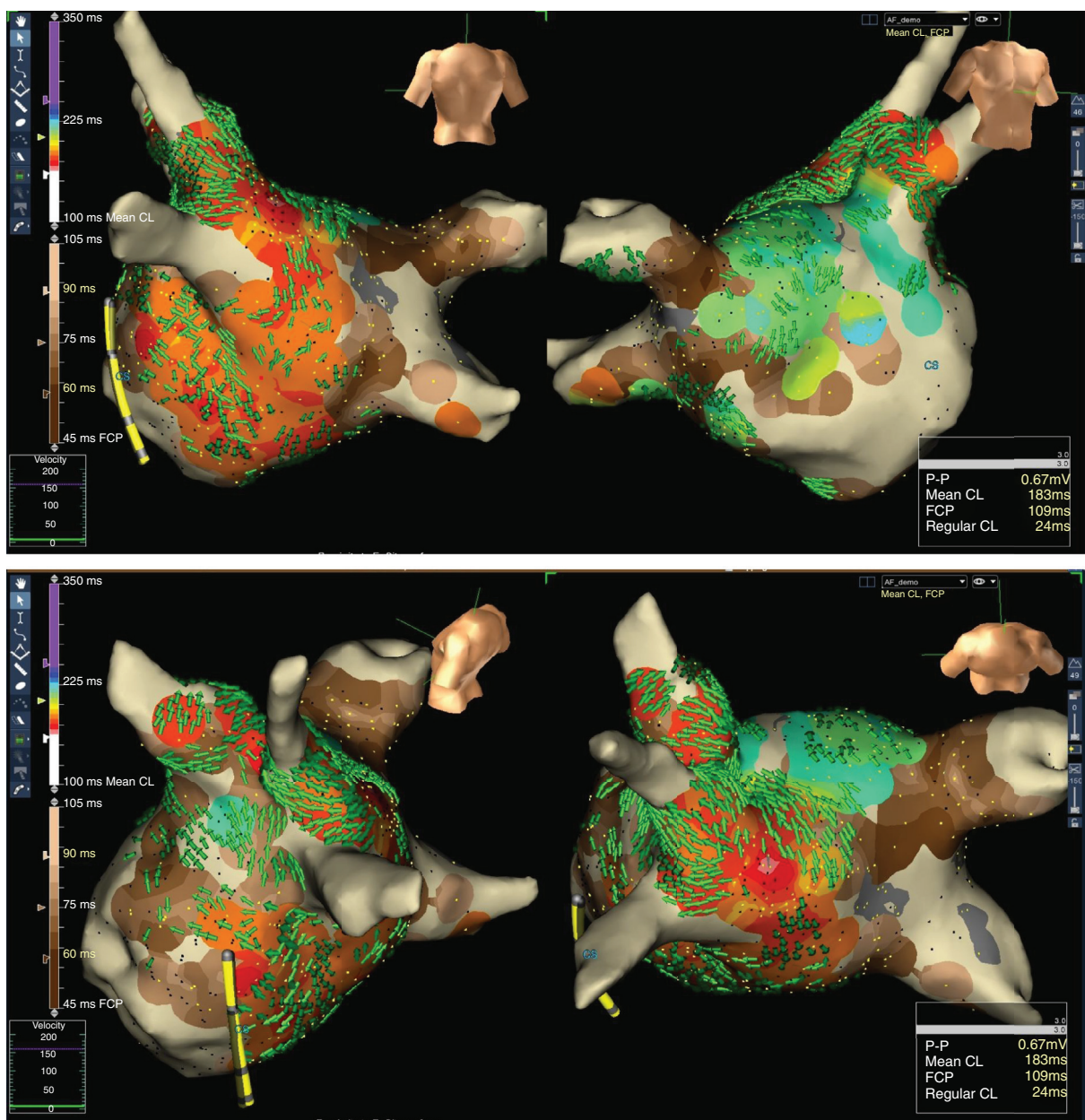


Figure 1 Integrated AF mapping technique:

In top panel PA and AP views, whereas in bottom panel left-lateral and cranial posterior views.

According to the Regular Cycle Length Map, the regions showing fast and regular activities are depicted in rainbow spectrum. The red/orange area represents region exhibiting the faster and most regular activities, while the green/blue area shows on the anterior septum another region with a relatively slower mean cycle length. Fractionated Map (brown spectrum), Voltage Map (low voltage in grey) and Conduction Velocity map (green 3D arrows) are also integrated.

This Map finally shows the dominant fast and regular activity in the roof (bottom panel) with a rotational activation pattern spreading to left-sided PVs and postero-inferior wall of the LA as demonstrated by the green arrows. Secondary activity is located at the septum (light-blue). The fast and regular regions are all surrounded by the irregular fragmented zones.

whom maintain it at 12 months after a single uncomplicated procedure.