

IMAGE IN CARDIOLOGY

An esophageal lymphoma discovered by echocardiography



Um linfoma esofágico descoberto por ecocardiografia

Raffaele Pellecchia^a, Giordano Zampi^{a,*}, Amedeo Pergolini^b, Luigi Sommariva^a

^a Department of Cardiology, Belcolle Hospital, Viterbo, Italy

^b Department of Cardiovascular Science, "S. Camillo-Forlanini" Hospital, Rome, Italy

Received 8 August 2015; accepted 22 November 2015

In this Image in Cardiology we describe the case of a lymphoma of the esophagus discovered by transthoracic echocardiography.

A 50-year-old Caucasian male was referred to our echocardiography laboratory complaining of epigastric pain and exertional dyspnea. Standard transthoracic echocardiography showed an ovoid, heterogeneous mass measuring about 4 cm×2 cm extending between the left atrium and the descending aorta (Figure 1a and b, Movie clip 1), not causing compression of the left atrium or the pulmonary veins.

Total body computed tomography with iodinated contrast was promptly performed, which showed a hypodense lesion, measuring about 7 cm, of a thickened (about 3 cm) distal esophagus (Figure 1c and d), accompanied by enlarged satellite lymph nodes.

Significant narrowing of the distal esophagus was also revealed by Gastrografin swallow.

Endoscopic examination was performed showing an ulcerated mass with circumferential growth constricting the distal third of the esophageal lumen. Multiple biopsies were

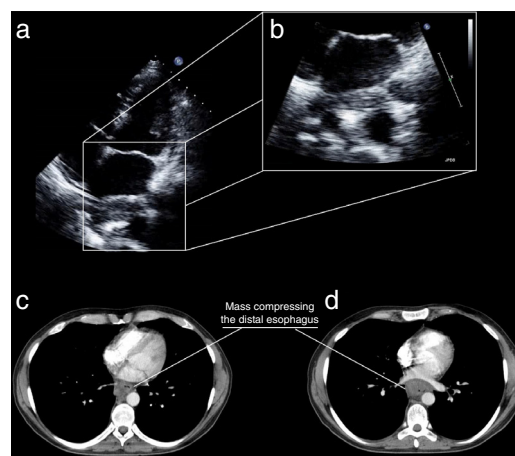


Figure 1 Top: transthoracic echocardiography, (a) apical 4-chamber view showing a mass to the rear of the left atrium and (b) zoom view on the mass; bottom: computed tomography of the chest, axial view, showing a mass constricting the distal esophagus.

* Corresponding author.

E-mail address: giordano.zampi@alice.it (G. Zampi).

obtained and histologic examination showed large, atypical lymphoid cells positive for CD30 and ALK.

The mass was accordingly diagnosed as a primary anaplastic large cell lymphoma of the esophagus.

Ethical disclosures

Protection of human and animal subjects. The authors declare that no experiments were performed on humans or animals for this study.

Confidentiality of data. The authors declare that no patient data appear in this article.

Right to privacy and informed consent. The authors declare that no patient data appear in this article.

Conflicts of interest

The authors have no conflicts of interest to declare.

Acknowledgments

We are grateful to sonographer Chiadon Secka, who performed the transthoracic echocardiography.

Appendix A. Supplementary material

Supplementary material associated with this article can be found in the online version at [doi:10.1016/j.repc.2015.11.022](https://doi.org/10.1016/j.repc.2015.11.022).