

Hydroxychloroquine in Psoriasis: Is it Really Harmful?

Stefania Sorbara, Emanuele Cozzani, Alfredo Reborá and Aurora Parodi

DiSEM Section of Dermatology, University of Genoa, Viale Benedetto XV, no. 7, IT-16132 Genoa, Italy. E-mail: aurora.parodi@unige.it
Accepted April 20, 2006.

Sir,

Antimalarial drugs are well known to be contraindicated in psoriasis (1). In particular, when utilized in psoriatic arthropathy, they have been reported to induce pustular eruption (2), erythroderma (3) and pustular psoriasis (4). We report here a patient with psoriasis and subacute cutaneous lupus erythematosus (SCLE) who was treated successfully with hydroxychloroquine. A critical review of the literature casts some doubts on the contraindication of antimalarials in psoriasis.

CASE REPORT

A 66-year-old woman had vitiligo for 40 years and psoriasis for 30 years with lesions localized on the extensory face of her elbows. The patient had treated the psoriatic plaques with emollients with some benefit. In March 2002, she began to suffer from arthralgia of the wrists and hands. At the same time the psoriatic lesions became more inflamed and larger. Because of a positive rheumatoid test, she was diagnosed as having rheumatoid arthritis (RA) and given 7.5 mg/day prednisone and 10 mg/week methotrexate. The arthralgia improved, but the psoriatic lesions did not.

In September 2002, still on the same doses of methotrexate and prednisone, she developed, after sun exposure, prurient annular erythematous lesions on the trunk, arms and face. At physical examination, the patient exhibited erythematodesquamative lesions, recalling psoriasis, on the extensor surface of the elbows, and annular papulo-erythematous areas with scales and a hypopigmented central zone on the trunk and forearms (Fig. 1). Vitiliginous patches were also present on the upper arms, armpits and genitalia.

Biopsies were taken of two types of lesions, the one recalling psoriasis and the annular one on the forearms. The histology of the former showed hyperparakeratosis with psoriasis-like hyperplasia of the epidermis and a perivascular lymphocyte infiltrate in the upper dermis, confirming the diagnosis of psoriasis. On

the annular lesion of the forearms, however, a vacuolar interface dermatitis was observed at the dermal-epidermal junction, with focal acanthosis, keratinocyte necrosis and a lymphocyte infiltrate (Fig. 2). Moreover, direct immunofluorescence revealed granular deposits of IgG and complement C₃ at the dermal-epidermal junction. The clinical, histological and immunological features suggested a diagnosis of SCLE. Antinuclear antibodies (ANA) were positive (IgG with a speckled pattern at the final titre of 1/80). Rheumatoid factor was repeatedly absent. Cyclosporine, 75 mg/day, was added, but 3 months later, arthralgia, psoriasis and SCLE lesions worsened, and cyclosporine was increased to 100 mg/day and prednisone to 12.5 mg/day. This therapy did not improve the psoriatic lesions and 6 months later SCLE lesions had again worsened. ANA were still positive in indirect immunofluorescence (IgG 1/80, and IgM 1/40 speckled pattern), anti-SSA/Ro antibodies were positive in contra-immunoelectrophoresis (1/8) and rheumatoid factor turned positive (34.5 UI/ml, normal value <20).

Radiography of the hands and wrists showed bilateral arthrosis and osteoporosis without any sign of erosive lesions typical of RA. Cyclosporine was stopped and hydroxychloroquine (400 mg/day) introduced. After a few weeks the SCLE lesions improved and so did arthralgia and psoriatic lesions, which became less inflamed and reduced in size. One month later, hydroxychloroquine was reduced to 200 mg/day, methotrexate was stopped and prednisone reduced to 5 mg/day. SCLE lesions disappeared while arthralgia improved. Psoriasis lesions almost vanished.

DISCUSSION

There are two interesting points about this patient: the association of the two diseases and the beneficial effect of hydroxychloroquine on both of them.

Psoriasis has been said to associate with other autoimmune dermatological diseases in 0.74% of cases (5). Its coexistence with lupus erythematosus (LE) is,

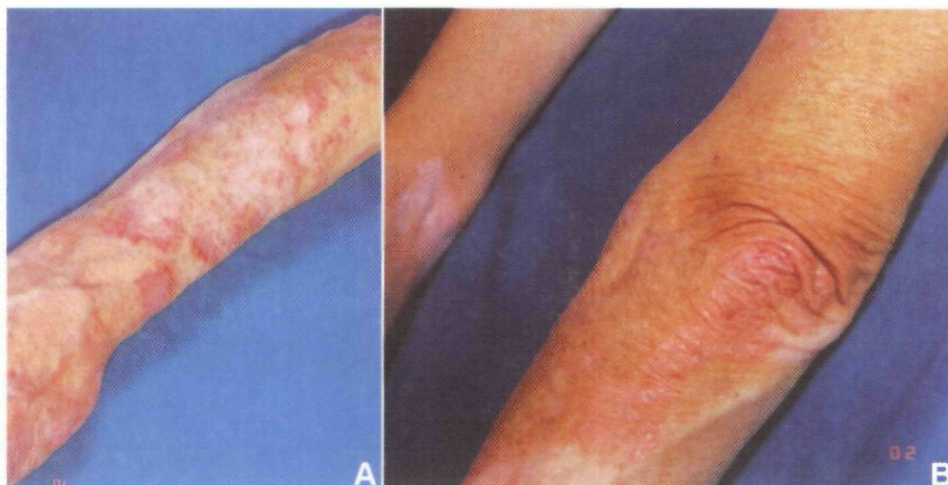

Fig. 1. Annular papulo-erythematous areas with (A) scales and a hypopigmented central zone, and (B) erythematodesquamative lesions recalling psoriasis and vitiliginous patches.

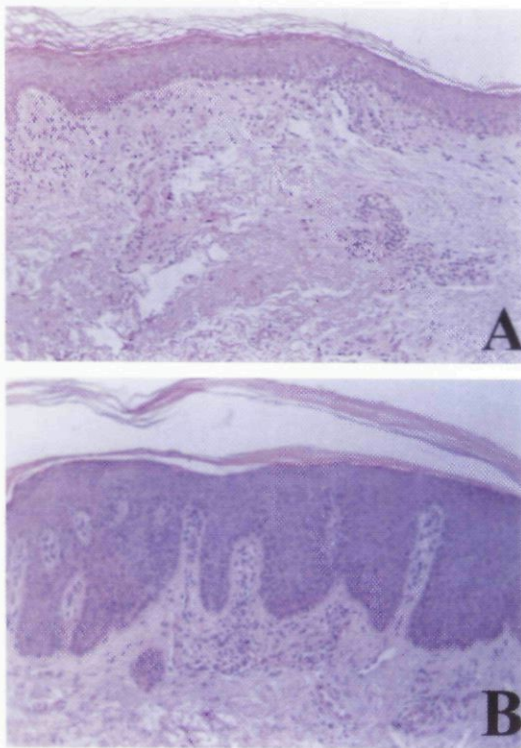


Fig. 2. Histological aspects of skin specimens taken from (A) annular lesion on the forearm, and (B) from a psoriasiform lesion. (A) Vacuolar interface dermatitis at the dermal-epidermal junction, with focal acanthosis, keratinocyte necrosis and a lymphocyte infiltrate and (B) hyperparakeratosis with psoriasis-like hyperplasia of the epidermis and a perivascular lymphocyte infiltrate in the upper dermis.

however, rare (6–8), accounting for 1.1% in patients with LE (4).

Different LE forms have been found associated with psoriasis: Millens & Muller (6) studied 27 patients in whom LE and psoriasis were associated and found that 48% of them had discoid lesions, 37% systemic LE and 15% SCLE. Psoriatic lesions antedated LE in 50% of cases, as occurred in our case, while they developed simultaneously in 38% and followed LE in 12% of cases. In our patient we also take into consideration a possible diagnosis of drug-induced SCLE. However, the patient had not been taking photosensitive drugs, such as non-steroidal anti-inflammatory drugs or diuretics. Methotrexate has been reported to cause photosensitivity reactions in 5–6% of the patients (9); however, it is not in the list of SCLE drug inducers.

The association with a third disease, such as autoimmune haemolytic anaemia, RA, Hashimoto's thyroiditis, gout and porphyria cutanea tarda, was also reported (6). Our case also had vitiligo. In our patient's history, she was diagnosed as having RA only because of a positive rheumatoid factor, but X-ray failed to reveal erosive lesions. Although the associations SCLE/RA and LE/RA/psoriasis have been reported in literature (10), we favour the hypothesis that the positive rheumatoid factor was simply part of LE immunological disorder.

The management of these patients is difficult, as psoriasis benefits from sun exposure, which is harmful in LE, and systemic corticosteroids, indicated in LE, may produce severe psoriasis rebounds. It is known that antimalarial drugs that are helpful in LE are contraindicated in psoriasis (1). This old concept is supported by the recent study of Wolf et al. (11), who demonstrated that hydroxychloroquine induces hyperproliferation and irregular keratinization in cultured skin of psoriatic patients.

Case reports of pustular eruption (2), erythroderma (3) and pustular psoriasis (4) have been described with the use of hydroxychloroquine in psoriatic arthropathy, but in a larger study no exacerbation of psoriatic skin lesions was observed (12). The clinical experience has been nicely summarized by Baker (13) who concluded that although antimalarials "have sometimes been responsible for serious aggravation of psoriasis, this is far from being a constant phenomenon". Our patient seems to confirm such a conclusion.

REFERENCES

1. Cornbleet T. Action of synthetic antimalarial drugs on psoriasis. *J Invest Dermatol* 1956; 26: 435–436.
2. Lotem M, Ingber A, Segal R, Sandbank M. Generalized pustular drug rash induced by hydroxychloroquine hydroxychloroquine. *Acta Derm Venereol* 1990; 70: 250–251.
3. Slagel GA, James WD. Plaquenil-induced erythroderma. *J Am Acad Dermatol* 1985; 12: 857–862.
4. Vine JE, Hymes SR, Warner NB, Cohen PR. Pustular psoriasis induced by hydroxychloroquine: a case report and review of the literature. *J Dermatol* 1996; 23: 257–261.
5. Poljack M, Begenesic M, Duran V, Matovic L, Matic M, Janovic M, et al. Psoriasis and autoimmune skin disorders. *Med Pregl* 2002; 55: 325–328.
6. Millens JL, Muller SA. The coexistence of psoriasis and lupus erythematosus. An analysis of 27 cases. *Arch Dermatol* 1980; 116: 658–663.
7. Hays SB, Camisa C, Luzar MJ. The coexistence of lupus erythematosus and psoriasis. *J Am Acad Dermatol* 1984; 10: 619.
8. Zalla MJ, Muller SA. The coexistence of psoriasis with lupus erythematosus and other photosensitive disorders. *Acta Derm Venereol Suppl* 1996; 195: 1–15.
9. Roenigk HH, Fowler-Bergfeld W, Curtis GH. Methotrexate for psoriasis in weekly oral doses. *Arch Dermatol* 1969; 99: 86–93.
10. Pantoja L, Gonzales-Lopez MA, Bouso M, Alija A, Ortiz-Saracho J. Subacute cutaneous lupus erythematosus in a patient with rheumatoid arthritis. *Scand J Rheumatol* 2002; 31: 377–379.
11. Wolf R, Lo Schiavo A, Lombardi ML, De Angelis F, Ruocco V. The in vitro effect of hydroxychloroquine on skin morphology in psoriasis. *J Invest Dermatol* 1999; 38: 154–157.
12. Kammer GM, Soter NA, Gibson DJ, Schur PH. Psoriatic arthritis: a clinical, immunologic and HLA study of 100 patients. *Semin Arthritis Rheum* 1979; 9: 75–97.
13. Baker H. The influence of chloroquine and related drugs on psoriasis and keratoderma blenorrhagicum. *Br J Dermatol* 1966; 78: 161–166.

Copyright of Acta Dermato-Venereologica is the property of Society for Publication of Acta Dermato-Venereologica and its content may not be copied or emailed to multiple sites or posted to a listserv without the copyright holder's express written permission. However, users may print, download, or email articles for individual use.