

Bruno Bordoni, DO, PhD and Allan R. Escher,* Jr., DO

Functional evaluation of the diaphragm with a noninvasive test

<https://doi.org/10.1515/jom-2021-0101>

Received April 6, 2021; accepted May 25, 2021;

published online September 14, 2021

Abstract: Cardiac surgery with median sternotomy causes iatrogenic damage to the function of the diaphragm muscle that is both temporary and permanent. Myocardial infarction itself causes diaphragmatic genetic alterations, which lead the muscle to nonphysiological adaptation. The respiratory muscle area plays several roles in maintaining both physical and mental health, as well as in maximizing recovery after a cardiac event. The evaluation of the diaphragm is a fundamental step in the therapeutic process, including the use of instruments such as ultrasound, magnetic resonance imaging (MRI), and computed axial tomography (CT). This article reviews the neurophysiological relationships of the diaphragm muscle and the symptoms of diaphragmatic contractile dysfunction. The authors discuss a scientific basis for the use of a new noninstrumental diaphragmatic test in the hope of stimulating research.

Keywords: breathing test; cardiopulmonary medicine; cardiothoracic surgery; diaphragm; osteopathic; phrenic nerve; sternotomy; vagus nerve.

Cardiothoracic surgery is always evolving, with tools and techniques in constant revision, such as robotic and video-assisted thorascopic surgery (VATS) [1, 2]. Despite the progressive improvement of the surgical approach, the patient is subject to risks during and after the surgery. Some of the major morbidities include wound infections, sternal instability, renal failure (acute or chronic), and stroke [3, 4]. Other potential long-term comorbidities are post-sternotomy pain syndrome (PSPS), with an incompletely understood etiology,

and postoperative cognitive dysfunction (POCD) for different brain events [5, 6]. Another iatrogenic event of cardiac surgery is damage to the functionality of the diaphragm muscle, for which, depending on the clinical indication, the surgeon may resort to diaphragmatic plication [7].

Diaphragm dysfunction can lengthen hospitalization times, with support in some patients by assisted mechanical ventilation, oxygen therapy, and nocturnal continuous positive airway pressure (CPAP) [8, 9]. Generally, iatrogenic damage to the diaphragm is attributed to injury to the phrenic nerve, reaching as high as 73% for the left phrenic nerve [10, 11]. Iatrogenic damage may also lead to vascular injury (in particular, to the internal mammary artery), which can potentially result in structural and functional changes in the diaphragm [10]. Iatrogenic effects may arise from cardiac surgery, such as harvesting the left internal mammary artery for bypass, which increases the risk of phrenic injury, or from purely mechanical mechanisms, such as pulling the retractor to open the sternum or ribs [11]. Hypothermia during surgery is another risk, as is electrocautery; such procedures increase the risk of trauma to the diaphragm [11].

Recently, genetic causes or adaptations not necessarily linked to the aforementioned effects, shed new light on the morphological adaptation of the diaphragm muscle in the postsurgical setting or in the presence of myocardial infarction. A study of mice undergoing thoracotomy compared with control mice, which were not operated on but with myocardial ischemia induced, revealed the presence of genetic alterations [12]. Some genes responsible for synaptic stabilization and acetylcholine release were downregulated, whereas other genes that influence myelin structure and the management of membrane depolarization were upregulated [12]. As for the structure of the diaphragm muscle, several proteins that form the contractile structure were downregulated, causing contractile dysfunction and a functional alteration similar to muscle tissue in elderly people [12]. Surgery not only puts the function of the diaphragm muscle at risk but also the presence of a heart attack in the absence of surgery [12]. Currently, we have no other data on younger patients or on animal models that reflect a younger age.

*Corresponding author: Allan R. Escher, Jr., DO, Anesthesiology/Pain Medicine, H. Lee Moffitt Cancer Center and Research Institute, 12902 USF Magnolia Drive, Tampa, FL 33612-9416, USA, E-mail: allan.escher@moffitt.org

Bruno Bordoni, DO, PhD, Foundation Don Carlo Gnocchi IRCCS, Department of Cardiology, Institute of Hospitalization and Care with Scientific, Milan, Italy

Invasive procedures, separately from cardiothoracic surgery, can damage the phrenic nerve. Radiofrequency catheter ablation due to the presence of atrial fibrillation or other arrhythmic problems, could cause iatrogenic damage to the phrenic nerve; the possible mechanisms are related to the heat generated and the electromagnetic field, which may negatively affect the phrenic nerve [13]. Percutaneous transluminal angioplasty with stent placement for the subclavian artery, could be a risk for hemiplegic damage to the phrenic nerve, yet the reasons are not clear [14]. This article briefly reviews the anatomic-neurological path of the diaphragm muscle and poses a hypothesis of utilizing a noninstrumental functional test of the same contractile area. The ultimate goal is to easily and quickly take advantage of an evaluation of the respiratory muscle as the first screening following cardiac surgery, myocardial infarction, or other hemodynamic approaches.

Neurological network of the diaphragm muscle

Central pattern generator (CPG) is involved in the eupneic action, and such neurological structures include the areas between the brain stem and the spinal cord [15]. Eupneic breathing is further divided into specific phases. Pre-inspiration is managed by the pre-Bötzinger complex (pre-BötC); from the brain stem, the preBötC neurons send the impulse of the inhalation, passing through a ramp-like depolarization (100–400 ms) or pre-inspiration [16, 17]. The preBötC sends impulses to the cranial nerve XII during the pre-inspiratory phase to widen the upper respiratory tract; the hyoid portion of the tongue is pushed forward, while the posterior and upper area of the lingual muscular body is pushed downward and posteriorly [18]. Cranial nerve XII also receives impulses from the vagus and phrenic nerves [19]. When the preBötC neurons reach full depolarization, the inhalation phase begins; this depolarization is influenced by other centers, such as the cerebellum, the midbrain, and the cortical and subcortical centers, and by peripheral mechano-metabolic afferents [17].

During the inspiratory phase, the preBötC continues to stimulate the XII and begins to stimulate the bodies of the pre-motor neurons and phrenic motor neurons of the spinal cord; phrenic neurons are also stimulated by the caudal ventral group (VRGc), the rostral ventral group (VRGr), the nucleus tractus solitarius (NTS, also known as the dorsal brain stem neural group [DRG]) and the parabrachial/Kölliker-Fuse complex [20]. The accessory respiratory muscles will be stimulated by preBötC neurons [17]. The eupneic phase following the inhalation is the exhalation, in which Bötzing neurons (VRGc) send inhibitory signals toward the preBötC; the Bötzing neurons (VRGc) will be influenced by the parabrachial/Kölliker-Fuse complex (Pontine

area) [17]. The NTS sends efferents to Bötzing's neural bodies (and to the preBötC) and simultaneously receives afferents from baroreceptors, chemoreceptors, and other information derived from the peripheral mechanisms of respiration (lungs and skeletal muscles) [20]. The vagus nerve is involved when the diaphragmatic area of the esophageal hiatus must be coordinated for the passage of a food bolus; this diaphragmatic area is innervated by the X cranial nerve [19]. Throughout this process, we must not forget the sympathetic system, which has a strong relationship with the subdiaphragmatic and diaphragmatic ganglia and the stellate ganglion; thus, a breathing disorder negatively affects the sympathetic system [21, 22].

This perfect respiratory network can be altered when there is phrenic (and vagus nerve) trauma, such as iatrogenic damage from surgery, as shown in Figure 1.

Location of the phrenic nerve and the vagus nerve

The phrenic nerve (C3–C5) involves the prevertebral fascia of the cervical spine anteriorly, and it runs down in an oblique direction to arrive above and in front of the anterior scalene muscle, which covers the phrenic nerve [21]. Continuing posteriorly, it comes into contact with the omohyoid muscle and the sternocleidomastoid muscle, which has close contact at the level of its insertion at the head of the clavicle laterally, before the phrenic nerve enters the thorax. Before entering the thoracic cavity, the nerve passes anteriorly to the subclavian artery, leaving the subclavian vein posteriorly [21]. The phrenic nerve may have several accessory nerves at the thoracic outlet, which may envelop the subclavian vein and the internal thoracic artery, or the nerve could become a constituent part of the cardiac plexus [21]. Inside the thorax, it contacts the pulmonary parietal pleura and the parietal pericardium to come into contact with the diaphragm muscle. The right nerve, in its passage, has a preferential relationship with the anatomical area of the right atrium and with the right mammary artery, and it will penetrate the diaphragm in its connective portion. The right phrenic nerve has an important relationship with the superior and inferior vena cava and the superior pulmonary vein. The left phrenic nerve, which is longer, touches the area of the left ventricle and the left mammary artery, passes beyond the pulmonary trunk, and it will penetrate the contractile area of the diaphragm [21].

The phrenic nerve continues beyond the diaphragm muscle until it involves other structures, such as the apex of the stomach, the area of the Glisson's capsule, the parietal peritoneum that involves the gallbladder, and the celiac and superior aorticorenal ganglia up to the suprarenal gland [21]. The vagus nerve or cranial nerve X exits

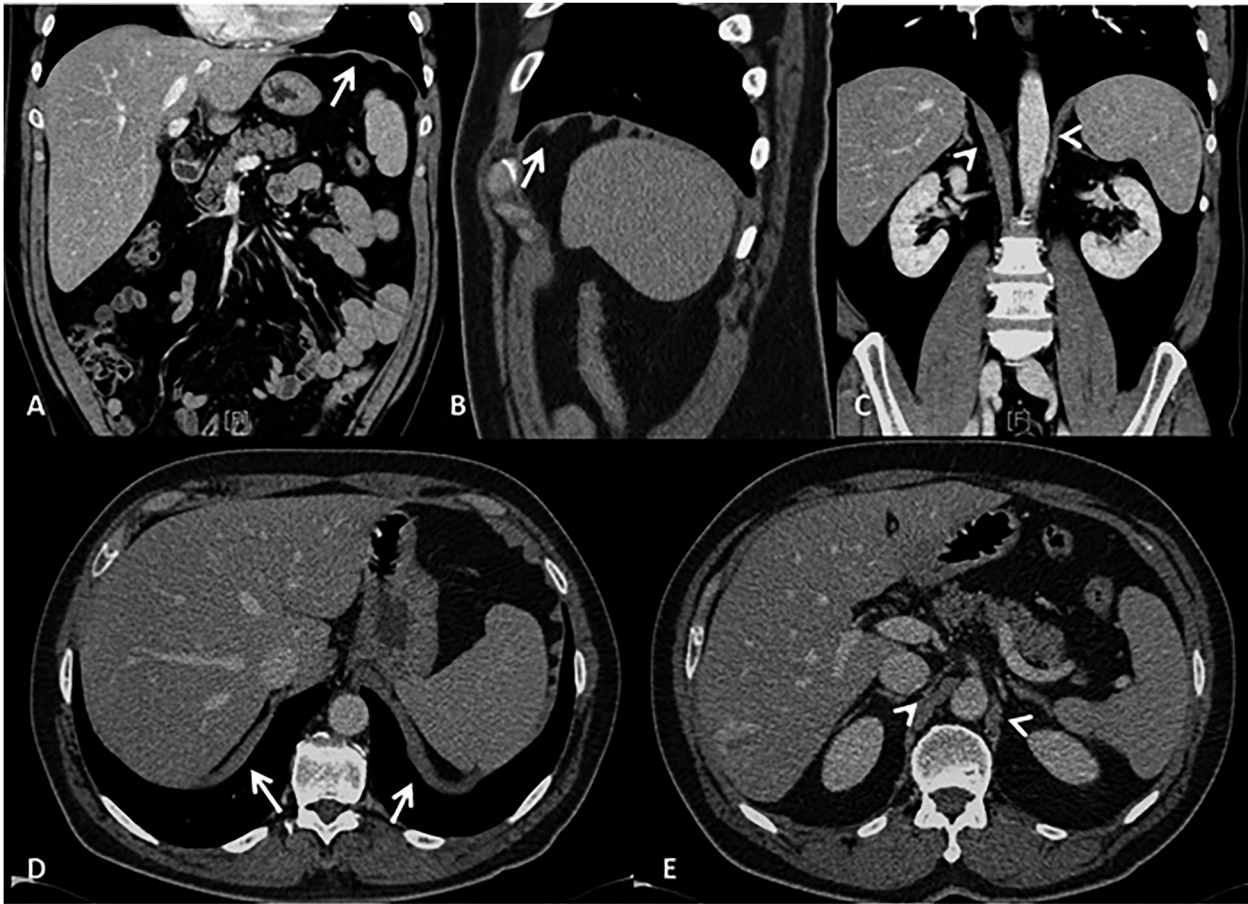


Figure 1: The CT images in the coronal and axial planes allow visualization of the diaphragm as a hyperdense linear band interposed between the chest and the abdominal cavity (A and D, respectively; see arrows). Sagittal images highlight a type of “corrugated” morphology that shows the orientation of the muscle bundles (B; see arrow), which may appear more or less pronounced in wellness or pathologic conditions, such as COPD. Clearly, visible diaphragmatic pillars also appear in both the coronal plane (C) and the axial plane (E) (arrowheads) [7].

the jugular foramen to travel with the carotid fascia and the jugular vein; before entering the chest, it forms a loop with the right subclavian artery. Entering the thoracic cavity, it creates a recurrent branch on the left, which passes under a fascial structure (arterial ligament) between the aortic arch and the pulmonary artery; in the chest, it will contact all the viscera [21]. At the diaphragmatic level, it will penetrate and innervate the esophageal hiatus, including Lamier’s ligaments, to pass the muscle and project toward the viscera of the abdomen and the sympathetic ganglia [21].

Clinical summary

Symptoms and instrumental evaluation

Symptoms resulting from a phrenic or vagal injury will depend not only on the surgeon’s work but also on the

patient’s anatomical variability and the relevant clinical history. The patient may be symptomatic and may have dyspnea, dysphagia, chest pain, esophageal disorders, insomnia, and somnolence [10, 23–25]. The patient may display Hoover’s sign for paradoxical breathing and pulmonary function disorders (atelectasis and pleural changes); it should be noted that approximately 10–21% of patients with a phrenic injury will not fully recover [11, 13]. Another problem that can arise is the asymptomatic patient. When the diaphragm muscle does not contract properly, the nervous system tries to reorganize itself by involving the accessory respiratory muscle districts in the motor scheme [26]. We must consider not only an obvious lesion (paresis) but also subclinical contractile dysfunctions. After surgery, the diaphragm decreases its thickness and consequently decreases its contractile capacity, regardless of the presence or absence of paresis [27].

If the patient is subjected to mechanical ventilation or night CPAP after the surgical event, the diaphragm undergoes nonphysiological alterations. In a study of 34 patients, the use of CPAP stimulates the production of a systemic and procholesterolemic inflammatory environment, which are scenarios that are not quickly eliminated once therapy is discontinued [28]. In studies conducted with an animal model and with patients, the same mechanical ventilation can induce phrenic axonal damage, further prolonging a nonphysiological adaptation in the breathing pattern, with possible atrophy of the protein scaffold of the diaphragm [26, 29]. A study of eight patients found that the use of mechanical ventilation during cardiothoracic surgery can weaken the diaphragm with structural and functional changes and, in some cases, lead the patient to assisted ventilation after chest surgery [30]. Other possible subtle symptoms related to diaphragmatic dysfunction are the presence of depression and a decrease in the pain threshold, with neurological reasons related to the diaphragm, as discussed in a previous review article [31].

There are different reasons for finding a weak and potentially inevident diaphragmatic district, as well as different tools for evaluating the diaphragm. One of the immediate instrumental examinations is chest radiography; however, returning to the concept of the patient's asymptomaticity, it is possible to have a diaphragm dysfunction without radiographic signals [10]. If the symptom is very evident, it is generally feasible to find an elevation of a hemidiaphragm, corresponding to the side of the phrenic lesion; in severe cases, both hemidiaphragms are elevated [10]. Other tests that can be performed are ultrasound and fluoroscopy; however, both are difficult to perform in the days following the surgery [10]. With ultrasound, in addition to *in vivo* movement, the diaphragmatic excursion and its thickness can be evaluated; in this way, a possible weakness or paresis of the diaphragm is highlighted [32]. The use of fluoroscopy (sniff test) confirms iatrogenic damage to the diaphragm muscle [10]. To understand if there is neuropraxic damage to the phrenic nerve, the most suitable examination remains the electrophysiological study. We can resort to the use of MRI or CT for a differential diagnosis, that is, to identify diaphragmatic hernias, muscle ruptures, or the presence of neoplastic formations, as shown in Figure 1 [10].

In conclusion, injuries to the glossopharyngeal nerve or ninth cranial nerve are extremely rare and transient. They are probably related to intubation during surgery.

Discussion

Functional evaluation of the diaphragm with a noninvasive test

In the literature, there is a protocol for the manual evaluation of the diaphragm and the use of an evaluation scale (Manual Evaluation Diaphragm [MED] scale) as a tool for dialogue between the various health professionals [33, 34]. A noninstrumental test for the diaphragm muscle that can highlight functional anomalies does not exist. We know that the observation of diaphragmatic behavior during the act of breathing is very indicative evaluation of functional anomalies [26]. What is the rationale for creating a test? The test “asks” the function to express itself. If the functional expression is lacking, the test is indicative of a problem that, if required by the clinical case, will be investigated further. The hypothesis of a noninstrumental test for the diaphragm is based on the neurophysiological information that we have about breathing. A deep inhalation is able to improve motor coordination and muscle strength expressed by approximately 10% more, when compared to eupneic breathing [35]. Forced inspiration activates, bilaterally, the primary motor cortex (area M1), which is also connected to emotional behavior (impulsivity) [35, 36]. Chronic pathologies in which a respiratory disorder is evident are associated with neuro-motor uncoordination [35].

Breathing determines oscillations of the motor cortex (in particular through gamma waves, 40–150 Hz), like a diapason of the neural system; these oscillations allow the increase of synaptogenesis, both in terms of the number of contacts as well as the duration of the same contacts between neurons [35]. This event results in improved peripheral neuromotor coordination. In chronic pathologies, for example, as in patients with chronic obstructive pulmonary disease (COPD) and congestive heart failure (CHF), we know that there is a decreased capacity of neuromotor coordination; one reason is a lower excursion of the diaphragm muscle, whose movement affects the quality of voluntary movement to a lesser extent [35].

Breathing stimulates different systemic receptors, such as baroreceptors, interoceptors, exteroceptors, sending afferents to the cerebellum and vestibular area, and passing through the NTS; the NTS is an important management site for afferents of the diaphragm muscle [37]. The motor movement results from the network formed by the cerebellum, the vestibular area, the motor cortex, and the limbic area, thanks to the receptor information that these areas receive from breathing [37]. This network works better if the

parasympathetic system has better activation than the action of the sympathetic system; breathing stimulates the vagal system to a greater extent and duration [38]. An optimal parasympathetic system allows the recording of a better electromyographic spectrum, with greater strength and muscle coordination [39]. Each breath activates the skin afferents, which stimulate the somatosensory opercular cortical area, which stimulates the vestibular area to control balance [40]. A deep breath improves neuromotor coordination, which allows stability and strength.

The test, which is called the Bordoni diaphragmatic test (BDT), is divided into two parts so that the result of a first pass has an identical response with the second pass. The first phase of the test is similar to the Fukuda Step Test but with the hands resting on the hips to give greater comfort and safety to the patient. The Fukuda test is used in the neurological and otolaryngological fields to evaluate a balance dysfunction. In this case, with the BDT test, we resume the position of the test, but with different objectives and with clearly different execution methods. The BDT is performed with the patient standing and with eyes closed; the patient must rhythmically raise one knee and then the other and, while flexing the thighs, should take inhaled deeply. Two push-ups per lower limb are sufficient, as well as four thigh lifts. This movement stimulates the cerebellar area and the vestibular area; with a deep breath, the neuromotor system linked to the parasympathetic system and the motor cortex is stimulated, in addition to the cerebellum and vestibular area, as described in the article. It should be emphasized that the diaphragm muscle is the main stabilizing muscle of the dorsal lumbar vertebral area; the depth of breathing will be greater and the respiratory functions expressed will be better [41–43]. A wider inhalation movement equates to a greater thickness of the diaphragm muscle, which links to better respiratory function [44]. The test just described is repeated, but without deep breaths, in order to highlight the positive influences of the diaphragm. If one's balance is better with deep breaths than with the same movement without forced inhalation, the diaphragm muscle is correctly situated in a neurophysiological context, so there should be no phrenic or vagal disorders.

The second phase of the test, to reinforce and have a comparison with the previous result, consists of the same position and the same movement with the eyes closed, but includes placing resistance on the knee each time that the patient has to flex the thigh. The operator places a hand on the subject's knee before the subject has performed a complete flexion of the thigh. Finally, the operator will remove his hand from the knee when the patient begins to bring the thigh back to the starting position. The operator will position himself in front of the patient, placing a little pressure on the

knee. The movements, with resistance placed by the operator's hand, are performed first with deep inspiration, for a total of two movements for each lower limb [4]; later, this is repeated with the same context just described but without a deep inspiration. If the force expressed by the flexion of the thigh improves, reflecting the information that we have on neurophysiological relationships, there should not be any diaphragmatic dysfunction, with consistent integration into the body context, as shown in Figure 2).

The BDT is the first noninstrumental test to verify the presence or absence of a diaphragmatic dysfunction, which may result from a phrenic or vagal trauma or from a functional alteration that is not necessarily surgical. The same presence of inflammation, as for example in patients with congestive heart failure, can inhibit phrenic neuroplasticity and alter the heart's function, with a decrease in diaphragmatic contractility; or, systemic inflammation in such patients can create an oxidative environment for DNA, with protein decrease [45–47]. The test is easy to perform, if the patient is able to hold an upright position, and it is a quick test if the subject is compliant. Breathing allows you to improve the expression of peripheral muscle strength and stability, influencing the parasympathetic system [48–50]. As a first diaphragmatic screening, the BDT exploits neurophysiological knowledge to identify any phrenic or vagal dysfunctions [50]. The BDT needs further investigation for its validation. The test should be repeated after a program of rehabilitation or after a course of manual osteopathic medicine. In this way, it is feasible to have a comparative result.

BDT cannot be performed by patients who are not autonomous from a neuromotor or cognitive point of view, just as it is not feasible to perform the test in the presence of acute (clinical instability) or other neuromotor or orthopedic pathologies that invalidate the result or the act of the BDT itself. A disturbed emotional state that can affect breathing (anxiety, marked depression, fear) can impair the patient's ability to perform the test. The manual, noninstrumental test is not diagnostic, but it is a further indication of utility for the clinician. In manual osteopathic medicine, there is no noninstrumental and nonmanual test for the evaluation of the diaphragm muscle. BDT could be a useful addition for the osteopathic physician's clinic as a noninvasive tool for patient assessment; however, at present, we do not have evidence to support this hypothesis. The description of this test has never been carried out before this article and, therefore, validation studies of BDT will be necessary to elucidate the evaluation inferred from the BDT.

In conclusion, we want to highlight the real meaning of evidence-based medicine (EBM), which is a concept conceived by David Sackett and Gordon Guyatt. The value

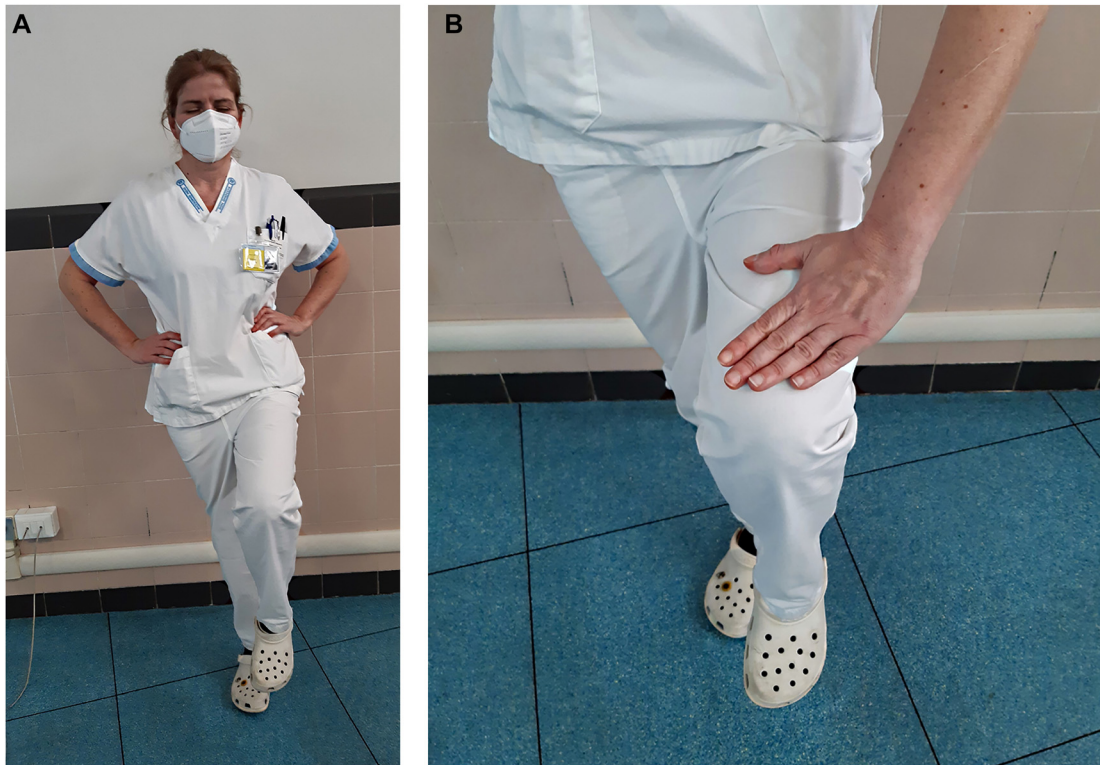

Figure 2: (A) The image illustrates the first step of the test in which the person raises her leg with her eyes closed and hands on her hips. (B) The image illustrates the second step of the test, in which the person lifts his leg with his eyes closed and his hands on his hips, while an operator places his hand to put slight pressure against the lifting of the leg.

of the clinician's experience, in tandem with the patient's experience with the treatments received, have equal value compared to what is achieved in the experimental research clinic [51].

Conclusions

The cardiac surgery approach in median sternotomy causes iatrogenic damage to the functionality of the diaphragm muscle. This article reviewed the neurophysiological information of the diaphragm muscle and the dysfunctions that can occur after a cardiac event, regardless of whether surgery is present. Based on this scientific information, because there is no noninstrumental diaphragmatic test, we have tried to present a new and unique test to identify the contractile function of the respiratory muscle. We believe that the BDT can become an easy reference point as a first screening to evaluate the function of the diaphragm before deciding if instrumental tests should be performed and, if so, which tests. In the next few years, this could result in an economic

and time-saving value, potentially avoiding more invasive tests such as X-rays. The future will require new efficiencies in clinical evaluations. With the elderly population (and chronic heart diseases) continuously increasing, a quick and simple test could become a winning strategy.

Research funding: None reported.

Author contributions: Both authors provided substantial contributions to conception and design, acquisition of data, or analysis and interpretation of data; both authors drafted the article or revised it critically for important intellectual content; both authors gave final approval of the version of the article to be published; and both authors agree to be accountable for all aspects of the work in ensuring that questions related to the accuracy or integrity of any part of the work are appropriately investigated and resolved.

Competing interests: None reported.

Ethical approval: This demonstration was exempt Institutional Review Board review process.

Informed consent: All participants in this study provided written informed consent prior to participation.

References

- Fatehi Hassanabad A, Kent WDT, Adams C. Review of transapical off-pump mitral valve intervention with NeoChord implantation. *Curr Opin Cardiol* 2021;36:130–40.
- Bakhtiar F, El-Sayed Ahmad A, Amer M, Salamate S, Sirat S, Borger MA. Video-assisted minimally invasive aortic valve replacement through right anterior minithoracotomy for all comers with aortic valve disease. *Innovations* 2020: 1556984520977212. <https://doi.org/10.1177/1556984520977212>.
- Shafi AMA, Abuelgasim E, Abuelgasim B, Iddawela S, Harky A. Sternal closure with single compared with double or figure of 8 wires in obese patients following cardiac surgery: a systematic review and meta-analysis. *J Card Surg* 2021;36:1072–82.
- Preventza O, Amarasekara H, Price MD, Chatterjee S, Green SY, Woodside S, et al. Propensity score analysis in patients with and without previous isolated coronary artery bypass grafting who require proximal aortic and arch surgery. *J Thorac Cardiovasc Surg* 2020;33144–5:50022-5223.
- Bordoni B, Marelli F, Morabito B, Sacconi B, Severino P. Post-sternotomy pain syndrome following cardiac surgery: case report. *J Pain Res* 2017;10:1163–9.
- Chen L, Wang L, Zhuo Q, Zhang Q, Chen F, Li L, et al. Effect of Shenmai injection on cognitive function after cardiopulmonary bypass in cardiac surgical patients: a randomized controlled trial. *BMC Anesthesiol* 2018;18:142.
- Uchida T, Tanaka Y, Shimizu N, Kuroda S, Doi T, Hokka D, et al. Diaphragmatic plication for iatrogenic respiratory insufficiency after cardiothoracic surgery. *J Thorac Dis* 2019;11:3704–11.
- Sahar W, Ajaz N, Haider Z, Jalal A. Effectiveness of pre-operative respiratory muscle training versus conventional treatment for improving post operative pulmonary health after coronary Artery bypass grafting. *Pak J Med Sci* 2020;36:216–9.
- Windmüller P, Bodnar ET, Casagrande J, Dallazen F, Schneider J, Berwanger SA, et al. Physical exercise combined with CPAP in subjects who underwent surgical myocardial revascularization: a randomized clinical trial. *Respir Care* 2020;65:150–7.
- Aguirre VJ, Sinha P, Zimmet A, Lee GA, Kwa L, Rosenfeldt F. Phrenic nerve injury during cardiac surgery: mechanisms, management and prevention. *Heart Lung Circ* 2013;22:895–902.
- Tanner TG, Colvin MO. Pulmonary complications of cardiac surgery. *Lung* 2020;198:889–96.
- Yegorova S, Yegorov O, Ferreira LF. RNA-sequencing reveals transcriptional signature of pathological remodeling in the diaphragm of rats after myocardial infarction. *Gene* 2021;770:145356.
- Miyazaki S, Kobori A, Sasaki Y, Miyamoto K, Sato E, Hanazawa K, et al. Real-world safety profile of atrial fibrillation ablation using a second-generation cryoballoon in Japan: insight from a large multicenter observational study. *JACC Clin Electrophysiol* 2021: 31198–1. <https://doi.org/10.1016/j.jacep.2020.11.016>.
- Parker MH, Colpitts DK, Gilson GF, Ryan L, Mukherjee D. Carotid-axillary bypass as an alternative to carotid-subclavian bypass following coverage of left subclavian artery during TEVAR. *Vasc Endovascular Surg* 2021;55:265–8.
- Del Negro CA, Funk GD, Feldman JL. Breathing matters. *Nat Rev Neurosci* 2018;19:351–67.
- Anderson TM, Ramirez JM. Respiratory rhythm generation: triple oscillator hypothesis. *F1000Res* 2017;6:139.
- Ghali MGZ. Respiratory rhythm generation and pattern formation: oscillators and network mechanisms. *J Integr Neurosci* 2019;18: 481–517.
- Jugé L, Knapman FL, Burke PGR, Brown E, Bosquillon de Frescheville AF, Gandevia SC, et al. Regional respiratory movement of the tongue is coordinated during wakefulness and is larger in severe obstructive sleep apnoea. *J Physiol* 2020;598:581–97.
- Bordoni B, Zanier E. Anatomic connections of the diaphragm: influence of respiration on the body system. *J Multidiscip Healthc* 2013;6:281–91.
- Ghali MGZ. The bulbospinal network controlling the phrenic motor system: laterality and course of descending projections. *Neurosci Res* 2017;121:7–17.
- Bordoni B. The five diaphragms in osteopathic manipulative medicine: neurological relationships, Part 2. *Cureus* 2020;12: e8713.
- Sunderram J, Semmlow J, Patel P, Rao H, Chun G, Agarwala P, et al. Heme oxygenase-1-dependent central cardiorespiratory adaptations to chronic intermittent hypoxia in mice. *J Appl Physiol* 2016;121:944–52. 1985.
- Teragawa H, Oshita C, Ueda T. History of gastroesophageal reflux disease in patients with suspected coronary artery disease. *Heart Ves* 2019;34:1631–8.
- Frieling T. Non-cardiac chest pain. *Visc Med* 2018;34:92–6.
- Bordoni B, Marelli F, Morabito B, Castagna R. Chest pain in patients with COPD: the fascia's subtle silence. *Int J Chron Obstruct Pulmon Dis* 2018;13:1157–65.
- LoMauro A, Aliverti A, Perchiazzi G, Frykholm P. Physiological changes and compensatory mechanisms by the action of respiratory muscles in a porcine model of phrenic nerve injury. *J Appl Physiol* 2021;130:813–26. 1985.
- Moury PH, Cuisinier A, Durand M. Diaphragm thickening in cardiac surgery: a perioperative prospective ultrasound study. *Ann Intensive Care* 2019;9:50.
- Gharib SA, Hurley AL, Rosen MJ, Spilsbury JC, Schell AE, Mehra R, et al. Obstructive sleep apnea and CPAP therapy alter distinct transcriptional programs in subcutaneous fat tissue. *Sleep* 2020; 43:zsz314.
- Urner M, Mitsakakis N, Vorona S, Chen L, Sklar MC, Dres M, et al. Identifying patients at risk for diaphragm atrophy during mechanical ventilation using routinely available clinical data. *Respir Care* 2020;66:551–8.
- Mankowski RT, Ahmed S, Beaver T, Dirain M, Han C, Hess P, et al. Intraoperative hemidiaphragm electrical stimulation reduces oxidative stress and upregulates autophagy in surgery patients undergoing mechanical ventilation: exploratory study. *J Transl Med* 2016;14:305.
- Bordoni B, Marelli F, Morabito B, Sacconi B. Depression and anxiety in patients with chronic heart failure. *Future Cardiol* 2018; 14:115–9.
- Qian Z, Yang M, Li L, Chen Y. Ultrasound assessment of diaphragmatic dysfunction as a predictor of weaning outcome from mechanical ventilation: a systematic review and meta-analysis. *BMJ Open* 2018;8:e021189.
- Bordoni B, Marelli F, Morabito B, Sacconi B. Manual evaluation of the diaphragm muscle. *Int J Chron Obstruct Pulmon Dis* 2016;11: 1949–56.
- Bordoni B, Morabito B. The diaphragm muscle manual evaluation scale. *Cureus* 2019;11:e4569.

35. Bordoni B, Purgol S, Bizzarri A, Modica M, Morabito B. The influence of breathing on the central nervous system. *Cureus* 2018;10:e2724.
36. Fakhraei L, Francoeur M, Balasubramani P, et al. Mapping large-scale networks associated with action, behavioral inhibition and impulsivity. *eNeuro* 2021;8. <https://doi.org/10.1523/ENEURO.0406-20.2021>.
37. Bordoni B, Simonelli M. Chronic obstructive pulmonary disease: proprioception exercises as an addition to the rehabilitation process. *Cureus* 2020;12:e8084.
38. Marmarstein JT, McCallum GA, Durand DM. Direct measurement of vagal tone in rats does not show correlation to HRV. *Sci Rep* 2021;11:1210.
39. Garg A, Xu D, Blaber A. Posture muscle relationship with cardiovascular changes under orthostatic challenge. *Annu Int Conf IEEE Eng Med Biol Soc* 2014;2014:4378–81.
40. Kuehn E, Mueller K, Lohmann G, Schuetz-Bosbach S. Interoceptive awareness changes the posterior insula functional connectivity profile. *Brain Struct Funct* 2016;221:1555–71.
41. Finta R, Boda K, Nagy E, Bender T. Does inspiration efficiency influence the stability limits of the trunk in patients with chronic low back pain? *J Rehabil Med* 2020;52:jrm00038.
42. Horris H, Anderson BE, Bay RC, Huxel Bliven KC. Clinical breathing mechanics differ based on test and position. *J Sport Rehabil* 2019;28:635–9.
43. Hida T, Yamada Y, Ueyama M, Araki T, Nishino M, Kurosaki A, et al. Time-resolved quantitative evaluation of diaphragmatic motion during forced breathing in a health screening cohort in a standing position: dynamic chest phrenicography. *Eur J Radiol* 2019;113:59–65.
44. Kocjan J, Gzik-Zroska B, Nowakowska K, Burkacki M, Suchoń S, Michnik R, et al. Impact of diaphragm function parameters on balance maintenance. *PLoS One* 2018;13:e0208697.
45. Tadjalli A, Seven YB, Perim RR, Mitchell GS. Systemic inflammation suppresses spinal respiratory motor plasticity via mechanisms that require serine/threonine protein phosphatase activity. *J Neuroinflammation* 2021;18:28.
46. Stefani GP, Nunes RB, Rossato DD, Hentschke VS, Domenico MD, Lago PD, et al. Quantification of DNA damage in different tissues in rats with heart failure. *Arq Bras Cardiol* 2020;114:234–42.
47. Arutyunov AG, Ilyina KV, Arutyunov GP, Kolesnikova EA, Pchelin VV, Kulagina NP, et al. Morphofunctional features of the diaphragm in patients with chronic heart failure. *Kardiologiya* 2019;59:12–21.
48. Marmarstein JT, McCallum GA, Durand DM. Direct measurement of vagal tone in rats does not show correlation to HRV. *Sci Rep* 2021;11:1210.
49. Jaenisch RB, Quagliotto E, Chechi C, Calegari L, Dos Santos F, Borghi-Silva A, et al. Respiratory muscle training improves chemoreflex response, heart rate variability, and respiratory mechanics in rats with heart failure. *Can J Cardiol* 2017;33:508–14.
50. Bordoni B, Pellegrini MV. Osteopathic manipulative treatment: 5 diaphragm procedure. In *StatPearls* [Internet]. Treasure Island (FL): StatPearls Publishing; 2021. Available from: <https://pubmed.ncbi.nlm.nih.gov/33620866/>.
51. Bordoni B. The benefits and limitations of evidence-based practice in osteopathy. *Cureus* 2019;11:e6093.