

University of Groningen

## Safety and feasibility of indocyanine green fluorescence angiography in pediatric gastrointestinal surgery

Breuking, Eline A.; van Varsseveld, Otis C.; Harms, Marc; Tytgat, Stefaan H.A.J.; Hulscher, Jan B.F.; Ruiterkamp, Jetske

*Published in:*  
Journal of Pediatric Surgery

*DOI:*  
[10.1016/j.jpedsurg.2022.10.045](https://doi.org/10.1016/j.jpedsurg.2022.10.045)

**IMPORTANT NOTE: You are advised to consult the publisher's version (publisher's PDF) if you wish to cite from it. Please check the document version below.**

*Document Version*  
Publisher's PDF, also known as Version of record

*Publication date:*  
2023

[Link to publication in University of Groningen/UMCG research database](#)

### *Citation for published version (APA):*

Breuking, E. A., van Varsseveld, O. C., Harms, M., Tytgat, S. H. A. J., Hulscher, J. B. F., & Ruiterkamp, J. (2023). Safety and feasibility of indocyanine green fluorescence angiography in pediatric gastrointestinal surgery: A systematic review. *Journal of Pediatric Surgery*, 58(8), 1534-1542. Advance online publication. <https://doi.org/10.1016/j.jpedsurg.2022.10.045>

### **Copyright**

Other than for strictly personal use, it is not permitted to download or to forward/distribute the text or part of it without the consent of the author(s) and/or copyright holder(s), unless the work is under an open content license (like Creative Commons).

The publication may also be distributed here under the terms of Article 25fa of the Dutch Copyright Act, indicated by the "Taverne" license. More information can be found on the University of Groningen website: <https://www.rug.nl/library/open-access/self-archiving-pure/taverne-amendment>.

### **Take-down policy**

If you believe that this document breaches copyright please contact us providing details, and we will remove access to the work immediately and investigate your claim.

Downloaded from the University of Groningen/UMCG research database (Pure): <http://www.rug.nl/research/portal>. For technical reasons the number of authors shown on this cover page is limited to 10 maximum.



## Review Article

# Safety and Feasibility of Indocyanine Green Fluorescence Angiography in Pediatric Gastrointestinal Surgery: A Systematic Review



Eline A. Breuking<sup>a,\*</sup>, Otis C. van Varsseveld<sup>b</sup>, Marc Harms<sup>c</sup>, Stefaan H.A.J. Tytgat<sup>a</sup>, Jan B.F. Hulscher<sup>b</sup>, Jetske Ruitkamp<sup>a</sup>

<sup>a</sup> Division Child Health, Wilhelmina Children's Hospital, University Medical Center Utrecht, Pediatric Surgery, Lundlaan 6, Utrecht, EA 3584, the Netherlands (NL)

<sup>b</sup> Beatrix Children's Hospital, University Medical Center Groningen, Pediatric Surgery, Hanzeplein 1, Groningen, GZ 9713, the Netherlands (NL)

<sup>c</sup> Stryker Endoscopy, Stryker Nederland BV Herikerbergweg 110, Amsterdam, CM 1101, the Netherlands (NL)

## ARTICLE INFO

## Article history:

Received 9 June 2022

Revised 5 October 2022

Accepted 13 October 2022

## Keywords:

ICG-FA  
Intestinal perfusion  
Anastomosis  
Pediatric gastrointestinal surgery  
Neonate  
Fluorescence  
ICG  
Pediatric surgery  
Perfusion assessment  
Safety  
NEC  
Hirschsprung  
SBS  
ARM  
Short Bowel Syndrome  
Anorectal Malformation  
Atresia

## ABSTRACT

**Background:** Although ICG-FA may be valuable in assessing anastomotic perfusion, reliable data on its use in pediatric gastrointestinal surgery is lacking. This systematic review analyzes whether ICG is useful for intestinal perfusion assessment in pediatric gastrointestinal surgery and safe to use in neonates.

**Methods:** Systematic searches of PubMed, EMBASE & MEDLINE and CENTRAL were performed (last conducted December 6, 2021). The main inclusion criteria were (1) use of ICG for intestinal perfusion assessment and (2) use of ICG in young infants. Exclusion criteria were lack of an English or Dutch full-text and MINORS quality score <60%. Data was presented in overview tables. The usefulness in pediatric gastrointestinal surgery was assessed by surgical outcome. Safety of ICG in neonates was assessed by complication or adverse event occurrence.

**Results:** Regarding intestinal perfusion assessment, four studies were included, reporting 45 patients (median age 1.5 years). ICG was considered useful for anastomotic blood flow evaluation and intraoperative determination of resection length. Regarding ICG safety in neonates, eight studies were included, reporting 46 infants (median age 24.9 days), of which 18 neonates. All but one studies reported the absence of complications or adverse events. Two studies reported subcutaneous dye retention, which fully disappeared within two weeks.

**Conclusion:** Although the number of available studies is small, ICG might be useful for intraoperative intestinal perfusion assessment, perhaps even more than conventional clinical assessment. Furthermore, its safety profile looks promising in neonates. Larger prospective studies are necessary to confirm these assumptions and seem warranted given the safety profile.

**Levels of evidence:** Since this is a systematic review, a Level of Evidence for clinical studies cannot be determined for this manuscript.

© 2022 The Authors. Published by Elsevier Inc.

This is an open access article under the CC BY license (<http://creativecommons.org/licenses/by/4.0/>)

## 1. Introduction

In gastrointestinal surgery, precise perfusion assessment is important to prevent complications such as ischemia, anastomotic leakage, and strictures. By using a fluorescence imaging device,

**Abbreviations:** ARM, anorectal malformation; HD, Hirschsprung's disease; HJS, hepaticojunostomy; HPE, hepatopertoenterostomy; ICG, indocyanine green; ICG-FA, indocyanine green fluorescence angiography; LPEA, lymphatic pleural effusion and ascites; MeSH, medical subject heading; MINORS, methodological index for non-randomized studies; NEC, necrotizing enterocolitis; OR, operating room; PE, portoenterostomy; PSARVUP, posterior sagittal anorectovaginourethroplasty; SBS, short bowel syndrome; TEF, tracheoesophageal fistula.

\* Corresponding author.

E-mail address: [e.a.breuking2@students.uu.nl](mailto:e.a.breuking2@students.uu.nl) (E.A. Breuking).

perfusion can be visualized in real-time intraoperatively [1]. In the adult population, it has already been established that indocyanine green fluorescence angiography (ICG-FA) may be valuable in determining the tissue perfusion rate of anastomoses [2,3]. Therefore, it is a valuable tool for reduction of the risk of anastomotic leakage in gastrointestinal surgery [4–6]. Moreover, it is a useful tool for intraoperative decision-making. A review of the use of ICG-FA to assess colorectal anastomosis perfusion in adults has already shown an intraoperative change in the surgical plan based on ICG-FA in 10.8% of the cases, as well as a reduction of anastomotic leakage rates from 7.4% to 3.4% [7]. Furthermore, in a 2020 randomized controlled trial ICG-FA resulted in a change of transection line in 19.3% of all patients undergoing colorectal resection surgery (left anterior rectal resection, anterior resection, or colostomy) as well

as a reduction in anastomotic leakage in low colorectal anastomoses [8].

In comparison to adults undergoing gastrointestinal surgery, little research has been conducted on the use of ICG-FA in neonatal gastrointestinal surgery. In neonates, however, severe gastrointestinal malformations and diseases may occur, such as necrotizing enterocolitis (NEC), esophageal atresia, intestinal atresia, Hirschsprung's disease (HD), spontaneous intestinal perforation and anorectal malformations (ARM). These diseases often require surgical repair or even bowel resection. Not only the disease, but also treatment of the disease can lead to malperfused tissue or leakage. For an optimal outcome, it is important to resect all avital tissue. However, resecting more tissue than necessary to ensure good tissue perfusion is an undesirable option, since resection of too long a bowel segment can lead to complications such as Short Bowel Syndrome (SBS) [9].

The goal of this review is twofold. First, to analyze whether indocyanine green is useful for the assessment of intestinal perfusion in pediatric gastrointestinal surgery. Second, to study whether the use of indocyanine green in neonates is safe. Currently, the side effects of ICG registered in the product information differ per producer but are consistently limited. The incidence of these effects in available studies will be evaluated in this review.

## 2. Methods

### 2.1. Protocol and registration

A systematic review of the literature was conducted in accordance with the PRISMA statement [10]. A search strategy was formulated by the reviewers and checked for errors by a trained research librarian. All reviewers checked the search terms and agreed on them. Two reviewers independently selected and reviewed the articles, assessed their quality and collected data from selected articles. Any discrepancies were discussed with and resolved by a third reviewer. The review was registered in PROSPERO, the international database of prospectively registered systematic reviews, under registration number CRD42022303735 [11].

### 2.2. Use of ICG for the assessment of intestinal perfusion in pediatric gastrointestinal surgery

First, a systematic review was conducted regarding the use of ICG for assessment of intestinal perfusion in pediatric gastrointestinal surgical procedures. To this end, a systematic search was conducted in PubMed, EMBASE & MEDLINE and CENTRAL. The search parameters consisted of Medical Subject Headings (MeSH), employed in combination with Boolean operations "AND" and "OR". The complete search for PubMed and CENTRAL was: ("Indocyanine green"[MeSH] OR "ICG" OR "ICG fluorescence") AND (Pediatric OR infant OR neonatal OR child) AND (Surgery OR "Pediatric surgery"). The search strategy was slightly different according to the different requirements and filter options in each database. The exact search and filters applied per database are listed in supplement 1. Besides the systematic database searches, MedRxiv, the NIH Clinical Trial database of the US National Library of Medicine and the International Clinical Trials Registry Platform of the World Health Organization were screened for ongoing clinical trials with relevant reports or unpublished results. All searches were last conducted on December 6, 2021.

The quality of selected articles was assessed using the Methodological Index for Non-Randomized Studies (MINORS) scale [12]. This scale scores the aim, endpoints, potential influence of bias on endpoints and follow-up of studies. For each item, a maximum of

2 points can be scored. Only the first eight items of the scale apply to non-comparative studies. Therefore, the maximum MINORS score for such studies is 16. For comparative studies, four additional items are scored, setting their maximum MINORS score at 24.

Data collected from each study were subject, goal, number and median age of patients, procedure performed, purpose of ICG therein, surgical outcome, discussion of the authors and minimum follow-up duration. If information was missing, it was requested per email. Results were published in an overview table.

*Inclusion criteria.* The search was limited to findings in human subject studies. Only clinical research articles were included, without any study design restrictions. The patient population was required to be pediatric (age <18 years) and to receive any gastrointestinal surgery with the use of ICG for assessment of intestinal perfusion. In the EMBASE & MEDLINE database it was possible to filter for articles on specific gastrointestinal diseases. The search results from the other databases, PubMed and CENTRAL, were hand-filtered for this criterion.

*Exclusion criteria.* All articles published more than 10 years ago (before 2012) and/or without a full-text version in English or Dutch were excluded. To this end, database filters were used. Ongoing clinical trials of which no reviewable results nor any reports or progress updates were published were also excluded. Last, articles with a quality level below 10 on the MINORS for non-comparative studies or below 15 on the MINORS for comparative studies were excluded.

### 2.3. Safety of intraoperative use of ICG in neonates

The second goal of this review is to assess whether the use of ICG in neonates is safe. To this end, the same exact systematic database search was conducted, again in PubMed, EMBASE & MEDLINE, CENTRAL and clinical trial databases. To focus on neonates without excluding too many results, all articles on infants with a median subject age of  $\leq 3$  months were included. Since the goal is to assess whether the indocyanine green administration itself caused complications, the exact procedure ICG was used for was not relevant. The exact search and filters applied per database are listed in supplement 2. All searches were last conducted on December 6, 2021. Again, the quality of selected items was assessed using the Methodological Index for Non-Randomized Studies (MINORS) scale [12].

Data collected from each study were disease, number of patients and their median age at surgery, procedure performed, ICG dose and type, administration route, complications/adverse events reported (number) and minimum duration of follow-up (days). If any information needed for this systematic review was missing from a study, the researchers were emailed for additional information and/or clarification. Results were once again published in an overview table.

*Inclusion criteria.* Inclusion criteria were nearly identical to the first search. The only difference was to select articles regarding only young infants (median age  $\leq 3$  months). Furthermore, studies on intravenously or subcutaneously administered ICG, irrespective of the use of the ICG, were included. The EMBASE & MEDLINE database search was automatically filtered for articles on infants (children aged  $\leq 12$  months) only and then hand-searched for having a median age within the range  $\leq 3$  months, whereas the search results from the other databases, PubMed and CENTRAL, were hand-filtered for this criterion.

*Exclusion criteria.* Exclusion criteria were the same as for the first search. Studies regarding other than gastrointestinal diseases were not excluded this time.

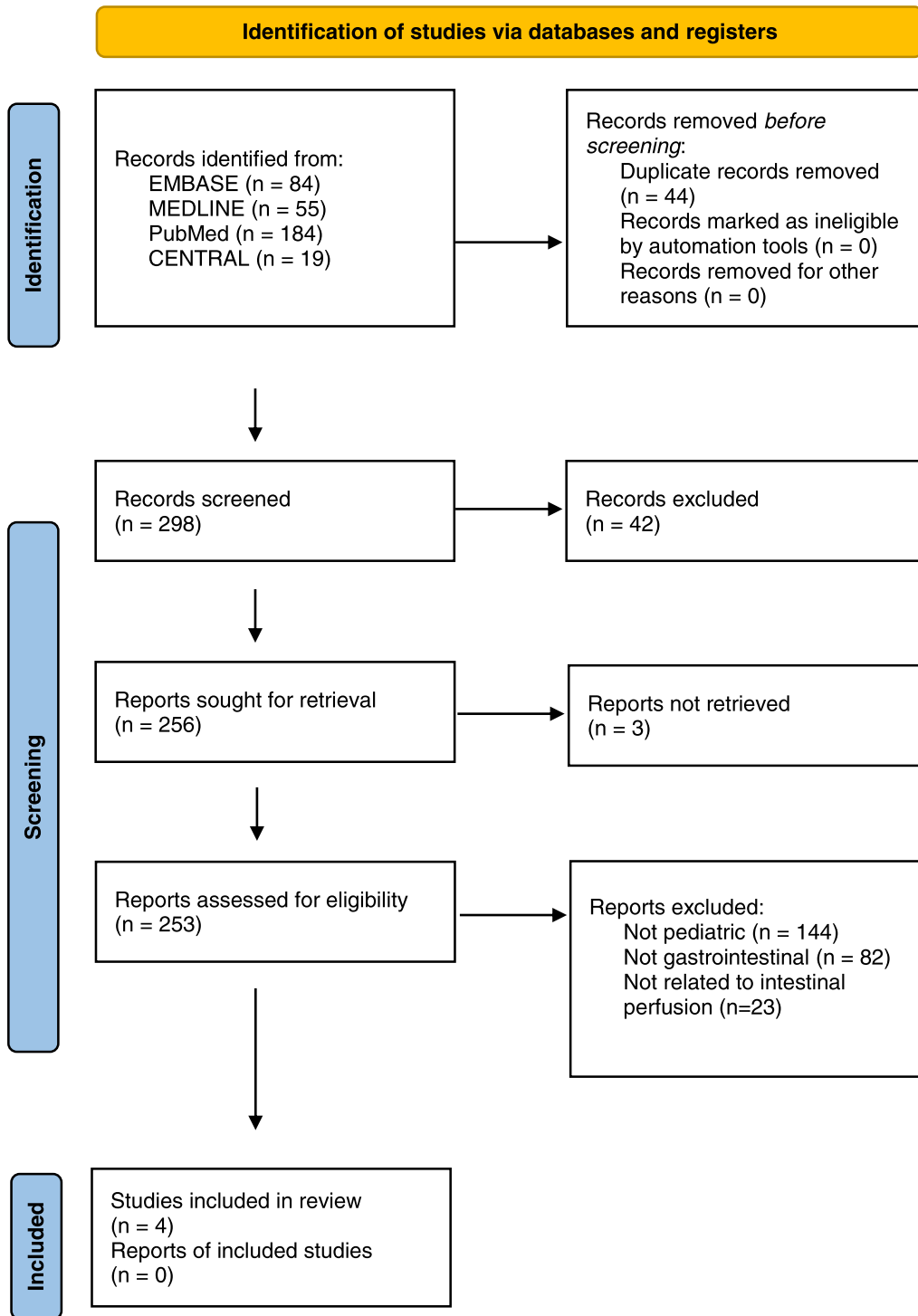


Fig. 1. PRISMA 2020 Flow Diagram regarding the use of ICG for assessment of intestinal perfusion in pediatric surgical procedures [10].

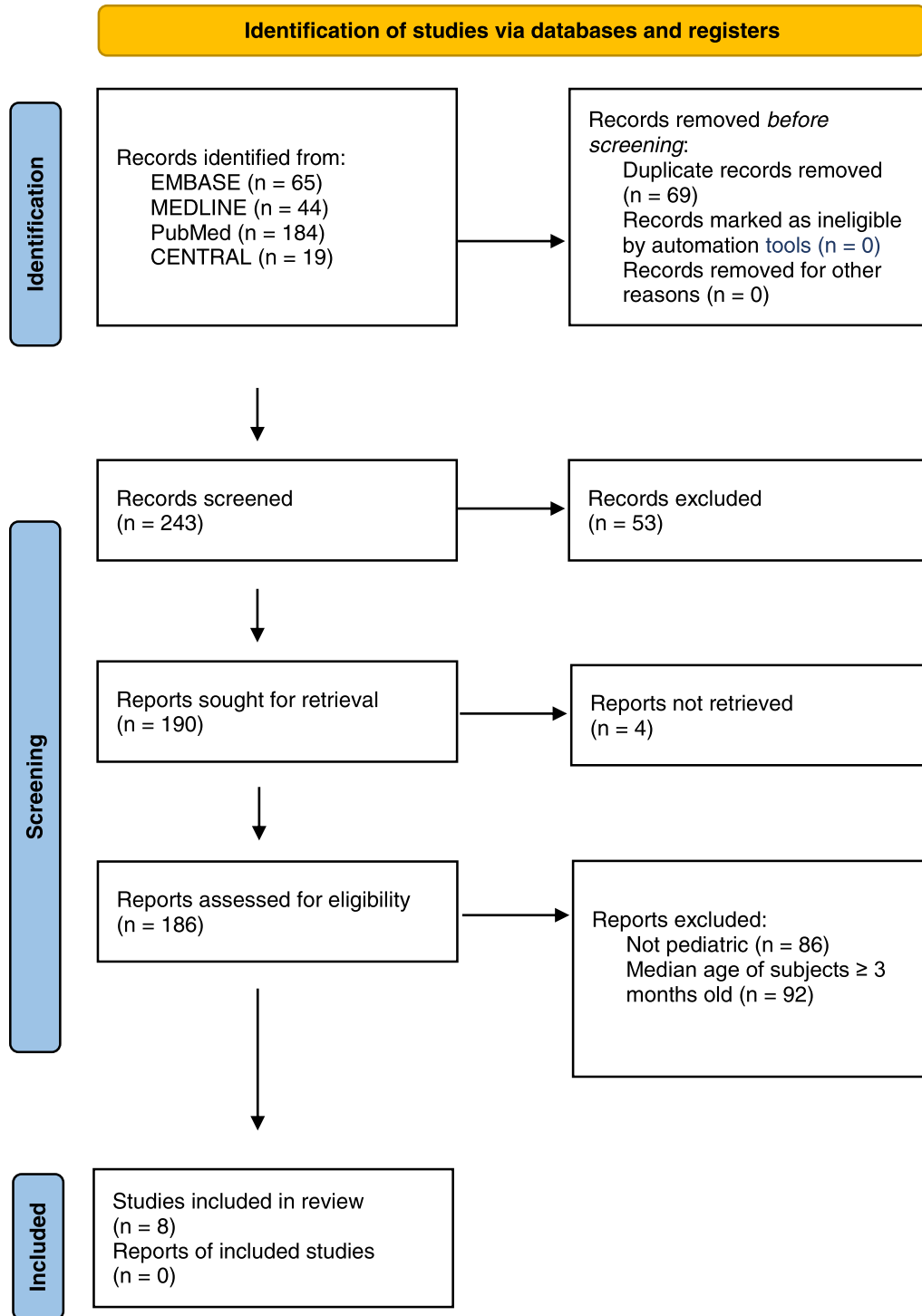


Fig. 2. PRISMA 2020 Flow Diagram regarding safety of ICG in neonates [10].

### 3. Results

#### 3.1. Use of ICG for assessment of intestinal perfusion in pediatric gastrointestinal surgery

After conducting the search and deduplication of the results, a total of 298 potentially eligible studies remained (Fig. 1). These articles were screened by abstract or, if necessary, fully searched by the reviewers to only include studies related to the use of ICG for assessment of intestinal perfusion in pediatric gastrointestinal surgery. Four non-comparative studies

fell within the scope and were thus selected for inclusion in this review. All studies scored 11 or higher (out of 16) on the MINORS for non-comparative studies. The MINORS score per study is shown in supplement 3. The gray literature database searches did not result in any relevant studies but one, of which no reports or results were available yet [13]. There were no discrepancies or disagreements between the reviewers regarding the search results and selected articles, nor were there any disagreements between the reviewers scoring the selected studies on the MINORS. The results of this search are listed in Table 1.

**Table 1**  
Overview of literature on the use of ICG for assessment of intestinal perfusion in pediatric gastrointestinal surgery.

Study	Study design	Subject	Goal	n (treated with ICG)	Median age	Procedure	Purpose of ICG	Outcome	Discussion	Follow-up (days), minimum
linuma 2013 [14]	Case report	Intestinal volvulus (no malrotation)	Demonstrating the relationship between the results of NIR-ICG AG and the natural final intestinal status in a young human patient	1	15 years	Primary laparotomy with massive necrotic intestinal resection, then relaparotomy with additional resection of intestine	Assessment of intestinal perfusion before determining resection length	- Primary laparotomy: decision of ICG not followed, resulting in complication - Relaparotomy with additional resection of segment marked as malperfused by ICG: successful	"Further studies are still necessary to clarify the relationship between the final intestinal viability and the vascular flow patterns of NIR-ICG AG in humans. However, NIR-ICG AG can intraoperatively provide more useful real time information on the intestinal perfusion than can conventional clinical assessments."	>22
Kamran 2021 [17]	Retrospective study	Recurrent TEFs (majority after EA-TEF type C correction)	Reviewing experience with the treatment of recurrent TEF using posterior tracheopexy, focusing on operative risks and long-term outcomes	29	14 (7–21) months	Posterior tracheopexy with rotational esophagoplasty	Assessment of esophageal perfusion	Surgical treatment of recurrent TEFs that incorporates a posterior tracheopexy and rotational esophagoplasty is highly effective for preventing re-recurrence with low perioperative morbidity	"Esophageal anastomotic leak developed in 3 patients (5%); 2 patients healed with nonoperative management and a chronic leak developed in the third patient after a Foker process and esophageal replacement was ultimately required."	912 (365–1825)
Rentea 2020 [15]	Retrospective study	HD, ARM, cloacal reconstruction	Investigating the utility of ICG-FA for operative management of the subject diseases, hypothesizing that it would be more accurate than the surgeon's eye	13	1.9 (0.5–7.8) years	PSARVUP (n = 8), redo PSARVUP (n = 1), redo colonic pull-through (n = 3), colonic pull-through (n = 1)	Assessment of colonic, rectal, vaginal, and neovaginal tissue perfusion for determining resection length	ICG-FA resulted in a change in the operative plan in 4 of the 13 (31%) cases. In three cases, ICG-FA resulted in the distal bowel being transected at a level (>10 cm) higher than originally planned, and in one case the distal bowel was discarded, and the colostomy used for pull-through	- "ICG-FA offers an in situ intraoperative method that permitted confirmation of tissue viability. The question of what the decreased perfusion implied has yet to be fully determined quantitatively." - "Despite the limitations because of small sample-sized study, ICG-enhanced fluorescence appears to be safe, reproducible, simple, and cost-effective to assess intraoperative perfusion."	365
Yada 2020 [18]	Case report	Colostomy closure	Discussing the first two cases who underwent colostomy closure using ICG fluorescence system	2	13.5 (11–16) months	Sigmoid loop colostomy closure (n = 1), transverse loop colostomy closure (n = 1)	Evaluation of anastomotic blood flow and postoperative bowel function	ICG fluorescence was safe and useful to evaluate intra-operative blood supply and post-operative bowel function for pediatric stoma closure without any postoperative complication	"ICG fluorescence can be useful to decide the anastomosis more accurately in pediatric patient. We need to collect more data to establish the accurate fluorescent time to prevent anastomotic leakage for pediatric patients."	>4

Abbreviations: ARM, anorectal malformation; HD, Hirschsprung's disease; PSARVUP, posterior sagittal anorectovaginothoroplasty; TEF, tracheoesophageal fistula.

**Table 2**  
Overview of literature regarding the safety of intraoperative use of ICG in neonates.

Study	Country, Study interval	Study design	Disease treated	n	Procedure	Median age at surgery	ICG dose	ICG type	Administration route	Complications/adverse events	Follow-up (days), minimum	Other remarks
Haga 2020 [19]	Japan, 2019	Case report	Chylothorax	1	Lipiodol lymphangiography	59 days	0.1–0.2 mL (0.125–0.25 mL/kg)	Lipiodol	Subcutaneous injection	No complications	276	–
Hayashida 2019 [20]	Japan, 2019	Case report	Chylothorax	1	ICG lymphography	38 days	0.2 mL	Diagno-green 0.5%	Subcutaneous injection	No complications or adverse events	82	–
Hirayama 2015 [21]	Japan, 2012–2014	Prospective study	Biliary atresia type III	5	HPE	42 days (31–75)	0.1 mg/kg	ICG	Intravenous injection	No hypersensitivity reactions or other adverse events	25	–
Mihara 2015 [22]	Japan, 2012	Retrospective study	Postoperative LPEA	8	ICG lymphography	2.9 months (0.5–7)	0.04 mL	Diagno-green 0.05%	Subcutaneous injection	No perioperative and postoperative complications	Unknown	–
Shibasaki 2014 [23]	Japan, 2011–2013	Prospective study	Congenital LPEA	10	ICG lymphography	67.6 days (1–275)	0.1 mL (0.25 mg)	Diagno-green 0.25%	Subcutaneous injection	Change in skin color because of the ICG for 1–2 weeks	30	2 patients died because of the disease
Shirotsuki 2018 [24]	Japan, 2014–2017	Retrospective study	TEF (n = 10), chylothorax (n = 3)	10	TEF repair (n = 8), postoperative chylothorax repair (n = 3)	2.0 days (1.0–10.0)	0.025 mg	Diagno-green	Subcutaneous injection	Retention of the injected dye for several days	11	–
Tan 2014 [16]	USA, 2012	Case report	Chylothorax	1	NIRF lymphatic imaging	5 weeks	0.05 mg	ICG (50 mcg in 2cc of saline)	Subcutaneous injection	No adverse events associated with the imaging, no apparent reactions to the ICG	N/A	Patient died because of the disease
Yanagi 2019 [25]	Japan, 2017–2018	Retrospective study	Biliary atresia type I (n = 2), type III (n = 8)	10	Kasai PE (n = 9), HJS (n = 1)	74.8 days (48–122)	0.5 mg/kg	ICG	Intravenous injection	No report on complications/adverse events	22	–

Abbreviations: HPE, hepatopertoenterostomy; HJS, hepaticojejunostomy; LPEA, lymphatic pleural effusion and ascites; PE, portoenterostomy; TEF, tracheoesophageal fistula.

The included studies were conducted in five centers in total. 78 patients were included with a median age of 1.5 years (range 0.5–15) at the time of surgery. Only 45 patients received ICG during the surgery, so only these patients and their respective results were included in this review. All patients required surgery for a gastrointestinal disease.

In 31 out of 45 patients, ICG was used to confirm vitality of the anastomosis by assessing the blood flow with ICG fluorescence with the goal of decreasing the risk of postoperative complications such as anastomotic leaks. The specific indications for these surgical procedures were recurrent tracheoesophageal fistula (TEF) ( $n = 29$ ) and colostomy closure ( $n = 2$ ). In both studies using ICG for the purpose of evaluation of anastomotic blood flow, the use of ICG was considered useful for evaluation of vitality of the anastomosis, thereby reducing the risk of recurrence or postoperative complications.

In the other 14 cases, ICG was used to make or confirm the intraoperative decision on length of the bowel segment that had to be resected. The specific indications for these surgical procedures were cloacal reconstruction ( $n = 9$ ), HD ( $n = 3$ ), ARM ( $n = 1$ ) and malrotation without volvulus ( $n = 1$ ). In the studies using ICG for intraoperative determination or confirmation of resection length, ICG was regarded as a safe and useful intervention by the authors, providing more useful information on the intestinal perfusion than conventional clinical assessment [14,15].

### 3.2. Safety of intraoperative use of ICG in neonates

In addition to the use of ICG for assessment of intestinal perfusion in pediatric gastrointestinal surgery, we reviewed whether the intraoperative use of ICG is safe in the neonatal population. The 243 potentially eligible studies were screened or, if necessary, searched by the researchers to only include studies related to the use of ICG in surgical procedures regarding only young infants with a median age  $\leq 3$  months. Afterwards, eight non-comparative studies remained (Fig. 2). All studies scored 11 or higher (out of 16) on the MINORS for non-comparative studies. The MINORS score per study is shown in supplement 4. Three studies were case reports, three were retrospective studies and two were prospective studies. The gray literature database searches did not result in any relevant studies. Again, there were no discrepancies or disagreements between reviewers regarding study selection or MINORS score. The results of this search are listed in Table 2.

The included studies were conducted in ten centers in total, nine of which were in Japan. Forty-six patients were included with a median age of 24.9 (range 1–275) days, of which 18 patients were neonates (age  $\leq 1$  month). All patients were treated with ICG, either for the purpose of lymphatic imaging in patients with lymphatic pleural effusion and ascites ( $n = 18$ ), primary tracheoesophageal fistula (TEF) repair with a risk of intraoperative iatrogenic chylothorax ( $n = 8$ ) or chylothorax ( $n = 6$ ), or for the purpose of visualizing biliary flow in biliary atresia correction surgery ( $n = 15$ ).

The dose of ICG varied between studies with a range from 0.04 mL to 0.5 mg/kg. Patients receiving ICG for the purpose of lymphatic imaging were administered ICG by subcutaneous injection ( $n = 31$ ), whereas patients receiving ICG for the purpose of visualizing biliary flow were administered ICG by intravenous injection ( $n = 15$ ).

In five out of eight studies involving 16 patients in total, no complications or adverse events occurred. In two out of eight studies involving 20 patients in total, no complications or adverse events were reported, except for retention of the injected dye or change of skin color after the use of ICG. The authors of both studies were successfully contacted by email for more information on

this condition. The change in skin color reported by Shibasaki et al. lasted for 1–2 weeks, then disappeared completely. The retention of dye for several days reported by Shiotsuki et al., causing discoloration of the skin without further symptoms, eventually disappeared in about two weeks. The authors further elucidated that they have treated more than 20 patients with ICG through subcutaneous injection, without there being a single case of residual pigment. One study did not report anything specific on peri- and postoperative events.

It should be explicitly noted that the patient of the case report by Tan et al. died from chylous ascites without any relation to the ICG administered [16]. Follow-up of all patients but the patient of Tan et al. was at least 11 days but mostly longer, up to 276 days. One study, including 8 patients, did not report anything on duration of follow-up.

## 4. Discussion

### 4.1. Summary of main results

The use of ICG for intraoperative assessment of the intestinal perfusion has already been studied extensively in adults, where it was found to be valuable for reduction of the risk of anastomotic leakage as well as for intraoperative decision-making. [4–7] Nevertheless, studies regarding the use of ICG for assessment of intestinal perfusion in pediatric surgery are scarce. The results of this systematic review suggest that ICG may be a useful and safe intervention for evaluation of anastomotic blood flow, evaluation of vitality of the anastomosis and intraoperative determination or confirmation of resection length. It may even provide more useful information on the intestinal perfusion than conventional clinical assessment. More specifically, visual assessment does not always reflect the precise perfusion status of the intestine, whereas ICG-FA can precisely visualize decreased perfusion in real-time [14,15].

This review of available literature shows that ICG may be safe to use in neonates, since all but one studies report the absence of any complication or adverse event occurring when ICG is used in infants  $\leq 3$  months. Two studies reported side effects of retention of the injected dye or change of skin color after the use of ICG, but these effects are temporary and fully disappear in several weeks.

### 4.2. Limitations

This review gives an analysis of early experiences with the use of ICG in pediatric gastrointestinal surgery as well as its safety profile in infants  $\leq 3$  months. However, this analysis has important limitations. Since all included studies are non-randomized, this systematic review is subject to a high risk of bias. Although the articles were assessed for quality before inclusion in this review, the study designs limit the possibility to come to a scientifically rigorous conclusion. Nevertheless, the analysis underlines the necessity of further, prospective research into both subjects.

Regarding the use of ICG for assessment of intestinal perfusion in pediatric gastrointestinal surgery, a total of 45 pediatric patients received ICG intraoperatively for this purpose. Only one of the four studies reports the number of surgical procedures in which ICG caused a change in intraoperative decision-making regarding resection length. So far, there is no scoring or grading system which can be used to objectively compare the visual inspection with the image produced by the ICG. Conclusions about the efficacy of ICG-FA, in all studies, are based on the interpretation of the surgeons. There was no study available on the use of ICG for assessment of intestinal perfusion during surgical management of neonates.

Regarding the safety of ICG in neonates, the most important limitation is the age of the patients included. The consensus is that a neonate is a child younger than one month. Unfortunately,



there is only one study available on the use of ICG in neonates exclusively. However, several articles have been written on the use of ICG in infants with inclusion of neonates. We extended our search to articles on patients up to a median age of 3 months to include more neonates, even if this meant also including infants slightly older than one month. Given the fact that the pharmacological mechanism in these children is still comparable, we considered a median age of 3 months acceptable. Out of 46 patients, 18 were truly neonates (range 1–31 days). The absence of complications or adverse events applied to all patients and thus all neonates included. All infants received ICG either subcutaneously for the purpose of lymphatic imaging or intravenously for visualization of biliary flow. The dose of ICG administered to the child varied per study. To be able to conclude that ICG is safe to use in neonates, more research with larger and strictly neonatal sample sizes in prospective settings is necessary.

Aside from the limitations of the evidence included in this systematic review, the findings of the search are in general subject to publication bias. As highlighted by the small number of available studies, the use of fluorescence is still a novelty in pediatric gastrointestinal surgery. Studies are more likely to be submitted for publication if the outcome of this new technique are positive. Furthermore, quality assessment of the included studies was done by means of the MINORS. This is the easiest assessment tool for non-randomized studies, but it must be noted there is no scale sufficiently validated for the quality assessment of non-randomized studies [26]. This may explain the relatively high scores for all studies included, even though the study design did not justify these scores, especially regarding the included case reports.

#### 4.3. Implications for practice and further research

The use of ICG could result in better and faster intraoperative decisions, which could especially be beneficial in cases of bowel ischemia. In neonatal colorectal surgery, this type of procedure is often performed, for example for extensive NEC, midgut volvulus and SIP. The operative time will not be extended by more than a few minutes if ICG and a fluorescence device are present in the designated OR and the surgeon is properly trained and/or experienced with the use of ICG-FA. After injection, the first signs of fluorescence are visible in just one minute. Within a few minutes, ICG-FA provides a useful image. After approximately 4 min, the fluorescence starts to fade. Because of the quick disappearance of the effect, there is no need to give the ICG before the operation if it is used for assessment of intestinal perfusion. This is different for gastrointestinal procedures in which ICG-FA is used to visualize other flows in the human body, such as in patients suffering from biliary atresia, where fluorescence is used to show the exact location and course of the bile ducts [25], first requiring absorption of the ICG by the liver, which then excretes it through the bile ducts.

A remaining question is whether the application of ICG will only lead to additional resection than initially planned for, or if it can also lead to a decision to resect less tissue than would have been resected based on visual assessment. If so, it may not only prevent complications following from malperfusion of intestinal sections or anastomoses, but it may also be helpful in preventing SBS. The results of this systematic review fall short in amount of included studies and patients as well as in available information to be able to predict anything about this remaining question. Future research will hopefully be clarifying.

## 5. Conclusion

There is little data on the use and safety of ICG in pediatric gastrointestinal surgery: the number of patients in which its use is

described is low. However, ICG might have a positive impact on intraoperative decisions in pediatric gastrointestinal surgery. It might be useful for the intraoperative assessment of intestinal perfusion, perhaps even more effective than conventional clinical assessment. Furthermore, its safety profile looks promising in the population of infants  $\leq 3$  months, as no serious complications or adverse events have been reported to date. In conclusion, prospective studies with larger sample sizes are necessary and seem warranted given the safety profile.

## Financial support statement

This research did not receive any specific grant from funding agencies in the public, commercial, or not-for-profit sectors. Specifically, Stryker Endoscopy did not sponsor this research by any means, though a collaboration between Stryker and the authors has been set up for future research.

## Registration

This review is registered in the PROSPERO database under registration number CRD42022303735. The protocol can be accessed at [https://www.crd.york.ac.uk/prospero/display\\_record.php?ID=CRD42022303735](https://www.crd.york.ac.uk/prospero/display_record.php?ID=CRD42022303735).

## Declaration of Competing Interest

One of the authors is a representative at Stryker Endoscopy.

## Supplementary materials

Supplementary material associated with this article can be found, in the online version, at doi:[10.1016/j.jpedsurg.2022.10.045](https://doi.org/10.1016/j.jpedsurg.2022.10.045).

## References

- [1] Cahil RA, Ris F&, Mortensen J. Near-infrared laparoscopy for real-time intraoperative arterial and lymphatic perfusion imaging. *Colorectal Dis* 2011;13:12–17. doi:[10.1111/j.1463-1318.2011.02772.x](https://doi.org/10.1111/j.1463-1318.2011.02772.x).
- [2] Jafari MD, Wexner SD, Martz JE, et al. Perfusion assessment in laparoscopic left-sided/anterior resection (PILLAR II): a multi-institutional study. *J Am Coll Surg* 2015;220:82–92. doi:[10.1016/j.jamcollsurg.2014.09.015](https://doi.org/10.1016/j.jamcollsurg.2014.09.015).
- [3] Ris F, Liot E, Buchs NC, et al. Multicentre phase II trial of near-infrared imaging in elective colorectal surgery. *Br J Surg* 2018;105:1359–67. doi:[10.1002/bjs.10844](https://doi.org/10.1002/bjs.10844).
- [4] Liu D, Liang L, Liu L, Zhu Z. Does intraoperative indocyanine green fluorescence angiography decrease the incidence of anastomotic leakage in colorectal surgery? A systematic review and meta-analysis. *Int J Colorectal Dis* 2021;36:57–66. doi:[10.1007/s00384-020-03741-5](https://doi.org/10.1007/s00384-020-03741-5).
- [5] Lin J, Zheng B, Lin S, et al. The efficacy of intraoperative ICG fluorescence angiography on anastomotic leak after resection for colorectal cancer: a meta-analysis. *Int J Colorectal Dis* 2021;36:27–39. doi:[10.1007/s00384-020-03729-1](https://doi.org/10.1007/s00384-020-03729-1).
- [6] Mok HT, Ong ZH, Yaow CYL, et al. Indocyanine green fluorescent imaging on anastomotic leakage in colectomies: a network meta-analysis and systematic review. *Int J Colorectal Dis* 2020;35:2365–9. doi:[10.1007/s00384-020-03723-7](https://doi.org/10.1007/s00384-020-03723-7).
- [7] Bos JvD, Al-Taher M, Schols RM, et al. Near-infrared fluorescence imaging for real-time intraoperative guidance in anastomotic colorectal surgery: a systematic review of literature. *J Laparoendosc Adv Surg Techniques* 2018;28:157–67. doi:[10.1089/lap.2017.0231](https://doi.org/10.1089/lap.2017.0231).
- [8] Alekseev M, Rybakov E, Shelygin Y, et al. A study investigating the perfusion of colorectal anastomoses using fluorescence angiography: results of the FLAG randomized trial. *Colorectal Dis* 2020;22:1147–53. doi:[10.1111/codi.15037](https://doi.org/10.1111/codi.15037).
- [9] Wales PW, Silva ND, Kim JH, et al. Neonatal short bowel syndrome: a cohort study. *J Pediatr Surg* 2005;40:755–62. doi:[10.1016/j.jpedsurg.2005.01.037](https://doi.org/10.1016/j.jpedsurg.2005.01.037).
- [10] Page MJ, McKenzie JE, Bossuyt PM, et al. The PRISMA 2020 statement: an updated guideline for reporting systematic reviews. *BMJ Clin Res* 2021;372:n71. doi:[10.1136/bmj.n71](https://doi.org/10.1136/bmj.n71).
- [11] Breuking EA, Varsseveld OC, Harms M, et al. Safety and feasibility of indocyanine green fluorescence angiography in pediatric gastrointestinal surgery: a systematic review. *J Pediatr Surg* 2022. doi:[10.1016/j.jpedsurg.2022.10.045](https://doi.org/10.1016/j.jpedsurg.2022.10.045).
- [12] Slim K, Nini E, Forestier D, et al. Methodological Index for Non-Randomized Studies (MINORS): development and validation of a new instrument. *ANZ J Surg* 2003;73:712–16. doi:[10.1046/j.1445-2197.2003.02748.x](https://doi.org/10.1046/j.1445-2197.2003.02748.x).
- [13] Butter A., Seemann N., Lam J, et al. Feasibility of use of indocyanine green in pediatric colorectal surgery. *ClinicalTrials.gov Identifier: NCT04904081*. May 27, 2021. <https://clinicaltrials.gov/ct2/show/NCT04904081>.

- [14] Iinuma Y, Hirayama Y, Yokoyama N, et al. Intraoperative near-infrared indocyanine green fluorescence angiography (NIR-ICG AG) can predict delayed small bowel stricture after ischemic intestinal injury: report of a case. *J Pediatr Surg* 2013;48:1123–8. doi:[10.1016/j.jpedsurg.2013.03.067](https://doi.org/10.1016/j.jpedsurg.2013.03.067).
- [15] Rentea RM, Halleran DR, Ahmad H, et al. Preliminary use of indocyanine green fluorescence angiography and value in predicting the vascular supply of tissues needed to perform cloacal, anorectal malformation, and hirschsprung reconstructions. *Eur J Pediatr Surg* 2020;30:505–11. doi:[10.1055/s-0039-1700548](https://doi.org/10.1055/s-0039-1700548).
- [16] IC Tan, Balaguru D, Rasmussen JC, et al. Investigational lymphatic imaging at the bedside in a pediatric postoperative chylothorax patient. *Pediatr Cardiol* 2014;35:1295–300. doi:[10.1007/s00246-014-0946-y](https://doi.org/10.1007/s00246-014-0946-y).
- [17] Kamran A, Zendejas B, Meisner J, et al. Effect of posterior tracheopexy on risk of recurrence in children after recurrent tracheo-esophageal fistula repair. *J Am Coll Surg* 2021;232:690–8. doi:[10.1016/j.jamcollsurg.2021.01.011](https://doi.org/10.1016/j.jamcollsurg.2021.01.011).
- [18] Yada K, Migita M, Nakamura R, et al. Indocyanine green fluorescence during pediatric stoma closure. *J Pediatr Surg Case Rep* 2020;61:101595. doi:[10.1016/j.epsc.2020.101595](https://doi.org/10.1016/j.epsc.2020.101595).
- [19] Haga M, Kato M, Kanno M, et al. Lipiodol lymphangiography in a very low birth weight premature infant. *J Pediatr Surg Case Rep* 2020;58:101480. doi:[10.1016/j.epsc.2020.101480](https://doi.org/10.1016/j.epsc.2020.101480).
- [20] Hayashida K, Yamakawa S, Shirakami E. Lymphovenous anastomosis for the treatment of persistent congenital chylothorax in a low-birth-weight infant: a case report. *Medicine* 2019;98:e17575 (Baltimore). doi:[10.1097/md.00000000000017575](https://doi.org/10.1097/md.00000000000017575).
- [21] Hirayama Y, Iinuma Y, Yokoyama N, et al. Near-infrared fluorescence cholangiography with indocyanine green for biliary atresia. Real-time imaging during the Kasai procedure: a pilot study. *Pediatr Surg Int* 2015;31:1177–82. doi:[10.1007/s00383-015-3799-4](https://doi.org/10.1007/s00383-015-3799-4).
- [22] Mihara M, Hara H, Shiotsuki J, et al. Indocyanine green lymphography and lymphaticovenous anastomosis for generalized lymphatic dysplasia with pleural effusion and ascites in neonates. *Ann Vasc Surg* 2015;29:1111–22. doi:[10.1016/j.avsg.2015.02.013](https://doi.org/10.1016/j.avsg.2015.02.013).
- [23] Shibasaki J, Hisako H, Mihara M, et al. Evaluation of lymphatic dysplasia in patients with congenital pleural effusion and ascites using indocyanine green lymphography. *J Pediatr* 2014;164:1116–20. doi:[10.1016/j.jpeds.2013.12.052](https://doi.org/10.1016/j.jpeds.2013.12.052).
- [24] Shiotsuki R, Uchida H, Tanaka Y, et al. Novel thoracoscopic navigation surgery for neonatal chylothorax using indocyanine-green fluorescent lymphography. *J Pediatr Surg* 2018;53:1246–9. doi:[10.1016/j.jpedsurg.2018.01.019](https://doi.org/10.1016/j.jpedsurg.2018.01.019).
- [25] Yanagi Y, Yoshimaru K, Matsuura T, et al. The outcome of real-time evaluation of biliary flow using near-infrared fluorescence cholangiography with Indocyanine green in biliary atresia surgery. *J Pediatr Surg* 2019;54:2574–8. doi:[10.1016/j.jpedsurg.2019.08.029](https://doi.org/10.1016/j.jpedsurg.2019.08.029).
- [26] Farrah K, Young K, Tunis MC, et al. Risk of bias tools in systematic reviews of health interventions: an analysis of PROSPERO-registered protocols. *Syst Rev* 2019;8:1–9. doi:[10.1186/s13643-019-1172-8](https://doi.org/10.1186/s13643-019-1172-8).