

University of Groningen

## Full 3-D digital planning of implant-supported bridges in secondary mandibular reconstruction with prefabricated fibula free flaps

Schepers, R. H.; Raghoobar, G. M.; Lahoda, L. U.; Van Der Meer, W. J.; Roodenburg, J. L.; Vissink, A.; Reintsema, H.; Witjes, M. J.

*Published in:*  
Head and Neck Oncology

**IMPORTANT NOTE: You are advised to consult the publisher's version (publisher's PDF) if you wish to cite from it. Please check the document version below.**

*Document Version*  
Publisher's PDF, also known as Version of record

*Publication date:*  
2012

[Link to publication in University of Groningen/UMCG research database](#)

*Citation for published version (APA):*

Schepers, R. H., Raghoobar, G. M., Lahoda, L. U., Van Der Meer, W. J., Roodenburg, J. L., Vissink, A., Reintsema, H., & Witjes, M. J. (2012). Full 3-D digital planning of implant-supported bridges in secondary mandibular reconstruction with prefabricated fibula free flaps. *Head and Neck Oncology*, 4(2), Article 44.

### Copyright

Other than for strictly personal use, it is not permitted to download or to forward/distribute the text or part of it without the consent of the author(s) and/or copyright holder(s), unless the work is under an open content license (like Creative Commons).

The publication may also be distributed here under the terms of Article 25fa of the Dutch Copyright Act, indicated by the "Taverne" license. More information can be found on the University of Groningen website: <https://www.rug.nl/library/open-access/self-archiving-pure/taverne-amendment>.

### Take-down policy

If you believe that this document breaches copyright please contact us providing details, and we will remove access to the work immediately and investigate your claim.

Downloaded from the University of Groningen/UMCG research database (Pure): <http://www.rug.nl/research/portal>. For technical reasons the number of authors shown on this cover page is limited to 10 maximum.

See discussions, stats, and author profiles for this publication at: <https://www.researchgate.net/publication/232720986>

# Full 3-D digital planning of implant-supported bridges in secondary mandibular reconstruction with prefabricated fibula free flaps

Article in *Head & Neck Oncology* · September 2012

Source: PubMed

CITATIONS

15

READS

637

8 authors, including:



**Rutger Schepers**

University of Groningen

82 PUBLICATIONS 998 CITATIONS

[SEE PROFILE](#)



**Lars-Uwe Lahoda**

Owner Private Practice, Biel Bienne BE Switzerland

55 PUBLICATIONS 495 CITATIONS

[SEE PROFILE](#)



**Wicher J van der Meer**

University of Groningen

206 PUBLICATIONS 6,744 CITATIONS

[SEE PROFILE](#)



**Jan L N Roodenburg**

University of Groningen, University Medical Center Groningen, The Netherlands

288 PUBLICATIONS 11,002 CITATIONS

[SEE PROFILE](#)



## Full 3-D digital planning of implant-supported bridges in secondary mandibular reconstruction with prefabricated fibula free flaps

RH Schepers<sup>1\*</sup>, GM Raghoobar<sup>2</sup>, LU Lahoda<sup>2</sup>, WJ Van der Meer<sup>3</sup>, JL Roodenburg<sup>1</sup>, A Vissink<sup>1</sup>, H Reintsema<sup>1</sup>, MJ Witjes<sup>1</sup>

### Abstract

#### Objectives

In the reconstruction of maxillary or mandibular continuity defects in dentate patients, the most favourable treatment is placement of implant-retained crowns or bridges in a bone graft that reconstructs the defect. Proper implant positioning is often impaired by suboptimal placement of the bone graft. This case describes a new technique of a full digitally planned, immediate restoration, two-step surgical approach for reconstruction of a mandibular defect using a free vascularised fibula graft with implants and a bridge.

#### Procedure

A 68-year-old male developed osteoradionecrosis of the mandible. The resection, cutting and implant placement in the fibula were virtually planned. Cutting and drilling guides were 3-D printed, and the bridge was computer aided design-computer aided manufacturing (CAD-CAM) milled. During the first surgery, two implants were placed in the fibula according to the digital planning, and the position of the implants was scanned using an intra-oral optical scanner. During the second surgery, a bridge was placed on the implants,

\* Corresponding author

Email: [r.h.schepers@umcg.nl](mailto:r.h.schepers@umcg.nl)

Department of Oral Surgery, University Medical Center Groningen, PO Box 30.001, NL-9700 RB Groningen, the Netherlands

<sup>1</sup> Department of Oral and Maxillofacial Surgery, University Medical Center Groningen and University of Groningen, Groningen, the Netherlands

<sup>2</sup> Department of Plastic Surgery, University Medical Center Groningen and University of Groningen, Groningen, the Netherlands

<sup>3</sup> Department of Orthodontics, University Medical Center Groningen and University of Groningen, Groningen, the Netherlands

and the fibula was harvested and fixed in the mandibular defect, guided by the occlusion of the bridge.

#### Conclusion

Three-dimensional planning allowed for positioning of a fibula bone graft by means of an implant-supported bridge, which resulted in a functional position of the graft and bridge.

#### Introduction

Large maxillary and mandibular bone defects have been a reconstructive challenge throughout time. A free bone transplant to restore a mandibular bone defect was first used in 1900. As reconstructions of larger bone defects with free bone transplants are accompanied by a high risk of dehiscence, free vascularised osseous flaps have become increasingly popular since the mid-1970s<sup>1</sup>. Large mandibular bone defects can be restored using free vascularised osseous flaps, though masticatory function often remains unfavorable because of the problems with retention and stabilisation of a mandibular prosthesis. This problem can be solved by placing dental implants in these osseous flaps to retain a mandibular denture, thus improving mastication and speech<sup>2</sup>. However, when placement of dental implants is considered part of the treatment plan, correct positioning of the osseous component of the free flap is important to allow for implant placement in the preferred anatomical locations from a prosthodontic perspective. When the bone is incorrectly positioned, implants often have to be placed in a suboptimal position. As a result,

post-operative function and aesthetics are often impaired with an implant-retained prosthesis, thereby negatively affecting the patient's quality of life<sup>2</sup>.

The vascularised fibula is often used in the reconstruction of large maxillary and mandibular defects<sup>3,4</sup>. Furthermore, implant survival in the vascularised fibula is shown to be high, which may be due to the presence of dense cortical bone, contributing to adequate initial implant stability<sup>5,6</sup>. Rohner et al.<sup>7</sup> described a method to prefabricate a free vascularised fibula graft to obtain optimal support of the suprastructure and to create a stable peri-implant soft-tissue layer. Prefabrication includes pre-operative planning of implant insertion, osteotomies of the fibula and planning of a skin graft on the fibula for a thin-lined soft-tissue reconstruction. The technique reported by Rohner et al.<sup>7</sup> involves a two-step approach. The first surgical step starts with the planning of the implants in the fibula using stereolithographic models of the maxillo-mandibular complex and fibula. Next, a backward planning for the placement of the dental implants is made based on the desired dental occlusion, which yields a drilling guide for inserting the dental implants at the exact predefined position in the fibula. The first step is completed by taking impressions of the implants in the fibula. The second step encompasses preparing the cutting guide for segmentation of the fibula and fabrication of the superstructure for completing the prosthodontic rehabilitation. The superstructure also acts as a guide

Copyright © 2012 OA Publishing London

**FOR CITATION PURPOSES:** Schepers RH, Raghoobar GM, Lahoda LU, Van der Meer WJ, Roodenburg JL, Vissink A, Reintsema H, Witjes MJ. Full 3-D digital planning of implant-supported bridges in secondary mandibular reconstruction with prefabricated fibula free flaps. *Head Neck Oncol.* 2012 Sep 9;4(2):44.

Competing interests: none declared. Conflict of interests: none declared.  
All authors contributed to the conception, design, and preparation of the manuscript, as well as read and approved the final manuscript.  
All authors abide by the Association for Medical Ethics (AME) ethical rules of disclosure.



### Introduction (Cont.)

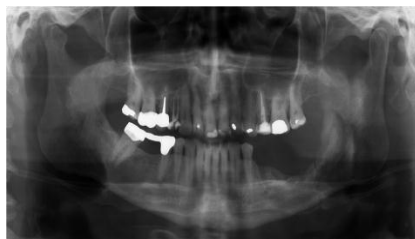for correctly positioning the fibula segments in the mandibular or maxillary defect that has to be reconstructed. A disadvantage of this technique is the extensive and demanding planning procedure, which requires a lot of laboratory work by an experienced technician, especially in the manufacturing of the drilling and cutting guides.

Recent developments in 3-D digital planning and additive manufacturing allow for entirely digitising this procedure for edentulous jaws<sup>8</sup>, but their use for dentate patients has never been described. In this article, we describe the next step towards functional reconstruction of mandibular or maxillary defects in dentate patients, viz. full 3-D digital planning of a functional reconstruction with rehabilitation of all missing teeth. The main advantage of virtual planning compared with conventional planning is that it significantly reduces the laborious manual steps.

### Full digitally planned secondary mandibular reconstruction

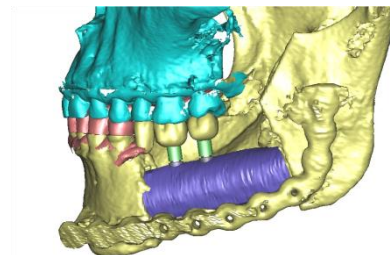
A 68-year-old patient was diagnosed with a squamous cell carcinoma (T3N0M0) of the left tonsil in 2005. Treatment consisted of accelerated radiotherapy of the oropharynx and left side of the neck with a cumulative dose of 70 Gy on the tonsil area and 50 Gy on the corpus of the left mandible. He developed osteoradionecrosis of the latter area in 2010. Despite hyperbaric oxygen therapy, combined with surgical removal of the second molar and bone sequesters, including local decorticalisation, osteoradionecrosis progressed and resulted in a pathologic fracture of the mandible in the left molar region with a persisting submandibular fistula in 2011 (Figure 1).

The patient was offered two options: a local resection of the diseased bone combined with a conventional



**Figure 1:** Panoramic radiograph showing osteolysis due to osteoradionecrosis of the left corpus of the mandible and a pathologic fracture. In the upper and lower jaw, a natural dentition is present with a bridge in the mandible from the second premolar to the second molar and absence of the second premolar and all molars on the left side. Periradicular healthy bone is present, and the periodontal chart revealed no pockets or bleeding on probing the remaining dentition.

reconstruction with a free vascularised osseous flap and a reconstruction with a free vascularised osseous flap with the subsequent planning of an implant-supported bridge. The patient preferred the latter. Written informed consent was obtained from the patient for this treatment. The treatment was divided into four phases. The first phase was the 3-D pre-planning of the fibula resection and implant positioning related to the needed reconstruction of the mandibular defect (Figure 2). The second phase comprised prefabrication of the fibula by guided implant insertion, digital implant registration, applying a skin graft around the implants and resection of the necrotic bone of the mandible. In the third phase, the implant-supported bridge and the fibula cutting guide were manufactured. The fourth phase included the reconstructive surgery of the mandibular bone defect with the free vascularised fibula flap and the bridge in the proper occlusion and position in the mandible.



**Figure 2:** Virtual planning of a fibula segment derived from a CT scan of the lower leg. The fibula was positioned in the 3-D model of the CBCT of the maxillofacial region and the mandible after the resection. A virtual set-up of the missing molars on premolar was performed in Simplant Crystal. Two implants were planned in an ideal position in the fibula supporting the missing dentition in the optimal prosthetic position for the bridge.

#### 1. Virtual pre-planning of the fibula resection and implant position related to the jaw defect

For virtual pre-planning, the maxillofacial region and the mandible were scanned with cone beam computed tomography (CBCT) (i-CAT, Imaging Sciences International, Hatfield, USA), and the fibula of choice (right or left) was scanned using a CT scanner (Siemens AG Somatom Definition Dual Source, Forchheim, Germany). The maxillofacial scan was imported into ProPlan CMF (Synthes, Solothurn, Switzerland and Materialise, Leuven, Belgium), and a 3-D model was created by volume rendering. The upper and lower dentition were optically scanned using the Lava™ Chairside Oral Scanner C.O.S. (3M™ ESPE™, St. Paul, USA) to retrieve a detailed surface model of the dentition. The surface scan was imported into ProPlan CMF at the correct anatomical location. The first surgical procedure started with the virtual planning and visualisation of the jaw defect. For functional reconstruction, a prefabricated free fibula graft was chosen. The fibula



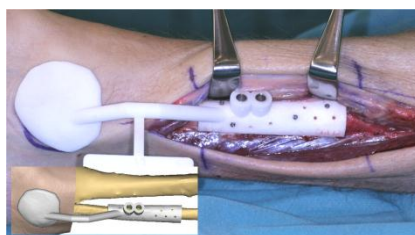
### Full digitally planned secondary mandibular reconstruction (Cont.)

graft has ideal aspects for mandibular reconstruction as it has a substantial cortical layer, assisting in excellent implant stability, a good shape for jaw reconstruction and a vessel with sufficient length to reach the neck vessels for recirculation connection<sup>3</sup>. The reconstruction was planned digitally using ProPlan CMF and Simplant Crystal (Materialise Dental, Leuven, Belgium). The virtual reconstruction started with the CBCT of the maxillofacial region and the mandible. The file was converted and loaded into ProPlan CMF together with the CT scan of the fibula. The fibula segmentation was planned following the jaw defect. A virtual set-up of the missing dentition was performed. Implants were planned in the fibula, supporting the missing dentition in the optimal prosthetic position (Figure 2). The planning was used to produce a drilling template for guided implant placement in the fibula. The drilling guide was planned on the level of the periosteum of the fibula with an extension to the skin of the lateral malleolus for optimal support of the exact planned position. The drilling and cutting guides were sterilised using gamma irradiation.

#### 2. Prefabrication of the fibula

The first surgical step included placement of the dental implants in the fibula by using the drilling guide and digital registration of the implant position. By using a surgical approach of the fibula, comparable to the standard technique used for free vascularised fibula transfer, the ventral rim of the fibula was exposed. The drilling guide was placed in position, with the lateral malleolus as reference, and fixed on the bone with miniscrews (KLS Martin Group, Tuttlingen, Germany) (Figure 3). After the implants (Nobel Speedy and Nobel Biocare AB, Göteborg, Sweden) were placed, the guide was removed. Because guided implant placement always has a small error in implant position compared to the

planned position<sup>9,10</sup>, an intra-operative optical scan of the implants with scan abutments (E.S. Healthcare, Dentsply International Inc., Hasselt, Belgium) was made with the Lava™ Chairside Oral Scanner to register the exact position and angulations. The Lava™ Chairside Oral Scanner is an intra-oral optical scanner developed for scanning crown preparations. The scanner has a very high accuracy, which makes it useful for digitising implant positions and replacing the conventional impression in this process. For research purposes, we registered the position of the implants also by taking a conventional dental impression. Thereafter, the periosteum around the implants was covered with a split skin graft to create a stably attached peri-implant soft-tissue layer, and this was then covered with a Gore-Tex patch (W.L. Gore and Associates, Flagstaff, Ariz). The wound in the lower leg was closed primarily.

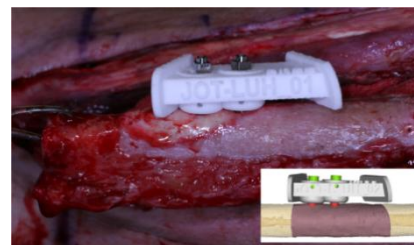

**Figure 3:** The 3-D printed drilling guide is positioned on the ventral rim of the fibula bone in the left lower leg and fixated with miniscrews. The implants were guided through the drilling guide. The insert shows the virtual planning of the guide (ProPlan CMF).

#### 3. Virtual planning of the bridge and cutting guide preceding the second surgical step

The data of the optical scan of the implant positions in the fibula using the Lava™ Chairside Oral Scanner were imported into the Simplant software and manually matched

with the original fibula planning, thereby creating a superimposed fusion model with the accurate position of the implants. The resection margins of the fibula were optimised according to the post-operative CBCT scan of the head. An implant-supported cutting guide of the fibula was then planned and printed (Figure 4). A digital design of the custom bridge abutment was virtually planned on the scanned position of the implants and subsequently converted to a stereolithography (STL) file from which the bridge abutment was milled out of titanium (E.S. Healthcare). The titanium structure was tested on the cast retrieved from the conventional impression and fitted without tension. To position the implant-supported bridge in the correct dimension to the upper and lower dentition, an intermediate occlusal guide with an extension to the implants was virtually planned in Simplant and printed in an STL model (Figure 5). The occlusal guide functioned as an implant positioner in the articulator to finish the bridge with composite. The bridge was planned out of occlusion to keep occlusal forces from interfering with bone healing of the fibula.




**Figure 4:** Selective laser sintering model of the cutting guide fixed on the implants with Nobel guide fixation screws in the left fibula. The insert shows the virtual cutting guide.

#### 4. Reconstructive surgery of the jaw

The second surgical step was planned five weeks after the

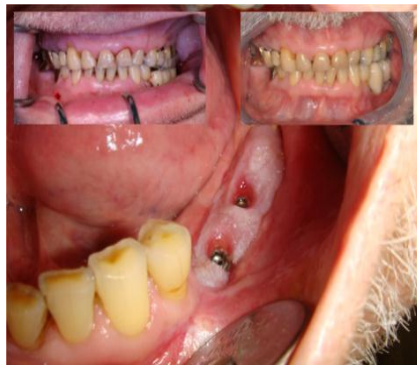### Full digitally planned secondary mandibular reconstruction (Cont.)



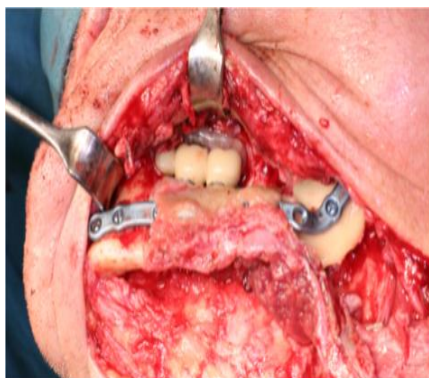**Figure 5:** An intermediate positioning wafer is shown, which is virtually designed in between the upper and lower dentition and the implant position (left panel). The purpose of this wafer is to translate the implant position and virtual planning of the fibula to the articulator. The occlusal guide printed in an STL model in the articulator (middle panel). The implant-supported bridge is fabricated in the correct dimension to the upper and lower dentition to prohibit transmission of occlusal forces on the fibula graft during consolidation. The bridge is deliberately made out of occlusion; a partial occlusal splint maintained this interocclusal space during positioning and fixation of the fibula segment (right panel).

prefabrication procedure to give the implants sufficient time to osseointegrate. The fibula with the implants was harvested while the vascular supply of the fibula stayed intact; the osteotomies were performed using the implant-supported cutting guide. After the osteotomies were performed, the bridge connecting the implants was screwed into place. The edge defects can be optimised to fit the reconstructive planning exactly using cutting guides. The prefabricated fibula with the bridge in place was detached from the veins and placed in the mandibular defect (Figure 6). The

graft was situated intra-orally using a positioning wafer, which was made out of occlusion to prohibit occlusal forces during the consolidation time of the fibula



**Figure 7:** The insert on the left shows the positioning of the bridge, which is deliberately made out of occlusion in the consolidation period of the fibula bone to the mandible. The bridge is finished with composite. The insert on the right shows the bridge after the healing period; the composite was corrected to a better occlusion and crown shape. In the future, the bridge will be finished with ceramic in a more ideal shape. Three months post-operative, the peri-implant soft tissue created by the split skin graft shows a favorable attached lining.



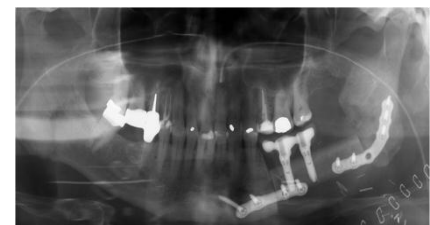
**Figure 6:** Fixation of the fibula was performed with 2.4 mm reconstruction plates. A positioning splint was used to position the bridge and graft out of the occlusion.

graft to the jaw (Figure 7). The skin graft was sutured to the oral mucosa. The patient was discharged from the hospital one week after surgery. A post-operative panoramic radiograph showed the favourable fit of the bridge on the implants (Figure 8).

### Discussion

With this new technique, it is possible to fully plan and perform the secondary reconstruction using optical scanning of the implant position with an intra-oral scanner and manufacturing a bridge by computer aided design-computer aided manufacturing (CAD-CAM) techniques. In contrast to conventional planning, no laboratory steps were needed in virtual planning, and the 3-D printed guides and occlusal guide proved to be accurate and easy to use during the various surgical steps.

Secondary reconstruction of maxillo-mandibular defects using a prefabricated fibula always implies that the patient must be willing to undergo at least two surgical procedures. It is possible to reconstruct such defects without pre-planning and insert implants directly or separately at a later stage. Schmelzeisen et al.<sup>11</sup> have shown that without pre-planning, the positioning of the implants becomes a major problem; implants could be used without placement of more implants in only two of the



**Figure 8:** Post-operative panoramic radiograph showing the well-planned segmentation of the fibula and resection of the mandible. Also, the bridge is well-seated on the implants.



### Discussion (Cont.)

nine patients in whom implants were inserted in the fibula before fixating the fibula in the defect. This observation showed that direct implant placement in a graft without planning is prone to suboptimal placement of the implants. Proper planning and guided placement can prohibit this.

There are three major benefits of using prefabricated fibulas instead of conventional planning: (1) Occlusion-guided implant planning ensures a functional implant position and, thus, a functional graft position. Therefore implant placement and prosthetic rehabilitation are not impaired by wrong placement of implants and bone. (2) The skin graft provides an excellent thin soft-tissue cover around the implants of the fibula bone (Figure 7)<sup>12</sup>. Skin pedicles that come with a free graft are much more bulky and less appropriate for lining implants. In large maxillofacial defects, there is usually not only a lack of bone but also a lack of soft tissue, a problem that can be resolved by the proposed technique. (3) The ischemia time of the flap is limited because segmentation of the fibula and fixation of the bridge on the implants are done in the lower leg, with the vascularisation still being intact. This reduces the time needed to fixate the bone transplant in the jaw defect, thus promoting the chances for flap survival<sup>13</sup>.

Planning backward from the preferred occlusion towards surgical reconstructive surgery may result in the placement of the bone at a different position than would have been the case in conventional reconstructive surgery. In the case we described to illustrate our new technique, this resulted in the placement of the fibula in a higher position in the midline of the mandibular bone instead of aligning it with the lower border of the mandible. This position was chosen to provide optimal support of the fibula

under the bridge without compromising oral hygiene. This resulted in good intra-oral peri-implant conditions of the soft tissues without creating a facial aesthetic problem for the patient (Figure 7).

Titanium abutment bridge structures can be planned digitally and milled highly accurately<sup>14</sup>. However, to date, it has not been possible to finish the bridge with ceramic or composite in a digitised procedure. To be able to finish the titanium bridge structure with composite, the bridge has to be positioned in an articulator together with a cast of the upper and lower dentition. To support this step in the proposed process, an occlusal guide was designed. The purpose of this guide was to translate the digital implant position to the articulator for finishing the bridge with composite. Every step back from a digital situation to plaster models in an articulator is a step back in accuracy and, therefore, undesired. In an ideal digital process, a total CAD-CAM-manufactured ceramic bridge in the appropriate colour should overcome this unwanted extra step of conversion.

The accuracy of the 3-D images produced by intra-oral scanners has not yet been assessed. There is still lack of clinical evidence regarding the limits of these scanners. Intra-oral scanners offer the possibility of digitising preparations of crowns, bridges and single implant positions relative to adjacent teeth. In this case, the scanned area of the fibula is much larger than when applying the scanner for an intra-oral scan. The tensionless fit of this bridge on two implants, as was shown in the case presented, points out how powerful these scanners in combination with CAD-CAM superstructures can be. Future research should aim at determining the accuracy of these intra-oral scanners for their use in larger implant-supported constructions.

From this study, it can be concluded that 3-D virtual planning provides an essential, powerful tool for complex reconstruction of mandibular defects. All necessary guides for this type of surgery can be designed by computer and printed by additive manufacturing. We foresee that for complex reconstructions, 3-D virtual planning combined with additive manufacturing might evolve to the standard approach instead of the use of conventional dental laboratory procedures.

### Consent

Written informed consent was obtained from the patient for publication of this case study and accompanying images.

### References

1. Taylor GI, Miller GD, Ham FJ. The free vascularized bone graft. A clinical extension of microvascular techniques. *Plast Reconstr Surg.* 1975 May;55(5):533-44.
2. Zlotolow IM, Huryn JM, Piro JD, Lenchewski E, Hidalgo DA. Osseointegrated implants and functional prosthetic rehabilitation in microvascular fibula free flap reconstructed mandibles. *Am J Surg.* 1992 Dec;164(6):677-81.
3. Lopez-Arcas JM, Arias J, Castillo JL, Burgueno M, Navarro I, Moran MJ, et al. The fibula osteomyocutaneous flap for mandible reconstruction: A 15-year experience. *J Oral Maxillofac Surg.* 2010 Oct;68(10):2377-84.
4. Cordeiro PG, Disa JJ, Hidalgo DA, Hu QY. Reconstruction of the mandible with osseous free flaps: A 10-year experience with 150 consecutive patients. *Plast Reconstr Surg.* 1999 Oct;104(5):1314-20.
5. Chiapasco M, Biglioli F, Autelitano L, Romeo E, Brusati R. Clinical outcome of dental implants placed in fibula-free flaps used for the reconstruction of maxillo-mandibular defects following ablation for tumors or osteoradionecrosis. *Clin Oral Implants Res.* 2006 Apr;17(2):220-8.
6. Gbara A, Darwich K, Li L, Schmelzle R, Blake F. Long-term results of jaw reconstruction with microsurgical fibula grafts and dental implants. *J Oral Maxillofac Surg.* 2007 May;65(5):1005-9.



### References (Cont.)

7. Rohner D, Jaquier C, Kunz C, Bucher P, Maas H, Hammer B. Maxillofacial reconstruction with prefabricated osseous free flaps: a 3-year experience with 24 patients. *Plast Reconstr Surg.* 2003 Sep;112(3):748–57.
8. Schepers RH, Raghoobar GM, Vissink A, Lahoda LU, Van der Meer WJ, Roodenburg JL, et al. Fully 3-dimensional digitally planned reconstruction of a mandible with a free vascularized fibula and immediate placement of an implant-supported prosthetic construction. *Head Neck.* 2011 Oct 24.
9. de Almeida EO, Pellizzer EP, Goiatto MC, Margonar R, Rocha EP, Freitas AC Jr, et al. Computer-guided surgery in implantology: review of basic concepts. *J Craniofac Surg.* 2010 Nov;21(6):1917–21.
10. Van der Meer WJ, Vissink A, Raghoobar GM, Visser A. Digitally designed surgical guides for placing extra-oral implants in the mastoid area. *Int J Oral Maxillofac Implants.* 2012 May-Jun;27(3):703–7.
11. Schmelzeisen R, Neukam FW, Shirota T, Specht B, Wichmann M. Postoperative function after implant insertion in vascularized bone grafts in maxilla and mandible. *Plast Reconstr Surg.* 1996 Apr;97(4):719–25.
12. Chang YM, Chan CP, Shen YF, Wei FC. Soft tissue management using palatal mucosa around endosteal implants in vascularized composite grafts in the mandible. *Int J Oral Maxillofac Surg.* 1999 Oct;28(5):341–3.
13. Jokuszies A, Niederbichler A, Meyer-Marcotty M, Lahoda LU, Reimers K, Vogt PM. Influence of transendothelial mechanisms on microcirculation: consequences for reperfusion injury after free flap transfer. previous, current, and future aspects. *J Reconstr Microsurg.* 2006 Oct;22(7):513–8.
14. Eliasson A, Wennerberg A, Johansson A, Ortorp A, Jemt T. The precision of fit of milled titanium implant frameworks (I-bridge) in the edentulous jaw. *Clin Implant Dent Relat Res.* 2010 Jun 1;12(2):81–90.

