

Washington University School of Medicine

Digital Commons@Becker

2020-Current year OA Pubs

Open Access Publications

6-2023

Cochlear implantation and audiological findings in a child with Zellweger spectrum disorder

Amit Walia

Amy Lynn Birath


Craig A. Buchman

Follow this and additional works at: https://digitalcommons.wustl.edu/oa_4



Part of the [Medicine and Health Sciences Commons](#)

Please let us know how this document benefits you.



Cochlear implantation and audiological findings in a child with Zellweger spectrum disorder

Amit Walia^{a,*}, Amy Lynn Birath^b, Craig A. Buchman^a

^a Department of Otolaryngology—Head and Neck Surgery, Washington University School of Medicine in St. Louis, St. Louis, Missouri, USA

^b Moog Center for Deaf Education, St. Louis, Missouri, USA

ARTICLE INFO

Keywords:

Zellweger syndrome
Electrocochleography
Peroxisome biogenesis disorder
Cochlear implantation

ABSTRACT

Peroxisome Biogenesis Disorders in the Zellweger Spectrum (PBD-ZSD) are autosomal recessive disorders characterized by defects in functional peroxisomes. Clinical manifestations can range in severity and age at presentation and often include retinitis pigmentosa, neuroregression, and peripheral neuropathy. Although hearing loss is often associated with PBD-ZSD, the site of lesion is poorly understood. This study reports our experience with a child with a moderate form of PBD-ZSD who underwent successful bilateral cochlear implantation for progressive severe-to-profound hearing loss and performs well with the device. The audiological profile was characterized by severe sensorineural hearing loss bilaterally on auditory brainstem responses, reduced cochlear microphonic potentials with absent compound action potential and summing potential on electrocochleography, and clear neural responses on cochlear implant-evoked, electrical compound action potential testing after implantation. These findings suggest a cochlear-neural site of lesion rather than a true auditory neuropathy.

1. Introduction

Peroxisome Biogenesis Disorders in the Zellweger Spectrum (PBD-ZSD) are a group of autosomal recessive disorders characterized by defects in formation of peroxisomes and are a result of mutations in one of 13 *PEX* genes [1–4]. Peroxisomes are crucial for lipid biosynthesis and fatty acid oxidation in eukaryotic cells. Clinically, PBD-ZSD can range from mild to severe phenotypes with core features that include developmental delay and other neurological abnormalities, liver dysfunction, vision impairment, and adrenocortical dysfunction [3,5]. Hearing loss is also an important manifestation of PBD-ZSD that is more often observed in intermediate and milder cases [3,6,7]. Despite being often noted, hearing loss associated with PBD-ZSD is not well understood. Most studies do not provide any specific audiological profile related to the hearing loss [2,8–11]. A few studies have objectively described the hearing loss with soundfield audiometry and/or auditory brainstem responses [1,4]. The objective of this study was to report the audiological profile in a child with intermediate PBD-ZSD who underwent comprehensive, audiological assessment before, during and after bilateral cochlear implantation. The site of lesion associated with hearing loss was evaluated using pure tone audiometry, tympanometry,

acoustically-evoked electrocochleography (ECochG), auditory brainstem response (ABR), and electrically evoked compound action potentials (eCAPs) after cochlear implantation.

2. Case report

KM is a 13-year-old Caucasian female with a history of an intermediate form of PBD-ZSD who presented to our department with progressive bilateral hearing loss since birth. Her past medical history included developmental delay, progressive vision loss as a result of retinitis pigmentosa, adrenal insufficiency, gastrostomy tube dependence as a result of severe dysphagia, and paraparesis of both lower limbs with dystonia. Her hearing loss was first identified as a result of an abnormal newborn hearing screening for both ears. At two months of age, she underwent ABR testing using click stimuli which showed mild hearing loss in the right ear and mild to moderately-severe hearing loss in the left ear (Fig. 1A). Wave I, III, and V were identified at stimulus intensity >40 dB HL, which shifted in latency with increasing intensity of the stimulus; this favored a sensorineural hearing loss etiology rather than an auditory neuropathy spectrum disorder (ANS) phenotype. Based on these ABR results, she was fitted with hearing aids. Behavioral Observation

* Corresponding author. Washington University School of Medicine, Department of Otolaryngology Head & Neck Surgery, 660 S. Euclid Ave. Campus Box 8115, St. Louis, MO, 63110, USA.

E-mail address: amitwalia@wustl.edu (A. Walia).

<https://doi.org/10.1016/j.xocr.2023.100513>

Received 16 December 2022; Received in revised form 13 January 2023; Accepted 25 January 2023

Available online 29 January 2023

2468-5488/© 2023 Published by Elsevier Inc. This is an open access article under the CC BY-NC-ND license (<http://creativecommons.org/licenses/by-nc-nd/4.0/>).

Audiometry was performed from four months of age to nine months of age. During this time, minimum response levels suggested no poorer than a moderately-severe hearing loss bilaterally. At nine months of age, when a reasonably reliable conditioned response was established via Visual Reinforcement Audiometry (VRA), results indicated moderately-severe hearing loss bilaterally. This was a decrease in hearing sensitivity as compared to her original ABR. Follow-up ABR at 2 years of age indicated severe rising to moderately-severe hearing loss bilaterally, confirming the decrease in hearing sensitivity (Fig. 1B). Behavioral hearing evaluation via VRA continued to indicate stable moderately-severe hearing loss bilaterally for eight years. At eight years of age, the patient's parents noticed decreased benefit with binaural hearing aids as the patient had a decline in spoken language and often removed her hearing aids. Prior to this decline, she was speaking in 2-to-4-word phrases. Repeat behavioral hearing evaluation suggested at least a 10-dB shift with now severe hearing loss from 250 Hz to 8 kHz bilaterally (Fig. 2). On otoscopy, both tympanic membranes were normal in appearance. Magnetic resonance imaging of the internal auditory canals and otic capsules bilaterally showed no abnormality. Due to her limited benefit with hearing aids, she underwent cochlear implant evaluation and subsequent bilateral simultaneous cochlear implantation surgery.

Audiological evaluation was carried out at CI candidacy evaluation which included pure tone audiometry and tympanometry. Tympanometry revealed normal ear canal volume, static admittance, and tympanometric peak pressure, indicating typical middle ear function at each ear. Intraoperatively, at the time of implantation, ECochG was performed at the round window as previously described [12]. Briefly, needle electrodes (RhythmLink, Columbia, SC) were placed on the contralateral mastoid and forehead and were the reference and common electrodes, respectively. The recording electrode was a monopolar stainless steel facial nerve monitor probe (Neurosign 3602-00-TE, Magstim Co., Wales, UK). At the time of surgery and after induction of anesthesia, an ER3-14A foam insert (Etymotic, Elk Grove Village, IL) was placed into the external auditory canal of the ear being implanted. The ipsilateral ear was then prepped and draped with the foam insert secured in the ear canal by allowing the auricle to fold anterior over the foam insert. Special care was necessary to ensure that the sound tube was not crimped during the surgical preparation. As previously described, using a facial recess surgical approach [12], the bony overhang over the RW recess was removed and the recording electrode was placed on the RW niche. Impedance levels on all electrodes were <16 kOhms prior to the recording. ECochG recordings were performed using a clinical stimulation/recording device (Interacoustics Eclipse, Demark). A frequency sweep was performed with tone burst (0.25, 0.5, 1, 2 kHz at ~100 dB SPL) stimuli which were delivered alternating in condensation and rarefaction starting phases, with 100 repetitions per phase. The rise and fall times are 1 ms and shaped by a Blackman window. For all frequencies, the recording epoch was 15 ms, starting 1 ms before stimulus onset, with a sampling rate of 20 kHz. A window isolating the ongoing

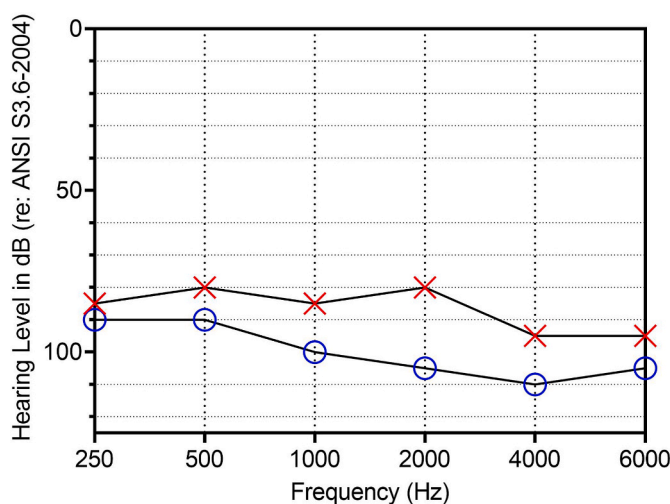


Fig. 2. Pure tone audiometry preoperatively showing air conduction thresholds at cochlear implant candidacy evaluation.

portion of the response waveform was selected for a fast Fourier transformation (FFT) to evaluate the spectral characteristics of the response. Using the FFT, we evaluated the amplitudes of the significant responses at the first, second, and third harmonics across 250 Hz–2 kHz; this provided some insight as to the contribution of the cochlear microphonic (CM) and auditory nerve neurophonic (ANN) to the patient's cochlear function. The ECochG-total response (ECochG-TR), a sum of the gross responsiveness of the cochlea, was then calculated by summing the 1st to 3rd harmonics across the four frequencies. The ECochG-TR for our patient was 6.8 dB re:1 μV. The response was dominated by the cochlear microphonic (Fig. 3); however, these responses were small compared to the average ECochG-TR of pediatric CI recipients [13]. There were also small ANN responses from 250 Hz to 2 kHz. No compound action potential (CAP) or summing potential (SP) was visualized at the tested frequencies, indicating minimal acoustically-evoked neural activity.

After electrocochleography recording, slim perimodiolar electrode arrays (CI632; Cochlear Ltd., Lane Cove, Australia) were successfully fully implanted into both ears. Neural response telemetry (NRT) was used to measure eCAP thresholds. Values were recorded using Auto-NRT software and Custom Sound 5.1 EP Software. The NRT thresholds were found to fall within the normal, average dynamic range bilaterally (Fig. 4). She had an uncomplicated postoperative recovery and was discharged after 24 hours. She followed-up as per protocol for CI recipients.

The patient underwent speech perception tests at 3-months post-activation. Given the patient's language and developmental delays, a limited battery of speech-perception testing was obtained. Auditory-only speech-perception testing was completed using monitored live

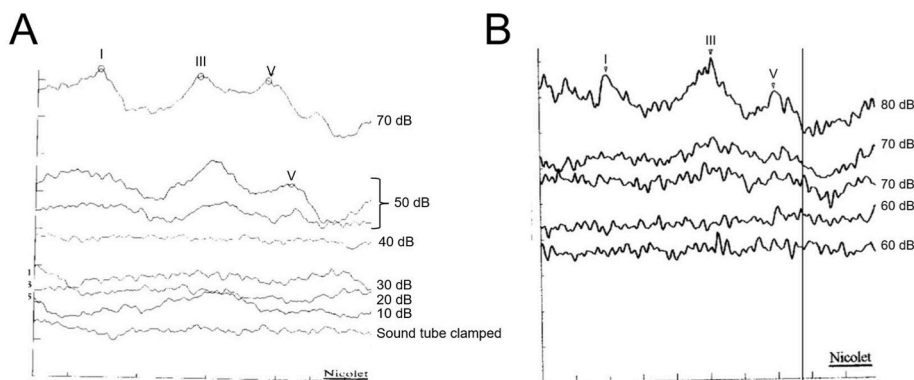


Fig. 1. The auditory brainstem response tracings recorded at (A) 2 months old and (B) 2 years old. Click stimuli were presented from 10 dB HL to 80 dB HL. Waves I, III, and V were present at >40 dB HL at 2 months of age and these waves were only present at >70 dB HL at 2 years of age, suggesting a progression of the patient's sensorineural hearing loss. The shift in latency with increasing intensity of the stimulus and identification of ear-specific thresholds with waves I–V suggest a sensorineural etiology for the hearing loss, rather than an auditory neuropathy spectrum disorder phenotype.

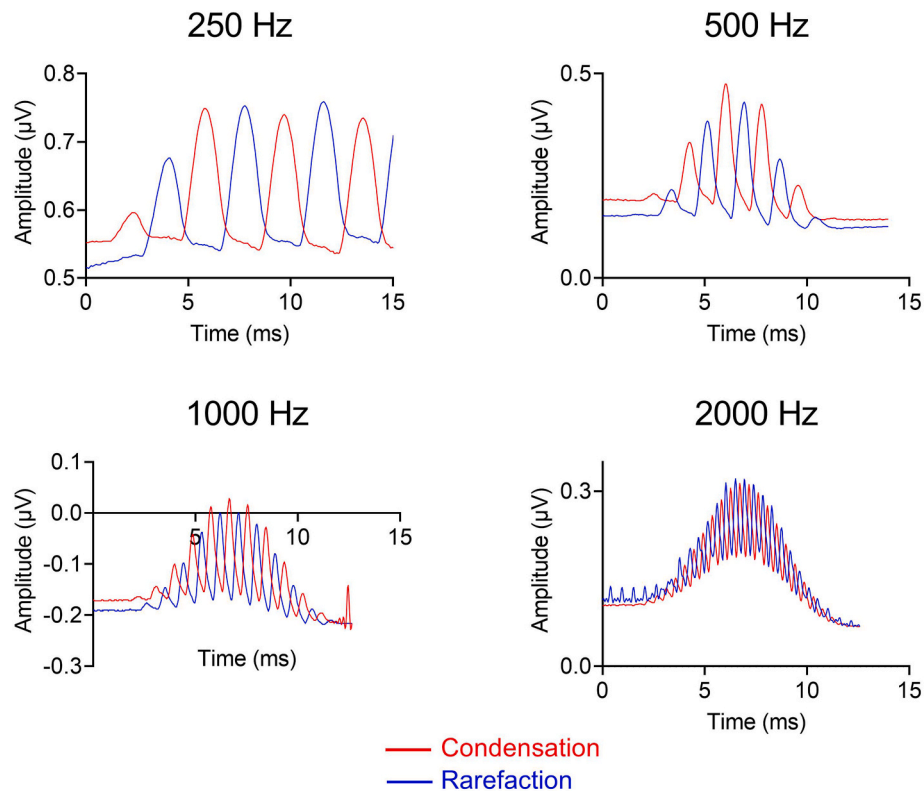


Fig. 3. Acoustically-evoked electrocochleography responses measured through the facial recess at the round window, prior to electrode insertion. Cochlear microphonic responses are dominant with no compound action potential or summing potential, suggesting site of lesion distal to or at the level of the hair cell-auditory nerve synapse.

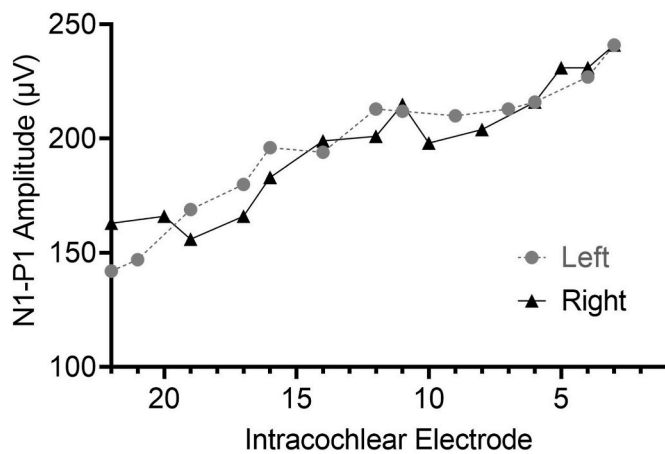


Fig. 4. Neural response telemetry (NRT) threshold for both left (gray dotted line) and right (black line) ears recorded intraoperatively using the slim peri-modiolar electrode array, where e22 was the most-apical electrode and e1 was the most basal electrode. Thresholds were at normal levels across all electrodes.

voice stimuli at 60 dBA SPL (normal conversational level) in the bilateral condition and in quiet. Known one- and two-syllable vocabulary (e.g., cheek, toes, Daddy, shoulder, etc.), familiar phrases (e.g., change the diaper), and familiar questions (e.g., What color is your shirt?) were presented to the patient in the soundfield. Only one repetition per presentation was permitted. The patient responded either by repeating the heard stimulus or pointing to the item/body part named. Of the 20 words/phrases/questions presented, the patient responded to 18 (90% correct) of them. The patient’s mother also completed LittLEARS [14] and The Parents Evaluation of Aural/Oral Performance in Children

(PEACH) [15] auditory questionnaires. LittLEARS consists of 35 questions and the PEACH consists of 13 questions that assess a child’s auditory development. On the LittLEARS, the patient received a score of 20/35, which was below the typical range for her chronological age, but within the typical range for children 20 months of age who have typical hearing. On the PEACH, the patient received a score of 50% in quiet, 45% in noise, and an overall score of 47.5%. Overall, these scores reflect that the patient is below the typical range when compared to same-age peers who have typical hearing; however, these scores are in the typical range for children approximately 16 months of age who have typical hearing. These results must be evaluated in the context of our patient’s language and developmental delays. The patient wears the implants during all waking hours and has clearer speech, can speak in short phrases, and is learning new words (e.g., hippopotamus). She continues to have deterioration in vision emphasizing the importance of hearing as her main sense.

3. Discussion

This report describes the audiologic profile of a patient with an intermediate form of PBD-ZSD. The salient finding on ECoChG was a largely diminished CM amplitude without a CAP or ANN, suggesting a cochlear origin to the hearing loss. Importantly, the normal eCAP thresholds and the significant improvement in speech-perception performance after implantation indicates that the patient has a functional neural substrate.

Although sensorineural hearing loss is frequently described with PBD-ZSD, the descriptions are primarily based on patients with a milder form of PBD-ZSD (i.e., Refsum disease) [16–18]. Phenotypically, hearing can range from normal hearing to profound sensorineural hearing loss in these patients. The onset of hearing loss in these patients is usually between 10 and 30 years of age. The pathology described with this milder form has previously been considered to be related to both the central

nervous system and involvement of the inner ear structures [19,20]. Through the use of temporal bone pathology, Schuknecht [21] explained the hearing loss associated with this milder form of PBD-ZSD to be associated with cochleosacculary atrophy resulting in ~50% loss of cochlear neurons, while Nadol [22] showed that the primary lesion was degeneration of the first-order cochlear neuron in relation with atrophy of organ of Corti and stria vascularis. Vandana et al. were the first to report the audiologic profile in a child with mild PBD-ZSD and noted normal otoacoustic emissions and absent brainstem-evoked potentials, suggesting auditory neuropathy as the primary etiology for hearing loss [18]. No prior study has used ECoChG, a near-field response, to understand the site of lesion in patients with PBD-ZSD. Understanding the site of pathology is critical as success with hearing interventions such as hearing aids and cochlear implants is dependent upon the site of lesion.

A few recent studies [23–25] have used acoustically-evoked ECoChG responses as potential markers to understand the site of lesion in patients with hearing loss. The SP, CAP, ANN, and dendritic potentials as measured from ECoChG have previously been used as markers of distal neuronal injury [23,24]. For example, if there is evidence of neural activity on ECoChG, the site of lesion is likely proximal to the inner hair cell-auditory nerve synapse. For our patient, there was a markedly decreased CM amplitude compared to normal subjects with absence of CAP and SP (Fig. 3). This supports the cochlear origin of hearing loss, where the site of lesion is likely at the level or distal to the hair cell-auditory nerve synapse.

The site of the lesion being peripheral to the level of the auditory nerve is further supported by the patient's success with cochlear implantation as demonstrated by the normal eCAP thresholds on NRT after implantation and the significant benefit obtained in speech perception after implantation. This again suggests that the pathology is not at the level of the auditory nerve or central auditory pathways but rather at the level of the hair cells and/or synapse with the afferent fibers. The lack of an ANSD pattern on ABR testing further support a site of lesion similar to that reported by Schuknecht [21] and Nadol [22] rather than that described as ANSD by Vandana et al. [18]. Clearly, differences in PBD-ZSD severity between their patient and our may explain these observations.

Early identification of hearing loss in patients with PBD-ZSD is critical as these patients have progressive vision loss and anosmia and are reliant on hearing as their main sense [3]. This is especially important in children as it can compromise pre- or post-lingual language acquisition. Management of hearing loss in these patients is focused on restoring compromised auditory processing which may be either through hearing aids, alternative forms of communications such as cued speech or sign language, or by cochlear implantation. Three previous reports have described benefit of cochlear implantation in adult patients with mild PBD-ZSD (age range, 59–65) and all patients showed better speech perception performance and quality of life after implantation [26–28]. The type of hearing loss was never characterized in these previous reports. Currently, there is no evidence regarding benefits of cochlear implantation in patients with moderate to severe forms of PBD-ZSD. This case report provides some support for bilateral cochlear implantation in patients with this rare condition.

4. Conclusion

This report highlights the cochlear-neural site of lesion for hearing loss in this patient with moderate PBD-ZSD and the significant benefit that cochlear implants can provide for this pathology. Early cochlear implantation may be considered in these patients as this is likely to lead to a dramatic improvement in quality of life, particularly when hearing loss is combined with deterioration in vision. Future studies should continue to characterize the hearing loss using ECoChG in addition to pure tone audiometry, tympanometry, and ABR for accurate diagnosis in these patients. This has the potential to improve management and interventions related to hearing loss and thus improving quality of life.

Funding

This work was supported by the American Hearing Research Foundation. AW was supported by NIH/NIDCD institutional training grant T32DC000022.

Declaration of competing interest

The authors declare the following financial interests/personal relationships which may be considered as potential competing interests: Amit Walia reports financial support was provided by National Institutes of Health. Craig A. Buchman – consultant for Advanced Bionics, Cochlear Ltd., Envoy, and IotaMotion, and has equity interest in Advanced Cochlear Diagnostics, LLC.

Acknowledgements

None.

References

- [1] Raas-Rothschild A, Wanders RJ, Mooijer PA, et al. A PEX6-defective peroxisomal biogenesis disorder with severe phenotype in an infant, versus mild phenotype resembling Usher syndrome in the affected parents. *Am J Hum Genet* 2002;70(4): 1062–8.
- [2] Poll-The BT, Gootjes J, Duran M, et al. Peroxisome biogenesis disorders with prolonged survival: phenotypic expression in a cohort of 31 patients. *Am J Med Genet* 2004;126a(4):333–8.
- [3] Braverman NE, D'Agostino MD, Maclean GE. Peroxisome biogenesis disorders: biological, clinical and pathophysiological perspectives. *Developmental disabilities research reviews* 2013;17(3):187–96.
- [4] Berendse K, Engelen M, Ferdinandusse S, et al. Zellweger spectrum disorders: clinical manifestations in patients surviving into adulthood. *J Inher Metab Dis* 2016;39(1):93–106. <https://pubmed.ncbi.nlm.nih.gov/26287655>. <https://www.ncbi.nlm.nih.gov/pmc/articles/PMC4710674/>.
- [5] Weller S, Gould SJ, Valle D. Peroxisome biogenesis disorders. *Annu Rev Genom Hum Genet* 2003;4(1):165–211. <https://doi.org/10.1146/annurev.genom.4.070802.110424>.
- [6] Braverman NE, Raymond GV, Rizzo WB, et al. Peroxisome biogenesis disorders in the Zellweger spectrum: an overview of current diagnosis, clinical manifestations, and treatment guidelines. *Mol Genet Metab* 2016;117(3):313–21.
- [7] Moser AB, Rasmussen M, Naidu S, et al. Phenotype of patients with peroxisomal disorders subdivided into sixteen complementation groups. *J Pediatr* 1995;127(1): 13–22.
- [8] Wilson GN, Holmes RG, Custer J, et al. Zellweger syndrome: diagnostic assays, syndrome delineation, and potential therapy. *Am J Med Genet* 1986;24(1):69–82.
- [9] Theil AC, Schutgens RB, Wanders RJ, Heymans HS. Clinical recognition of patients affected by a peroxisomal disorder: a retrospective study in 40 patients. *Eur J Pediatr* 1992;151(2):117–20.
- [10] Lee PR, Raymond GV. Child neurology: Zellweger syndrome. *Neurology* 2013;80(20). e207–e210. <https://pubmed.ncbi.nlm.nih.gov/23671347>. <https://www.ncbi.nlm.nih.gov/pmc/articles/PMC3908348/>.
- [11] Gunduz M, Unal O. Dysmorphic facial features and other clinical characteristics in two patients with PEX1 gene mutations. *Case Reports in Pediatrics* 2016;5175709. <https://doi.org/10.1155/2016/5175709>. 2016.
- [12] Fitzpatrick DC, Campbell AP, Choudhury B, et al. Round window electrocochleography just before cochlear implantation: relationship to word recognition outcomes in adults. *Otol Neurotol* : official publication of the American Otological Society, American Neurotology Society [and] European Academy of Otolology and Neurotology 2014;35(1):64–71.
- [13] Fontenot TE, Giardina CK, Dillon M, et al. Residual cochlear function in adults and children receiving cochlear implants: correlations with speech perception outcomes. *Ear Hear* 2019;40(3):577–91.
- [14] Coninx F, Weichbold V, Tsiakpini L, et al. Validation of the LittleEARS® auditory questionnaire in children with normal hearing. *Int J Pediatr Otorhinolaryngol* 2009;73(12):1761–8. <https://www.sciencedirect.com/science/article/pii/S0165587609005230>.
- [15] Ching TYC, Hill M. The parents' evaluation of aural/oral performance of children (PEACH) scale: normative data. *J Am Acad Audiol* 2007;18:220–35. 03.
- [16] Bamiou DE, Spraggs PR, Gibberd FB, Sidey MC, Luxon LM. Hearing loss in adult Refsum's disease. *Clin Otolaryngol Allied Sci* 2003;28(3):227–30.
- [17] Baldwin EJ, Gibberd FB, Harley C, et al. The effectiveness of long-term dietary therapy in the treatment of adult Refsum disease 2010;81(9):954–7.
- [18] Vandana VP, Bindu PS, Nagappa M, Sinha S, Taly AB. Audiological findings in infantile Refsum disease. *Int J Pediatr Otorhinolaryngol* 2015;79(8):1366–9.
- [19] Rake M, Saunders M. Refsum's disease: a disorder of lipid metabolism. *J Neurol Neurosurg Psychiatry* 1966;29(5):417–22. <https://pubmed.ncbi.nlm.nih.gov/v/4162745>. <https://www.ncbi.nlm.nih.gov/pmc/articles/PMC496071/>.

- [20] Hallpike C. Observations on the structural basis of two rare varieties of hereditary deafness. In: Ciba foundation symposium-myotatic, kinesthetic and vestibular mechanisms. Wiley Online Library; 1967. p. 285–94.
- [21] Schuknecht HF. Pathology of the ear. Cambridge: Harvard University; 1976.
- [22] Nadol JB. Primary cochlear neuronal degeneration in Auditory neuropathy: a new perspective on hearing disorders. In: Sininger Y, Starr A, editors. Singular; 2001. p. 99–140.
- [23] McMahon CM, Patuzzi RB, Gibson WP, Sanli H. Frequency-specific electrocochleography indicates that presynaptic and postsynaptic mechanisms of auditory neuropathy exist. *Ear Hear* 2008;29(3):314–25.
- [24] Santarelli R, Starr A, Michalewski HJ, Arslan E. Neural and receptor cochlear potentials obtained by transtympanic electrocochleography in auditory neuropathy. *Clin Neurophysiol* 2008;119(5):1028–41. <https://www.sciencedirect.com/science/article/pii/S1388245708000448>.
- [25] Fontenot TE, Giardina CK, Teagle HF, et al. Clinical role of electrocochleography in children with auditory neuropathy spectrum disorder. *Int J Pediatr Otorhinolaryngol* 2017;99:120–7.
- [26] Nogueira C, Meehan T, O'Donoghue G. Refsum's disease and cochlear implantation. *Ann Otol Rhinol Laryngol* 2014;123(6):425–7.
- [27] Raine CH, Kurukulasuriya MF, Bajaj Y, Strachan DR. Cochlear implantation in Refsum's disease. *Cochlear Implants Int* 2008;9(2):97–102.
- [28] Stähr K, Kuechler A, Gencik M, et al. Cochlear implantation in siblings with refsum's disease. *Ann Otol Rhinol Laryngol* 2017;126(8):611–4.