

Washington University School of Medicine

Digital Commons@Becker

---

2020-Current year OA Pubs

Open Access Publications

---

1-1-2023

## The rate and predictors of healing of repaired lesser tuberosity osteotomy in reverse total shoulder arthroplasty

Benjamin Zmistowski

*Washington University School of Medicine in St. Louis*

Sean V Cahill

*Washington University School of Medicine in St. Louis*

J Ryan Hill

*Washington University School of Medicine in St. Louis*

Joseph T Gibian

*Washington University School of Medicine in St. Louis*

Ruba Sokrab

*Washington University School of Medicine in St. Louis*

*See next page for additional authors*

Follow this and additional works at: [https://digitalcommons.wustl.edu/oa\\_4](https://digitalcommons.wustl.edu/oa_4)



Part of the [Medicine and Health Sciences Commons](#)

Please let us know how this document benefits you.

---

### Recommended Citation

Zmistowski, Benjamin; Cahill, Sean V; Hill, J Ryan; Gibian, Joseph T; Sokrab, Ruba; Keener, Jay D; and Aleem, Alexander W, "The rate and predictors of healing of repaired lesser tuberosity osteotomy in reverse total shoulder arthroplasty." *JSES International*. 7, 1. 10 - 15. (2023).

[https://digitalcommons.wustl.edu/oa\\_4/2317](https://digitalcommons.wustl.edu/oa_4/2317)

This Open Access Publication is brought to you for free and open access by the Open Access Publications at Digital Commons@Becker. It has been accepted for inclusion in 2020-Current year OA Pubs by an authorized administrator of Digital Commons@Becker. For more information, please contact [vanam@wustl.edu](mailto:vanam@wustl.edu).

---

**Authors**

Benjamin Zmistowski, Sean V Cahill, J Ryan Hill, Joseph T Gibian, Ruba Sokrab, Jay D Keener, and Alexander W Aleem



## The rate and predictors of healing of repaired lesser tuberosity osteotomy in reverse total shoulder arthroplasty

Benjamin Zmistowski, MD\*, Sean V. Cahill, MD, J. Ryan Hill, MD, Joseph T. Gibian, MD, Ruba Sokrab, BS, Jay D. Keener, MD, Alexander W. Aleem, MD

Department of Orthopaedic Surgery, Washington University, St. Louis, MO, USA



### ARTICLE INFO

#### Keywords:

Subscapularis  
Reverse total shoulder arthroplasty  
Lesser tuberosity osteotomy  
Repair  
Healing  
Internal rotation

Level of evidence: Level III; Retrospective Cohort Comparison; Prognosis Study

**Background:** Evidence is building that a functional subscapularis improves function—specifically internal rotation tasks—following reverse total shoulder arthroplasty (rTSA). However, the optimal method for subscapularis repair during rTSA remains unknown with variable healing rates reported. This study aims to investigate the rate of and predictors for healing a lesser tuberosity osteotomy (LTO) following rTSA.

**Methods:** Following local institutional review board approval, patients with at least one-year follow-up for rTSA managed with an LTO and subsequent repair between March, 2017 and March, 2020 were retrospectively identified. Shoulders were selected for LTO repair based upon preoperative imaging and intraoperative assessment of subscapularis quality. All patients were implanted with a system consisting of a 150° or 155° (constrained) humeral neck-shaft angle and 2.5 to 4.5 millimeters (mm) of glenoid lateralization (Trabecular Metal Reverse Shoulder System; Zimmer Biomet, Warsaw, IN, USA). At a minimum of six months, radiographs were reviewed for an assessment of LTO healing by three independent reviewers. Healing was classified as displaced, fibrous union, or ossified union. For assessing predictors, the repair was considered intact if the LTO fragment was not displaced (fibrous union or ossified union).

**Results:** Sixty-five rTSA with LTO repair were performed in 64 patients. These patients had an average age of 67.2 years (range, 31–81) and 36 (55.4%; 36/65) were female. At an average follow-up of 15.2 months (range, 8–38), 50 cases (76.9%; 50/65) were classified as having an ossified union. The radiographic healing could not be assessed in a single case. Of the 14 cases without ossific union, 8 (12.3%; 8/65) were displaced and 6 (9.2%; 6/65) were classified as a fibrous union. In logistic regression, only combined humeral liner height predicted LTO displacement (odds ratio = 1.4 [95% confidence interval = 1.1–1.8];  $P = .01$ ). Humeral loosening was not found in any cases following LTO.

**Conclusion:** This analysis demonstrates that radiographic healing of LTO repair is more favorable than published rates of healing after subscapularis tenotomy or peel in the setting of rTSA. Subscapularis management with LTO provides the ability to monitor repair integrity with plain radiographs and a predictable radiographic healing rate. The integrity of subscapularis repair may be influenced by the use of thicker humeral liners. Further investigation is needed to determine the functional impact of a healed subscapularis following rTSA.

Published by Elsevier Inc. on behalf of American Shoulder and Elbow Surgeons. This is an open access article under the CC BY-NC-ND license (<http://creativecommons.org/licenses/by-nc-nd/4.0/>).

Reverse total shoulder arthroplasty (rTSA) provides consistent improvement in pain and shoulder function in the setting of a variety of expanding indications.<sup>2</sup> However, functional limitations associated with rTSA, especially decreased internal rotation and

instability, have not been fully resolved.<sup>11</sup> Although debatable, some authors have advocated for subscapularis repair when performing rTSA, in attempts to improve behind-the-back function, internal rotation strength and possibly decrease the rate of prosthetic instability.<sup>12,15</sup>

Choice of subscapularis management (subscapularis tenotomy, subscapularis peel, and lesser tuberosity osteotomy [LTO]) in anatomic total shoulder arthroplasty has not been shown to consistently affect clinical outcomes,<sup>14,16</sup> despite evidence suggesting that a lesser tuberosity osteotomy provides favorable biomechanical strength and healing rates.<sup>13,18</sup> Healing of the

Institutional review board approval was obtained from the Washington University in St. Louis Institutional Review Board (Approval Date: 4/5/21; IRB#: 202104094).

\*Corresponding author: Benjamin Zmistowski, MD, Department of Orthopaedic Surgery, Washington University in St. Louis, 660 S. Euclid Ave. Campus Box 8233, St. Louis, MO 63110, USA.

E-mail address: [bzmistowski@wustl.edu](mailto:bzmistowski@wustl.edu) (B. Zmistowski).

<https://doi.org/10.1016/j.jseint.2022.09.007>

2666-6383/Published by Elsevier Inc. on behalf of American Shoulder and Elbow Surgeons. This is an open access article under the CC BY-NC-ND license (<http://creativecommons.org/licenses/by-nc-nd/4.0/>).

subscapularis in the setting of rTSA, however, remains poorly understood. Given the altered joint position and glenohumeral kinematics of rTSA compared to anatomic total shoulder arthroplasty, there are theoretical concerns regarding subscapularis healing potential.<sup>3,9,10</sup> Some have questioned whether effective healing occurs with soft tissue subscapularis repair techniques in the setting of rTSA.<sup>5</sup> Using an rTSA system with a lateralized glenoid and medialized humerus, Collin et al reported a 52% healing rate on ultrasound following repair of a subscapularis tenotomy.<sup>4</sup> Importantly, these authors reported improved functional internal rotation in patients with a healed subscapularis repair. Given the potential influence of subscapularis integrity on functional outcomes following rTSA, further studies are needed to determine the method of repair that maximizes healing. LTO for subscapularis management and repair provides theoretical advantages of subscapularis integrity following rTSA. This study aims to (a) quantify the healing rate and (b) determine predictors of healing for this unique approach. It is hypothesized that in the setting of rTSA, LTO repair will provide a superior healing rate compared to other subscapularis management techniques, and that meaningful predictors of LTO healing will be identified.

## Methods

Following local institutional review board approval, a retrospective analysis was undertaken. All patients undergoing primary rTSA with a repaired LTO by one of two shoulder and elbow fellowship-trained surgeons at a single academic institution between 2017 and 2020 with an identical rTSA implant were identified. Patients undergoing rTSA for fracture or revision arthroplasty were excluded. Minimum follow-up for inclusion was 6 months with plain radiographs that included an anteroposterior, Grashey, Scapular-Y, and axillary lateral.

The decision to perform and repair an LTO was based upon preoperative imaging and intraoperative assessment of subscapularis integrity. Specifically, repair was only considered if > 2/3 of the subscapularis was still intact on visual inspection and the LTO could be repaired with the arm in 30° of external rotation at the side after rTSA implantation. After release of the rotator interval tissue, the LTO was created with an oscillating saw which began at the deep medial aspect of the bicipital groove moving from lateral to medial. In cases where a portion of the humeral head remained attached to the LTO fragment, this was removed prior to LTO repair to facilitate anatomic reduction to the tuberosity bed. All patients received an rTSA system consisting of 150° or 155° (constrained) humeral neck-shaft angle and 2.5 to 4.5 millimeters (mm) of glenoid lateralization (Trabecular Metal Reverse Shoulder System; Zimmer Biomet, Warsaw, IN, USA). The length of the humeral spacer/liner construct was individualized based on intraoperative stability trialing parameters. Prior to stem insertion, four drill tunnels were placed lateral to the bicipital groove. Four #5 nonabsorbable sutures (FiberWire; Arthrex, Naples, FL, USA) were passed through these drill tunnels with the three most inferior sutures passed around the stem (Fig. 1). After final reduction, these sutures were then passed just medial to the subscapularis tendon-bone junction and tied, securing the LTO fragment to the proximal humerus. Bone grafting was not routinely performed. Postoperatively, patients were immobilized in a sling for two weeks prior to initiating passive and active-assisted range of motion in forward elevation and external rotation. Patients were instructed to avoid motion behind the back (active internal rotation in adduction) for the first six postoperative weeks.

During clinical follow-up, standard radiographs were obtained at two weeks, six-eight weeks, three months, one year, and two

years. To classify radiographic LTO healing, the categories described by Small et al were utilized<sup>17</sup> (Fig. 2). Films at all time-points were reviewed independently by three reviewers (JDK, BMZ, JRH) with the most recent films used to determine the final healing classification. In cases of disagreement among raters, the consensus of 2 out of 3 observers was used to establish the LTO healing status. For those patients with displaced LTO, time to displacement was also determined.

In addition, patient and surgical characteristics were gathered to assess variables that may predict LTO healing in the setting of rTSA. This included age, gender, humeral spacer/polyethylene liner thickness, and glenoid lateralization. Within this specific rTSA system, metal spacers can be utilized in conjunction with a polyethylene liner to increase the overall humeral height. Therefore, if a metal spacer was utilized, liner size was an aggregate of the spacer size and the polyethylene thickness. For this analysis, cases were considered to have a healed LTO if there was osseous union or a fibrous union (non-displaced).

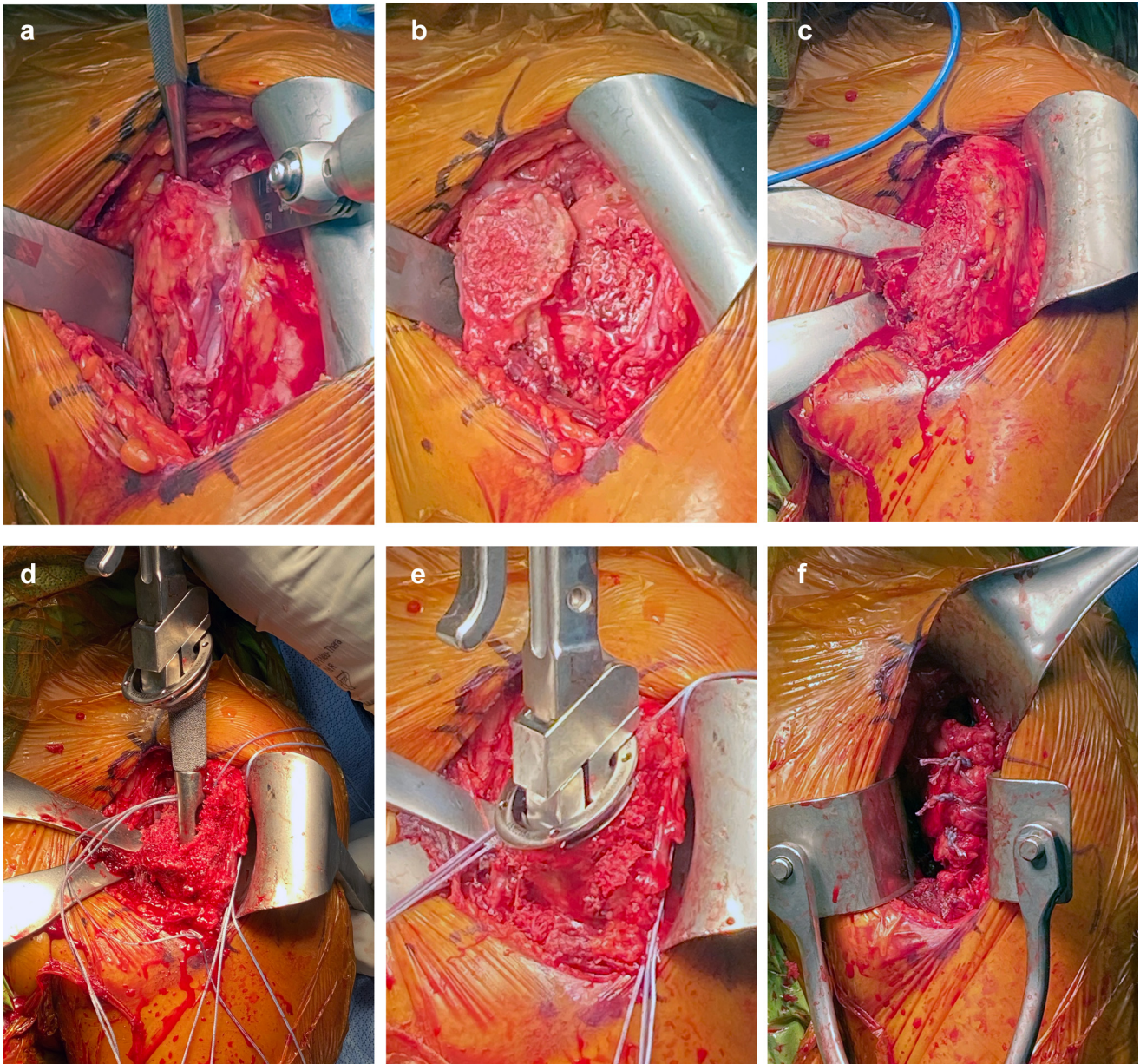
Descriptive statistics were used to describe demographic factors of the cohort. Intraobserver and interobserver reliability were calculated using Fleiss' kappa to grade the reliability of measurement among the three observers.<sup>8</sup> To assess predictors of radiographic LTO healing, appropriate univariate statistical tests were used for continuous and categorical variables. Statistical significance was defined as *P*-value <.05. To determine independent predictors of LTO repair failure, logistic regression was performed in which all tested variables were included with a forced entry. For predictive continuous variables, a receiver operating characteristic curve was analyzed to determine a threshold that predicted LTO repair failure. Youden's *J*-statistic was utilized to calculate this diagnostic threshold.

## Results

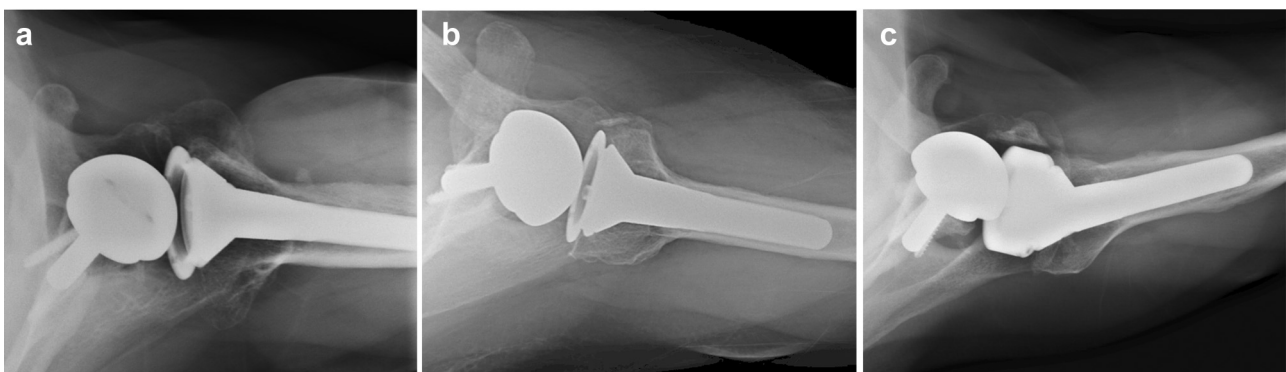
The final cohort consisted of 65 shoulders in 64 patients. The mean age of patients at the time of surgery was 67.5 years (range, 31–81; Table 1) and 36 (55.4%; 36/65) were women. The mean follow-up time was 15.2 (range, 8–39) months. Only 8 cases had a displaced LTO nonunion at the time of the latest follow-up (8/65; 12.3%). In a single case, the LTO could not be visualized as displaced or healed by a majority of the reviewers. Of the 56 with non-displaced LTO, 50 (50/65; 77% of entire cohort) had bony union and 6 (6/65; 9%) were fibrous union. In this early follow-up period, there was no evidence of stem subsidence or humeral loosening in any cases. Interobserver reliability for determination of LTO healing was substantial with kappa value of 0.74 (substantial agreement), both for full classification and for dichotomous healed versus not healed (displaced). In 55 cases (84.6%; 55/65), all three reviewers independently agreed. In the remaining cases, 2 of the 3 reviewers agreed during the independent review.

When comparing healed versus non-healed (displaced) LTO, there was no difference in the age (67.1 vs. 67.6 years; *P* = .89). Male patients were more likely to develop an LTO nonunion (24.1%; 7/29) compared to females (2.8%; 1/35; *P* = .02; Fig. 3). Females were more likely to develop a non-displaced fibrous union (14.3%; 5/35) than males (3.4%; 1/29; *P* = .02). Patients with an LTO nonunion had a thicker humeral liner (mean 6.75 mm; standard deviation (SD) = 4.7) compared to those with an intact LTO repair (mean 2.0 mm; SD = 2.4; *P* < .001). No statistically significant difference was noted between males (3.1 mm; SD = 4.0) and females (2.0 mm; SD = 2.2; *P* = .07) for humeral liner thickness. On multivariate logistic regression, overall liner height was the only significant predictor of LTO displacement with a 1 mm increase in liner height associated with a 40% increase in the odds for LTO displacement (odds ratio = 1.4 [95% confidence interval = 1.1–1.9]; *P* = .01).





**Figure 1** Intraoperative photographs detailing (a) saw placement for lesser tuberosity osteotomy, (b) completed lesser tuberosity osteotomy, (c) placement for drill tunnels lateral to the bicipital groove, (d) heavy-braided sutures passed through the drill tunnels around the stem, (e) impacted stem with secured sutures, and (f) repaired lesser tuberosity osteotomy.

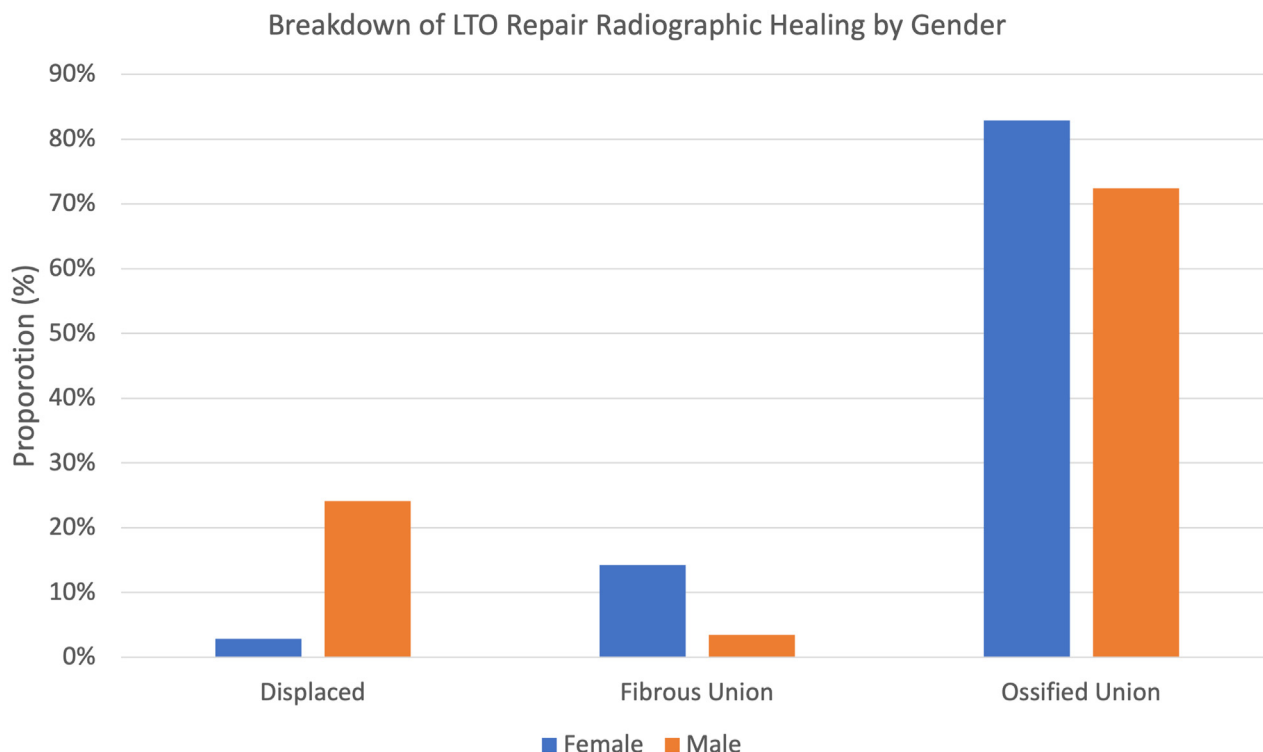


**Figure 2** Examples of radiographic (a) ossified union, (b) fibrous nonunion, and (c) displaced nonunion following LTO repair in the setting of rTSA. LTO, lesser tuberosity osteotomy; rTSA, reverse total shoulder arthroplasty.

**Table 1**  
Cohort characteristics and breakdown by LTO healing.

Variable	Entire cohort	Displaced LTO	Ossified or fibrous union	P-value
Age (mean; SD)	67.3 (8.9)	67.1 (9.4)	67.6 (3.8)	.90
Gender				
Male (n; %)	29 (44.6%)	7 (87.5%)	22 (39.2%)	.02
Female (n; %)	36 (55.4%)	1 (12.5%)	34 (60.7%)	
Liner thickness (mean; SD)	2.6 (3.2)	6.75 (4.7)	2.0 (2.4)	<.001

n, count; SD, standard deviation; LTO, lesser tuberosity osteotomy.



**Figure 3** Breakdown of radiographic healing following LTO repair in the setting of rTSA, stratified by gender. LTO, lesser tuberosity osteotomy; rTSA, reverse total shoulder arthroplasty.

Receiver operating characteristic analysis (area under the curve = 0.74) demonstrated a sensitivity and specificity of radiographic failure for LTO healing of 85.7% and 55.6%, respectively, for a liner thickness of 4.5 millimeters or greater.

**Discussion**

Subscapularis repair during rTSA remains a controversial topic with theoretical but poorly defined advantages. Some authors suggest improved internal rotation and decreased risk for instability with subscapularis repair,<sup>12,15</sup> while others have highlighted the poor healing rate of subscapularis repair with tenotomy<sup>1,4</sup> or peel.<sup>7</sup> This study aimed to understand the radiographic healing rate of traditional LTO repair using a single rTSA system with a valgus humeral stem and slight lateral glenoid offset. Only 12.3% of repaired LTO in this rTSA cohort were displaced at the latest follow-up. Furthermore, over three-quarters of the cohort achieved an ossified union of the LTO.

The healing rates reported in this study are substantially higher than healing following rTSA with other methods of subscapularis management. Using a Grammont-style implant, de Boer et al found that only 40% of selectively repaired subscapularis tenotomies were intact on ultrasound at a minimum of 12 months.<sup>1</sup> They were

unable to detect a difference in functional scores based upon subscapularis repair or postrepair integrity. Similarly, Collin et al found a marginal healing rate (52.6%) for patients undergoing rTSA with a Grammont style implant with lateralized placement of the glenoid component via bone-graft and selective subscapularis tenotomy repair.<sup>4</sup> While they also noted no difference in patient-reported outcome measures, they did find that patients with an intact subscapularis demonstrated significantly greater internal rotation with no loss of external rotation. In contrast, Erickson et al reported an 83.3% healing rate on ultrasound of a double row subscapularis peel repair following rTSA with a 135° humeral neck-shaft angle.<sup>7</sup> They also did not note a difference in patient-reported outcomes of range of motion based upon postoperative subscapularis integrity. Lastly, Dedy et al reported on the subscapularis integrity of a cohort of patients treated with mixed subscapularis management techniques (48% LTO) and a mix of Grammont style implants.<sup>6</sup> They found that 77% of cases had a subscapularis in continuity. However, a majority of the cohort had a subscapularis that was mildly (33%) or severely (31%) attenuated. In their analysis, subscapularis integrity did not appear to impact patient-reported outcomes but did influence achievable internal rotation.

In addition to finding a high incidence of healing, this study identified that at-risk repairs may be predictable. Multivariate



analysis demonstrated that polyethylene liner thickness is independently associated with LTO displacement. The majority of displaced LTO nonunions in this cohort occurred in males. However, men trended toward having an increased liner thickness. The humeral implant used in this study is characterized by a valgus neck-shaft angle, leading to relatively greater distalization with increasing liner thickness compared to a system with a varus humeral implant. Increasing the humeral liner thickness may place greater strain on the repair and ultimately lead to early failure. Conceptually, this may explain the variability in previous reports of subscapularis healing,<sup>1,4,7</sup> with higher healing rates associated with systems utilizing humeral implants with more varus neck-shaft angles.<sup>7</sup> Decreasing tension through smaller humeral liners in a Grammont-style system may improve LTO union rates without compromising prosthetic stability, as prior literature suggests improved stability with subscapularis repair.

The findings of this analysis must be interpreted in light of its limitations. First, this is a retrospective analysis with many confounding variables that cannot easily be controlled for, including surgeon bias toward which patients were considered for subscapularis repair, and variable indications for surgery. This complicates the assessment of predictors for displacement following LTO repair. Given the selective use of subscapularis repair, findings of this study would have limited applicability to shoulders with advanced subscapularis damage and/or contracture.

All repairs in this study were performed in a similar technique using the same humeral stem and a consistent range of glenoid offset. In the presence of reasonable subscapularis tissue quality, this method of repair produces consistent healing results. The goal of this study was to report radiographic rates of LTO union. Ossific or fibrous union of an LTO repair does not necessarily dictate a healthy and functional subscapularis tendon, and we cannot make conclusions about association of healing with clinical function. In this analysis, there was no utilization of ultrasound or computed tomography to further confirm subscapularis integrity. Other analyses have demonstrated some clinical improvement with subscapularis repair and subsequent integrity. While we note a suspected improvement in subscapularis integrity with an LTO repair in this setting, we make no effort to correlate this with clinical outcomes. We report that humeral liner thickness has a significant impact on LTO displacement. However, we did not account for the humeral stem placement or any further radiographic parameters that may dictate humeral liner thickness. Although this was a single implant system and single repair technique, findings of radiographic union may not be reproducible in systems with greater lateralization and/or varus humeral neck-shaft angles. Finally, given the retrospective nature of this study, we did not precisely control for the size or dimension of the LTO fragment. Bony surface area for healing could have a potential influence of healing rates following LTO repair. Despite this potential flaw, we were able to discern the position of the LTO in all but one case and were able to demonstrate a consistent rate of LTO healing across a nonuniform range of LTO sizes in this cohort.

## Conclusion

In conclusion, subscapularis repair through a lesser tuberosity osteotomy has a high rate of radiographic healing compared to other repair constructs described. Furthermore, repair of the subscapularis with an LTO in the setting of rTSA allows for reproducible radiographic monitoring of the repair integrity with plain radiographs. Consideration should be given to minimizing humeral liner thickness when attempting to repair the subscapularis with a more

valgus humeral stem. More research is needed to truly understand the impact of a repaired and functional subscapularis on functional outcomes following rTSA.

## Disclaimers:

Funding: No funding was disclosed by the authors.  
 Conflicts of interest: Jay D. Keener, MD Research support – National Institute of Health; Consultant – Shoulder Innovations and Wright Medical; Royalties – Shoulder Innovations and Wright Medical; Assistant Editor - Journal of Shoulder and Elbow Surgery, Associate Editor – Seminars in Shoulder Arthroplasty: JSES.  
 Alexander W. Aleem, MD is a paid consultant for Wright Medical. Benjamin Zmistowski is a paid consultant for Zimmer-Biomet. The other authors, their immediate families, and any research foundation with which they are affiliated have not received any financial payments or other benefits from any commercial entity related to the subject of this article.

## References

- de Boer FA, van Kampen PM, Huijsmans PE. The influence of subscapularis tendon reattachment on range of motion in reversed shoulder arthroplasty: a clinical study. *Musculoskelet Surg* 2016;100:121-6. <https://doi.org/10.1007/s12306-016-0401-8>.
- Chalmers PN, Keener JD. Expanding roles for reverse shoulder arthroplasty. *Curr Rev Musculoskelet Med* 2016;9:40-8. <https://doi.org/10.1007/s12178-016-9316-0>.
- Chan K, Langohr GDG, Mahaffy M, Johnson JA, Athwal GS. Does humeral component lateralization in reverse shoulder arthroplasty affect rotator cuff torque? Evaluation in a cadaver model. *Clin Orthop Relat Res* 2017;475:2564-71. <https://doi.org/10.1007/s11999-017-5413-7>.
- Collin P, Rol M, Muniandy M, Gain S, Lädermann A, Ode G. Relationship between postoperative integrity of subscapularis tendon and functional outcome in reverse shoulder arthroplasty. *J Shoulder Elbow Surg* 2022;31:63-71. <https://doi.org/10.1016/j.jse.2021.05.024>.
- De Fine M, Sartori M, Giavaresi G, De Filippis R, Agrò G, Cialdella S, et al. The role of subscapularis repair following reverse shoulder arthroplasty: systematic review and meta-analysis. *Arch Orthop Trauma Surg* 2022;142:2147-56. <https://doi.org/10.1007/s00402-020-03716-9>.
- Dedy NJ, Gouk CJ, Taylor FJ, Thomas M, Tan SLE. Sonographic assessment of the subscapularis after reverse shoulder arthroplasty: impact of tendon integrity on shoulder function. *J Shoulder Elbow Surg* 2018;27:1051-6. <https://doi.org/10.1016/j.jse.2017.12.008>.
- Erickson BJ, Shishani Y, Bishop ME, Patel M, Jones S, Romeo AA, et al. Subscapularis repair during reverse total shoulder arthroplasty using a stem-based double-row repair: Sonographic and clinical outcomes. *Orthop J Sports Med* 2020;8:2325967120906806. <https://doi.org/10.1177/2325967120906806>.
- Fleiss J. Measuring Nominal Scale Agreement among many raters. *Psychol Bull* 1971;76.
- Giles JW, Langohr GDG, Johnson JA, Athwal GS. The rotator cuff muscles are antagonists after reverse total shoulder arthroplasty. *J Shoulder Elbow Surg* 2016;25:1592-600. <https://doi.org/10.1016/j.jse.2016.02.028>.
- Herrmann S, König C, Heller M, Perka C, Greiner S. Reverse shoulder arthroplasty leads to significant biomechanical changes in the remaining rotator cuff. *J Orthop Surg Res* 2011;6:42. <https://doi.org/10.1186/1749-799X-6-42>.
- Huish EG, Athwal GS, Neyton L, Walch G. Adjusting implant size and position can improve internal rotation after reverse total shoulder arthroplasty in a three-dimensional computational model. *Clin Orthop Relat Res* 2021;479:198-204. <https://doi.org/10.1097/CORR.0000000000001526>.
- Jawa A, Colliton EM. Role of subscapularis tendon repair in reverse total shoulder arthroplasty. *J Am Acad Orthop Surg* 2021;29:604-8. <https://doi.org/10.5435/JAAOS-D-20-01151>.
- Krishnan SG, Stewart DG, Reineck JR, Lin KC, Buzzell JE, Burkhead WZ. Subscapularis repair after shoulder arthroplasty: biomechanical and clinical validation of a novel technique. *J Shoulder Elbow Surg* 2009;18:184-92. <https://doi.org/10.1016/j.jse.2008.09.009>.
- Levine WN, Munoz J, Hsu S, Byram IR, Bigliani LU, Ahmad CS, et al. Subscapularis tenotomy versus lesser tuberosity osteotomy during total shoulder arthroplasty for primary osteoarthritis: a prospective, randomized controlled trial. *J Shoulder Elbow Surg* 2019;28:407-14. <https://doi.org/10.1016/j.jse.2018.11.057>.
- Matthewson G, Kooner S, Kwapisz A, Leiter J, Old J, MacDonald P. The effect of subscapularis repair on dislocation rates in reverse shoulder arthroplasty: a meta-analysis and systematic review. *J Shoulder Elbow Surg* 2019;28:989-97. <https://doi.org/10.1016/j.jse.2018.11.069>.

16. Shields E, Ho A, Wiater JM. Management of the subscapularis tendon during total shoulder arthroplasty. *J Shoulder Elbow Surg* 2017;26:723–31. <https://doi.org/10.1016/j.jse.2016.11.006>.
17. Small KM, Siegel EJ, Miller LR, Higgins LD. Imaging characteristics of lesser tuberosity osteotomy after total shoulder replacement: a study of 220 patients. *J Shoulder Elbow Surg* 2014;23:1318–26. <https://doi.org/10.1016/j.jse.2013.12.010>.
18. Van den Berghe GR, Nguyen B, Patil S, D'Lima DD, Mahar A, Pedowitz R, et al. A biomechanical evaluation of three surgical techniques for subscapularis repair. *J Shoulder Elbow Surg* 2008;17:156–61. <https://doi.org/10.1016/j.jse.2007.04.016>.