

University of the Western Cape
Faculty of Dentistry
Department of Maxillo-Facial and Oral Surgery



**A comparative immunohistochemical study of Ki-67 expression in
Adenomatoid Odontogenic Tumour, Unicystic Ameloblastoma and
Dentigerous Cyst**

Minithesis for partial fulfillment of Degree MChD (MFOS)

Student: E Fakir

No: 2005961

January 2014



**A comparative immunohistochemical study of Ki-67 expression in
Adenomatoid Odontogenic Tumour, Unicystic Ameloblastoma and
Dentigerous Cyst**



Researcher:

E Fakir

Supervisors:

Prof J Hille

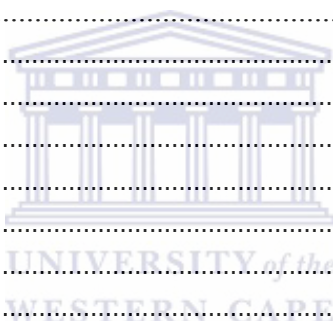Prof J Morkel

January 2014

TABLE OF CONTENTS

PG

Abstract	ii
List of Figures	iv
List of Tables	vi
Declaration	vii
Dedication	viii
Acknowledgements	ix
Introduction	1
Null hypothesis	2
Aim	2
Objectives	2
Ethical clearance	2
Literature Review	3
Epidemiology	3
Clinical Presentation	4
Location	5
Radiology	5
Macroscopic features	9
Histological features	10
Immunohistochemistry (IHC)	11
Materials and Methods	12
Results	13
Discussion	20
Conclusion	23
References	24
Appendix A	30
Table of results	30



Abstract

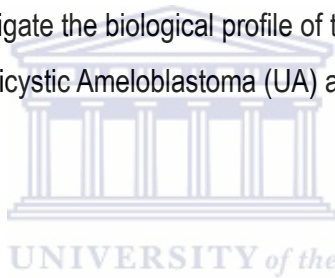
Adenomatoid Odontogenic Tumours (AOTs) are classified as benign epithelial odontogenic neoplasms with mature fibrous stroma, without odontogenic mesenchyme. However these lesions, like odontomes, occur almost exclusively during the final period of odontogenesis, and clinically behave like self-limiting hamartomatous lesions. Histologically they seem to arise from the lining of dental follicles.

Null hypothesis

The adenomatoid odontogenic tumour is a true neoplasm.

Objective

The aim of this study was to investigate the biological profile of the AOT by comparing the Ki-67 proliferative indices of the AOT, Unicystic Ameloblastoma (UA) and Dentigerous Cyst (DC) using ImmunoRatio® software.



Method

Formalin-fixed and paraffin-embedded tissue blocks and routine-stained sections from 10 AOTs, 10 UAs and 10 DCs were retrieved from the archive of the Department of Anatomical Pathology, Tygerberg Hospital, Cape Town, South Africa. Immunohistochemical (IHC) staining of additional tissue sections was performed using the standard Avidin-Biotin Complex method. Ki-67 was detected using the monoclonal antibody MIB-1 (diluted 1:100, Dako, Carpinteria, CA, USA).

Digital images of 10 selected high power fields of the IHC sections were captured using a BX41 Olympus microscope. Each acquired image was submitted online for automated image analysis of Ki-67 immunostained tissue section using the ImmunoRatio® (Institute of Biomedical Technology, University of Tampere, Finland) software. The percentage of DAB-stained nuclei over the total nuclear area (DAB- and hematoxylin-stained) was calculated (proliferative index/PI). The mean labeling index for each case and category was calculated using simple statistical analysis (R Core Team 2013). All statistical analysis was conducted in consultation with a statistician.

Results

The mean proliferation indexes for DC, UA and AOT were respectively calculated as 10.403, 10.406 and 4.757.

Conclusion

The considerably lower Ki-67 proliferation index for AOT confirms the limited growth potential of this odontogenic lesion and adds further support to its hamartomatous nature. Similar active proliferation indices for UA and DC could support the notion that dentigerous cysts may be regarded as benign cystic odontogenic neoplasms and should be treated accordingly.



List of Figures

Figure 1. Distribution of pericoronal (dentigerous, follicular) AOT associated with unerupted permanent teeth (n = 341). (Data from Philipsen HP, Reichart PA. Adenomatoid odontogenic tumour: facts and figures. *Oral Oncol*, 1998;35:125–31.)

Figure 2. An extrafollicular radiolucent cyst-like lesion in the right parasymphyseal area. Note the root divergence, but absence of root resorption

Figure 3. The same lesion showing the egg-shelled cortical bone with buccal expansion

Figure 4. A well-circumscribed extrafollicular radiolucent lesion associated with an upper canine. Note the divergence of the adjacent tooth roots. Photo: Courtesy Prof CJ Nortje

Figure 5. AOT showing root divergence, note the absence of root resorption. Photo: Courtesy Prof CJ Nortje

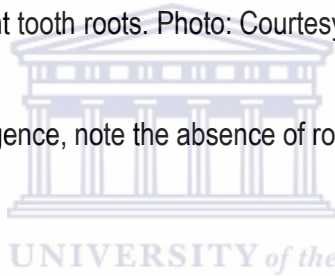


Figure 6. A standard maxillary occlusal radiograph showing fine radiopaque changes within the intrafollicular lesion. Note the presence of impacted teeth and the displacement of the adjacent teeth. Photo: Courtesy Prof CJ Nortje

Figure 7. Gross specimen of an excised AOT. Photo: Courtesy Prof CJ Nortje

Figure 8. An AOT displaying thick connective tissue wall and the exophytic epithelial lining growing into the lumen. Photo: Courtesy Prof CJ Nortje

Figure 9. Histological features of UA showing a very thin layer of odontogenic epithelium, with an epithelial island in the underlying connective tissues. Note the positively stained nucleus in active cells (red arrows)

Figure 10. Histological features of DC showing a non-keratinised stratified squamous epithelium derived from reduced enamel epithelium. Note the positively stained nucleus in active cells (red arrows)

Figure 11. Histological features of AOT showing large pseudo-ductular structures and rosettes. Note the positively stained nucleus in active cells (red arrows)

Figure 12. A plot of individual slide values using different symbols for AOT, DC and UA

Figure 13. A plot of means per type

Figure 14. Boxplots of variable Y for the AOT, DC and UA



List of Tables

Table 1. Summary statistics variable Y

Table 2. Summary statistics variable $\log_e(Y)$



Declaration

I, Ebrahim Fakir, declare that this research report is my own work. It is being submitted as a mini-thesis for the MCHD degree in Maxillo-Facial and Oral Surgery at the University of the Western Cape. It has not been submitted before for any degree at this or any other university.

.....

..... day of2014



Dedication

This thesis is dedicated to my beloved late father and mentor.



Acknowledgements

I would like to express my sincere gratitude to the following persons for their assistance with this project:

Prof JJ Hille and Dr A Afrogeh for assistance and encouragement with this research project at the Dept of Oral Pathology at NHLS Tygerberg.

Profs JA Morkel and G Kariem for all the support throughout my career.

Dr Tanya Wantenaar for her expertise in Anatomical pathology at NHLS, Tygerberg.

Mr Derek Lovelot who assisted with the retrieval of specimens.

Prof S C Maritz for his insight and expertise in statistics.

Prof CJ Nortje for providing clinical and radiographic pictures.

My family, my parents Allie and Fatima Fakir and brothers Tofique and Uthman who have supported me in all my academic endeavours.

My children Nura and Taha. Thank you for helping me realise my goal and thank you for loving and supporting me every step of the way.

My beautiful wife, Shihaam, for all the sacrifice, perseverance and tolerance throughout my career. I love you and thank you for everything.

Introduction

The Adenomatoid Odontogenic Tumour (AOT) has quite a remarkable history due to the ongoing debate regarding its classification. Its basis for inclusion as an odontogenic tumour is the pathology's exclusive location within the tooth-bearing region of the jaws and its histological resemblance to the dental organ. The AOT is not believed to be a true neoplasm and is known to be derived from odontogenic epithelium. It is characterised as having duct-like structures with varying degrees of inductive change in the connective tissue. (Kramer, Pindborg and Shear 1992). To this day, some believe it should be classified as an odontogenic tumour (Gardner 1978), an Adenomatoid Odontogenic Cyst (Marx and Stern 2003) and even a Hamartoma (Phillipsen and Reichart 1998).

Radiographically, an AOT resembles both the unicystic ameloblastoma (true neoplasm) and dentigerous cyst in young patients. The ameloblastoma is defined as "a benign but locally invasive polymorphic neoplasm consisting of proliferating odontogenic epithelium, which usually has a follicular or plexiform pattern, lying in a fibrous stroma" (Kramer, Pindborg and Shear 1992). The dentigerous cyst is defined as "a cyst which encloses the crown and is attached to the neck of an unerupted tooth. It is believed to develop by the accumulation of fluid between the reduced enamel epithelium and the crown of an unerupted tooth. It can also form between the layers of the reduced enamel epithelium" (Kramer, Pindborg and Shear 1992). Marx and Stern define the AOT as "a cystic hamartoma arising from odontogenic epithelium; it is characterised by an epithelium lined lumen, which proliferates to such an extent that it fills the entire luminal space, then mimicking a solid tumour". Numerous authors have recently questioned the cystic nature of the AOT as bisection of the lesion indicated varying amounts of cystic change, proving that the tumour is often not entirely cystic (Gadewar and Srikant 2010).

The proliferative index (PI) may be used to determine the terminology/naming of the AOT with Ki-67 as a marker. The aim of the test is to measure the rate at which the cells divide in the tumour.

This will determine the classification of the AOT: true neoplasm, cyst or hamartoma, by comparing the PI (Ki-67 expression) in an AOT to that of a true neoplasm (such as the unicystic

ameloblastoma) and a true cyst (such as the dentigerous cyst).

Null hypothesis

The adenomatoid odontogenic tumour is a true neoplasm.

Aim


To compare the proliferative indices of the AOT, Unicystic Ameloblastoma (UA) and Dentigerous Cyst (DC) using immunohistochemical analysis with Ki-67.

Objectives

1. To evaluate the histopathological nature of the AOT
2. To determine whether the AOT should be classified as a cyst, tumour or hamartoma.

Ethical clearance

Ethical clearance was obtained from the NHLS to carry out this retrospective study. Anonymity of all specimens was maintained.



This research proposal was submitted to the Faculty and Senate Research Ethics Committee of the University of the Western Cape. Ethical clearance (clearance number 13/7/12) was obtained from the Research Ethics Committee of the University of the Western Cape.

1. Literature Review

In the recent 2nd edition of the WHO "Histological Typing of Odontogenic Tumours" (Kramer, Pindborg and Shear 1992) the Adenomatoid Odontogenic Tumour (AOT) has been defined as: "A tumour of odontogenic epithelium with duct-like structures and with varying degrees of inductive change in the connective tissue. The tumour may be partly cystic, and in some cases the solid lesion may be present only as masses in the wall of a large cyst. It is generally believed that the lesion is not a neoplasm."

For over a century a specimen that meets the above diagnostic criteria has been diagnosed as an AOT. There have, however, been numerous attempts at accurately naming this pathological entity. In a review by Philipsen and Reichardt in 1998, the most likely first diagnosis of an AOT was that of Steensland in 1905 where he described the "Epithelioma Adamantinum". Initially, the AOT was considered to be a histological variant of the ameloblastoma. It was in 1965 that Philipsen and Birn reviewed 76 cases of AOTs that clearly distinguished it from the solid or multicystic ameloblastoma. Prior to this, the review article by Unal et al. in 1995 suggested that the AOT was a histological variant of the ameloblastoma. Names included "Adamantoma, Chorioblastomatous cyst, Adamantoblastoma, Adeno-ameloblastoma, simple Ameloblastoma, a pleomorphic adenoma-like tumour within the wall of a dentigerous cyst, Adenomatoid Ameloblastoma, Adenomatoid Odontoma" (Rick 2004).

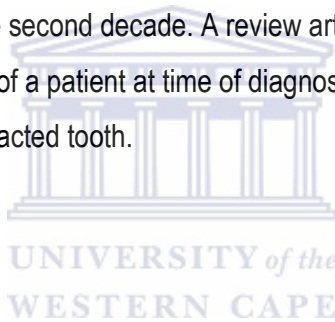
Philipsen and Birn (1969) eventually proposed the name as we know it today, the Adenomatoid Odontogenic Tumour. The WHO histological typing of odontogenic tumours has retained this descriptive term.

Epidemiology

AOT accounts for approximately 3% to 7% of odontogenic tumours at institutions across the world and makes it the fourth most frequently occurring odontogenic tumour (Philipsen et al. 1991 and 1998). In an article by Mohamed et al. in 2010, the demographics and incidences of AOTs amongst a sample of the South African population was reviewed between 1986 and 2006. 746 odontogenic

tumours were diagnosed, 33 of them were AOTs. The ages of the patients ranged from 9-37 years with an average age of 15 years. The 33 AOTs all occurred in rural/peri-urban areas of the northern region of South Africa. Thirty-two of the patients were younger than 30, and most of them were in their 20's (Mohamed et al. 2010). The South African data appear to concur with the international indices for the AOT.

In a review article by Philipsen et al in 1991 on AOTs, lesions were present in patients between the ages of 3 and 82. AOTs, however, occur more frequently in the second decade of life with 68.6% of all AOTs diagnosed in recent years being in patients in their twenties. DCs, on the other hand, do not show any particular age bias and were diagnosed in patients ranging in age from 6-99 years (Zhang et al 2010). The UA seems to be diagnosed in much younger patients than its solid or multicystic counterpart (Ackermann et al, 1988). In the latter series, the mean age was 23.8 years (SD14.9) with 48% occurring in the second decade. A review article by Philipsen and Reichardt (1998) showed that the mean age of a patient at time of diagnosis of the UA correlated closely with the presence of an associated impacted tooth.



Clinical Presentation

The majority of AOTs occur in bone. They attach to the necks of unerupted teeth, surrounding the crowns and resembling a follicle (Jivan et al 2007). However, some cases have shown no connection to unerupted teeth and have been reported to occur in the soft tissue extra-osseously (Philipsen et al 1992).

Most central lesions are initially identified during routine dental radiography. The delayed eruption of a permanent tooth or a slow-growing bony expansion (with or without displacement of adjacent teeth) that overlies the tumour commonly lead to the discovery of intragnathic AOTs.

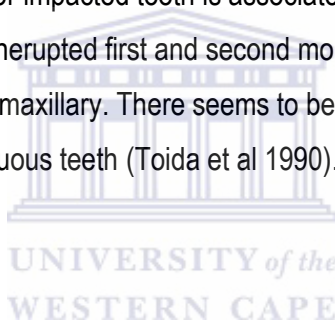
The classic signs of odontogenic tumours namely tooth mobility, facial asymmetry and cheek swelling, have been reported less frequently as presenting signs (Takahashi et al 2001). The peripheral variant can present as a gingival-coloured lesion that ranges from 1 to 1.5 mm in

diameter (Rick 2004). The peripheral variants of the AOT have ten times the propensity for maxillary gingiva than those of the mandible (Rick 2004).

Location

The AOT can be follicular, extrafollicular or peripheral. Extrafollicular and follicular variants account for 96% of all AOTs and are intragnathic bony or central tumours. The follicular variant is three times more common than the extrafollicular type across genders. The lesion is found more commonly in the maxilla than in the mandible at a ratio of 2:1. The peripheral type occurs almost exclusively (88% of the time) in the anterior maxilla (Philipsen and Reichardt 1998).

More often than not an unerupted or impacted tooth is associated with the AOT. The teeth showing least involvement with AOTs are unerupted first and second molars. The four canines account for 59% of AOTs, 40% of those being maxillary. There seems to be no real relationship between central AOTs and unerupted deciduous teeth (Toida et al 1990).



Radiology

The AOT occurs as an intra-osseous as well as a peripheral lesion. Intrabony AOTs consist of follicular or extrafollicular types. The follicular type mimics a DC presenting as a unilocular radiolucency associated with the crown and they are initially diagnosed as dentigerous up to 77% of the time (Philipsen and Reichardt 1998).

The extrafollicular type is found on the roots of unerupted teeth and has a well-defined unilocular radiolucency. Depending on the location of the lesion and the radiological similarities to other cysts usually found in these locations, they are often mistaken as residual, radicular, globulomaxillary or lateral periodontal cysts (Fig 1) (Philipsen and Reichardt 1998).

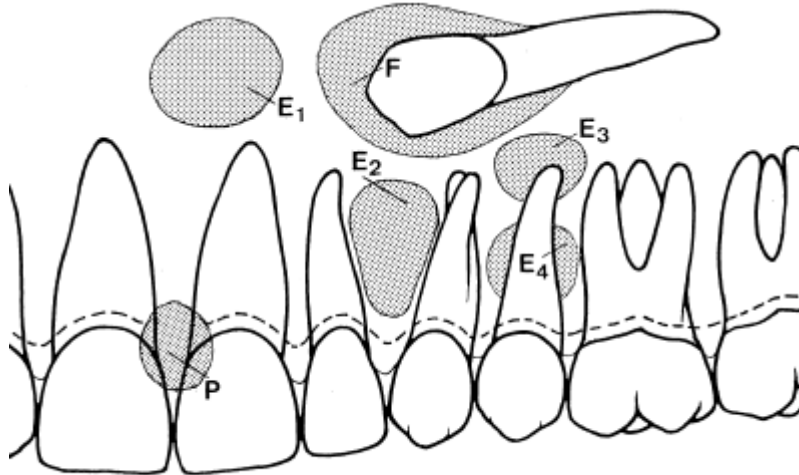


Fig 1. Distribution of pericoronal (dentigerous, follicular) AOT associated with unerupted permanent teeth (n = 341).
 (Data from Philipsen HP, Reichart PA. Adenomatoid odontogenic tumor: facts and figures. Oral Oncol 1998;35: 125-31.)

Approximately 65% of reported cases demonstrate faintly detectable radio-opacities within the cystic radiolucent lesion. In 1994, Dare et al illustrated that this feature is often not visible on panoramic films and it is thus advisable to obtain good quality periapical views of the area of suspected cases. With AOTs, divergence of roots and displacement of teeth occurs more frequently than root resorption (Fig 2 and 3) (Rick 2004).

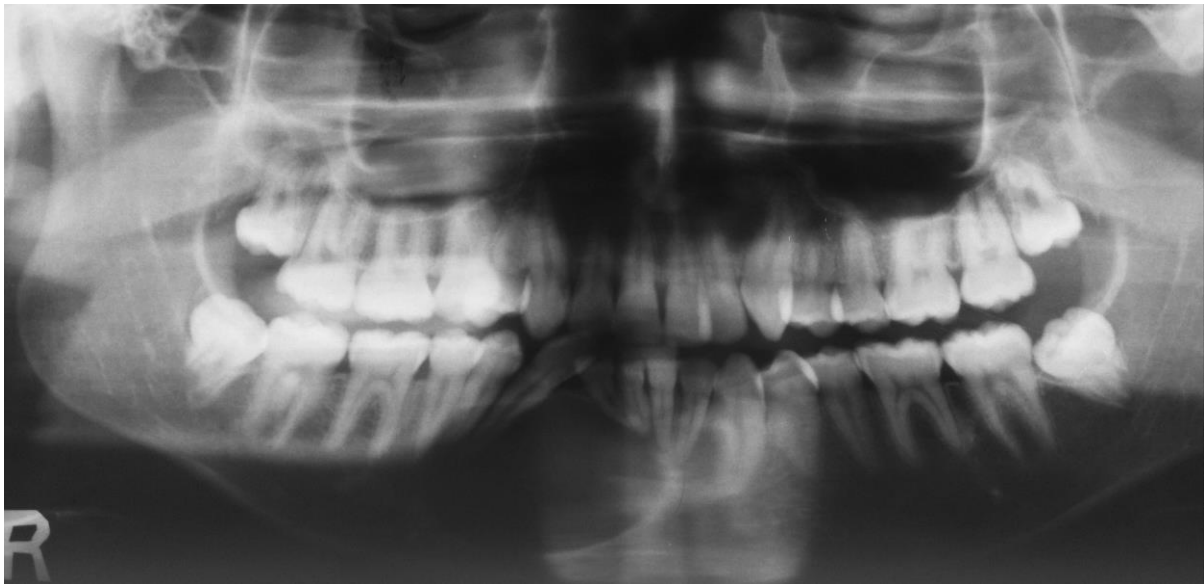


Fig 2. An extrafollicular radiolucent cyst-like lesion in the right parasymphyseal are. Note the root divergence, but absence of root resorption.

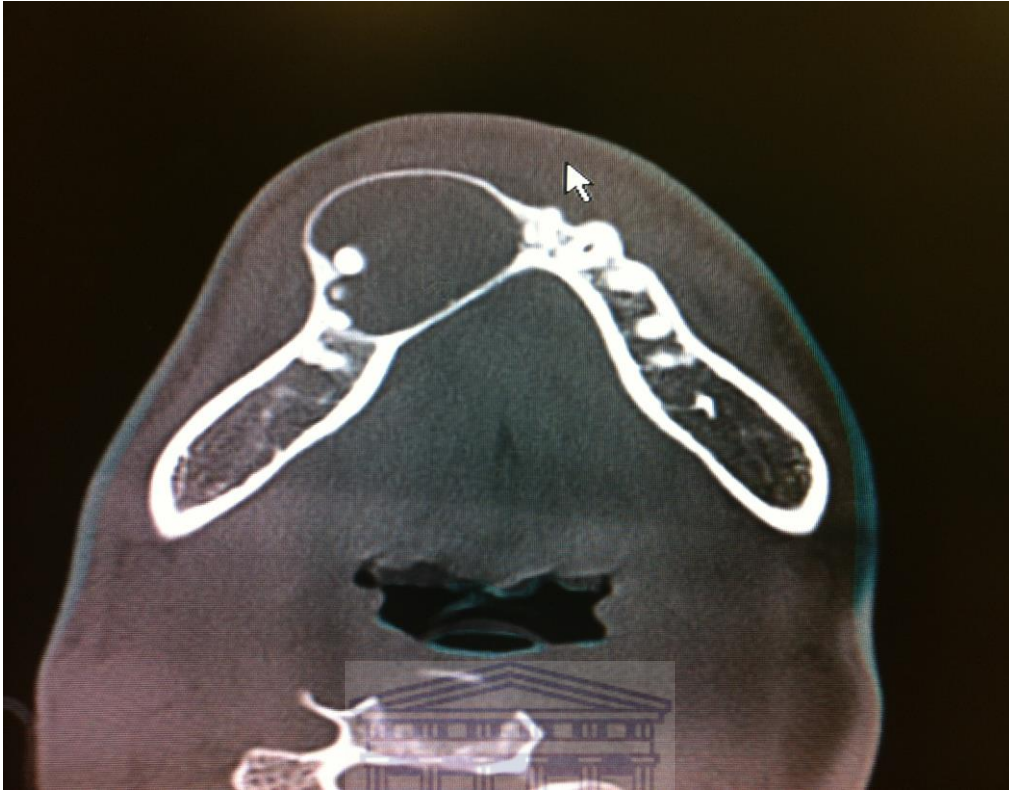

Fig 3. The same lesion showing the egg-shelled cortical bone with buccal expansion.

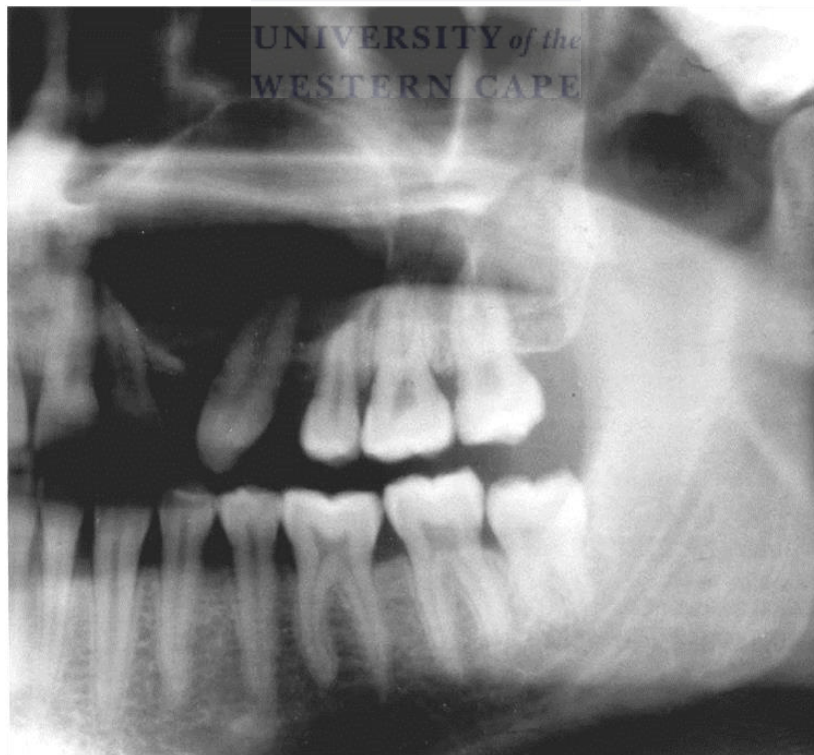


Fig 4. A well-circumscribed extrafollicular radiolucent lesion associated with an upper canine. Note the divergence of the adjacent tooth roots.

Photo: Courtesy Prof CJ Nortje

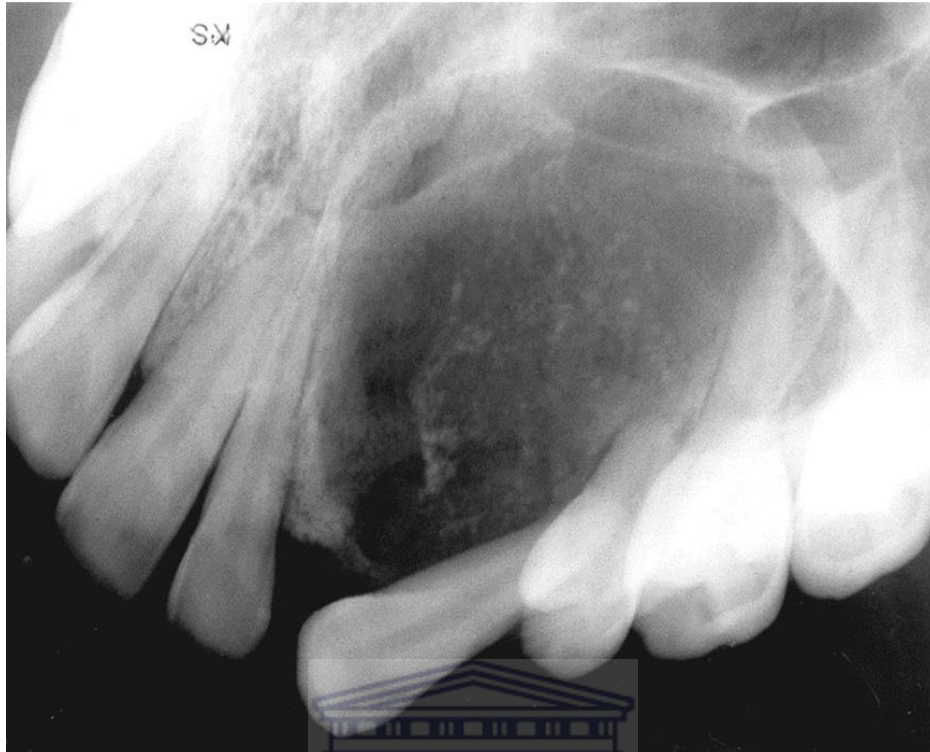


Fig 5. AOT showing root divergence, note the absence of root resorption. Photo: Courtesy Prof CJ Nortje

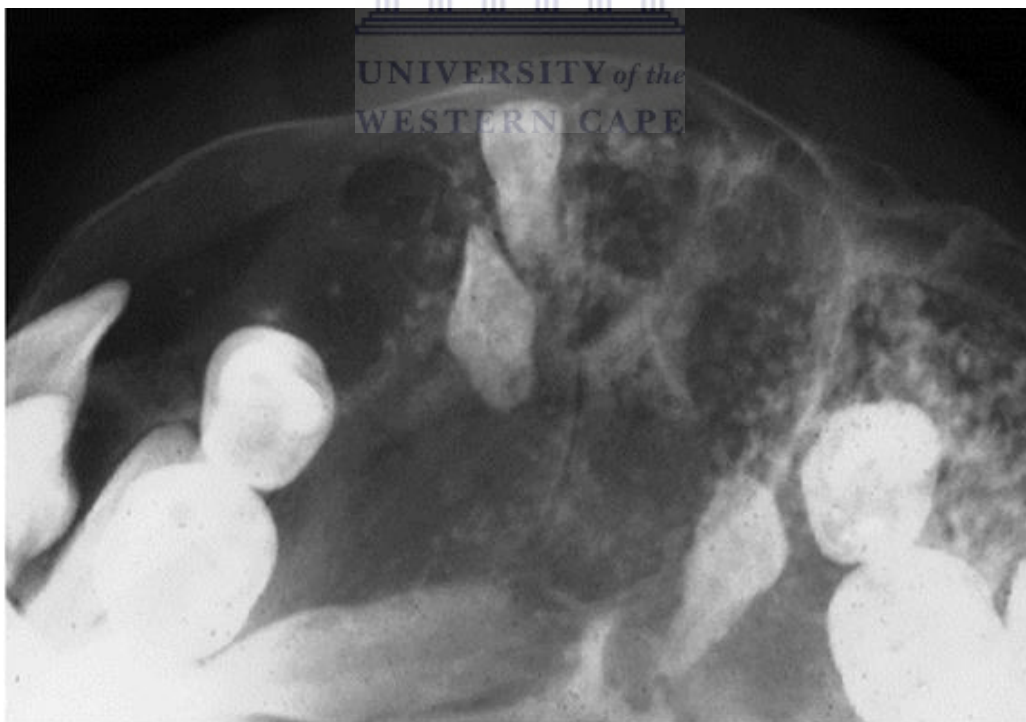

Fig 6. A standard maxillary occlusal radiograph showing fine radiopaque changes within the intrafollicular lesion. Note the presence of impacted teeth and the displacement of the adjacent teeth. Photo: Courtesy Prof CJ Nortje

The peripheral AOT variant is usually similar in appearance to a gingival fibroma. It has also been likened to an epulis attached to the labial gingiva. In most cases plain radiographs do not detect any changes in the alveolar crest. In some cases, the AOT can show erosion (Philipsen and Reichardt 1998).

Macroscopic features

On gross examination the macroscopic appearance of most excised surgical specimens of central AOTs reveal a soft, almost spherical mass surrounded with a thick fibrous capsule. Upon gross sectioning, the tumour may exhibit an exophytic-like epithelial lining (Fig 8). On occasion the proliferation will mask the cystic nature of the tumour. It is for this reason that Marx et al feel that the lesion is a cyst because it arises from the root sheet of Hertwig (Marx and Stern 2003).

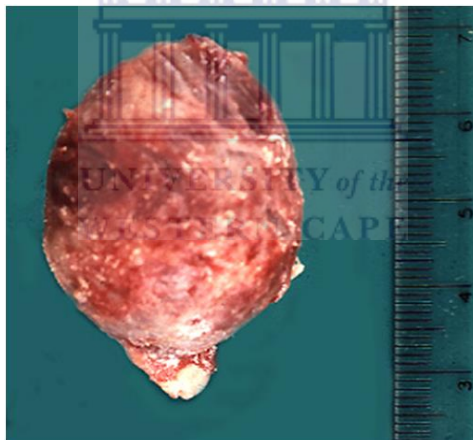


Fig 7. Gross specimen of an excised AOT: Photo: Courtesy Prof CJ Nortje

The lesion may occasionally appear as minimal yellow-brown fluid to semisolid material. It may also exhibit a white to tan, solid to crumbly tissue. There may even be one or more cystic spaces of varying size present. It can be filled with a fine, hard gritty, granular material. One to several larger calcified masses may also be present (Fig 8) (Rick 2004).

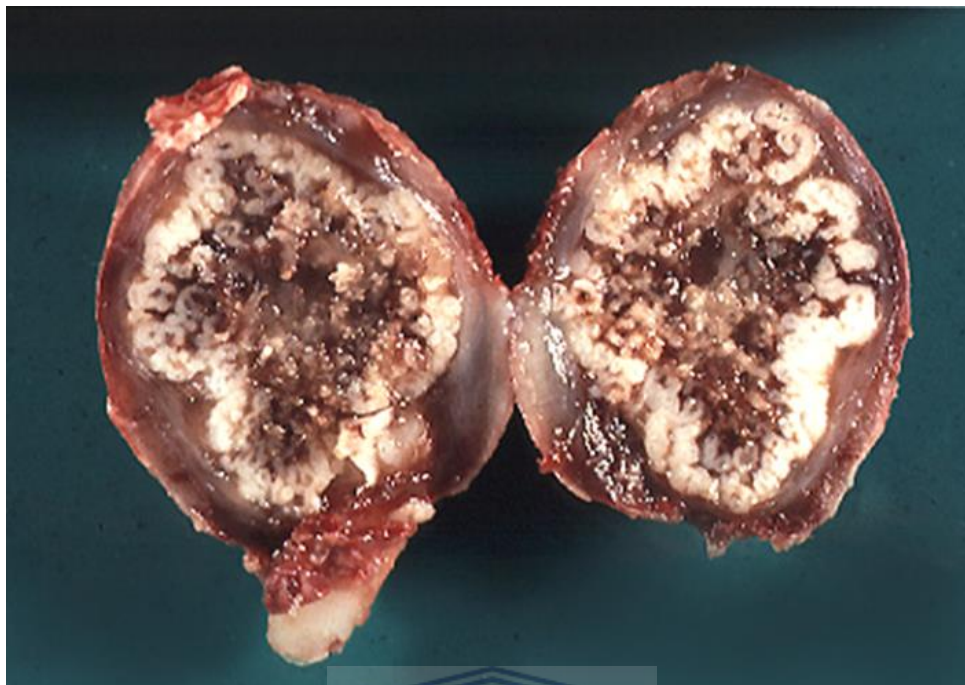


Fig 8. An AOT displaying thick connective tissue wall and the exophytic epithelial lining growing into the lumen. Photo: Courtesy Prof CJ Nortje

Histological features

The AOT may be solid or there may be more or less extensive cyst formation. The epithelium typically shows plexiform strands. Sheets and rings of spindle cells are likely to be evident as well. The duct-like appearance is due to the rings of columnar cells. However, these duct-like structures can be scanty. Between opposing rows of columnar cells there is often an acidophilic material that is usually Periodic Acid-Schiff positive. Immunohistochemical studies have shown this to be basement membrane-like material (Kramer, Pindborg and Shear 1992).

Although most literature reviews contain multiple histochemical, ultrastructural and immunohistochemical analyses, these special tests are specifically required to establish a reliable diagnosis of the AOT. They have been almost exclusively used in research attempts to determine the cell of origin or the nature of the lesional products (Rick 2004).

Two cases published by Raubenheimer et al in 1995 showed an association between UAs and AOTs. In another study, Zeitoun et al in 1995 showed an AOT originating within a calcifying

odontogenic cyst (COC). They illustrated the transformation of the epithelial lining of a COC to form an AOT. Numerous other studies have subsequently shown an AOT and Calcifying Epithelial Odontogenic Tumour in combination. It is generally accepted that these are all histological variants of the AOT (Raubenheimer et al 1995; Matsumoto et al 2001; Zeitoun et al 1996 and Mosqueda-Taylor et al 2005).

Immunohistochemistry (IHC)

In any neoplastic process, the cell cycle is a very important process where Cyclin-Dependent Kinases (CDKs) control the passage cycle. A group of proteins called CDK inhibitors that are present within the cycle, can block the activity of CDKs (Suzuki and Hashimoto, 2005).

The Ki-67 protein (also known as MKI67) is associated with cellular proliferation and it is a distinctive marker that illustrates the rate at which cells proliferate. It is present in all active phases of the cell cycle. These include: G₁, S, G₂, and mitosis. During interphase, Ki-67 is found in the cell nucleus, whereas in mitosis it can be found on the surface of the chromosomes. It is not present in resting (G₀).



Numerous immunohistochemical studies have examined Keratocystic Odontogenic Tumours (KCOTs) by using different markers. These markers were specific for rate of proliferation and apoptosis. Ki-67 has been used in numerous studies as a marker of cell proliferation. The Ki-67 antigen is present in the entire cell cycle and its level is shown to increase during the s-phase. Studies comparing KCOTs and dentigerous cysts have indicated the epithelial lining in the KCOT as having a higher proliferative potential than ameloblastomas. Ki-67 cells were most commonly found in the suprabasal layers of the cyst epithelium, whereas they were shown to be more in the epithelial linings of the KCOTs compared to other inflammatory cysts (Mendes 2011; Li et al 1995; Thosaporn et al 2004).

2. Materials and Methods

Formalin-fixed and paraffin-embedded tissue blocks and routine-stained sections from 10 AOTs, 10 UAs and 10 DCs were retrieved from the archive of the Department of Anatomical Pathology, Tygerberg Hospital, Cape Town, South Africa. Immunohistochemical (IHC) staining of additional tissue sections was performed using the standard Avidin-Biotin Complex method. Ki-67 was detected using the monoclonal antibody MIB-1 (diluted 1:100, Dako, Carpinteria, CA, USA). Digital images of 10 selected high power fields (HFP) of the IHC sections were captured using a BX41 Olympus microscope. Each acquired image was submitted on-line for automated image analysis of Ki-67 immunostained tissue section using the ImmunoRatio® (Institute of Biomedical Technology, University of Tampere, Finland) software. The percentage of DAB-stained nuclei over the total nuclear area (DAB- and hematoxylin-stained) was calculated (proliferative index).

Inclusive criteria which were examined by two observers were the existence of enough epithelial lining in the UA and DC, and the duct-like rosette structures in the AOT (Figs 8, 9 and 10). Specimens that had significant inflammation were excluded, as inflammation destroys the architecture of tumours, exaggerates tumoral dysplasia and falsely increases the PI in affected areas.

Data were analyzed using a standardised statistical programme (R Core Team 2013) and captured on a Microsoft Excel® data sheet. Statistical analysis was conducted in consultation with a statistician.

3. Results

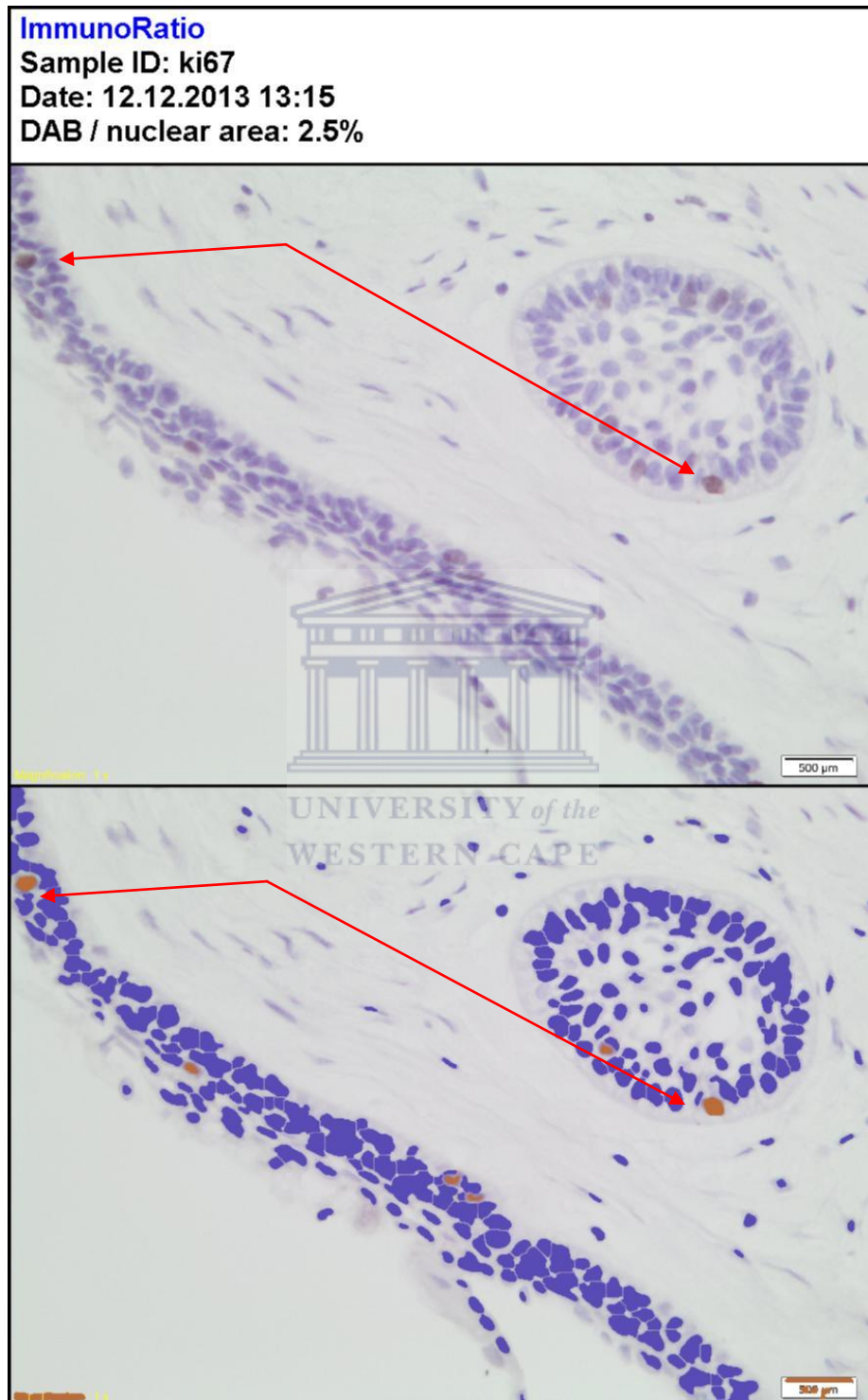


Fig 9. Histological features of UA showing a very thin layer of odontogenic epithelium, with an epithelial island in the underlying connective tissues.
Note the positively stained nucleus in active cells (red arrows)

ImmunoRatio

Sample ID: ki67

Date: 12.12.2013 16:11

DAB / nuclear area: 6.0%

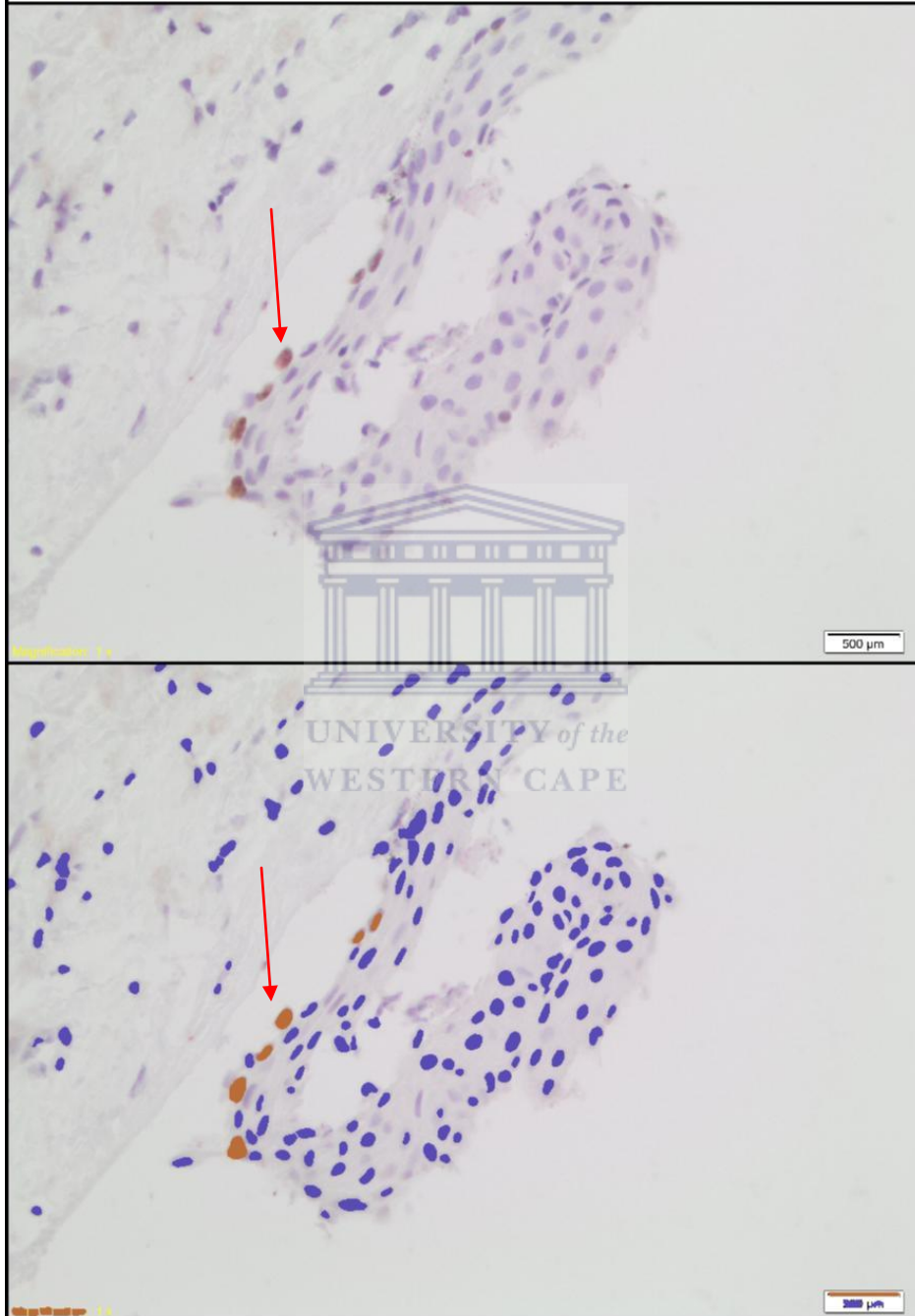


Fig 10. Histological features of DC showing a non-keratinised stratified squamous epithelium derived from reduced enamel epithelium. Note the positively stained nucleus in active cells (red arrows)

ImmunoRatio

Sample ID: EPA2858

Date: 17.12.2013 14:27

DAB / nuclear area: 4.7%

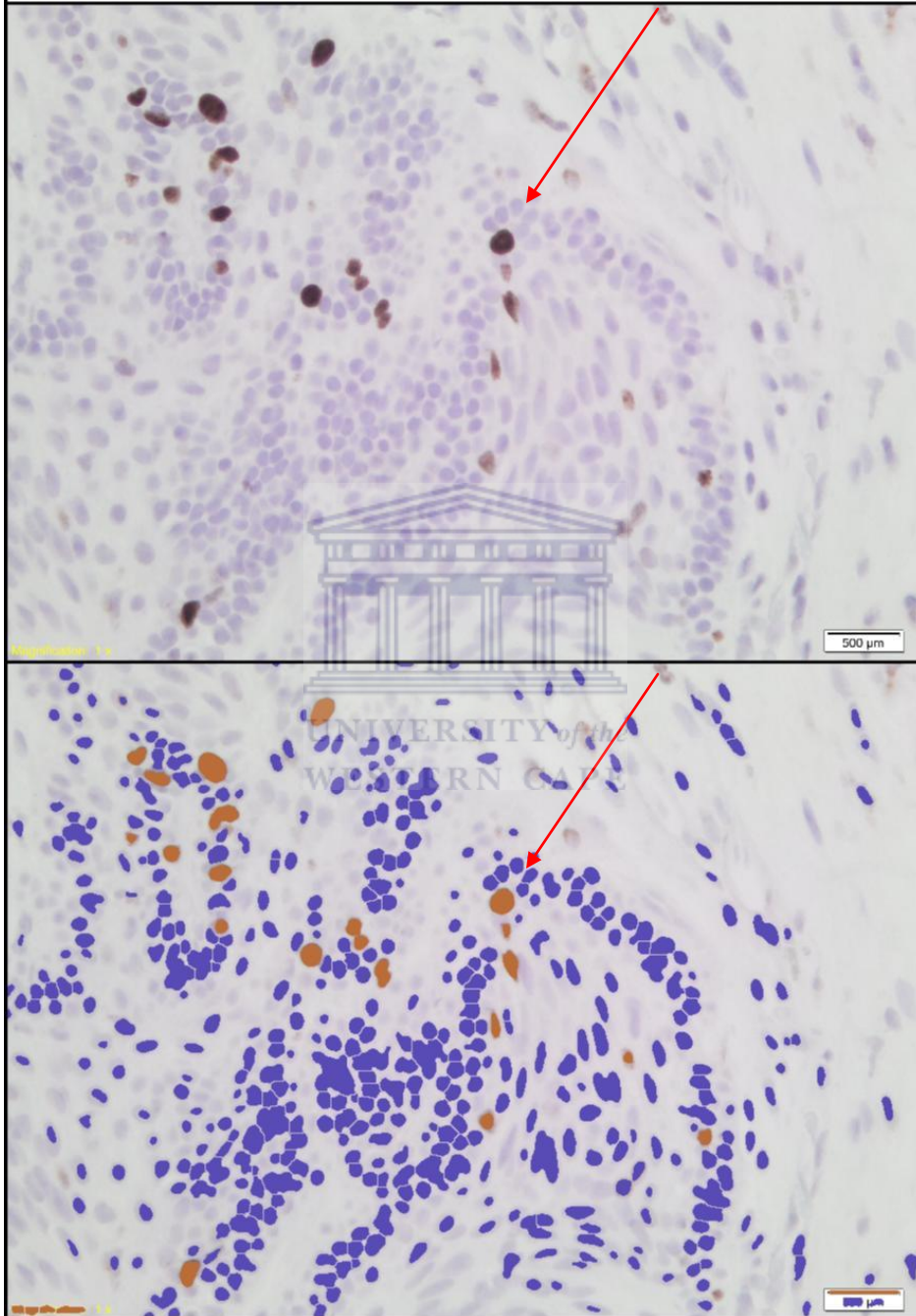


Fig 11. Histological features of AOT showing large pseudo-ductular structures and rosettes. Note the positively stained nucleus in active cells (red arrows)

After reviewing the data and the spreadsheet for the 300 photomicrographs, the analysis was based on the following assumptions: (a) that there was no significant ordering of the 10 slides whose data were labelled a to j in the data spreadsheet (Appendix 1), and (b) that the mean of the slide values of a specimen was an appropriate representation of its PI.

Assumption (a) was supported by Figure 12, a plot of individual slide values using different symbols for AOT, DC, UA, and Figure 13, a plot of means per type. Neither plot exhibited trends that clearly departed from randomness.

Fig 12. A plot of individual slide values using different symbols for AOT, DC and UA

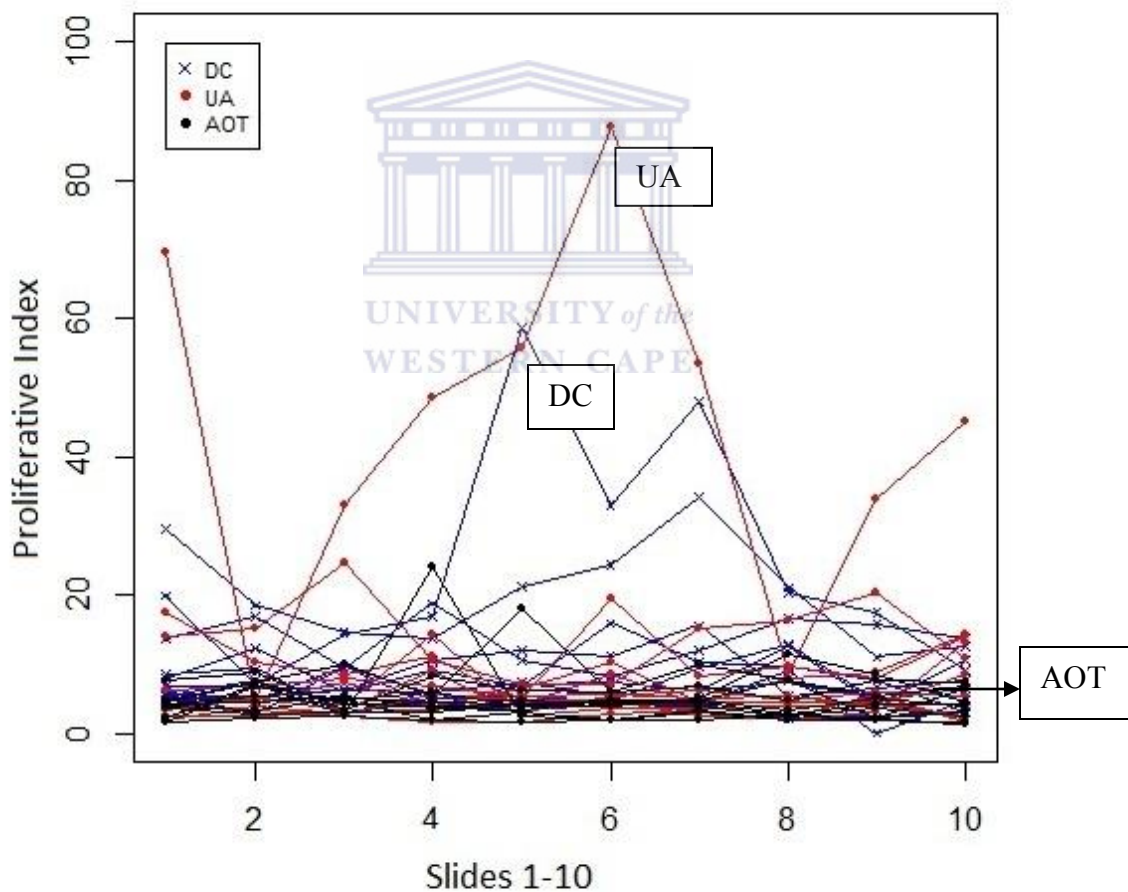
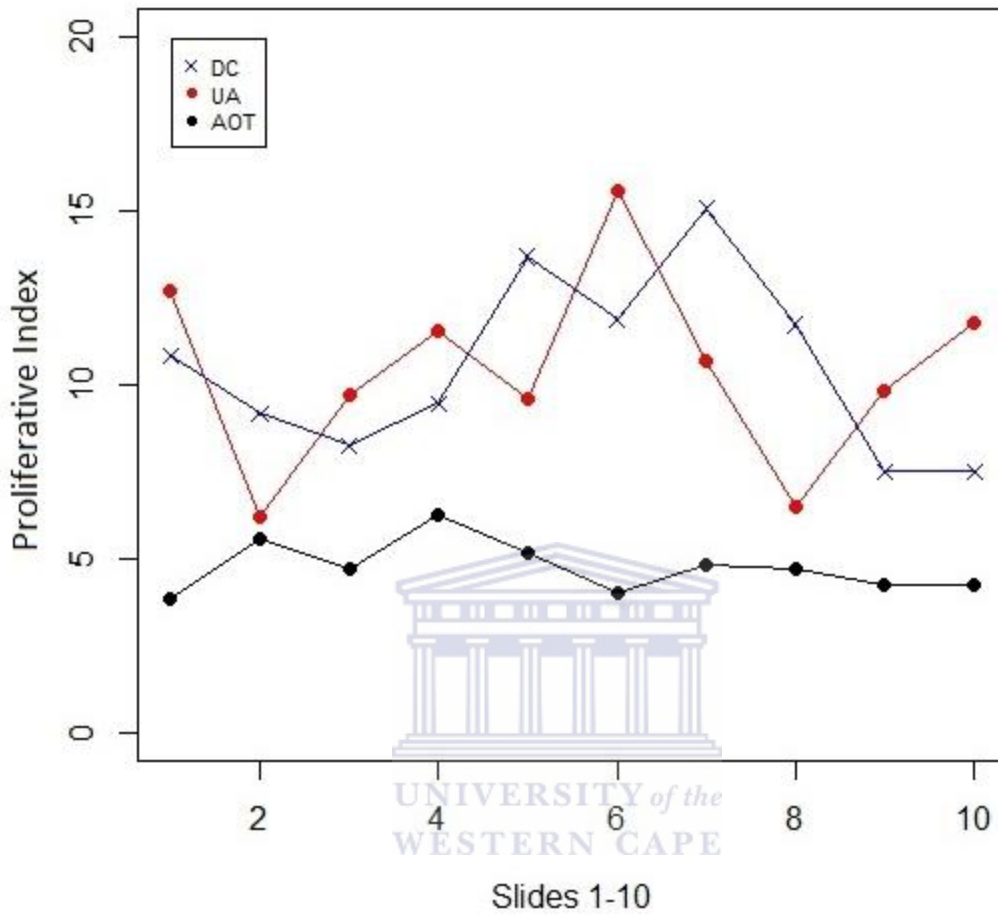


Fig 13. A plot of means per type.



For convenience the mean of the PI values over slides was called Y. There were 30 values of Y, 10 for each type: AOT, DC and UA. Table 1 supplies some details on Y.

	Mean	Median	SD	Min	Max
AOT	4.757	4.735	1.749	2.18	7.8
DC	10.508	8.06	6.810	4.47	24.5
UA	10.406	6.005	12.234	3.57	44.01

Figure 14. Boxplots of variable Y for the AOT, DC and UA.

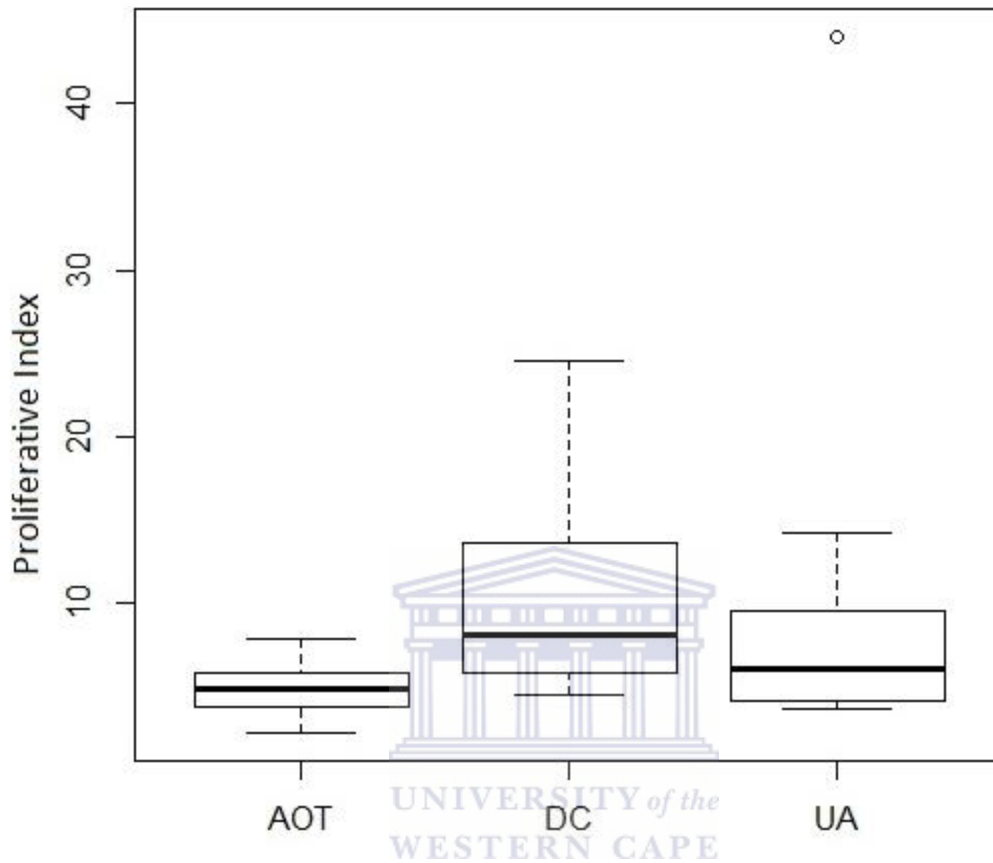


Figure 14 indicates that the mean PI of type AOT was smaller than the means of the other two types. The dispersion of PI for AOT was also clearly smaller than that of the other two types. There appeared to be one outlier in type UA, but it was not eliminated. These trends were also clear in Table 1.

To examine the statistical significance of the apparent differences in location of the three pathologies, some form of one-way analysis of variance is commonly used. One of the most important requirements for applicability of the ANOVA-test is homogeneity of the variances of the three groups. According to a Bartlett test, the variances are significantly different (Bartlett's K-squared = 22.4876, df = 2, p-value <0.0001). Transforming the Y values to $\log_e(Y)$ has the effect of

stabilizing the variances (Bartlett's K-squared = 3.4415, df = 2, p-value = 0.1789). Table 2 gives summary statistics of variable $\log_e(Y)$.

	Mean	Median	SD	Min	Max
AOT	1.493	1.551	0.396	0.779	2.054
DC	2.191	2.082	0.577	1.497	3.199
UA	1.998	1.792	0.761	1.273	3.784

The next step was to perform a one-way ANOVA using the $\log_e(Y)$ values; the result was F-statistic: 3.644 on 2 and 27 DF, p-value: 0.03973, indicating statistically significant differences between the means. The mean of AOT was significantly smaller than that of DC (p-value=0.015); the mean of AOT was marginally significantly different from that of UA (p-value=0.069). The means of DC and UA did not differ significantly.

An alternative to the usual ANOVA as applied to either the original values or to some transformation of these values, like a logarithmic transformation, is to perform an analysis based on ranks. The Kruskal-Wallis test is rank-based. The result of applying this test to Y was: Kruskal-Wallis chi-squared = 6.8361, df = 2, p-value = 0.03278, thus confirming the result of the ANOVA of $\log_e(Y)$.

4. Discussion

In a survey by Leon et al. (2005), the Ki-67 IHC marker was evaluated in 39 AOT cases. The expression of this marker was very low in AOTs (PI<1%) which led the investigators to conclude that this tumour grows very slowly and that it cannot invade adjacent tissues.

In 2005 Barboza et al. applied Proliferative Cell Nuclear Antigen (PCNA) and P53 markers in 16 cases of solid ameloblastomas (SAB) and eight cases of AOTs. PCNA is a known marker for mitosis activity and is very similar to Ki-67. P53 is another marker that indicates proliferative and anti-apoptotic activities. Both markers were higher in SABs compared to AOTs (Barboza et al. 2005). Barboza further concluded that SABs were more aggressive than AOTs after levels of Bcl-2 and Ki-67 were evaluated in SABs and AOTs.

The expression of Ki-67 is higher in the epithelial linings of Keratocystic Odontogenic Tumours (KCOTs) when compared to other developmental and inflammatory cysts (Mendes, Carvalho, Van Der Waal, 2011). For this reason Ki-67 was used to compare proliferative indices in the AOT, UA and the DC. The aim was to shed light on the actual characteristics of the AOT by comparing it to a true neoplasm such as the UA and a true cyst such as the DC. Tuominen et al developed Immunoratio® in 2010. They described an image analysis application, which is a user-friendly tool to assess Ki-67 proliferative indexes in hematoxylin-counterstained tissue sections. Immunoratio® analysis is based on defining positively stained pixel counts, which, according to their calibration data, correlates very well with cell nuclei enumerated visually.

Ki-67 is a proliferation marker specific to mitoses and is never found in the non-proliferative phase of the cell cycle. This makes it an ideal marker for measuring tumour growth. Aggressive tumours have the ability to invade healthy surrounding tissues. The higher the PI, the more likely a tumour is to invade.

Many studies in the scientific literature examine the histological basis of the AOT (Aritoba et al. 1997, Greer 1997, Mohamed et al. 2010). Others examine histological evidence of induction (Jivan et al 2008). In other studies arguments were put forward regarding whether or not the AOT is

indeed a tumour, hamartoma or cyst (Otero et al 2009, Marx and Stern 2003, Garg et al 2008, Gadewar and Srikant, 2010).

The basis of this study was to evaluate the PI for the three distinctly different pathologies. All three, however occur in similar parts of the jaws and have a similar radiological appearance. They also occur in a similar age group. The proliferation marker Ki-67 made it possible to measure the rate of growth for each of these pathologies and compare them to one another.

The AOT is characterised by numerous pseudo-ductular structures of varying size which consist of a single layer of palisaded columnar non-secreting cells surrounding a central lumen. It is in these pseudo-ductular areas where most of the cellular proliferation takes place. It is exactly here (as seen in Figure 9) that most of the lesion's growth takes place. The linings found within UA can classically have three different variants as described by Ackermann, Altini and Shear (1988). Group 1 lesions usually have a non-descript thin epithelial lining. Group 2 show intraluminal epithelial thickening and Group 3 show downward epithelial growth into the cyst wall or epithelial islands within the wall. All these areas showed positively stained nuclei with Ki-67. The DC cyst proved to be the most difficult pathology to source as only non-inflamed specimens had to be used for the study. Acute inflammation proved to increase the PI and would invariably distort the results.

Measuring the PI can be a laborious process. Previously most studies counted the total number of positively stained cells and divided that figure by 1000. This process was undertaken by three different examiners to exclude intra- and inter-examiner variability. With Immunoratio® (Institute of Biomedical Technology, University of Tampere, Finland) this study was able to use an internationally accepted, standardised method of measuring PI (Tuominen et al 2010). This excluded the need for multiple examiners as photomicrographs were uploaded and PIs were attained for each of the HPFs that were taken (Figures 8, 9 and 10).

The mean proliferation indices for DC, UA and AOT were respectively calculated as 10.508, 10.406 and 4.757 (Table 1). The mean of AOT is significantly smaller than that of DC (p -value = 0.015); the mean of AOT is borderline significantly different from that of UA (p -value = 0.069). The means of DC and UA do not differ significantly (Table 2).

There is a significant difference in PI of AOTs compared to DCs. The DC also grows at a faster rate than the AOT. In addition, the limited growth potential of the AOT is also apparent when compared to the UA. This led the researchers to question why the AOT is considered a neoplasm while the DC is considered a cyst.

However AOTs, like odontomes, occur almost exclusively during the final period of odontogenesis, and clinically behave like self-limiting hamartomatous lesions. Therefore, if one considers the reclassification of KCOTs by the WHO where Ki-67 expression is higher in the epithelial linings of KCOTs in comparison to other developmental and inflammatory cysts, and if a cystic neoplasm like the UA has a significantly higher PI than the AOT, then the AOT could be considered to be a cystic hamartoma arising from odontogenic epithelium, rather than a true neoplasm.



Conclusion

The considerably lower Ki-67 proliferation index for the AOT confirms the limited growth potential of this odontogenic pathology and adds further support to its hamartomatous nature. Similar active proliferation indices for UAs and DCs could support the notion that dentigerous cysts may be regarded as benign cystic odontogenic neoplasms and should be treated accordingly.



References

- ACKERMANN, G.L., ALTINI, M., SHEAR, M., 1988. The unicystic ameloblastoma: a clinicopathological study of 57 cases. *J Oral Path*, 17:541-546.
- ADEBAYO, E.T., AJIKE, S.O., ADEKEYE, E.O., 2002 .Odontogenic tumours in children and adolescents: a study of 78 Nigerian cases. *J Cranio-Maxillo-Facial Surg*, 30: 267–272.
- ADEBAYO, E.T., AJIKE, S.O., ADEKEYE, E.O., 2005. A review of 318 odontogenic tumours in Kaduna, Nigeria. *J Oral Maxillofac Surg*, 63: 811–819.
- ARITIBA, G.T., ARITIBA, J.T., OLAITAN, A.A., AJAYI, O.F., 1997. The adenomatoid odontogenic tumour: an analysis of 57 cases in a black African population. *J Oral Maxillofac Surg*, 55: 146–148.
- BARBOZA, C.A., PEREIRA PINTO, L., FREITAS, R. A., COSTA, A. L., SOUZA, L.B. Proliferating cell nuclear antigen (PCNA) and p53 protein expression in ameloblastoma and adenomatoid odontogenic tumor. *Braz Dent J*. 2005;16(1):56-61. Epub 2005.
- BARNES, L., EVESON, J.W., REICHARDT, P., SIDRANSKY, D., 2005. eds: World Health Organization Classification of Tumours. *Pathology and genetics of head and neck tumours*. Lyon: IARC Press 304–305.
- BARTISTA DE PAULA, A.M., CARVALHAIS, J.N., DOMINGUES, M.G., BARRETO, D.C., MESQUITA, R.A., 2000. Cell proliferation markers in the odontogenic keratocyst: effect of inflammation. *J Oral Pathol Med*, 29:477- 482.
- CHAMBERS, K.S.,1973. The adenoameloblastoma. *Br J Oral Surg*, 10: 310–320.
- DARE, A., YAMAGUCHI, A., YOSHIKI, S., OKANO, T., 1994. Limitation of panoramic radiography in diagnosing adenomatoid odontogenic tumours. *Oral Surg Oral Med Oral Pathol*, 77(6):662– 8.

GADEWAR, D.R., SRIKANT, N., 2010. Adenomatoid odontogenic tumour: Tumour or a cyst, a histopathological support for the controversy. *International Journal of Paediatric Otorhinolaryngology*, Volume 74, Issue 4, pp 333–337.

GARCIA-POLA VELLEJO, M., GONZALEZ GARCIA, M., LOPEZ-ARRANZ, J.S., HERRERO ZAPATERO, A., 1998. Adenomatoid odontogenic tumour arising in a dental cyst: report of unusual case. *J Clin Pediatr Dent*, 23:55–58.

GARDNER, D.G., 1978. The concept of Hamartomas: its relevance to the pathogenesis of odontogenic lesions. *Oral Surg*, 45:884-886.

GARG, D., PALASKAR, S., SHETTY, V.P., BHUSHAN, A., 2008. Adenomatoid Odontogenic Neoplasm - hamartoma or true neoplasm: a case report. *J Oral Sc*,51:1 155-159.

GREER, R.O., 1997. The Adenomatoid Odontogenic Tumour: An analysis of 57 cases in a black African population. *J Oral Maxillofac Surg*, 55:149-150.

JIVAN, V., ALTINI, M., MEER, S., 2008. Secretory cells in adenomatoid odontogenic tumour: tissue induction or metaplastic mineralisation? *Oral Diseases*, 14: 445-449.

JIVAN, V., ALTINI, M., MEER, S., MOHOMED, A., 2007. Adenomatoid Odontogenic Tumour (AOT) Originating in the Unicystic Ameloblastoma. *Head and Neck Pathol* 1:146-149.

KAMB, A., GRUIS, N.A., WEAVER-FELDHAUS, J., LIU, Q., TAVTIGIAN, S.V., STOCKERT, E., JOHNSON, B.E., SKOLNICK, M.H., 1994. A cell cycle regulator potentially involved in genesis of many tumour types. *Science*, 264:436-440.

KRAMER, I.R., PINDBORG, J.J., SHEAR, M. Adenomatoid odontogenic tumour. Histological typing of odontogenic tumours. 2nd ed. Berlin; Springer-Verlag, 1992:19-20.

LEON, J. E., MATA, G.M., FREGNANI, E.R., CARLOS-BREGNI, R., DE ALMEIDA, O.P., MOSQUEDA-TAYLOR, A., VARGAS, P.A., 2005. Clinipathological and immunohistochemical study of 39 cases of Adenomatoid Odontogenic Tumour: A multicentric study. *Oral Oncology*, 41, 835-842.

LI, T.J., BROWNE, R.M., MATHEWS, J.B., 1995. Epithelial cell proliferation in odontogenic keratocysts: immunocytochemical study of Ki-67 in simple, recurrent and basal cell naevus syndrome (BCNS)-associated lesions. *J Oral Pathol Med*, 24:221-6.

MARX, R.E., STERN, D., 2003. Oral and Maxillofacial Pathology. Chicago: *Quintessence*.

MATSUMOTO, Y., MIZOUE, K., SETO, K., 2001. Atypical plexiform ameloblastoma with dentinoid: adenoid ameloblastoma with dentinoid. *J Oral Pathol Med*, 30:251-254.

MENDES, R.A., CARVALHO, J.F.C., VAN DER WAAL, I., 2011. A comparative immunohistochemical analysis of COX-2, p53, and Ki-67 expression in keratocystic odontogenic tumours. *Oral Surg Oral Med Oral Pathol Oral Radiol Endo* 111:333-339.

MOHAMED, A., SINGH, S., RAUBENHEIMER, E.J., BOUCKAERT, M.M.R., 2010. Adenomatoid odontogenic tumour: review of the literature and an analysis of 33 cases from South Africa. *Int J Oral Maxillofac Surg*, 39:843-846.

MOSQUEDA-TAYLOR, A., CARLOS-BREGNI, R., LEDESMA-MONTES, C., FILLIPI, R.Z., DE ALMEIDA, O.P., VARGAS, P.A., 2005. Calcifying epithelial odontogenic tumour-like areas are common findings in adenomatoid odontogenic tumours and not a specific entity. *Oral Oncol*, 41:214-215.

NEVILLE, B.W., DAMM, D.D., ALLEN J.E., BOUQUOT, E.D.S., 2002. Oral and Maxillofacial Pathology, Chapter 15. *Odontogenic cysts and tumours* (Second edition), *Saunders, New Delhi*.

OTERO, D., ISRAEL M.S., ANTERO, S., LOURENCO, S., 2009. Bilateral adenomatoid hamartoma. *Oral*

Surg Oral Med Oral Path Oral Radiol Endo, 107:24-26.

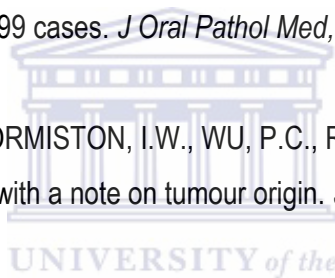
PHILIPSEN, H.P, BIRN, H., 1969. The adenomatoid odontogenic tumour. Ameloblastic adenomatoid tumour or adeno-ameloblastoma. *Acta Pathol Microbiol Scand*, 75: 375–398.

PHILIPSEN, H.P, REICHARDT, P.A., 1998. Adenomatoid Odontogenic tumour: facts and figures. *Eur J Cancer B Oral Oncol*, 35:125-31.

PHILIPSEN, H.P, REICHARDT, P.A., 1998. Unicystic Ameloblastoma. A review of 193 cases from the literature. *Oral Oncology*, 34:317-325.

PHILIPSEN, H.P., REICHARDT, P.A, ZHANG, K.H., NIKAI, H., YU, Q.X., 1991. Adenomatoid odontogenic tumour: biologic profile based on 499 cases. *J Oral Pathol Med*, 20:149-158.

PHILIPSEN, H.P., SAMMAN, N., ORMISTON, I.W., WU, P.C., REICHARDT, P.A., 1992. Variants of the adenomatoid odontogenic tumour with a note on tumour origin. *J Oral Pathol Med*, 21:348-352.



R CORE TEAM (2013). R: A language and environment for statistical computing. R Foundation for Statistical Computing, Vienna, Austria. URL <http://www.R-project.org/>

RAUBENHEIMER, E.R., SEELIGER, J.E., VAN HEERDEN, W.F.P., DREYER, A.F., 1991. Adenomatoid odontontogenic tumour: a report of two large lesions. *Dentomaxillofac Radiol*, 20: 43–45.

RAUBENHEIMER, E.J., VAN HEERDEN, W.F.P., NOFKE, C.E.E., 1995. Infrequent clinicopathological findings in 108 ameloblastomas. *J Oral Pathol Med*, 24:227–32.

REGEZI, J.A., 1978. Odontogenic tumours: Analysis of 706 cases. *J Oral Surg*, 36: 771-778.

REGEZI, J.A., SCIUBBA, J.J., JORDAN, R.C.K., 1999. Oral Pathology Clinical Pathologic Correlation (Fourth edition) *Odontogenic tumours*. Saunders, St. Louis, Missouri, USA.

- RICK, G.M., 2004. Adenomatoid Odontogenic Tumour. *Oral Maxillofacial Surg Clin N Am*, 16: 333-354.
- SHEAR, M., 2003. Odontogenic keratocysts: natural history and immunohistochemistry. *Oral Maxillofacial Surg Clin N Am*, 15 (2003) 347–362.
- SHEAR, M., 2002. The aggressive nature of the odontogenic keratocyst: is it a benign cystic neoplasm? Part 2. Proliferation and genetic studies. *Oral Oncology*, 38 (2002): 323–331.
- SHEAR, M., 1964. The Unity of tumours of Odontogenic epithelium. *British Journal of Oral Surgery*, Volume 2: 212-221.
- SINGH, S., 2000. Unicystic ameloblastoma: A critical appraisal. *MCHD Thesis*.
- STEENSLAND, H.S., 1905. Epithelioma adamantinum. *J Exper Med*, 6: 377–389.
- SUZUKI, H., HASHIMOTO, K., 2005. Adenomatoid Odontogenic Tumour of the Maxilla; Immunohistochemical Study. *Asian J Maxillofacial Surg*, 17(4):267-271.
- TAJIMA, Y., SAKAMOTO, E., YAMAMOTO, Y., 1992. Odontogenic cyst giving rise to an adenomatoid odontogenic tumour: report of a case with peculiar features. *J Oral Maxillofac Surg*, 50:190–193.
- TAKAHASHI, K., YOSHINO, T., HASHIMOTO, S., 2001. Unusually large cystic adenomatoid odontogenic tumour of the maxilla: case report. *Int J Oral Maxillofac Surg*, 30(2):173–5.
- THOSAPORN, W., IAMAROON, A., PPONGSIRIWET, S., NG, K., 2004. A comparative study of epithelial cell proliferation between the odontogenic keratocyst, orthokeratinized odontogenic cyst, dentigerous cyst and ameloblastoma. *Oral Dis*, 2004;10:22-6.
- TUOMINEN, V., RUOTOISTENMAKI, S., VIITANEN, A., JUMPPANEN, M., ISOLA, J., 2010. ImmunoRatio: a publicly available web application for quantitative image analysis of estrogen receptor (ER), progesterone receptor (PR), and Ki-67. *Breast Cancer Res*, 2010, 12:R56


TOIDA, M., HYODO, I., OKUDA, T., TATEMATSU, N., 1990. Adenomatoid odontogenic tumour: report of two cases and survey of 126 cases in Japan. *J Oral Maxillofac Surg*, 48:404-408.

UNAL, T., CETINGUL, E., GUNBAY, T., 1995. Peripheral adenomatoid odontogenic tumour; Birth of a term. *J Clin Paed Dent*, 19:139-142.

YAMAMOTO, H., KOZAWA, Y., HIRAI, G., HAGIWARA, T., NAKAMURA, T., 1981. Adenomatoid odontogenic tumour: light and electron microscopic study. *Int J Oral Surgery*, 10: 272-278.

ZEITOUN I, M., DHNRAJANI, P.J., MOSADOMI, H.A., 1996. Adenomatoid odontogenic tumour arising in a calcifying odontogenic cyst. *J Oral Maxillofac Surg*, 54:634–637.

ZHANG, L.L., YANG, R., ZHANG, L., LI, W., MACDONALD-JANKOWSKI, D., POH, C.F., 2010. Dentigerous cyst: a retrospective clinicopathological analysis of 2082 dentigerous cysts in British Columbia, Canada. *Int. J. Oral Maxillofac Surg*, 39: 878–882.



Appendix A

Table of results

Slide	a	b	c	d	e	f	g	h	i	j	Total	Average
28295	29.6	18.5	14.7	13.8	21.2	24.3	34.2	21.1	11	12.6	201	20.1
A22666	19.9	7.1	14.4	16.9	58.6	33	48	20.4	17.5	9.2	245	24.5
B22666	4.9	5.5	6.1	6	7.4	5.3	6.3	7.5	5.2	3.9	58.1	5.81
5092	6.9	6.8	6.2	10.5	12	11.2	15.6	5.3	6.6	7.6	78.2	7.82
6532	6	4.8	9.7	4	7	7.4	6.2	12.7	4.1	10.6	72.5	7.25
6664	13.6	16.9	9.4	18.8	10.6	8.3	12	16.6	15.8	13.8	135.8	13.58
6981	5.4	7.8	3.2	5.1	5.3	4.4	4.3	9	0	4.8	49.3	4.93
12536	8.6	9.3	3.2	4.4	3.3	4.1	4.1	2.2	2.4	3.1	44.7	4.47
8400	7.9	12.2	6	9.2	6.9	15.9	10.4	9.6	7.6	3.1	88.8	8.88
18347	5.6	2.9	9.7	5.8	4.5	4.9	9.5	12.8	4.8	6.4	66.9	6.69
12545	1.9	3.9	2.8	5.7	4.8	4.7	2.5	2.1	5.7	1.6	35.7	3.57
12770	69.5	4.7	33	48.4	55.6	87.7	53.5	8.7	34	45	440.1	44.01
13889	17.4	10.3	8.4	11.2	4.1	8.6	4.3	7.9	8.7	14.4	95.3	9.53
13889-5	3.9	5.2	4.1	14.4	3.2	5.5	6.2	4.8	6	5.5	58.8	5.88
10688	6.2	6.8	7.9	6.7	5.3	5.7	5	5.3	3.8	8.6	61.3	6.13
8607	2.5	2.6	3.1	3.5	5	19.6	8.2	9.8	8.1	14	76.4	7.64
3854	4.1	3.3	2.5	1.7	1.5	2.7	3.3	1.9	3.1	13.2	37.3	3.73
4512	3.3	5.1	3.3	9.1	2.5	3.7	3.7	3.8	4.1	2.1	40.7	4.07
7162	4.3	4.8	7.5	4	6.5	10.4	4.6	4.4	4.6	2.6	53.7	5.37
19455	13.9	15.1	24.6	10.6	7.2	7.1	15.3	16.3	20.3	10.9	141.3	14.13
EPA2858	4.7	7.4	4.2	3.8	4.1	4.9	4.8	7.8	5.3	6.9	53.9	5.39
6503	4.2	4.5	5.5	3.7	3.3	4.9	4.9	3.4	5	3.9	43.3	4.33
7912	4.5	7.3	10.1	5.5	17.9	6	6.9	4.9	7.6	7.3	78	7.8
18698	4.1	5.3	4.8	6	3.9	3.9	5	11.5	8.4	4.5	57.4	5.74
18912	1.7	6.8	4.9	1.9	1.7	2	3	1.8	2	1.4	27.2	2.72
19342	3.8	3.4	5.2	4.5	4.8	4.2	3.9	2.5	3.7	2.6	38.6	3.86
15404	2.3	7.2	2.9	24	2.4	1.9	3.4	1.9	2.2	3.2	51.4	5.14
17932	3.6	2.7	3.2	3.1	4.1	4.4	4.6	2.8	4.3	4.1	36.9	3.69
9783	1.7	2.3	2.5	2	3	2	2	2.8	1.8	1.7	21.8	2.18
12148	7.8	8.9	3.5	8.3	6.3	5.9	9.9	7.8	2.2	6.6	67.2	6.72