

UNIVERSIDADE DE SÃO PAULO
HOSPITAL DE REABILITAÇÃO DE ANOMALIAS CRANIOFACIAS

GUILHERME ADAM FRAGA

**Evolution of speech perception in patients with ossified
cochlea and short array cochlear implant**

**Evolução da percepção de fala em pacientes com
ossificação coclear e implante coclear com eletrodo curto**

BAURU
2023

GUILHERME ADAM FRAGA

Evolution of speech perception in patients with ossified cochlea and short array cochlear implant

Evolução da percepção de fala em pacientes com ossificação coclear e implante coclear com eletrodo curto

Dissertação constituída por artigo apresentada ao Hospital de Reabilitação de Anomalias Craniofaciais da Universidade de São Paulo para obtenção do título de Mestre em Ciências da Reabilitação, na área de concentração Fissuras Orofaciais e Anomalias Relacionadas.

Orientador: Prof. Dr. Luiz Fernando Manzoni Lourençone

Versão Corrigida

BAURU
2023

Adam Fraga, Guilherme

Evolution of speech perception in patients with
ossified cochlea and short array cochlear implant/
Guilherme Adam Fraga. -- Bauru, 2023.
41 p. : il. ; 31 cm.

Dissertação (mestrado) -- Hospital de
Reabilitação de Anomalias Craniofaciais,
Universidade de São Paulo, 2023.

Orientador: Prof. Dr. Luiz Fernando Manzoni
Lourençone

Nota: A versão original desta dissertação encontra-se disponível
no Serviço de Biblioteca e Documentação da Faculdade de
Odontologia de Bauru – FOB/USP.

Autorizo, exclusivamente para fins acadêmicos e científicos, a
reprodução total ou parcial desta dissertação/tese, por processos
fotocopiadores e outros meios eletrônicos.

Comitê de Ética do HRAC-USP
Protocolo nº: 4.741.728
Data: 28/05/2021

FOLHA DE APROVAÇÃO



FOLHA DE APROVAÇÃO

Guilherme Adam Fraga

Dissertação constituída por artigo apresentada ao Hospital de Reabilitação de Anomalias Craniofaciais da Universidade de São Paulo para obtenção do título de Mestre em Ciências da Reabilitação, na área de concentração Fissuras Orofaciais e Anomalias Relacionadas.

Aprovado em: 27 de junho de 2023.

Banca Examinadora

Prof. Dr. Joel Lavinsky
Instituição: UFRGS

Profa. Dra. Liege Franzine Tanamati
Instituição: HRAC-USP

Prof. Dr. Rubens Vuono de Brito Neto
Instituição: FOB-USP

Prof. Dr. Luiz Fernando Manzoni Lourençone
Hospital de Reabilitação de Anomalias Craniofaciais (Orientador)

Profa. Dra. Ivy Kiemle Trindade Suedam
Presidente da Comissão de Pós-Graduação do HRAC-USP

Data de depósito da dissertação junto à SPG: 22/05/2023

DEDICATÓRIA

Aos meus pais, Marcia e Carlos, que me proporcionaram o milagre de estar nesse mundo e me constituíram humano, com a mais fina educação que se poderia ter recebido.

Ao meu irmão Gustavo, inseparável companheiro da infância e juventude, que me fez mais sólido em todos os momentos e me ensinou a partilhar.

À minha avó Nilda, que me abraça diariamente desde outra dimensão, ainda envolvendo-me com sua sofisticada simplicidade e dedicação a cada tarefa.

Aos meus tios e tias, segundos pais e mães, fundamentais alicerces para meu crescimento.

À minha primeira professora, Claurenice, alfabetizadora da primeira série do ensino fundamental na Escola Estadual Senador Pinheiro Machado, em São Luiz Gonzaga-RS, que me permitiu escrever essas palavras e poder compreendê-las.

AGRADECIMENTOS

Agradeço ao Prof. Dr. Luiz Fernando Manzoni Lourenço, Professor livre-docente pela Faculdade de Odontologia de Bauru da Universidade de São Paulo (USP), meu orientador, por todos os conhecimentos teóricos e práticos compartilhados e por ser um grande exemplo de docente e profissional.

À Dra. Júlia Speranza Zabeu pela colaboração neste trabalho e por compartilhar sua experiência no campo da pesquisa.

À colega otorrinolaringologista Rhaissa Heinen Peixoto pelo apoio na execução deste trabalho.

Ao Prof. Dr. Joel Lavinsky, à Dra Liège Franzine Tanamati e à Dra. Maria Valéria Schmidt Goffi Gomez, membros da banca examinadora no exame de qualificação, pelas importantes observações e orientações.

Ao Hospital de Reabilitação de Anomalias Craniofaciais (HRAC) da Universidade de São Paulo pela oportunidade de pesquisa.

Aos queridos colegas e amigos da Seção de Implante Coclear do HRAC/USP, por todos os conhecimentos compartilhados e pelo acolhimento e dedicação exemplar aos pacientes.

À minha amiga Elisabete Honda Yamaguti, pelo auxílio e atenção em todos os momentos.

À minha amiga, Ana Carolina Soares Succar, colega do programa de Prática Profissionalizante em Implante Coclear e Próteses Auditivas Implantáveis do HRAC/USP, pelo apoio na realização deste trabalho.

Aos meus colegas e preceptores da Residência Médica de Otorrinolaringologia do Hospital de Reabilitação de Anomalias Craniofaciais (HRAC) da Universidade de São Paulo, pelos momentos compartilhados e pelo apoio em todos os momentos.

Aos meus colegas e professores do Curso de Medicina da Universidade Federal de Santa Maria (UFSM-RS) pela formação médica de excelência recebida.

Aos pacientes do Hospital de Reabilitação de Anomalias Craniofaciais (HRAC) da Universidade de São Paulo, que dão sentido ao esforço da pesquisa.

“Como no estás experimentado en las cosas del mundo, todas las cosas que tienen dificultad te parecen imposibles; confía en el tiempo, que suele dar dulces salidas a muchas amargas dificultades”.

Miguel de Cervantes Saavedra

El ingenioso Hidalgo Don Quijote de la Mancha

“Eu quase que nada não sei. Mas desconfio de muita coisa”.

João Guimarães Rosa
Grande Sertão: Veredas

RESUMO

Objetivo. Relatar a percepção de fala dos usuários de implante coclear com eletrodo curto, indicado como reabilitação em pacientes com surdez severa a profunda, especialmente quando houver ossificação coclear. Nesses casos, com redução da luz intracoclear, a inserção total se torna mais difícil, com a necessidade do uso desse tipo de eletrodo (15 mm). Poucos estudos foram publicados para avaliar o desempenho auditivo nesses pacientes, apresentando resultados audiológicos, até o momento, controversos. **Metodologia.** Procedeu-se análise retrospectiva de prontuários de pacientes submetidos à cirurgia para implante coclear com eletrodo curto, entre 2009 e 2020, no Hospital de Reabilitação de Anomalias Craniofaciais da USP. **Resultados.** Houve evolução de desempenho nos testes de percepção de fala na análise dos dados. Meningite e perda auditiva congênita foram as principais etiologias de indicação de IC na amostra. **Conclusão.** O IC com eletrodo curto é uma alternativa no manejo de pacientes com história de ossificação coclear e perda auditiva neurossensorial severa ou profunda.

Descritores: Implante coclear. Percepção de fala. Eletrodo curto.

ABSTRACT

Evolution of speech perception in patients with ossified cochlea and short array cochlear implant

Purpose. To report the speech perception of users of cochlear implants (CI) with short array, indicated as rehabilitation in patients with severe to profound deafness, especially when there is cochlear ossification. In these cases, with reduced intracochlear patency, total insertion becomes more difficult, requiring the use of this type of electrode (15 mm). Few studies have been published to evaluate auditory performance in these patients, presenting controversial audiological results. **Methods.** A retrospective analysis of medical records of patients who underwent surgery for cochlear implantation with short electrode, between 2009 and 2020, at the Hospital for Rehabilitation of Craniofacial Anomalies, University of São Paulo (HRAC-USP) was carried out. **Results.** There was performance evolution in the speech perception tests in the data analysis. Meningitis and congenital hearing loss were the main indications for CI in the sample. **Conclusion.** CI with a short lead is an alternative in the management of patients with a history of cochlear ossification and severe or profound sensorineural hearing loss. **Significance.** To demonstrate the evolution of speech perception tests with short array cochlear implant in patients with or without ossified cochlea and its characteristics for application in clinical practice.

Keywords: Cochlear Implant; speech perception; short array

LIST OF FIGURES

Figure 1 - Evolution of tests in patients with and without cochlear ossification	26
--	----

LIST OF TABLES

Table 1 -	Short array patients data	24
Table 2 -	Evaluation of speech perception tests among groups of patients with ossified (Yes) and non-ossified cochlea (No)	25

LIST OF ACRONYMS

CI	Cochlear Implant
CSF	Cerebrospinal Fluid
GM/MS	Ministry of Health Minister's Office (Gabinete do Ministro/Ministério da Saúde)
HRAC	Hospital for Rehabilitation of Craniofacial Anomalies
IT-MAIS	Infant Toddler – Meaningful Auditory Integration Scale
LC	Language Category
MUSS	Meaningful Use of Speech Scale
PSAD	Personal Sound Amplification Device
RSS	Recognition of Sentences in Silence
RSN	Recognition of Sentences in Noise
USP	University of São Paulo
WR	Word Recognition

SUMMARY

1	INTRODUCTION	14
2	OBJECTIVES	16
3	ARTICLE	17
4	FINAL CONSIDERATIONS.....	32
	REFERENCES	33
	APPENDIX	36
	ANNEXES	37

1. INTRODUCTION

Cochlear Implant (CI) is considered one of the possible treatments for deafness, being indicated mainly for severe and profound bilateral sensorineural loss, since deafness is the most common sensory disorder, affecting 1 in every 700-1,000 live births [1]. The first cochlear implant surgery was performed in 1961 by House and Edgerton, and since then, devices, technologies and surgical techniques have been developing [2].

The number of inserted electrodes is a significant factor in determining post-implant performance, especially with regard to speech and language skills. Each commercially available cochlear implant system contains a specific number of electrodes. Ideally, all electrodes should be inserted, even if they are not subsequently activated, as this allows greater flexibility in programming [3].

Standard electrode arrays are designed for a normal cochlea, therefore they may not be suitable for cochlea with anatomical changes. To contemplate the atypical cochlear anatomy, special matrices were developed, as is the case of the compressed array, from the company Med-El (Innsbruck, Austria), which compressed the same twelve electrodes existing in its standard implants (26.4mm) in a space of 12.1mm.

Cochlear ossification was once considered a contraindication for implantation [4], as obliteration of the cochlea by bone neoformation or fibrous tissue does not allow standard electrodes to be properly inserted from the basal turn, in addition to causing potential complications, such as perilymphatic fistula [5]. Some options of surgical techniques are available to solve this problem. If ossification or fibrosis are found in the scala tympani, for example, an alternative is the insertion of electrodes in the scala vestibuli. The oldest technique used in fully ossified cochleae is to drill the basal turn as deep as possible and insert the number of electrodes that fits inside it. In these cases, an average insertion length of 8.5 to 14.3 mm can be achieved [6].

Studies have been done on the performance of cochlear implant users with cochlear ossification and partial electrode insertion and controversial results have been reported. Kirk et. al. [7] did not find significant difference when comparing the speech perception tests in the partial or total insertion of the electrodes. Croghan et al. [8] analyzed speech performance with a competitive speaker, using 4, 8, 12 or 22

electrodes, with significant improvement as the number of active electrodes increased from 12 to 22 electrodes.

A major challenge for cochlear implant surgery is ossified cochleae, in which electrode insertion may be incomplete, with potential loss of auditory performance. In these patients, with short array, the evaluation of speech perception is still scarce in the literature. This study was motivated due to the parameters observed in the scores of these patients in our clinical practice, so the aim is to report the speech perception of users of cochlear implants (CI) with short array.

2. OBJECTIVES

This study was undertaken to report the speech perception of users of cochlear implants with short array and its characteristics.

3. ARTICLE

The article presented in this Dissertation was written according to the Acta Oto-Laryngologica instructions and guidelines for article submission.

Evolution of speech perception in patients with ossified cochlea and short array cochlear implant

Guilherme Adam Fraga¹

1 Hospital for Rehabilitation of Craniofacial Anomalies (HRAC), University of São Paulo, Bauru, Brazil

Rhaissa Heinen Peixoto¹

1 Hospital for Rehabilitation of Craniofacial Anomalies (HRAC), University of São Paulo, Bauru, Brazil

Julia Speranza Zabeu²

2 Cochlear Implant Section, Hospital for Rehabilitation of Craniofacial Anomalies (HRAC), University of São Paulo, Bauru, Brazil

Luiz Fernando Manzoni Lourençone³

3 Cochlear Implant Section and Department of Otolaryngology, Hospital for Rehabilitation of Craniofacial Anomalies (HRAC), University of São Paulo, Bauru, Brazil; Bauru School of Dentistry, University of São Paulo, Bauru, Brazil.

CONTACT

Prof. Luiz Fernando Manzoni Lourençone

luiz.fernando@usp.br

Section of Cochlear Implant

Hospital for Rehabilitation of Craniofacial Anomalies, University of São Paulo
Bauru, Brazil

Abstract

Purpose. To report the speech perception of users of cochlear implants (CI) with short array, indicated as rehabilitation in patients with severe to profound deafness, especially when there is cochlear ossification. In these cases, with reduced intracochlear patency, total insertion becomes more difficult, requiring the use of this type of electrode (15 mm). Few studies have been published to evaluate auditory performance in these patients, presenting controversial audiological results. **Methods.** A retrospective analysis of medical records of patients who underwent surgery for cochlear implantation with short electrode, between 2009 and 2020, at the Hospital for Rehabilitation of Craniofacial Anomalies, University of São Paulo (HRAC-USP) was carried out. **Results.** There was performance evolution in the speech perception tests in the data analysis. Meningitis and congenital hearing loss were the main indications for CI in the sample. **Conclusion.** CI with a short array is an alternative in the management of patients with a history of cochlear ossification and severe or profound sensorineural hearing loss. **Significance.** To demonstrate the evolution of speech perception tests with short array cochlear implant in patients with or without ossified cochlea and its characteristics for application in clinical practice.

Keywords: Cochlear Implant; speech perception; short array; ossified cochlea

Introduction

Cochlear Implant (CI) is considered one of the possible treatments for deafness, being indicated mainly for severe and profound bilateral sensorineural loss, since deafness is the most common sensory disorder, affecting 1 in every 700-1,000 live births [1]. The first cochlear implant surgery was performed in 1961 by House and Edgerton, and since then, devices, technologies and surgical techniques have been developed [2].

The number of inserted electrodes is a significant factor in determining post-implant performance, especially with regard to speech and language skills. Each commercially available cochlear implant system contains a specific number of electrodes. Ideally, all electrodes should be inserted, even if they are not subsequently activated, as this allows greater flexibility in programming [3].

Standard electrode arrays are designed for a normal cochlea, therefore they may not be suitable for cochlea with anatomical changes. To contemplate the atypical cochlear anatomy, special matrices were developed, as is the case of the compressed array, from the company Med-El (Innsbruck, Austria), which compressed the same twelve electrodes existing in its standard implants (26.4mm) in a space of 12.1mm.

Cochlear ossification was once considered a contraindication for implantation [4], as obliteration of the cochlea by bone neoformation or fibrous tissue does not allow standard electrodes to be properly inserted from the basal turn, in addition to causing potential complications, such as perilymphatic fistula [5]. Some options of surgical techniques are available to solve this problem. If ossification or fibrosis are found in scala tympani, for example, an alternative is the insertion of electrodes in scala vestibuli. The oldest technique used in fully ossified cochleae is to drill the basal turn as deep as possible and insert the number of electrodes that fits inside it. In these cases, an average insertion length of 8.5 to 14.3 mm can be achieved [6].

Studies have been done on the performance of cochlear implant users with cochlear ossification and partial electrode insertion and controversial results have been reported. Kirk et. al. [7] did not find significant difference when comparing the speech perception tests in the partial or total insertion of the electrodes. Croghan et al. [8] analyzed speech performance with a competitive speaker, using 4, 8, 12 or 22

electrodes, with significant improvement as the number of active electrodes increased from 12 to 22 electrodes.

A major challenge for cochlear implant surgery is ossified cochleae, in which electrode insertion may be incomplete, with potential loss of auditory performance. In these patients, with short array, the evaluation of speech perception is still scarce in the literature. This study was motivated due to the parameters observed in the scores of these patients in our clinical practice, so the aim is to report the speech perception of users of cochlear implants (CI) with short array.

Methods

Study Design

This is a retrospective and descriptive study, with a two-year longitudinal follow-up, of data from the medical records of all patients who underwent surgery for cochlear implantation with a Compressed electrode from the company Med-El® (Innsbruck, Austria), between 2009 and 2020, in Cochlear Implant Section of the Hospital for Rehabilitation of Craniofacial Anomalies, University of São Paulo (HRAC-USP), in Bauru (São Paulo), Brazil. Upon submission of the research project to the Research Ethics Committee of HRAC/USP, the informed consent form was waived.

Participant eligibility

Patients with severe or profound sensorineural hearing loss, with an indication for CI according to GM/MS Ordinance No. 2776 of the Brazilian Ministry of Health; all patients operated with a Med-El® cochlear implant, Ti100 internal device, compressed electrode, between 2009 and 2020, who had imaging tests with signs suggesting ossification or cochlear fibrosis, regardless of the etiology of the hearing loss; use of CI for at least two years after surgery, with daily use of the device; and cognitive ability to respond to audiological tests performed pre- and postoperatively.

Free field tests were collected at frequencies of 0.5, 1, 2, 3, 4 e 6kHz in all patients when cochlear implant was indicated, before surgery. At 0.5 and 1kHz, the mean was 118.3dB and the median was 120dB; at 2, 3, 4 and 6kHz, the mean and median were 120dB.

The indications of the Brazilian Ministry of Health are: severe and/or profound bilateral sensorineural hearing loss; use of a personal sound amplification device (PSAD) prior to surgery, with a result equal to or less than 60% of sentence recognition in an open set with the use of PSAD in the better ear and equal to or lower than 50% in the ear to be implanted; presence of favorable indicators for the development of oral language measured by standardized protocols; psychological adequacy; access to speech therapy; and commitment to care for the components of the cochlear implant.

Patients with auditory neuropathy or who did not allowed adequate audiological evaluation were excluded from the study.

Data collection

The data collected and analyzed by the study were: age, presence of associated syndrome, clinical indication, complete or partial insertion of electrodes, presence of cochlear ossification and pre-surgical speech perception tests and 3, 6, 12 and 24 months after implantation.

The tests collected and described are: IT-MAIS (Infant Toddler – Meaningful Auditory Integration Scale) [9], MUSS (Meaningful Use of Speech Scale) [10], hearing category [11], language category [12], word recognition [13] and sentences recorded in silence and in noise [14], according to what was done in each analyzed patient.

Based on the questionnaires and assessments, children were classified into one of the following six hearing categories [11]: Category 0- Does not detect speech; Category 1- Detects speech; Category 2- Differs words based on suprasegmental cues; Category 3- Begins closed set identification (identical words in duration, but with multiple spectral differences); Category 4- Identifies words by recognizing vowels in a closed context; Category 5- Identifies words by recognizing consonants in closed contexts; Category 6- Recognizes words in open sets.

Based on responses to MUSS [10], the therapist's perception and observation, and the parents' report, the children were classified into one of the following five language categories [12]: Category 1- The child does not speak and may present undifferentiated vocalizations; Category 2- The child speaks only isolated words; Category 3- The child builds sentences with two or three elements; Category 4- The child builds sentences with four or five words and begins using connectives;

Category 5- The child builds sentences with more than five words and conjugates verbs, uses connectives, and is fluent in oral language.

Speech perception was assessed using an open-set list of 20 disyllable words (CVCV; C = consonant, V = vowel) [13] in quiet and three open-set lists with 20 sentences each in quiet and noise [14]. The speech signal was presented in an acoustic booth by using the Madsen Astera audiometer (Otometrics; Natus, Medical Denmark) connected to an amplifier in a free field at 0° azimuth at 60 dB SPL. Words were presented by trained audiologists using live voice while monitoring the VU meter to keep intensity at 60 dB SPL. Sentences were conducted by applying a recorded list of 20 affirmative Portuguese sentences with each sentence having three to seven words for a total of 100 words without repetition. The lists were balanced according to the Brazilian Portuguese phonetic inventory [14]. For the test in noise, a cocktail party noise at 50 dB SPL (+10 dB signal-to-noise ratio, SNR) was presented simultaneously through the same loudspeaker. For both the word and sentence recognition tests, participants were asked to repeat the speech stimuli and each word repeated correctly was scored, resulting in a final score range from 0 to 100%.

Statistical Analysis

The Friedman test was used to assess the effect of the five periods (pre-implantation, 3 months, 6 months, 12 months and 24 months) on the score of each test performed on the individual. The use of the Friedman test is justified because the observations are characterized by repeated measurements on the same individuals, and despite the number of observations ($n = 53$), the normal approximation may be unfeasible given the nature of the scale of the response variables.

The Friedman Test is a non-parametric test analogous to the analysis of variance with repeated measures. The significance level adopted was $\alpha = 0.05$. In case of statistical significance of the Friedman test, post-hoc analysis was performed with the Conover Test.

Results

In a total of 1713 patients undergoing implantation, 70 users of the MED-EL Cochlear Implant, Sonata Ti 100 internal device, short array, who underwent surgery between 2009 and 2020 at the Hospital for Rehabilitation of Craniofacial Anomalies, University of São Paulo (HRAC-USP). Twenty-five patients were excluded: 10 who underwent internal device replacement, 10 who used another type of contralateral electrode, and 5 who did not have sufficient data for analysis, due to transfer to another service or unjustified absences from follow-up appointments.

Among the 45 patients eligible for the study, 53 ears implanted unilaterally or bilaterally were analyzed (Table 1). Thirty eight ears were from male patients (72%) and 15 from female patients (28%). All patients underwent unilateral or bilateral cochlear implantation using a surgical technique with a standardized retroauricular approach, through posterior tympanotomy, performed by the same surgical team.

In this total of 53 ears, 37 (70%) were from patients aged between 1 and 12 years old and 16 (30%) from patients over 12 years old. The most frequent indications were post-meningitis (66%) and congenital hearing loss (24%). In addition, cases of otosclerosis and sudden deafness were also observed. Among the congenital causes, there were idiopathic ones, Branchio-Oto-Renal Syndrome, Cardiofacial Syndrome and Dandy-Walker Syndrome.

Ossification was observed at the opening of the cochlea in 25 ears (47%), while cochlear patency was found in 28 ears (53%). All patients were successful in completely inserting the array, except for 11 cases (21%). These patients with partial insertion, due to severe cochlear ossification, consist of 8 cases of post-meningitis, 1 case of sudden deafness, 1 case of otosclerosis and 1 case of congenital deafness.

Among patients who reported a medical history of meningitis as the etiology of deafness, the mean age at implantation was 1.8 years (standard deviation 2.06). The youngest patient was implanted at 1 year old, while the oldest underwent the procedure at 59 years old. Cochlear ossification was found in 18 ears (51%): 7 had partial insertion of electrodes, and 11 complete. The average implantation time after the diagnosis of meningitis was 6.97 years, with a median of 2 years. The shortest time interval between diagnosis and CI was 30 days, and the longest was 38 years.

Table 1. Etiology x Ossification: short array patients data.

Etiology	Ossification	No ossification	Total of ears
Meningitis	18	17	35
Congenital hearing loss	4	8	12
Otosclerosis	1	1	2
Dandy Walker Syndrome	0	1	1
Cardiofacial Syndrome	0	1	1
Branchiootorenal Syndrome	1	0	1
Sudden hearing loss	1	0	1

Performance Outcomes

Patients with ossification, regardless of the etiology of hearing loss (n= 25 ears), were evaluated in five periods with eight tests performed at each time. In Language Category, a stability of scores was observed in the first 12 months of follow-up and an improvement after 24 months of CI use ($p= 0.001$). Word and Sentence Recognition in Silence and Noise also tended to increase scores at 24 months, but without statistical significance ($p= 0.09$, $p= 0.09$ and $p= 0.24$ respectively). IT-MAIS showed worsening scores over time, but also without statistical significance ($p= 0.64$) (table 2).

Patients without ossification were also evaluated in the same period, regardless of the etiology of the hearing loss (n= 28 ears). IT-MAIS kept the scores stable over time ($p= 0.03$). In Language Category, scores improved at 12 months, with a new increase at 24 months ($p= 0.00$). Word and Sentence Recognition in Silence remained stable from the preoperative period up to 12 months of CI use, showing improvement at 24 months (both $p= 0.00$). Sentence Recognition in Noise tended to improve over time, but no statistical difference was observed in the Friedman Test for this variable ($p=0.14$) (table 2).

Auditory Category and MUSS tests had no patients in the five successive evaluations and therefore could not be evaluated. Comparing patients with and without ossification, an evolution was observed in all tests over 24 months, with the exception

of IT-MAIS. Better scores were observed in the follow-up of patients without cochlear ossification (figure 1).

Table 2. Evaluation of speech perception tests among groups of patients with ossified (Yes) and non-ossified cochlea (No). LC: language category; WR: word recognition; RSS: recognition of sentences in silence; RSN: recognition of sentences in noise.

Group	Test	Statistic	Degrees of Freedom	<i>p</i> -value
Yes	LC	17.8689	4	.0013
Yes	IT-MAIS	2.4762	4	.6489
Yes	WR	8.000	4	.0916
Yes	RSS	7.8049	4	.0990
Yes	RSN	5.4167	4	.2472
No	LC	25.7963	4	.0000
No	IT-MAIS	10.5618	4	.0320
No	WR	29.5260	4	.0000
No	RSS	26.3457	4	.0000
No	RSN	6.8454	4	.1443

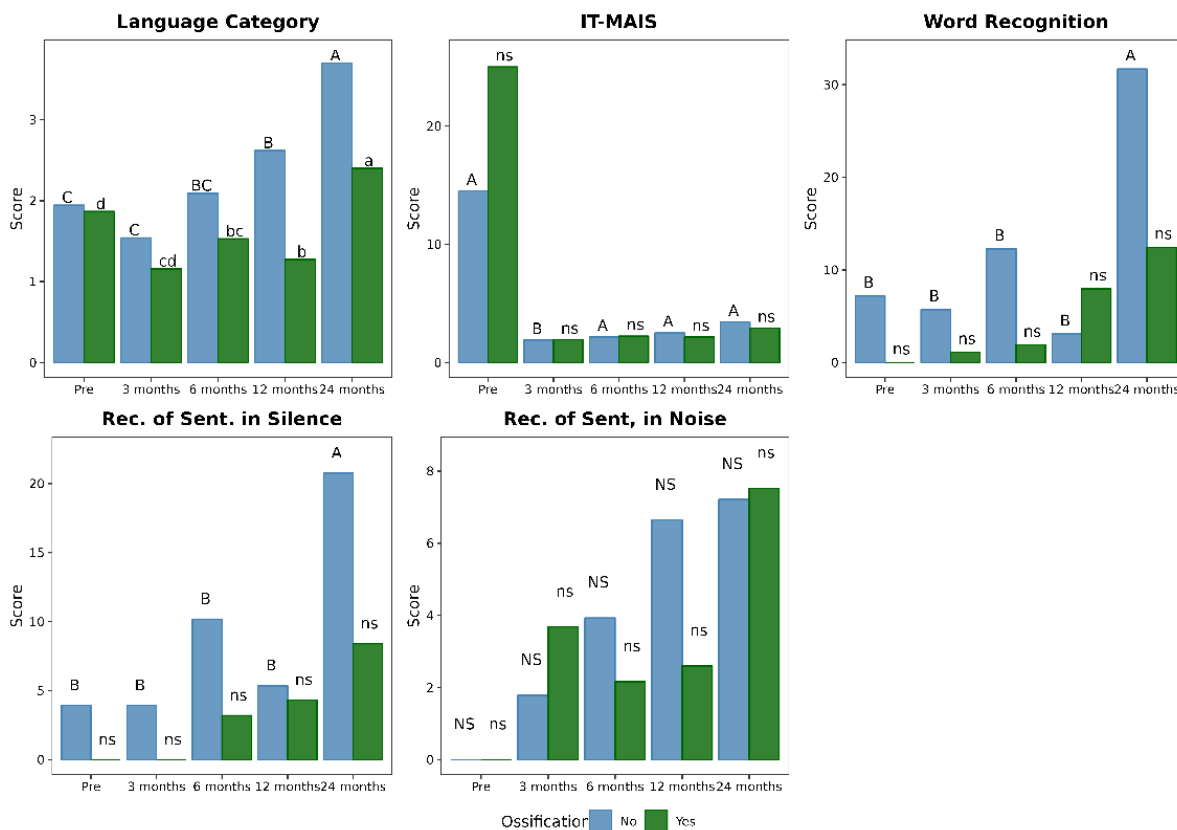


Figure 1. Evolution of tests in patients with and without cochlear ossification (uppercase letters = group without ossification, with “A” being the best score found and “C” being the worst; lowercase letters = with ossification, with “a” being the best score and “d” the worst; NS/ns = not significant at a significance level of 5%; different letters in the same group represent statistically significant difference).

Discussion

The most common indications described for short array are post-meningitis and congenital hearing loss. One of the advantages is patient safety, once its insertion can be performed without a complete drill-out, which reduces the risk of injury to the facial nerve, as it is known that this technique is associated with its increase, in addition to of injury to the carotid artery and the modiolus [15].

Sixteen patients had signs of fibrosis or cochlear ossification on preoperative imaging, but had complete insertion of electrodes intraoperatively. Since their clinical conditions and complementary exams suggested ossification, the use of a short array was previously requested, without the possibility of changing to a longer array when the cochlear patency was verified, a fact also described in the population studied by Bauer (2004) [3]. Studies show that the sensitivity of Computed Tomography (CT) in detecting early ossification is low, approximately 33% to 73%. Magnetic Resonance Imaging (MRI) is considered to have better sensitivity and specificity than CT in predicting ossification. The sensitivity of MRI combined with CT for detecting ossification can exceed 90% [4]. The ossification described in our study is the one found intraoperatively for each patient, regardless of imaging findings.

Wang et. al [16] showed that patients with partial insertion of electrodes had worse auditory performance than those with complete insertion. However, Tokat [17] and Nichani [18] affirm that patients with cochlear ossification may have auditory results as satisfactory as those without ossification, regardless of the array complete or partial insertion. These conflicting results are probably attributed to the clinical and surgical conditions of the patients in the different studies.

In our sample, among the 53 implants with short array, in 25 (47%) ossification was found in the cochlear opening. In the global evaluation, the scores of the speech perception tests of these patients tended to stability in the first 12 months of use, showing significant changes from this period of time up to 24 months. Several factors can explain the level of performance observe. By compressing the electrode, the distance between the pairs of electrodes is decreased, which can lead to an overlap of electric fields. This would limit selective stimulation of the auditory nerve, which is associated with reduced pitch discrimination and worse speech understanding [6].

Among these patients with ossification, there are 11 with a history of meningitis (6 children between 1 and 11 years old and 5 adults between 15 and 53 years old), 3 with a diagnosis of congenital hearing loss (2-3 years old), 1 with otosclerosis (40 years old) and 1 with Branchio-Oto-Renal Syndrome (1 year old). In these cases, it was not possible to exclude that sequelae resulting from the etiology of the hearing loss were responsible for the low performance in speech perception scores.

The etiology of hearing loss in our sample was meningitis in more than half of the cases, also being the most common cause of cochlear ossification reported in the literature. Infection of the subarachnoid space reaches the cochlea mainly through the cochlear aqueduct, which is the natural connection channel between the cerebrospinal fluid (CSF) and the inner ear [19], therefore, the ossification of the basal turn of the cochlea could be explained by the anatomical path itself. In these patients, there may still be a decrease in the number of functional spiral ganglion cells, in addition to the presence of fibrous tissue and new bone formation that may alter the cochlear nerve electrical impulse [19]. Damage to the central auditory system can occur, causing alterations in processing, as well as other cognitive deficits. In this sense, it is not surprising that this population has poorer objective outcome measures.

Cochlear ossification in meningitis develops rapidly, starting within 4 to 8 weeks of illness, and there may be complete ossification after 5 months. Auditory evaluation is recommended for all patients immediately after the diagnosis of meningitis [4], so that adequate auditory rehabilitation is carried out quickly and has a favorable outcome. The shortest time interval between the diagnosis of meningitis and CI was 30 days in our sample, with a median of 2 years among all patients with this etiology.

Despite the different tools for monitoring auditory performance in children and adults, the patients monitored had an evolution in speech perception with the time of use of the CI. In cases where these parameters were less satisfactory, further damage or reduction of spiral ganglion cells caused by inflammation or ossification and partial insertion of the electrode array should be considered. No complications were reported in the group of patients studied during the analyzed period.

Conclusion

A short array cochlear implant is an alternative in the management of patients with a history of cochlear ossification and severe or profound sensorineural hearing loss. The benefits for these patients are more clearly seen in subjective measures, showing evolution in auditory performance, especially with long-term effects.

Disclosure statement

The authors declare no conflicts of interest. The authors alone are responsible for the content and writing of this manuscript.

References

- [1] NISHIO, S., USAMI, S. Deafness Gene Variations in a 1120 Nonsyndromic Hearing Loss Cohort : Molecular Epidemiology and Deafness Mutation Spectrum of Patients in Japan. **Annals of Otology, Rhinology & Laryngology**. p. 1-12, 2015.
- [2] CÔTÉ, M. et al. Improving Audiologic Performance with Partial Insertion of a Compressed Array despite Intracochlear Retention Four Electrodes during Revision Cochlear Implant Surgery: A Case Report. **Cochlear Implants International**. 1rd ed. v. 16, p. 57–60, 2015.
- [3] BAUER, P. W.; ROLAND, P. S. Clinical Results with the Med-EI Compressed and Split Arrays in the United States. **Laryngoscope**. 3rd ed. v. 114, p. 428–433, 2004.
- [4] ZHANG N, Ruijuan Dong, Jun Zheng, Yanling Zhao, Yongxin Li, Xueqing Chen & Shouqin Zhao (2022) Cochlear implantation for post-meningitis deafness with cochlear ossification: diagnosis and surgical strategy, **Acta Oto Laryngol**, 142:5, 369-374.
- [5] BRITO R, Monteiro TA, Leal AF, Tsuji RK, Pinna MH, Bento RF. Surgical complications in 550 consecutive cochlear implantation. **Braz J Otorhinolaryngol**. 2012 Jun;78(3):80-5.

[6] COHEN, N. L., WALTZMAN, S.B. Partial insertion of the nucleus multichannel cochlear implant: technique and results. **Am J Otol.** v. 14, p. 357–361, 1993.

[7] KIRK, K. I. et al. Speech Perception Performance of Nucleus Multichannel Cochlear Implant Users with Partial Electrode Insertions. **Ear and Hearing.** v. 18, p. 456–471, 1997.

[8] CROGHAN et al. Re-examining the relationship between number of cochlear implant channels and maximal speech intelligibility. **The Journal of the Acoustical Society of America.** 6rd ed. v. 142, 2017.

[9] CASTIQUINI EAT, Bevilacqua MC. Escala de integração auditiva significativa: procedimento adaptado para a avaliação da percepção da fala. **Rev Soc Bras Fonoaudiol.** 2000;6:51-60.

[10] NASCIMENTO LT. Uma proposta de avaliação da linguagem oral [Monografia]. Bauru: Hospital de Pesquisa e Reabilitação de Lesões Lábio-Palatais, 1997.

[11] GEERS A. Techniques for assessing auditory speech perception and lipreading enhancement in young deaf children. **Volta Review.** 1994;96(5):85-96.

[12] BEVILACQUA MC, Delgado EMC, Moret ALM. Estudos de casos clínicos e crianças do Centro Educacional do Deficiente Auditivo (CEDAU) do Hospital de Pesquisa e Reabilitação de Lesões Lábio-Palatais – USP. **Encontro Internacional de Audiologia;** 1996; Bauru (SP).

[13] DELGADO EMC, Bevilacqua MC. Lista de palavras como procedimento de avaliação da percepção dos sons da fala para crianças deficientes auditivas. **Pró-fono Revista de Atualização Científica.** 1999; 11(1): 59-64.

[14] OLIVEIRA ST. Avaliação da percepção de fala utilizando sentenças do dia a dia. [Dissertação]. São Paulo: Pontifícia Universidade Católica de São Paulo; 1992.

[15] LENARZ T, Lesinski-Schiedat A, Weber BP, et al. The nucleus double array cochlear implant: a new concept for the obliterated cochlea. **Otol Neurotol** 2001;22:24–32.

[16] WANG L, Zhang D. Surgical methods and postoperative results of cochlear implantation in 79 cases of ossified cochlea. **Acta Otolaryngol** 2014;134:1219–24.

[17] TOKAT, Catli T, Bayrak F, et al. Cochlear implantation in postmeningitic deafness. **J Craniofac Surg** 2018;29:e245–8.

[18] NICHANI J, Green K, Hans P, et al. Cochlear implantation after bacterial meningitis in children: outcomes in ossified and nonossified cochleas. **Otol Neurotol** 2011;32:784–9.

[19] MERCHANT SN, Gopen Q. A human temporal bone study of acute bacterial meningogenic labyrinthitis. **Am J Otol** 1996;17:375–85.

4. FINAL CONSIDERATIONS

1. Auditory Category and MUSS tests had no patients in the five successive evaluations and could not be analyzed.
2. No complications were reported in the group of patients studied during the analyzed period.
3. All the information analyzed was collected from the medical records of patients undergoing cochlear implant surgery with short array, therefore, the absence of certain secondary data may limit the evaluations performed.

REFERENCES

- [1] NISHIO, S., USAMI, S. Deafness Gene Variations in a 1120 Nonsyndromic Hearing Loss Cohort : Molecular Epidemiology and Deafness Mutation Spectrum of Patients in Japan. **Annals of Otology, Rhinology & Laryngology**. p. 1-12, 2015.
- [2] CÔTÉ, M. et al. Improving Audiologic Performance with Partial Insertion of a Compressed Array despite Intracochlear Retention Four Electrodes during Revision Cochlear Implant Surgery: A Case Report. **Cochlear Implants International**. 1rd ed. v. 16, p. 57–60, 2015.
- [3] BAUER, P. W.; ROLAND, P. S. Clinical Results with the Med-El Compressed and Split Arrays in the United States. **Laryngoscope**. 3rd ed. v. 114, p. 428–433, 2004.
- [4] ZHANG N, Ruijuan Dong, Jun Zheng, Yanling Zhao, Yongxin Li, Xueqing Chen & Shouqin Zhao (2022) Cochlear implantation for post-meningitis deafness with cochlear ossification: diagnosis and surgical strategy, **Acta Oto Laryngol**, 142:5, 369-374.
- [5] BRITO R, Monteiro TA, Leal AF, Tsuji RK, Pinna MH, Bento RF. Surgical complications in 550 consecutive cochlear implantation. **Braz J Otorhinolaryngol**. 2012 Jun;78(3):80-5.
- [6] COHEN, N. L., WALTZMAN, S.B. Partial insertion of the nucleus multichannel cochlear implant: technique and results. **Am J Otol**. v. 14, p. 357–361, 1993.
- [7] KIRK, K. I. et al. Speech Perception Performance of Nucleus Multichannel Cochlear Implant Users with Partial Electrode Insertions. **Ear and Hearing**. v. 18, p. 456–471, 1997.
- [8] CROGHAN et al. Re-examining the relationship between number of cochlear implant channels and maximal speech intelligibility. **The Journal of the Acoustical Society of America**. 6rd ed. v. 142, 2017.

[9] CASTIQUINI EAT, Bevilacqua MC. Escala de integração auditiva significativa: procedimento adaptado para a avaliação da percepção da fala. **Rev Soc Bras Fonoaudiol.** 2000;6:51-60.

[10] NASCIMENTO LT. Uma proposta de avaliação da linguagem oral [Monografia]. Bauru: Hospital de Pesquisa e Reabilitação de Lesões Lábio-Palatais, 1997.

[11] GEERS A. Techniques for assessing auditory speech perception and lipreading enhancement in young deaf children. **Volta Review.** 1994;96(5):85-96.

[12] BEVILACQUA MC, Delgado EMC, Moret ALM. Estudos de casos clínicos e crianças do Centro Educacional do Deficiente Auditivo (CEDAU) do Hospital de Pesquisa e Reabilitação de Lesões Lábio-Palatais – USP. **Encontro Internacional de Audiologia;** 1996; Bauru (SP).

[13] DELGADO EMC, Bevilacqua MC. Lista de palavras como procedimento de avaliação da percepção dos sons da fala para crianças deficientes auditivas. **Pró-fono Revista de Atualização Científica.** 1999; 11(1): 59-64.

[14] OLIVEIRA ST. Avaliação da percepção de fala utilizando sentenças do dia a dia. [Dissertação]. São Paulo: Pontifícia Universidade Católica de São Paulo; 1992.

[15] LENARZ T, Lesinski-Schiedat A, Weber BP, et al. The nucleus double array cochlear implant: a new concept for the obliterated cochlea. **Otol Neurotol** 2001;22:24–32.

[16] WANG L, Zhang D. Surgical methods and postoperative results of cochlear implantation in 79 cases of ossified cochlea. **Acta Otolaryngol** 2014;134:1219–24.

[17] TOKAT, Catli T, Bayrak F, et al. Cochlear implantation in postmeningitic deafness. **J Craniofac Surg** 2018;29:e245–8.

[18] NICHANI J, Green K, Hans P, et al. Cochlear implantation after bacterial meningitis in children: outcomes in ossified and nonossified cochleas. **Otol Neurotol** 2011;32:784–9.

[19] MERCHANT SN, Gopen Q. A human temporal bone study of acute bacterial meningogenic labyrinthitis. **Am J Otol** 1996;17:375–85.

APPENDIX 1 – Declaration of exclusive use of the article in Dissertation

DECLARATION OF EXCLUSIVE USE OF THE ARTICLE IN DISSERTATION/THESIS

We hereby declare that we are aware of the article "Evolution of speech perception in patients with ossified cochlea and short array cochlear implant" will be included in Dissertation of the student Guilherme Adam Fraga was not used and may not be used in other works of Graduate Programs at the Bauru School of Dentistry, University of São Paulo.


Bauru, May 22nd 2023

Guilherme Adam Fraga
Author



Signature

Rhaissa Heinen Peixoto
Author

 Documento assinado digitalmente
RHAISSA HEINEN PEIXOTO
Data: 22/05/2023 11:13:22 -0300
Verifique em <https://wllstar.it.gov.br>


Signature

Julia Speranza Zabeu
Author



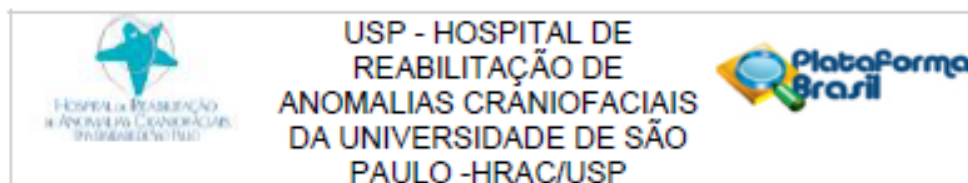
Signature

Luiz Fernando Manzoni Lourençone
Author



Signature

ANNEX A – Approval of the Ethics Committee in Research



PARECER CONSUBSTANCIADO DO CEP

DADOS DO PROJETO DE PESQUISA

Título da Pesquisa: Avaliação da percepção de fala em usuários de implante coclear MED-EL Compressed

Pesquisador: GUILHERME ADAM FRAGA

Área Temática:

Versão: 1

CAAE: 46586921.3.0000.5441

Instituição Proponente: Hospital de Reabilitação de Anomalias Craniofaciais da USP

Patrocinador Principal: Financiamento Próprio

DADOS DO PARECER

Número do Parecer: 4.741.728

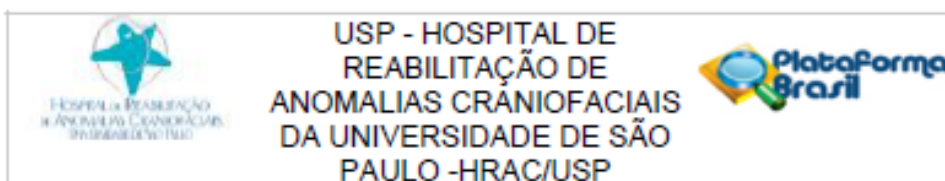
Apresentação do Projeto:

Trata-se da primeira apresentação do projeto de pesquisa intitulado "Avaliação da percepção de fala em usuários de implante coclear MED-EL Compressed", de autoria de Guilherme Adam Fraga, aluno de Prática Profissionalizante em Implante Coclear e Próteses Auditivas do HRAC-USP, sob orientação do Prof Dr Luiz Fernando Manzoni Lourenço tendo, ainda, como equipe de pesquisa a fonoaudióloga Julia Speranza Zabeu Fernandes.

De acordo com o projeto apresentado (arquivo PB_INFORMAÇÕES_BÁSICAS_DO_PROJETO_1742350.pdf, de 09/05/2021 e projeto.docx, de 30/04/2021):

A surdez é a principal desordem sensorial do mundo. Entre as terapêuticas disponíveis, o implante coclear se destaca como possível tratamento de perdas auditivas severas e profundas. Ele está indicado em vários distúrbios que são capazes de produzir surdez severa a profunda, entre elas a ossificação e a malformação coclear. Nessas causas, devido a redução da luz intracoclear, a inserção total dos eletrodos se torna mais difícil. Diante disso, a Med-el Corporation® lançou o eletrodo tipo compressed com o cabo mais curto (15mm), comparado ao cabo standard (31mm). Poucos estudos foram publicados para avaliar o desempenho auditivo e de linguagem nos usuários desse tipo de implante, apresentando resultados

Endereço: Rua Sílvio Marchioni, 3-20
Bairro: Vila Nova Cidade Universitária CEP: 17.012-900
UF: SP Município: BAURURU
Telefone: (14)3235-8421 Fax: (14)3234-7818 E-mail: cephrac@usp.br



Continuação do Parecer: 4.741.728

presente trabalho objetiva relatar a percepção de fala dos usuários de Implante coclear do tipo compressed através da análise retrospectiva de prontuários de pacientes submetidos à cirurgia para Implante coclear, no Hospital de Reabilitação de Anomalias Craniofaciais da USP.

Para tanto, os pesquisadores pretendem realizar uma análise retrospectiva e descritiva de prontuários de todos os pacientes submetidos à cirurgia para implante coclear com eletrodo tipo compressed da Med-El®, no Setor de Implante Coclear do Hospital de Reabilitação de Anomalias Craniofaciais da USP (HRAC/USP), na cidade de Bauru (SP), Brasil. Foi definida uma amostra total de 80 prontuários.

Serão analisados os seguintes dados: Idade, sexo, presença de síndrome/anomalia associada, indicação clínica, idade na implantação, quantidade de eletrodos inseridos, audiometria antes e após cirurgia de implante coclear, testes de percepção de fala pré-cirúrgico e 3, 6, 12, 24 e 60 meses pós-implante coclear. Os testes de percepção de fala que serão descritos são: IT-MAIS, MUSS, categoria de audição e categoria de linguagem em crianças, e sentenças gravadas no silêncio e no ruído em adultos, de acordo com o que foi realizado em cada paciente analisado.

Critérios de Inclusão:

- a) Pacientes com perda auditiva neurossensorial severa ou profunda, que se enquadravam na indicação de implante coclear (pela portaria GM/MS Nº 2.776 do Ministério da Saúde);
- b) Todos os pacientes operados com implante coclear da Med-El®, dispositivo Interno T1100, eletrodo tipo compressed;
- c) Uso do implante coclear por no mínimo um ano após a cirurgia.
- d) Capacidade cognitiva de responder aos exames audiológicos realizados no pré e no pós-operatório.

Critérios de exclusão:

- a) Pacientes com neuropatia auditiva;
- b) Pacientes que não possibilitem avaliação audiológica adequada.

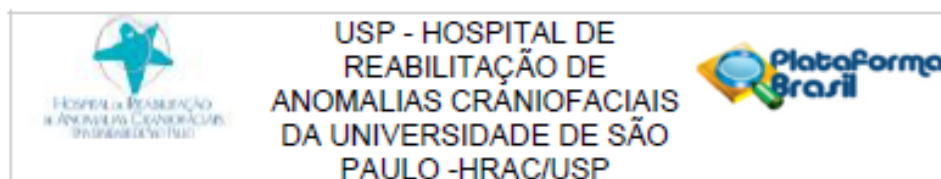
(arquivo projeto.docx, de 30/04/2021)

Objetivo da Pesquisa:

O objetivo do estudo é (arquivo PB_INFORMAÇÕES_BÁSICAS_DO_PROJETO_1742350.pdf, de 09/05/2021 e projeto.docx, de 30/04/2021):

Endereço: Rua Sívio Marchione, 3-20	CEP: 17.012-900
Bairro: Vila Nova Cidade Universitária	
UF: SP	Município: BAURU
Telefone: (14)3235-8421	Fax: (14)3234-7818 E-mail: cephrac@usp.br

Página 02 de 05



Continuação do Parecer: 4.741.728

Analisar a percepção de fala dos usuários de implante coclear eletrodo compressed Med-El®, através da análise retrospectiva de prontuários de pacientes submetidos à cirurgia para implante coclear, no Hospital de Reabilitação de Anomalias Craniofaciais da USP.

Os pesquisadores consideraram a hipótese de que:

A percepção de fala de pacientes usuários de implante coclear com eletrodo Compressed apresenta melhor desempenho com o passar do tempo (arquivo PB_INFORMAÇÕES_BÁSICAS_DO_PROJETO_1742350.pdf, de 09/05/2021).

Avaliação dos Riscos e Benefícios:

Os pesquisadores definiram como riscos:

Os riscos são mínimos por se tratar de uma pesquisa com fontes secundárias de dados. O possível risco seria a quebra de sigilo dos usuários submetidos à análise de prontuário. Em caso de riscos não previstos, a pesquisa será suspensa e a equipe de pesquisa assumirá as responsabilidades.

E como Benefícios:

Descrição do desempenho nos testes de percepção de fala antes e após cirurgia de implante coclear tipo compressed, contribuindo para a adequação na indicação e acompanhamento dos implantes cocleares na instituição, possibilitando planejamento futuro de novas abordagens cirúrgicas.

(arquivo PB_INFORMAÇÕES_BÁSICAS_DO_PROJETO_1742350.pdf)

Comentários e Considerações sobre a Pesquisa:

Pesquisa de caráter retrospectivo que será realizada por meio de análise de prontuários e dados arquivados. Os pesquisadores informaram que serão coletados dos prontuários dados referentes às cirurgias de implante coclear com eletrodos compressed(MED-EL) ocorridos entre janeiro de 2009 e junho de 2021. Os pesquisadores solicitaram dispensa do TCLE.

Considerações sobre os Termos de apresentação obrigatória:

Todos os termos obrigatórios foram apresentados:

Carta de encaminhamento (arquivo carta_de_encaminhamento.pdf, de 30/04/2021)

Formulário HRAC (arquivo formulario.pdf, de 30/04/2021)

Folha de Rosto da Plataforma Brasil (arquivo folha_de_rosto.pdf, de 30/04/2021)

Endereço:	Rua Sílvio Marchione, 3-20	
Bairro:	Vila Nova Cidade Universitária	CEP: 17.012-900
UF:	SP	Município: BALRU
Telefone:	(14)3235-8421	Fax: (14)3234-7818 E-mail: cephrac@usp.br

Página 03 de 05



USP - HOSPITAL DE
REABILITAÇÃO DE
ANOMALIAS CRÂNIOFACIAIS
DA UNIVERSIDADE DE SÃO
PAULO -HRAC/USP



Continuação do Parecer: 4.741.728

Justificativa de Dispensa de TCLE (arquivo dispensa_tcle.pdf, de 30/04/2021)

Termo de Compromisso, Confidencialidade e Autorização de Utilização de Dados em Projetos de Pesquisa (arquivo termo_confidencialidade.pdf, de 30/04/2021)

Termo de Compromisso de Tornar Públicos os Resultados da Pesquisa e Destinação de Materiais ou Dados Coletados (arquivo termo_compromisso.pdf, de 30/04/2021)

Termo de Compromisso do Pesquisador Responsável (arquivo termo_pesquisador.pdf, de 30/04/2021)

Recomendações:

Não há.

Conclusões ou Pendências e Lista de Inadequações:

Considerando que o projeto apresentado não apresenta infrações éticas que impossibilitem sua realização, sugiro ao CEP a aprovação do projeto.

Considerações Finais a critério do CEP:

O pesquisador deve atentar que o projeto de pesquisa aprovado por este CEP refere-se ao protocolo submetido para avaliação. Portanto, conforme a Resolução CNS 466/12, o pesquisador é responsável por "desenvolver o projeto conforme delineado", se caso houver alterações nesse projeto, este CEP deverá ser comunicado em emenda via Plataforma Brasil, para nova avaliação.

Cabe ao pesquisador notificar via Plataforma Brasil o relatório final para avaliação. Os Termos de Consentimento Livre e Esclarecidos e/ou outros Termos obrigatórios assinados pelos participantes da pesquisa deverão ser entregues ao CEP. Os relatórios semestrais devem ser notificados quando solicitados no parecer.

Este parecer foi elaborado baseado nos documentos abaixo relacionados:

Tipo Documento	Arquivo	Postagem	Autor	Situação
Informações Básicas do Projeto	PB_INFORMAÇÕES_BÁSICAS_DO_PROJETO_1742350.pdf	09/05/2021 11:25:38		Acelto
Outros	termo_pesquisador.pdf	30/04/2021 19:03:55	GUILHERME ADAM FRAGA	Acelto
Outros	termo_confidencialidade.pdf	30/04/2021 19:02:45	GUILHERME ADAM FRAGA	Acelto
Outros	termo_compromisso.pdf	30/04/2021 19:02:25	GUILHERME ADAM FRAGA	Acelto

Endereço: Rua Sílvio Marchioni, 3-20
Bairro: Vila Nova Cidade Universitária CEP: 17.012-900
UF: SP Município: BAURUR
Telefone: (14)3235-8421 Fax: (14)3234-7818 E-mail: cephrac@usp.br



USP - HOSPITAL DE
REABILITAÇÃO DE
ANOMALIAS CRÂNIOFACIAIS
DA UNIVERSIDADE DE SÃO
PAULO -HRAC/USP



Continuação do Parecer: 4.741.726

TCLE / Termos de Assentimento / Justificativa de Ausência	dispensa_tcie.pdf	30/04/2021 19:00:30	GUILHERME ADAM FRAGA	Aceito
Projeto Detalhado / Brochura Investigador	projeto.docx	30/04/2021 19:00:10	GUILHERME ADAM FRAGA	Aceito
Declaração de Instituição e Infraestrutura	formulario.pdf	30/04/2021 18:57:55	GUILHERME ADAM FRAGA	Aceito
Outros	carta_de_encaminhamento.pdf	30/04/2021 18:57:17	GUILHERME ADAM FRAGA	Aceito
Folha de Rosto	folha_de_rosto.pdf	30/04/2021 18:56:43	GUILHERME ADAM FRAGA	Aceito

Situação do Parecer:

Aprovado

Necessita Apreciação da CONEP:

Não

BAURU, 28 de Maio de 2021

Assinado por:
Renata Paciello Yamashita
(Coordenador(a))

Endereço: Rua Sílvio Marchioni, 3-20
Bairro: Vila Nova Cidade Universitária CEP: 17.012-900
UF: SP Município: BAURU
Telefone: (14)3235-8421 Fax: (14)3234-7818 E-mail: cephrac@usp.br

Página 05 de 05