

# Non-secretory Multiple Myeloma with Extramedullary Plasmocytoma : A Case Report

Abed Hussain Khan<sup>1</sup>, Rafia Afrose<sup>2</sup>, Mujahida Rahman<sup>3</sup>, Mohammad Ferdous Ur Rahaman<sup>4</sup>, Md. Shahabul Huda Chowdhury<sup>5</sup>, MA Jalil Chowdhury<sup>6</sup>.

<sup>1</sup>Medical Officer, Department of Medicine, BSMMU, <sup>2</sup> Medical Officer, Dhaka Dental college Hospital, Dhaka, <sup>3</sup>Medical Officer, Department of Haematology, BSMMU, <sup>4</sup>Assistant Professor, Department of Medicine, BSMMU, <sup>5</sup> MD Resident, Phase-B (Internal Medicine), BSMMU, <sup>6</sup> Professor, Department of Medicine, BSMMU.

## Abstract:

Non-secretory multiple myeloma (NSMM) is an uncommon variation of the classic form of multiple myeloma (MM) that has an analogous clinical and radiologic presentation except for the absence of the M-protein in serum and/or urine. NSMM may have or not detectable monoclonal free light chain in urine/serum. We describe here a case of a 46-year-old woman who presented with back pain and lower limb weakness. A tumour lesion at D1 level and multiple osteolytic bone lesions were found. This woman had no other symptoms and her basic blood biochemistry were normal. She had normal serum and urine protein electrophoresis. Biopsy from the D1 vertebra showed plasmocytoma. In the bone marrow, 20% atypical plasma cell found, all were being CD38+ and CD138+ in flowcytometry, confirming the diagnosis of myeloma presenting as NSMM. A high index of suspicion is needed to diagnose cases like this, as the biology of NSMM is not completely understood.

**Keywords:** Multiple Myeloma, Extramedullary plasmocytoma, Non-secretory Multiple Myeloma.

[BSMMU J 2013; 6 (1): 66-68]

## Introduction:

Multiple myeloma (MM) is a neoplasia of plasma cells (PCs), of the bone marrow (BM) and production of monoclonal immunoglobulin (Ig) detectable in serum and/or urine. At present, it accounts for 2% of all cancer deaths and nearly 20% of deaths caused by hematological malignancies in the United States. Non-secretory multiple myeloma (NSMM) is a rare clinical and biological variant of the classic form of MM characterized by the absence of monoclonal immunoglobulins in either serum or urine electrophoresis and represents less than 1% of this spectrum<sup>1</sup>. The first case of this variant was described in 1958<sup>2</sup>.

While some authors consider NSMM as an entity that secretes neither entire immunoglobulins nor immunoglobulin light chains<sup>2,3,4</sup>. Others assume that all the ones that do not have the M-protein in electrophoresis can be classified as NSMM, in spite of having small elevations of

monoclonal free light chains in serum and/or urine<sup>5-8</sup> by using techniques other than agarose gel electrophoresis, like immunoelectrophoresis or immunofixation<sup>6,8</sup>.

Less than 5% of patients with a plasma cell dyscrasia present with a single bone (SBP) or extramedullary plasmocytoma (EMP) due to a malignant plasma cell infiltrate without evidence of systemic disease (normocalcemia, absence of anemia, preservation of uninvolved immunoglobulins, or renal disease attributable to myeloma). Diagnosis requires biopsy confirmation of a monoclonal plasma cell infiltrate from a single site.

We present here a case of NSMM with a single bone or extramedullary plasmocytoma without the M-protein spike, clinically presenting as spinal cord compression.

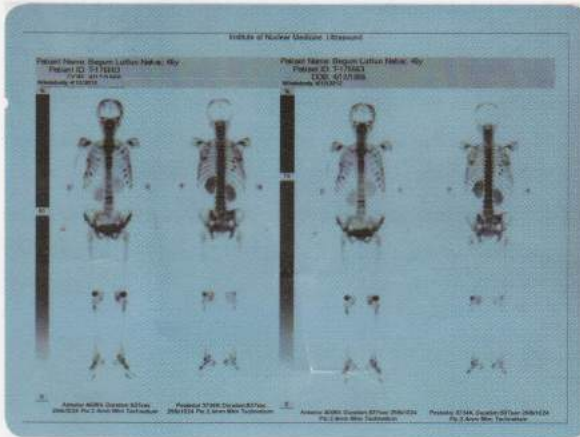
## Case Report:

A 46-year-old woman was admitted in Bangabandhu Sheikh Mujib Medical University (BSMMU) on 29.03.2012 with the complaints of back pain which was at first appeared at cervical region then lumber region

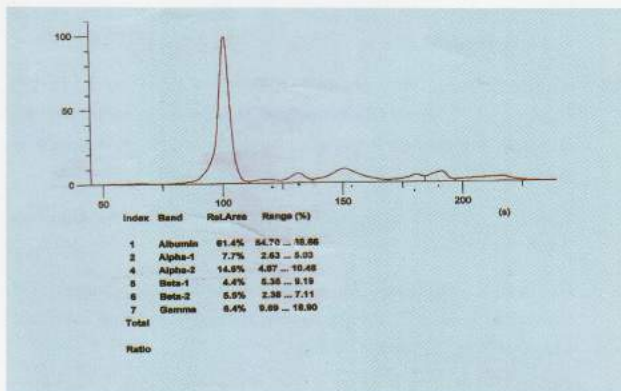
---

**Address of correspondence: Dr. Abed Hussain Khan**  
Medical Officer, Department of Medicine, BSMMU  
Mobile No: 01911483331

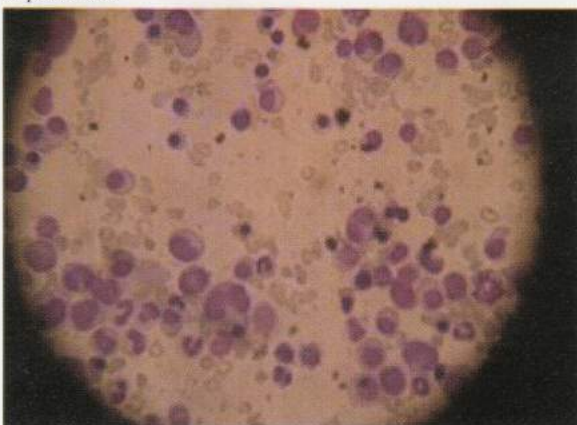
radiating towards arms and thighs. It was mechanical in nature and subsided by taking rest and supportive medication. She also complained of weakness in both lower limbs for last 1 month with normal bowel and bladder activity. On examination patient was mildly anaemic, no lymphadenopathy but bony tenderness present, no organomegaly.



**Fig-1:** Bone Scintigraphy finding→ Focal increase uptake of Radio tracer is seen in→ Multiple ribs on both sides, multiple Vertebra, Both pelvic Bones, Rt. sacroiliac joint (Showing lytic change)



**Fig-2:** Serum protein electrophoresis non-specific with normal immunodisplacement



**Fig-3:** Bone marrow Study Shows Significant increase plasma cells (about 20%) with fair number of Bi-nucleated immature forms, plasmacytoid lymphocytes are also seen.

lanter reflex-extensor, deep tendon reflexes of lower limb were exaggerated; muscle power was 3/5 in lower limbs. Joint movement of both lower limb restricted with grade 2/4 tenderness. Upper limbs were normal. Hematological profile: Hemoglobin -10.2 gm/dl, ESR-110 mm in 1st hour, Total leucocyte count-  $6.5 \times 10^9$  /L, Platelet count -  $80 \times 10^9$  /L, PBF Shows - Bi-cytopenia with Anisocytosis & Anisocromia. Fasting plasma glucose-7.6mmol/l, plasma glucose 2 hours after 75gm glucose load -8.8mmol/l, serum urea 30 mg/dl, serum calcium - 8.8mg/dl, serum creatinine -1.1 mg/dl. Serum uric acid-5.9 mg/dl, serum albumin- 25gm/L, RA test -negative. Serum LDH -514 U/l,  $\beta 2$  microglobulin-8.7  $\mu$ gm/ml. Urine Bence Jones protein was absent. X-ray skull B/V- multiple lytic lesion of variable size is noted in the frontal, parietal & occipital region and the body of the mandible, suggestive of Multiple Myeloma. Common tumor markers such as CA15-3, CA 19-9, CA 125, and CEA were negative. Bone scintigraphy showed focal increase uptake of radio tracer in multiple ribs, multiple vertebra, both pelvic bones, right sacroiliac joint suggestive of Metastasis (Figure 1). Serum protein electrophoresis non-specific with normal immunodisplacement (Figure 2). Bone marrow study shows significant increase plasma cell (about 20%) with fair number of binucleated immature forms, plasmacytoid lymphocytes are also seen. Features were suggestive of lymphoplasmacytic disorder-Probably plasma cell Dyscrasia (Figure 3). Flow cytometric analysis reveals a small population (7% of total )of atypical cells which were positive for CD38 & CD138 but were negative for CD 45 & B lymphoid markers .Of the remaining cells 55% are granular myeloid cells, 35% are lymphoid &3% erythroid. MRI of dorso lumbar spine reveled expansile bony lesion involving the posterior element of D1 vertebra resulting spinal canal stenosis & compression over the spinal cord. Decompression & excision of tumor was done at level of 1st thoracic spine. Histopathology showed dense collection of immature plasma cell (Plasma cell Tumor).

**Discussion:**

Non-secretory multiple myeloma (NSMM) is a rare variant of the classic form of MM that has a similar clinical and radiologic presentation except for the absence of the M-protein in serum and/or urine.

In this particular case, our patient presented with spinal plasmocytoma and osteolytic bone lesions associated

with pain and lower limb weakness, with no other systemic symptoms or alteration on serum basic analysis, including normal serum protein electrophoresis and negative tumor markers. The diagnosis of multiple myeloma relied on the result of the bone marrow biopsy, which showed a predominant population of atypical plasmacytes, and the increased uptake on the bone scan, multiple lytic lesions in x-ray skull and ribs. Excision and biopsy of spinal tumour at D1 level shows plasma cell tumour. With further studies we found small population of plasmacytes is positive for CD38 and CD138 in flow cytometric analysis, but there was no M-protein in plasma protein electrophoresis. This led us to classify this myeloma as non-secretory.

There are studies showing that a cytoplasmic M-protein can be identified by immunohistochemistry in nearly 85% of these patients initially classified as NSMM: with increasing sensitivity of detection of M-protein, the diagnosis of true NSMM is decreasing<sup>3,6</sup>. This is especially true with the introduction of immunoglobulin free light chain assays that are capable of detecting small elevations in monoclonal free light chains, which would otherwise have escaped detection by agarose gel electrophoresis and immunoelectrophoresis<sup>3,6,9</sup>. It's possible that this is what happened in this particular case. Initially, we detected no M-protein in serum. Electrophoresis was normal. It is possible that by using more sensitive techniques we would have detected an M-protein spike earlier, diagnosing the disease earlier.

Less than one-quarter of patients with extramedullary plasmacytoma have evidence of a low level of monoclonal protein in serum or urine by electrophoresis and/or immunofixation, and we require normal levels of uninvolved immunoglobulins to confirm the absence of occult disease elsewhere<sup>10</sup>. Although current experience is minimal, free-light chain assays should also prove useful in monitoring such patients, particularly those classified with non-secretory features

With cases like this we conclude that in patients with symptoms, signs and radiologic findings (including bone scan) typical of MM but with no M-protein in plasma protein electrophoresis and/or absent urinary Bence Jones protein, the hypothesis of NSMM should always be considered. Besides marrow aspiration and biopsy, more advanced techniques like immunoelectrophoresis or immunofixation may be necessary to confirm the diagnosis<sup>8</sup>. The quantification of free light chains in serum

is probably also useful for the diagnosis and monitoring of many patients with non-secretory myeloma<sup>6</sup>. Observation of the affected cells by electron microscopy may also be useful for the identification of cell lineage and more accurate diagnosis of NSMM, identifying well-developed rough endoplasmic reticulum, a clear Golgi apparatus and cytoplasmic phagocytic vacuoles<sup>7</sup>.

The treatment of secretory and non-secretory MM is similar, and the prognosis is also identical.<sup>2,3,9,11</sup> Studies are now necessary to better understand the etiology, pathogenesis and evolution of this disorder, since its adequate treatment relies on the full understanding of its pathologic mechanisms.

#### References:

1. Bosman C, Fusilli S, Bisceglia M, Musto P, Corsi A. Oncocytic nonsecretory multiple myeloma. A clinicopathologic study of a case and review of the literature. *Acta Haematol* 1996;96:50-56
2. Gray ST, Antunovic DM, White AE. Non-secretory multiple myeloma involving the Maxilla: Report of a case with update of biology and new approaches to management. *Oral Oncol* 1997;33:136-40
3. Kumar S, Perez WS, Zhang MJ, Ballen K, Bashey A, To LB, Bredeson CN, et al. Comparable outcomes in nonsecretory and secretory multiple myeloma after autologous stem cell transplantation. *Biol Blood Marrow Transplant* 2008; 14(10):1134-1140
4. Kyle RA. Multiple myeloma: review of 869 cases. *Mayo Clin Proc* 1975; 50(1):29-40
5. Rubio-Felix D, Giralto M, Giraldo MP, Martinez-Penuela JM, Oyarzabal F, Sala F, Raichs A. Nonsecretory multiple myeloma. *Cancer* 1987; 59(10):1847-1852
6. Drayson M, Tang LX, Drew R, Mead GP, Carr-Smith H, Bradwell AR. Serum free light-chain measurements for identifying and monitoring patients with nonsecretory multiple myeloma. *Blood* 2001; 97(9):2900-2902
7. Kuyama J, Kosugi S, Take H, Matsuyama T, Kanayama Y. Non-secretory multiple myeloma with azurophilic granules and vacuoles: an immunological and ultrastructural study. *Intern Med* 2004; 43(7):590-594
8. Sheehan T, Sinclair D, Tansey P, O'Donnell JR. Demonstration of serum monoclonal immunoglobulin in a case of non-secretory myeloma by immunoelectric focusing. *J Clin Pathol* 1985; 38(7):806-809
9. Bourantas K. Nonsecretory multiple myeloma. *Eur J Haematol* 1996; 56(1-2):109-111
10. Lieboss RH, Ita CS, Cox JD, et al. Clinical Course of extramedullary plasmacytoma. *Radiother Oncol*. 1999; 52:245-249
11. Smith DB, Harris M, Gowland E, Chang J, Scarffe JH. Non-secretory multiple myeloma: a report of 13 cases with a review of the literature. *Hematol Oncol* 1986; 4(4):307-313