

Management of Tooth Resorption by Using Calcium Hydroxide: A Case Report

Shirin Sultana Chowdhury¹, Md. Shamsul Alam²

¹Assistant Professor, Department of Conservative Dentistry & Endodontics, Update Dental College & Hospital, Bangladesh, ² Professor and Chairman, Department of Conservative Dentistry and Endodontics, Faculty of Dentistry, BSMMU, Bangladesh

Abstract:

In this case report, the treatment of internal root resorption in a 24 years-old male was done by using non-surgical root canal therapy and the clinical outcome was evaluated. Both the maxillary central incisors were examined clinico-radiographically. On clinical examination, the maxillary incisors were found discolored. Radiographic examination revealed a punched-out radiolucent lesion on the cervical area of pulpal canal of both of the teeth and periradicular radiolucency was also evident. Conservative non-surgical root canal treatment was performed with long term calcium-hydroxide therapy. Following eight months of the treatment, the resorption process was stopped and a calcific bridge was formed at the apex of the roots indicated the evidence of recalcification. Conventional root canal obturation method was implied followed by clinical and radiological evaluation for next two years.

Key words: Resorption, Ca(OH)₂, Recalcification.

[BSMMU J 2012; 5(1):72-75]

Introduction:

Resorption of root is one of the reasons for loss of the tooth at an early age and it is a major concern in endodontic therapy.¹ The enamel, dentine and cementum of permanent teeth do not normally undergo resorption.² When resorption of permanent teeth is observed clinically, the resorption is usually due to the result of trauma; chronic inflammation of the pulp or periodontal tissues, or both; or induced pressure in the periodontal ligament associated with orthodontic tooth movement, tumors, or tooth eruption.³

Pulpal inflammation initiates internal resorption followed by disappearance of the odontoblasts and pre-dentin, and a pulpal invasion of macrophage-like resorbing cells.^{4,5} The signs and symptoms of this pathologic condition remain asymptomatic unless it is detected on radiographic screening. Frequently, it is observed in the cervical region but may occur in all areas of the root canal system.³ When the resorption occurs in coronal region it is usually appears as pink spot. The reason is that the prolific capillaries in the pulpal inflammatory (granulomatous) tissue resorbing the coronal dentin and enamel.⁶ In external resorption, a change in the natural balance between osteoblastic and osteoclastic action in the periodontal ligament occurs which removes dentine from the root surface. This process

of tooth resorption involves an elaborate interaction among inflammatory cells, resorbing cells, and hard tissue structures.⁷

In the cases of tooth trauma, the internal pulpal hemorrhage can develop. Formed blood clots are then organized and replaced by granulation tissue which compresses dentin wall of the pulpal chamber or root canal. With activation of undifferentiated mesenchymal cells of the pulpal tissue they differentiate into dentinoclasts, which is said to be responsible for resorption of the hard tooth structure⁸. Furthermore, the chronic trauma or inflammation can be the cause of transformation of undifferentiated cells of connective pulpal tissue into giant multinuclear cells which are responsible for the resorption process.⁹⁻¹¹

If root resorption remains untreated, it usually leads to perforation of the tooth root followed by tooth fracture¹. Surgical correction and filling of the communication with restorative materials has been suggested in cases of large defects.¹² However, successful correction of resorptive tooth through non-surgical intervention has been well reported.¹³⁻¹⁵ The procedure included tooth trepanation, the removal of residual vital pulp tissue and newly developed granular tissue and application of either Calcium hydroxide (Ca(OH)₂), Mineral Trioxide Aggregate (MTA), calcium phosphate cement (CPA) or hydroxyapatite.¹

In this case study, internal root resorption in a 24 years male was treated by non-surgical root canal therapy and the clinical as well as radiological outcome was evaluated.

Address for Correspondence: Dr. Shirin Sultana Chowdhury, Assistant Professor, Department of Conservative Dentistry & Endodontics, Update Dental College & Hospital, Bangladesh




Fig. -1: Pretreatment intraoral photograph (a) shows extruded left lateral incisor tooth, and intra-oral periapical radiograph (b) shows sign of periapical & pulpal pathology. Determination of working length (c) of the same tooth by intra-oral periapical radiograph.

Case report:

A 24 years old patient reported to the Dept. of Conservative Dentistry and Endodontics, BSMMU with the complaint of intermittent pus discharge through labial mucosa of maxillary incisors for last two years. The patient gave the history of trauma five years back. The patient felt no significant pain during the whole period but gave the history of occasional swelling and release of exudates on pressure. Slight discoloration of the affected teeth was noticed during clinical examination but no pink spot was identified. However, the left central incisor was extruded 1mm in relation to the right one [Figure-1(a)]. A sign of sinus tract through the periodontal pocket of right maxillary incisor was present. There was mild pain on percussion on both of the teeth.

Pulp vitality tests, ethyl chloride spray for cold sensation and warm gutta percha stick for hot sensation, were negative. Radiographic findings revealed that an oval shaped enlargement of root canal space having a smooth

margin where pulp chamber was more radiolucent than other non-resorptive area of the pulp canal. In the apical area there was radiolucency and irregular root outline especially at the right maxillary central incisor revealed external root resorption along with bone resorption [Figure-1(b)].

The initial treatment plan included the removal of all necrotic tissues and microorganisms by vigorous cleaning by using 5.25% sodium hypochlorite solution and shaping of the canals after, determining the working length [Figure-1(c)]. Then the canals were fully prepared with 60 number of H-file and the canal made dry. Then it was filled with radio-opaque $\text{Ca}(\text{OH})_2$ up to apical region by lentulo spiral instrument [Figure-2(d)]. During follow up after three months the patient had no complain of discharge of exudates [Figure-2(e)] and the same was evident at six months follow-up period [Figure-2(f)].

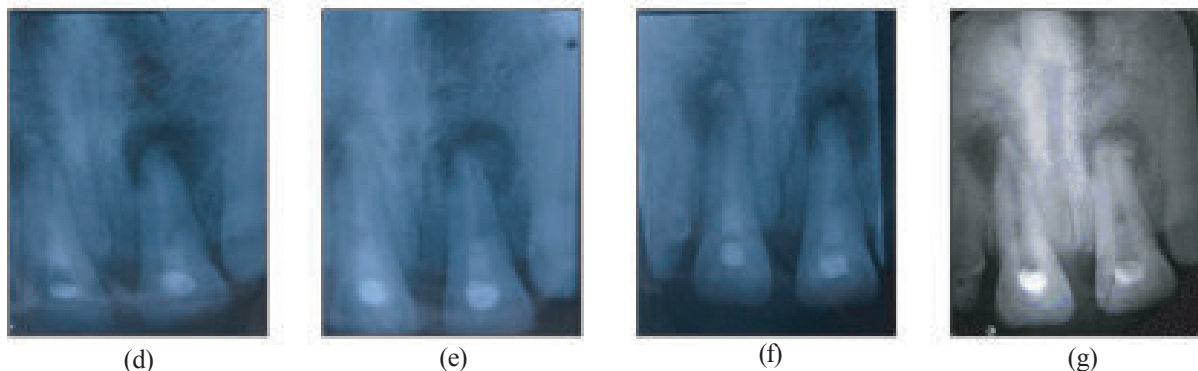


Fig.-2: Follow up radiographic view of that teeth, just after application of $\text{Ca}(\text{OH})_2$ (d), at 3 months interval (e), at 6 months interval (f), & at 8 months interval (g).

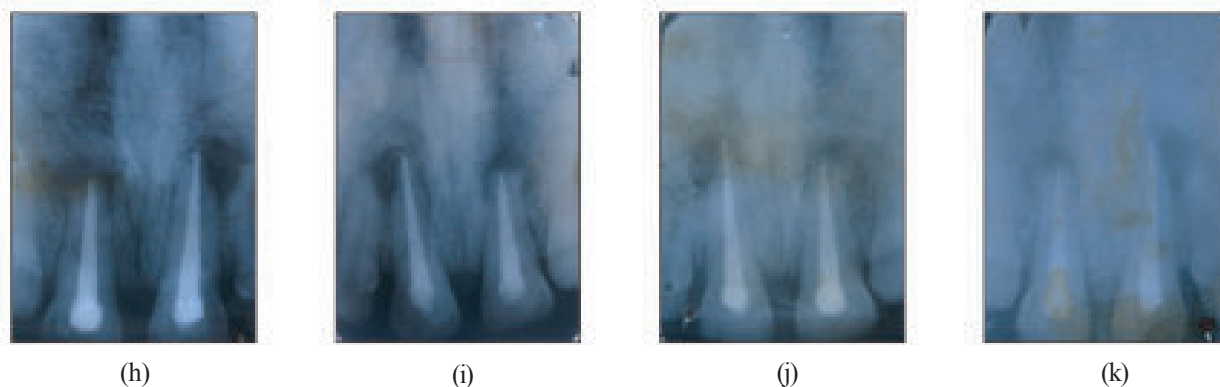


Fig. -3: Follow up radiographic view of the same teeth just after root canal obturation (h), at 6 months interval (i), at 12 months interval (j) and at 24 months interval (k).

A new dressing of $\text{Ca}(\text{OH})_2$ was reapplied every one month interval till the cessation of resorption and evidence of remineralization both clinically and radiologically. After eight months, radiographic evidence showed no extension of resorption both internal and external [Figure-2(g)] and, therefore, the root canal treatment was completed with lateral condensation technique [Figure-3(h)] where zinc oxide eugenol was used as sealer. The resorption condition remained static in the periradicular region at six months follow-up visit [Figure-3(i)]. The patient was recalled for radiographic evaluation after one [Figure-3(j)] and two [Figure-3(k)] years and reduction of periapical radiolucency indicated reparative procedure of apical bone regeneration.

Discussion:

In the present study, $\text{Ca}(\text{OH})_2$ in paste form was applied with the help of lentulo-spiral instrument after complete debridement of the canals. At six months of $\text{Ca}(\text{OH})_2$ application there was no evidence of further resorption and calcific bridge was formed at eight months. $\text{Ca}(\text{OH})_2$ worked by its high alkaline pH to create an antibacterial environment and it also causes irritation to the surrounding tissues that had stimulated pulpal defense and repair.¹⁶ The periradicular area, where the $\text{Ca}(\text{OH})_2$ paste can cause stimulatory effect on the undifferentiated mesenchymal cells to transform into cementoblasts.^{17,18} The cementoblasts and periodontal ligaments slowly resurface the damaged root and even closed minor foramina that no longer contain neurovascular bundles.¹⁸ In the follow-up visits up to three years, no radiographic and clinical evidence of further root resorption was observed and the teeth were in function.

Many previous studies have reported that internal resorption can be managed by non-surgical and surgical methods. Ingle et al. and others made a case for the wider use of $\text{Ca}(\text{OH})_2$ as a stimulating and healing agent.¹ Now-a-days these thoughts become a reality i.e. $\text{Ca}(\text{OH})_2$ is frequently being used as an apical plug before total obturation.¹⁹⁻²¹

The advantages of $\text{Ca}(\text{OH})_2$ include elimination of surviving bacteria when used as intracanal medicament²² and arresting inflammatory root resorption as well as stimulation of healing in treating resorption.²³

In the present study, the mechanism of $\text{Ca}(\text{OH})_2$ to heal internal resorption is not clearly understood. However previous studies indicated that the hydroxyl group of $\text{Ca}(\text{OH})_2$ provides an alkaline environment which encourages repair and active calcification. The alkaline pH neutralizes lactic acid that is released from the osteoclasts and thus prevent a dissolution of the mineral components of dentine. Additionally, alkaline pH activates alkaline phosphatase for tissue formation.²³ Following well-executed treatment, wherein infection and irritation are terminated, cementoblasts and periodontal ligament slowly resurfaced the damaged root and close the minor foramina²⁴ which in turn provides protection against further infection.

Based on the present study and together with the previous studies, it can be stated that the teeth were saved successfully only by non-surgical endodontic treatment.

References

1. Ingle, JI; Bakland, LK and Banumgartner, JC. Pathologic tooth resorption. Ingle's Endodontics 6th edition, Ontario, BC Decker inc.; 2008.
2. Carrotte, P. Endodontics: Part 9 Calcium hydroxide, root resorption, endo-perio lesions. *British Dental Journal* 2004; 197: 735-743.

3. Maurice N, Gunraj MN. Dental root resorption, *Oral Surg Oral Med Oral Pathol Oral Radiol Endod* 1999;88:647-53
4. Wedenberg C, Lindskoj S. Experimental internal resorption in monkey teeth. *Endod it can be stated that Traumatol* 1985;1:221-7.
5. Pindborg JJ, editor. *Pathology of the dental hard tissues*. Copenhagen: Munksgaard; 1970.
6. Heithersay GS. Clinical endodontic and surgical management of tooth and associated bone resorption. *Int Endod J* 1985;18:72-92.
7. Witherspoon, DE and Gutmann JL. Tooth resorption. *Quint Int* 1999; 30 (1): 9-25.
8. Andreasen JO, Andereasen FM. *Textbook and color atlas of traumatic injuries of teeth*. 3rd Edi. Copenhagen ; Munskgaard; 1994.
9. James VS, Englander HR, Massler M. Histologic response of amputated pulps to calcium compounds and antibiotics. *Oral Surg*. 1957;10:1975
10. Nyborg H. Healing process in the pulp on capping. *Acta Scand*. 1955;13, Suppl. 16:9-130.
11. Kalnins V, Frisbie HE. The effect of dentine fragments on the healing of exposed pulp. *Arch Oral Biol*, 1960;2:96
12. Fuss Z, Tsesis I, Lin S. Root resorption— diagnosis, classification and treatment choices based on stimulation factors. *Dent Traumatol* 2003;19:175-82
13. Sadd Y. Calcium hydroxide in treatment of external root resorption. *JADA* 1989;118: 579-581.
14. Attala MN, Noujain Aa. Role of calcium hydroxide information of reparative dentin. *Can Dent Assoc* 1969; 35: 267-268
15. Oktem ZB, Cetinba^o T, Ozer L, Sönmez H. Treatment of aggressive external root resorption with calcium hydroxide medicaments: a case report. *Dent Traumatol*. 2009;25(5):527-31.
16. Cox CF, Subay RK, Ostro E, Suzuki S, Suzuki SH. Tunnel defects in dentine bridges: their formation following direct pulp capping. *Oper Dent* 1996; 21(1): 4-11
17. Binnie WH, Rowe AH. A histological study of the periapical tissue of incompletely formed pulpless teeth filled with calcium hydroxide. *J Dent Res* 1973; 52: 1110
18. Cvek M. Treatment of non-vital permanent incisors with calcium hydroxide. IV. Periodontal Healing and closure of the root canal in the coronal fragment of the teeth with intraalveolar fracture and vital apical fragment. A follow-up. *Odontol Revy* 1974; 25: 239
19. Coolidge ED, Kesl RG. *Endodontology*, 2nd ed. Philadelphia: Lea & Febiger; 1956.
20. Laws A. Calcium hydroxide as a possible root filling material. *N.Z. Dent. J.*, 1962;58:199-215
21. Cvek J. Treatment of non-vital permanent incisors with calcium hydroxide. I. Follow-up of periradicular repair and apical closure of immature roots. *Odont Rev*. 1972;23:27
22. Zvi Fuss, Igor Tsesis, Shaul Lin: Root resorption- diagnosis, classification and treatment choices based on stimulation factors. *Dental Traumatol* 2003;19:175-182.
23. Tronstad L. Root resorption: etiology, terminology and clinical manifestations. *Endod Dent Traumatol* 1988;4:241-52. Apical closure of immature roots. *Odont Rev*. 1972;23:27
24. Studat GS, Katunaric M, Ivic-Kardum M. Internal Root Resorption, Therapy and Filling *Acta Stomatol Croat* 2000; 34 (4):431