



Comparison between Intravitreal Injection of Ranibizumab and Bevacizumab as Preoperative Measure for Diabetic Vitrectomy

Mohammed A. Omar, Abdallah M. Elamin, Sherif A. Dabour, Ahmed A. Elbarawy

Department Ophthalmology, Faculty of Medicine, Aswan University, Aswan, Egypt

Corresponding Authos E-mail: ophthalmology1977@gmail .com

Article History	Abstract
Received: 17 June 2023 Revised: 01 Sept 2023 Accepted: 10 October 2023	<p>Purpose :In order to examine the parameters of surgical operation between intravitreal bevacizumab and ranibizumab as adjuvant therapy before pars plana vitrectomy in proliferative diabetic retinopathy. Patients & methods:A randomized clinical study on 68 eyes, the patients are classified into two groups, group A (n = 34), and group B (n =34), both groups injected by anti-vascular endothelial growth factor before vitrectomy operation, group A injected by Bevacizumab and group B injected by Ranibizumab, the duration between injection and the operation was 3-6 days, the basic data of each patient include vision, type of DM, duration of DM, level of HbA1c, during the operation we record the following parameters diathermy application number, breaks, bleeding, bottle height, and type of tamponade. Results :The mean BCVA was improved from base line to post- operative in both groups without statistically difference between the groups p value =0.231, diathermy application was one application in 30.3% in group A and 32.4% in group B, and two applications in 15.2% in group A and 2.9% in group B. break was one break in 23.5% in group A and 20.6% in group B. two breaks in 2.9% in each group. Bleeding was in 16 cases in group A and 17 cases in group B. tamponade was silicon in 58.8% in group A and 52.9% in group B, fluid tamponade was 38.3% in group A and 44.2% in group B, air tamponade was one case in each group. without statistical difference between groups. Conclusion :When administered preoperatively during a diabetic vitrectomy procedure, there is no difference between bevacizumab and ranibizumab.</p>
CC License CC-BY-NC-SA 4.0	Keywords : Diabetic vitrectomy, proliferative diabetic retinopathy, Ranibizumab, Bevacizumab.

1. Introduction

One of the most common major problems all over the world is the complication of DM in the form of diabetic retinopathy, which affects the vision by proliferation of neovessels, which complicated by vitreous haemorrhage and tractional retinal detachment. (1) The stages of diabetic retinopathy can be classified into non- proliferative and proliferative which complicated by vitreous haemorrhage, fibrosis, traction, and development of tractional retinal detachment. (2)

The era of intravitreal injection of pharmacologic agents, especially the drugs that act on the endothelial growth factor (VEGF) by blocking its receptors, have changed the aim of management of diabetic retinopathy to improvement than stabilization. (3) The principal regulator of angiogenesis and vascular permeability in the eye for both pathologic and physiological processes is vascular endothelial growth factor (VEGF)-A. (4)

Bevacizumab is an inhibitor of the VEGF, so act as antiangiogenic, its Molecular weight about 149 kDa.(5) Ranibizumab one of the anti-VEGFs, its molecular weight about 48 kDa, act by decreasing the neovascularization after its injection intravitreally. (6)

Advanced proliferative retinopathy is characterised by tractional retinal detachment, vitreous haemorrhage, and fibrovascular growth. (7) The most appropriate decision for management modality

depends on the staging of the disease and identification of high-risk criteria of PDR. (8) The Advanced stage of diabetic retinopathy usually requires management with diabetic vitrectomy.(9)

The management of refractory diabetic macular edema (DME) by Pars plana vitrectomy leading to good and significant improvement in both vision and anatomy of the macula. (10)

The standard surgical manouvre of diabetic vitrectomy was used 20-gauge or 23-gauge, to visualize the posterior pole good and adequate removal of the hemorrhage from the vitreous cavity, the modified en bloc technique used for removal of the fibrovascular proliferative tissue, at first PVD induction by elevation the posterior hyaloids, good and careful removal of the vitreous by shaving from the retinal surface, these steps aided by good wide angle visualizaion system, any area of previously untreated by PRP need more panretinal endolaser photocoagulation (PRP) , give attention for good relieving of traction, stopping of bleeding by endodiathermy and endolaser. (11)

Patients and methods

A prospective randomized study was done on patients with DR (both type I diabetes and type II diabetes) undergoing diabetic vitrectomy after approval from the Ethical and Technical Review Committee of Aswan faculty of medicine. Informed written consents were taken from all patients for the specific procedure After the approval from the Institutional Research Board (444-3-20) was taken, the study was carried out following the tenets of the Declaration of Helsinki. Before each procedure in the study, written informed consent was obtained from each participant.

Inclusion criteria:

Patients with: -

- (1) Patients with Diabetic Vitreous hemorrhage of duration more than 3 months.
- (2) Tractional retinal detachment involving the macula or threatening the macula.
- (3) Combined tractional retinal and rhegmatogenous detachment.
- (4) Persistant premacular hemorrhage.
- (5) Combination of the above with associated reduced visual acuity.

Exclusion criteria:

- (1) Dense fibrovascular proliferative membranes.
- (2) History of ocular inflammatory disease.
- (3) Patients with other intra ocular diseases that may have affect the vitreoretinal surgery, such as uveitis, traumatic retinal detachment, and congenital vitreoretinopathies.
- (4) Acute intraocular infection.
- (5) Severe recent intra ocular trauma.
- (6) Glycosylated haemoglobin more than 13%.
- (7) VH for reasons other than PDR (e.g., sickle cell, retinal vein occlusion).

Groups of the study: -

Group (A) in which patients received intravitreal Bevacizumab (Avastin) 1.25 mg/0.05ml injection, and group (B) in which patients received intravitreal Ranibizumab (Lucentis) 0.26 mg/0.05ml injection.

Preoperative evaluation: -

General:

As the patient for diabetic vitrectomy could be ill before or after the surgery, careful review by the internist and anesthesia team is required before the decision to proceed to surgery is taken.

Preoperative data at the time of primary surgery included age; sex; status of diabetes mellitus (HbA1C); history of other systemic diseases such as hypertension, dyslipidemia, renal impairment.

Ophthalmic:

Evaluation of visual acuity, IOP, cornea, iris, angle, pupil, and lens status.

Time interval between injection and vitrectomy:

Duration between intravitreal injection and vitrectomy 3 to 6 days.

Intravitreal injection

- We obtain informed consent also the patient's signature on the consent.

- Dilating drops, 1% tropicamide and 2.5% phenylephrine, are instilled twice, 15 minutes apart, at least 40 minutes before the injection.
- Before the procedure confirm the following the correct patient, correct eye, correct medication and any allergies.
- Use of ophthalmic microscope.
- Benoxinate hydrochloride, and Povidone-iodine was dropped into the conjunctival sac.
- Place sterilized closed-blade eyelid speculum.
- Marking the site of injection: 3-3.5mm for pseudophakes, 3.5-4.0 mm for phakic patients. Tip: Can use the end of caliper (to mark 3.5-4.0 mm). After marking and causing an indentation with the caliper, consider placing 5% povidone-iodine again. It will slightly pool in the indentation ring and adequately underline the injection site.
- Insert the needle at the marked site in a smooth and single movement, aiming for the center of the globe.
- Inject agent slowly and withdraw needle.
- Check light perception, IOP, central retinal artery pulsation no light perception suggests central retinal artery occlusion, consider paracentesis if persists.
- Antibiotic use is controversial, post-procedure antibiotics were given for approximately 3 days (likely for medico-legal reasons).

The surgeon:

- ❖ All surgical procedures were performed by the same surgeon. Dr: Sherif Abbas Dabour.

Anesthesia:

Anesthesia for diabetic vitrectomy is challenging since such surgery is typically longer than cataract phaco-emulsification surgery and the patient have such comorbidities as diabetes and hypertension so general anesthesia may be used, but local anesthesia peribulbar/ retrobulbar is the used in all cases, 2% lidocaine (Lidocain Hydrochloride Injection), and 0.75% bupivacaine (Bupivacaine Hydrochloride Injection), Choosing the type of anesthesia according to the anesthesiologist, the surgeon, and the patient's choice.

Sterilization of the surgical field:

After appropriate anesthesia, the operative field is prepared using antiseptic solutions. Preoperatively the eye undergoing surgery was prepared with 5% povidone-iodine for 3 minutes.

Machines: -

Microscope:

The microscope (Zeiss lumera, Carl Zeiss Meditec AG, Germany) should be examined to match the pupillary distance and any refractive error of the surgeon. Once the microscope is placed over the patient, the light source must be aligned with the eye to obtain an excellent red reflex.

Phacovitrectomy:

Stellaris elite, Bausch+Lomb, American.

Laser:

FOX, surgical laser, A.R.C, Diode laser, Germany.

Phacoemulsification (if phaco-vitrectomy):-

Combined cataract and vitreoretinal surgery are performed to the patients with cataract affecting the visualization, so improve the intraoperative visualization during vitreoretinal surgery, and to facilitate postoperative monitoring of the retina.

We record the following items:

- 1- Type of anesthesia (peribulbar or general).
- 2- Diathermy application numbers.
- 3- Iatrogenic breaks.
- 4- Intra operative bleeding.
- 5- Bottle height in centimeters.
- 6- Tamponade by (silicon – fluid – gas – air).
- 7- Use of healon as haemostatic.
- 8-

Vitrectomy operation: -

Insertion of pars plana cannula:

Insertion is accomplished by first displacing the conjunctiva laterally by approximately 2 mm. An initially oblique around 25–30° angle parallel to the limbus, then perpendicular, the trocar is turned directly toward the center of the globe and is advanced until the hub of the cannula is flush with the sclera. The trocar is then removed, leaving the cannula in place.

Number and location of sclerotomies: -

Usually, three sclerotomies are placed around 3.5 (psudophacic) – 4mm (phacic) from the limbus depending upon the lens status, using trocar-cannula system: lower temporal quadrant, for infusion; upper right, for active instrumentation such as cutter or scissors and upper left for endoilluminator.

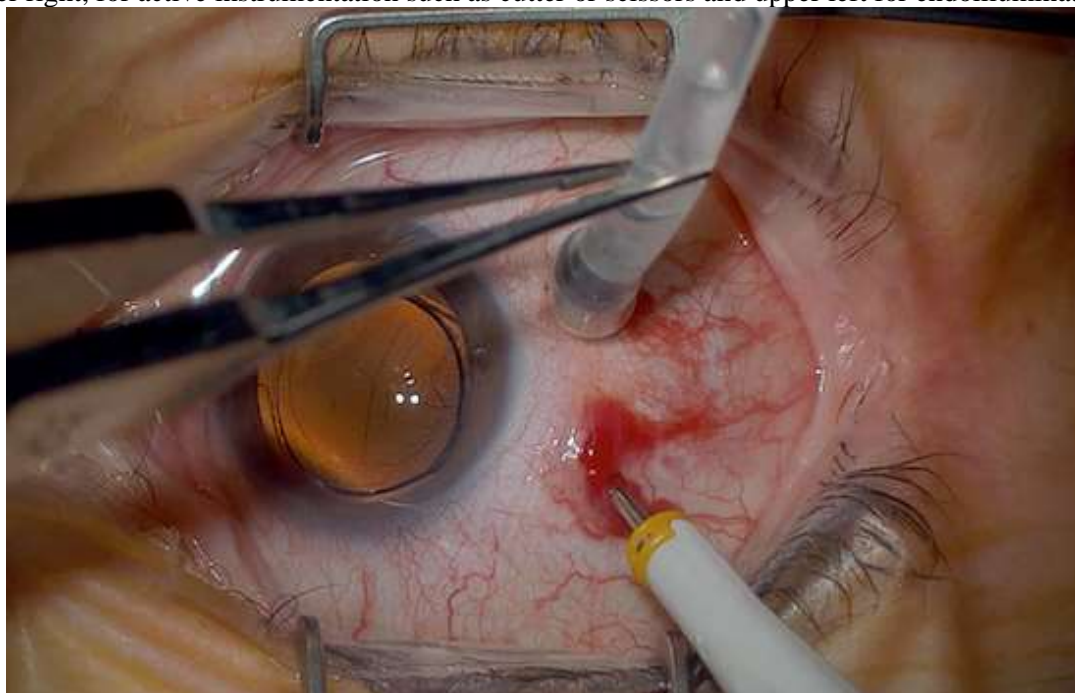


Figure (1): Holding the infusion with forcep when inserting trocars.

BIOM: -

The noncontact wide-angle viewing system was used for visualization

Core vitrectomy: -

A light pipe and a vitrector are then passed through the superior sclerotomies. The first step is to perform a core vitrectomy to debulk the central vitreous. This can be performed under direct visualization with the microscope. In patients with phakic eyes, to avoid crystalline lens damage, the vitreous cutter should not be positioned too anteriorly, and the midline should not be crossed with any instrument, because this can cause lens touch.

If identifying the vitreous is difficult, triamcinolone acetonide may be injected into the posterior segment to highlight the gel, and to identify the location of vitreoretinal adhesions.

PVD Induction

Elevation of the posterior hyaloid is one of the most important steps for the vast majority of vitrectomy cases. PVD induction is almost always accomplished with the vitreous cutter alone. We will start by placing the cutter over the disc on aspiration. Stay on the center of the disc, aspirate, make sure enough gel is occluding the mouth, and then pull straight up. This can be repeated in all quadrants Inject triamcinolone to visualize the hyaloid better. Once a posterior vitreous detachment is induced and the posterior hyaloid is removed, shaving the vitreous base is often necessary.

Removal of fibrovascular tissue:

Surgeon initially removes all elevated cortical vitreous that is producing anteroposterior traction on posterior fibrovascular tissue. Fibrous tissue removal by segmentaion, and delamination

Combined TRD/ RRD:

A combination (RRD)/TRD will result from the tractional tissue contracting and ripping the retina. So, we will carefully dissect tissue around the breaks, even if it enlarges the break a bit. Next, mark the break with diathermy. The case then becomes more like an RRD. Perform a fluid-air exchange and drain the subretinal fluid through the break. Apply laser around the break followed by PRP.

Endolaser:

We do PRP or completing a PRP intra operatively in all cases of diabetic vitrectomy; we use diode laser and the sclera depressor and apply a dense PRP up to the ora serrata.

The most common laser parameters used are: power 100-150 mw; duration 200 ms, and interval 200-300 ms. these values are dependent on the pigmentation of the fundus.

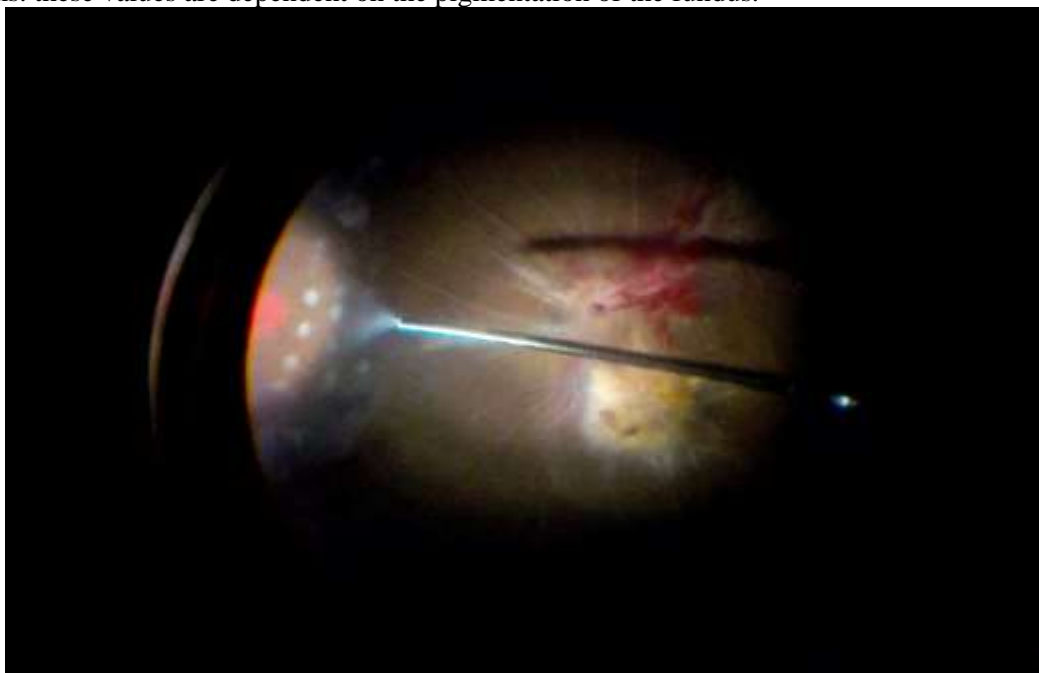


Figure (2): Endolaser

Endodiathermy:

In cases of slight bleeding, aspirate the blood and cauterize the bleeding source with endodiathermy.

Tamponade:

With fluid, air or silicon oil, in case of silicon oil, we use 1000/5000cst silicon oil. Inject the silicon oil under BIOM view, in case of overfill, we cut the infusion line, and excessive silicon oil will escape.

Ending of the operation:

After removal of sclerotomy ports their sites were tested for leakage before being sutured shut with Vicryl 6-0 sutures.

Following surgery, cyclopentolate 1% drops were used four times a day for two weeks and combined antibiotic-steroid drops (tobramycin 0.3 % with dexamethasone 0.1 %) were used six times a day for four weeks. Patients with gas-filled eyes were orderd to keep their prone position with faces down for at least one week. Patients with silicon-filled eyes were not told to take any special positions.

Postoperative follow up: - early - late

Assessment of:

- 1- Visual acuity.
- 2- Intra ocular pressure.

Statistical analysis and data interpretation:

Data were fed to the computer and analyzed using IBM SPSS Corp. Released 2013. IBM SPSS Statistics for Windows, Version 22.0. Armonk, NY: IBM Corp. Qualitative data were described using number and percent. Quantitative data were described using median (minimum and maximum) and

mean, standard deviation for normally distributed data after testing normality using Kolmogorov-Smirnov test. Significance of the obtained results was judged at the (0.05) level.

Data analysis

Qualitative data:

- Chi-Square, Fischer exact and Monte Carlo tests for comparison of 2 or more groups

Quantitative data between groups:

Parametric tests:

- Student t-test was used to compare 2 independent groups

Non-Parametric tests:

- Mann Whitney U test was used to compare 2 independent groups

Probability (P-value):

- P-value <0.05 was considered significant.
- P-value <0.001 was considered as highly significant.
- P-value >0.05 was considered insignificant.

2. Results and Discussion

Our study was carried out on sixty-eight diabetic patients, with type 1 or 2 diabetes mellitus and have complications of diabetic retinopathy which need diabetic vitrectomy.

The demographic data:

Thirty-four eyes of patients were included in each group; the groups were well matched in terms of basic and demographical information.

Of whom 32 (47.05%) were male, and 36 (52.95 %) were female with a mean age of 57.92 years (SD \pm 8.37, range 32 - 76). there were 34 eyes in the Bevacizumab group (A) and 34 eyes in the Ranibizumab group (B).

For patients in group A, the mean age of the patients was 58.32 (SD \pm 11.16, range 32 - 76) of whom 14 patients (41.17%) were for males and 20 patients (58.82%) were for females. For patients in group B, the mean age of the patients was 57.52 (SD \pm 8.37, range 44 - 73) of whom 18 patients (52.95%) were for males and 16 patients (47.05%) were for females.

Diabetic characteristics:

The study was carried out on both types of DM, as shown in table (2) the number of patients of type 1 (IDDM) more than the number of types 2 (NIDDM) in both groups with the mean of duration is longer in Bevacizumab group with high level of HbA1c.

Table (1): comparison of demographic characteristics, lens status, PRP, diabetes status, systemic diseases, and smoking between the studied groups

	Group 1 (n=34) (Bevacizumab)	Group 2 (n=34) (Ranibizumab)	Test of significance
Age/years mean±SD	58.32±11.01	57.53±8.25	t=0.337 p=0.737
Sex	n(%)	n(%)	
Male	14(41.2)	18(52.9)	$\chi^2=0.944$ p=0.331
Female	20(58.8)	16(47.1)	
Lens pseudo Phakic	12(35.3) 22(64.7)	7(20.6) 27(79.4)	$\chi^2=1.83$ p=0.177
PRPn(%)			
-ve	21(61.8)	25(73.5)	$\chi^2=1.08$ p=0.300
+ve	13(38.2)	9(26.5)	
Type of DM	n(%)	n(%)	
NIDDM	11(32.4)	9(26.5)	$\chi^2=0.283$ p=0.595
IDDM	23(67.6)	25(73.5)	
Duration of DM (years)	15.76±7.36	14.76±5.65	Z=0.689 p=0.491
HbA1c (gm%) mean±SD	10.34±1.91	9.78±1.99	t=1.17 p=0.248
Systemic diseases			
-ve	25(73.5)	26(76.5)	$\chi^2=0.078$ p=0.779
+ve	9(26.5)	8(23.5)	
Smoking			
-ve	30(88.2)	28(82.4)	$\chi^2=0.469$ p=0.493
+ve	4(11.8)	6(17.6)	

t: Student t test, χ^2 : Chi-Square test, Z: Mann Whitney U test, *statistically significant.

Visual acuity:

Visual acuity measured preoperative, early post operative and late post operative in logMAR visual acuity, as shown in table (7).

IOP:

Intra ocular pressure measured preoperative, early post operative and late post operative. With significant raise in IOP in Ranibizumab group in late post operative follow up as shown in table (8).

Table (2): comparison of visual acuity and IOP among studied groups and during follow up.

	Group 1 (n=34) (Becavizumab)	Group 2 (n=34) (Ranibizumab)	Test of significance (Student t test)
V/A pre-operative	1.56±0.43	1.44±0.57	t=0.939 p=0.351
V/A Early post-operative	1.02±0.44	0.873±0.549	t=1.21 p=0.231
V/A Late post-operative	0.518±0.241	0.447±0.259	t=1.18 p=0.243
IOP pre-operative	17.12±4.67	17.29±4.14	t=0.165 p=0.870
Early post-operative IOP	18.09±3.55	19.06±3.83	t=1.09 p=0.282
Late post-operative IOP	18.79±2.83	20.44±2.95	t=2.35 p=0.02*

t: Student t test, *statistically significant.

Parameters described as mean±SD.

Operation characters:

Indications of PPV are vitreous hemorrhage in 30 cases of our study, 13 cases in Bevacizumab group, and 17 cases in Ranibizumab group. Premacular haemorrhage in 7 cases; 2 in Bevacizumab group, and 5 in Ranibizumab group. Combined TRD+RRD in 3 cases; 2 in Bevacizumab group, and 1 in Ranibizumab group. vitreous hemorrhage+TRD in 28 cases; 17 in Bevacizumab group, and 11 in Ranibizumab group. The numbers of diathermy applications, iatrogenic breaks, bleeding, and bottle height was recorded as in the table.

Table (3): comparison of operation characters between studied groups

	Group 1 (Becavizumab)	Group 2 (Ranibizumab)	Test of significance
Diathermy application Number			
0	18(54.5)	22(64.7)	$\chi^2=3.10$ p=0.212
1	10(30.3)	11(32.4)	
2	5(15.2)	1(2.9)	
Breaks			
0	25(73.5)	26(76.5)	$\chi^2=0.0860$ p=0.958
1	8(23.5)	7(20.6)	
2	1(2.9)	1(2.9)	
Bleeding			
no	18(52.9)	17(50.0)	$\chi^2=0.059$ p=0.808
yes	16(47.1)	17(50.0)	
Bottle height mean±SD	30.82±7.96	33.24±7.45	t=1.29 p=0.202

χ^2 : Chi-Square test, *statistically significant

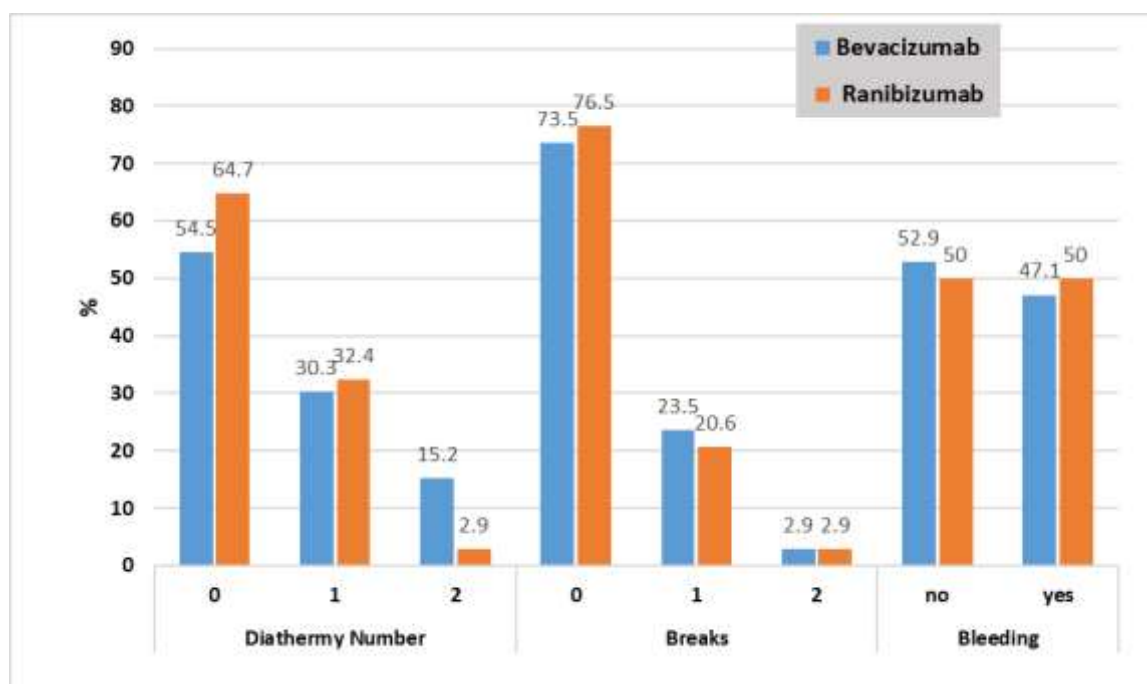


Figure (3): diathermy application number, breaks number, and bleeding incidence between studied groups

The tamponade:

In our study the surgeon uses different types of materials for tamponade according to the severity of the case, the types of tamponades used are shown in table (4), the healon used for haemostasis in some cases.

Table (4): comparison of tamponade between studied groups:

	Group 1 (Bevacizumab)	Group 2 (Ranibizumab)	Test of significance
Tamponade			
Silicon	20(58.8)	18(52.9)	MC=0.248 P=0.883
Fluid	13(38.3)	15(44.2)	
Air	1(2.9)	1(2.9)	
Healon			
-ve	25(73.5)	21(61.8)	$\chi^2=1.075$ p=0.300
+ve	9(26.5)	13(38.2)	
silicon removal			
yes	17(85)	14(70)	MC=1.98

MC:Monte Carlo test, χ^2 : Chi-Square test, *statistically significant.

Parameters described as number (percentage).

➤ This table shows no statistically difference between the studied groups.

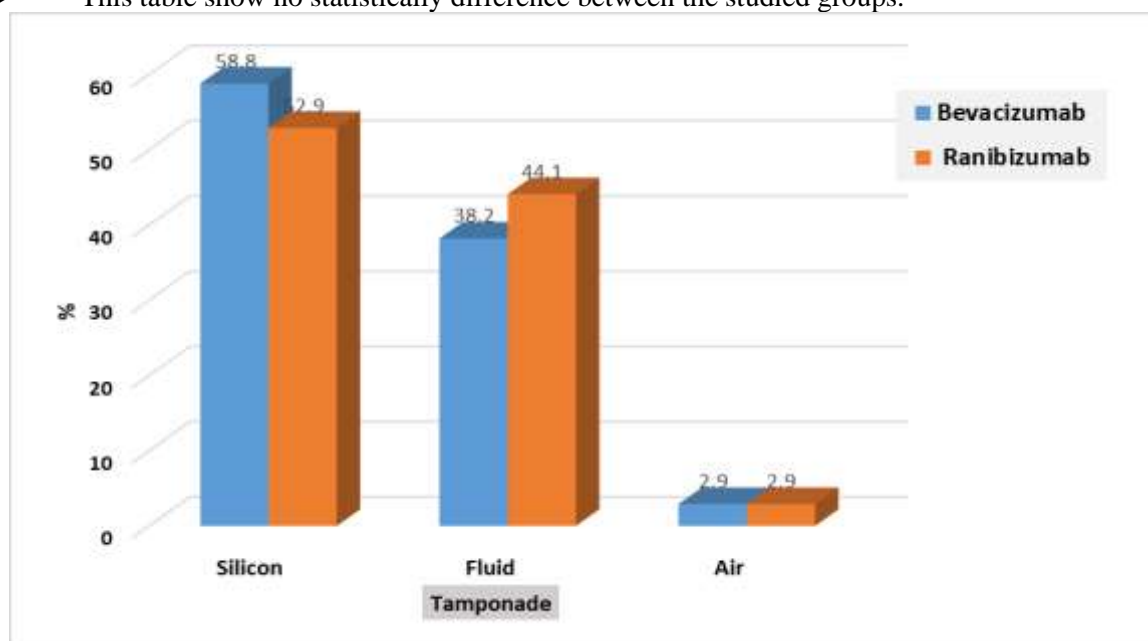


Figure (4): tamponade type distribution between studied groups

Complications of Proliferative diabetic retinopathy is one of the leading causes of permanent visual loss; Diabetic Vitrectomy for the complications of proliferative changes has resulted in preservation of vision (12). In patients with vitreous hemorrhage associated with advanced PDR, preoperative injection of anti-VEGF agents (usually one week before vitrectomy) seems to be advantageous. (13) Pre operative injection of Ranibizumab could affect the surgical time of operation, reduce the intraoperative complications as bleeding and break formation, and sometimes spare the need for silicon tamponade. (14)

Preoperative administration of Bevacizumab before diabetic vitrectomy is effective in decreasing vitreous VEGF concentration and decreasing intraoperative bleeding measured by reducing the numbers of coagulation spots. (15)

Our study is a randomized study demonstrate the difference between preoperative intravitreal injection of bevacizumab or ranibizumab to facilitate and help the operation of diabetic vitrectomy. The intravitreal injection of anti VEGF is being widely used for managements of ocular neovascular complications especially proliferative diabetic retinopathy. The injection of anti VEGF before operation will effect on the duration of operation, diathermy use, breaks, bleeding, helon use, type of tamponade.

Diabetic characteristics:

In the current study, the HbA1c was 10.34% in Bevacizumab group, and 9.78% in Ranibizumab group, with p value =0.248, without any statistical difference, also the type of DM, which is IDDM in 67.6% of the patients in Bevacizumab group, and 73.5% of the patients in Ranibizumab group, with p value=0.595, without any statistical difference, and the mean of duration of DM which is 15.76 year in Bevacizumab group and 14.76 year in Ranibizumab group, with p value=0.491, without any statistical difference, In the study by kaivon (16), the mean HbA1c was 8.9% in Ranibizumab group, and 9.6% in Bevacizumab group these factors indicates the uncontrolled nature of the disease and prolonged duration of DM in our patients and the patients of the previous study.

Systemic diseases:

There is a slight difference between our two groups in systemic diseases which affecting diabetic vitrectomy, by history of the patients, in Bevacizumab group; 34 patients one patient of them (2.94%) has solitary kidney, three patients of them (8.82%) have nephropathy, five patients of them (14.70%) have hypertension, and two patients of them (5.88%) have ischemic heart disease with pacemaker implant, but in ranibizumab group 34 patients; one patient of them (2.94%) has chronic renal failure, one patient of them (2.94%) has nephropathy, and six patients of them (17.64%) have hypertension, p value=0.779, without any statistical difference.

In our study the prevalence of hypertension is higher in Ranibizumab group than the bevacizumab group. in Ranibizumab group six cases (17.6%) from which five cases develop intraoperative bleeding (83.3%), but in Bevacizumab group five cases (14.7%) from which three cases develop intraoperative bleeding (60%), with p value=0.4932, without any statistical difference, In a study by (17) Intraoperative or early postoperative high systemic blood pressure ≥ 150 mmHg is a risk factor for intraoperative bleeding in patients who underwent PPV for PDR. So, the anesthesiologist controle the BP of the patients when raised during the operation.

Ischemic heart diseases in our study present in two cases (5.88%) of Bevacizumab group only, without any complications reported, visual acuity improved in the two cases, as a study by abdah (18) ischemic heart diseases was significantly associated with decrease in visual acuity among patients who undergo diabetic vitrectomy, IHD has been identified as a poor prognostic factor for survival after PPV for PDR patients with 50% of these patients dying within 3.5 years of surgery

Smoking:

Smoking in our candidate is 11.8 % in Bevacizumab group and 17.6% in Ranibizumab group with p value=0.493, without any effect on the vitrectomy operation, in a study by Michal Jan Stasiowski, (19). Smoking status has no predictive value for the occurrence of post operative nausea and vomiting when undergoing PPV. smoking (defined as daily use of tobacco products), Smoking was observed to be associated with an increased hazard of retinal detachment surgery failure (20) This is consistent with previous study by dean (21) suggesting smoking increases the risk of proliferative vitreoretinopathy formation.

Lens status:

In our study the total number of pseudophakic cases are 19 (28%); in Bevacizumab group are 12 (35.5%) cases, and in Ranibizumab group 7 (20.6) cases, with p value=0.177, without any statistical difference. The majority of postoperative complications and final visual acuity were similar between

the two groups in our study's phaco-vitrectomy cases, suggesting that the PPV combined with cataract surgery approach may be more secure and suitable for patients with significant cataract and coexisting proliferative diabetic retinopathy. The study by kang (22). PPV combined with cataract surgery, it is recommended that surgeons be cautious in their evaluation of the retina and provide adequate PRP if there is an indication of active proliferative diabetic retinopathy or neovascularization, and patients should be regularly followed up for development of NVG.

Visual acuity:

In our study the visual acuity of snellen converted to logMAR visual acuity by tables discussed by Roy (23). The mean of the basic best-corrected visual acuity (BCVA) LogMAR 1.56 in Bevacizumab group, compared with LogMAR 1.44 in Ranibizumab group, with p value=0.351, without any statistical difference. The mean of early post operative best corrected visual acuity in Bevacizumab group was LogMAR 1.02, and 0.873 in Ranibizumab group, with p value=0.231, without any statistical difference. The main of the final best corrected visual acuity in Bevacizumab group 0.518, and 0.447 in Ranibizumab group, with p value=0.243, without any statistical difference. There is a statistically significant improvement in visual acuity from basic best corrected visual acuity to early and post operative.

IOP:

There was no significant difference in IOP between the groups at base line, p value= 0.870, but at the follow-up visits, early visit no significant difference between the groups, p value=0.282. But at late visit the Ranibizumab group show mild elevation in IOP in comparison to Bevacizumab group, with p value= 0.02.

A study by travis (24) Good report the IOP elevation was more after Bevacizumab intravitreal injection. Another study by Ron (25) the incidence of OHT is more after Ranibizumab intravitreal injection, and in a study by Daniel (26) is normal for IOP to increase after intravitreal injection; however, there was no correlation between the frequency, number, or anti-vascular endothelial growth factor drug utilised in the injections.

As the multiple intravitreal injection is the risk factor for IOP elevation, in our study all candidates receive one intravitreal injection. In a study by Josef (27) Multiple injections of anti VEGF 'Ranibizumab or Bevacizumab' may lead to persistent elevation of IOP which require anti glaucoma therapy.

PRP:

When diabetic retinopathy is more severe, pan retinal photocoagulation should be considered to avoid the complications of progression of retinopathy which leading to visual loss. In our study the number of patients who previously did PRP were in Bevacizumab group 13 (38.2%), but in Ranibizumab group 9 (26.5%), with p value 0.3060, no significant difference between groups. The presence of PRP scres associated with better operation and outcomes, as all our cases of previus PRP not complicated by rebleeding after operation this result as that done by Petros (28) The presence of pre-operative panretinal photocoagulation scars is associated with better outcomes following PPV for VH, including a reduced risk of rebleeding after the operation.

PPV Indications:

Our study done on complications of diabetic retinopathy in the form of vitreous haemorrhage which present in 30 cases (44.11 %); 13 cases in Bevacizumab group, and 17 cases in Ranibizumab group. Premacular haemorrhage in 7 cases (10.29%); 2 cases in Bevacizumab group, 5 cases in Ranibizumab group. Combined RRD+TRD in 3 cases (4.41 %); 2 cases in Bevacizumab group, and 1 case in Ranibizumab group. Viterous haemorrhage+ TRD in 28 cases (41.17); 17 cases in Bevacizumab group, and 11 cases in Ranibizumab group.

In our study there was no case develop new tractional retinal detachment, or progression of already present ones during the study in both groups even in cases of longer duration between anti VEGF and diabetic vitrectomy.

In a study by Taurin (29) Fibrovascular proliferation causing excessive traction of ischemic thinned retina in cases of PDR resulting in formation of retinal breaks and this can result in combined tractional

and rhegmatogenous retinal detachment so the vitrectomy should be performed as soon as possible. The combined TRD and RRD present in our study in three cases only, 2 (5.9%) in Bevacizumab group and 1 (2.9%) in Ranibizumab group.

Anesthesia:

All cases of our study done by the same surgeon (Dr Sherif A Dabour) under local peribulbar anesthesia, so no case develop the side effects of anesthesia as oculocardiac reflex or post operative nausea and vomiting. A study by (30), vitrectomy operation can be done by regional anesthesia peribulbar block with good anesthesia and akinesia with better haemodynamic stability and less post operative complications

Operative characters:

Iatrogenic retinal break:-

One of the most significant and dangerous risks associated with vitreoretinal surgery is iatrogenic retinal break which is defined a full thickness break in the neurosensory retina caused by surgery (31), such breaks are most frequently produced by excessive vitreous traction on the retina. The overall incidence of the retinal break in our study 25%, the incidence of the break were single break in 23.5% in Bevacizumab group, but 20.6% in Ranibizumab group, and double breaks in 2.9% in the two groups similarly, p value=0.958, also the incidence of the break is higher in phakic patients in the Bevacizumab group 66.6%, but in Ranibizumab group the incidence is similar in phakic and pseudophakic, the incidence is higher in phakic candidates than in pseudophakic due to cataract surgery induce PVD which decrease the incidence of the break. In a study by Aliranza Mirshahi (32) the cataract surgery induces posterior vitreous detachment, so the iatrogenic breaks during PVD induction not present in these cases.

Iatrogenic breaks include those caused by a variety of mechanisms, such as those at the posterior pole during fibrovascular membrane dissection, those in the peripheral retina during the induction of a posterior vitreous detachment or thorough dissection of the peripheral vitreous and oral dialysis connected to instrument insertion and removal. (33), in our study the mechanism of the iatrogenic breaks not recorded just presence or absence of the break.

In a study by Kaivon-Vaezi (16), the incidence of the iatrogenic retinal break was 14.3% in Bevacizumab group, but 20.0% in Ranibizumab group, with P value .535 which are nearly similar to our study.

The association between the incidence of retinal break and TRD was, in Bevacizumab group all cases (8 cases) of TRD develop retinal break except one case (87.5%), but in Ranibizumab group all cases (7 cases) of TRD develop retinal break except two cases (71.4%).

Bleeding:-

Bleeding is the most challenging to the retinal surgeon during diabetic vitrectomy, Throughout the entire surgery, bleeding must be under control, Prolonged and uncontrolled bleeding can make it difficult to determine the cause of the haemorrhage, and when the blood coagulates, pseudomembranes can form, making it even more challenging to dissect membranes. Elevated tamponade pressure can be beneficial, but the underlying cause of the bleeding must be treated with diathermy or a long-lasting endolaser. Long-term tamponade pressure can cause optic neuropathy and increase ischemia.

In our study the bleeding occurred in 47.1% in Bevacizumab group but in Ranibizumab group 50% with p value =0.808 which similar to the pervious study by Kaivon-Vaezi, et at, 2014 (16), the intraoperative bleeding occurred in 57.1% in Bevacizumab group, and 53.3% in Ranibizumab group with p value=.837.

Methods of stopping bleeding during diabetic vitrectomy at first by raising the IOP by manipulation of the infusion line pressure, if not controlled the second by heat-induced coagulation using intraocular diathermy, in some cases we need to use helon as a haemostatic effect, the helon used in 26.5% in Bevacizumab group, but used in 38.2% in Ranibizumab group. The total cases of bleeding in Bevacizumab group 16 cases from which 9 cases (56.25%) need helon as a haemostatic effect, but in Ranibizumab group the total cases of bleeding are 17 cases from which 13 cases (76.47%) need helon as a haemostatic effect, with p value=0.300.

Endodiathermy:-

Intraoperative bleeding can be controlled by endodiathermy (gentle endodiathermy, proportional diathermy 12% of the maximum power value of the instrument); at first aspiration or reflux of the haemorrhage by vitrectomy probe or extrusion canula to clear the haemorrhage, then contact with the endodiathermy probe. In our study one spot endodiathermy applied in 8 cases (23.5%) in Bevacizumab group and 7 cases (20.6%) in Ranibizumab group, and two spots are applied in one case only in each group with p value=0.958, in a study by Kaivon -Vaezi, et al, 2014 (16), endodiathermy was applied to 13 cases in each group (Becavizumab '92.9%' and Ranibizumab '86.7%' groups) with p value =.527.

Bottle height:

Bottle height during vitrectomy in our study with mean of 30.82 cm in Bevacizumab group and 33.24cm in Ranibizumab group, which may be raised to 60cm during operation to control IOP and bleeding, in Bevacizumab group three cases need to elevate the bottle high from 40cm to 60cm, but in Ranibizumab group six cases need to elevate the bottle. In A study by Sang Uk Park (34) During vitrectomy, the variations in IOP were positively associated with bottle heights in the shape of a curve, Patients who are at risk for retinal or optic nerve injury after vitrectomy should therefore be constantly watched. In a study by Bing et al., 2020 (35) Intraoperative bleeding controlled by elevating infusion pressure.

Tamponade:

In our study we used one of three substances in tamponade, the first one silicon oil 5000 cst used in 55.88% of total cases, in Bevacizumab group 20 cases (58.82%), but in Ranibizumab group 18 cases (52.94%), the silicon oil removed after 3- 6 months in 17(85%) cases in Bevacizumab group, and in 14(70%) in Ranibizumab group. The rest of the patients (3cases in Bevacizumab group and 4 cases in Ranibizumab group) did not complete follow up, the second fluid (Balanced salt solution) used in 41.17% of total cases, in Bevacizumab group used in 13 cases (38.3%), but in Ranibizumab group used in 15 cases (44.2.4%), the third sterile air used in one case in each group (2.9%), with p value=0.883. the increased number of tamponade by silicon due to presence of complicated cases. In a study by by Kaivon-Vaezi et al, 2014 (16) silicon oil tamponade used in 2 cases (14.3%) of Bevacizumab group, and in 4 cases (26.7%) in Ranibizumab group, with p value= .361.

Conclusion

Diabetic vitrectomy is the standard management of proliferative diabetic retinopathy complicated by vitreous haemorrhage, Pre operative injection of Bevacizumab or Ranibizumab has equal effectiveness during diabetic vitrectomy, by decreasing the duration of operation, intra operative bleeding, iatrogenic break, diathermy application, and no difference in the type of tamponade.

References:

1. Gopal Lingam, and Tien Yin Wong: Systemic medical management of diabetic retinopathy: Middle East Afr J Ophthalmol, 20, 301-8, 2013.
2. Emily C Fletcher, Miranda Buckle, and Quresh Amir Mhamed: Diabetic retinopathy: intravitreal vascular endothelial growth factor inhibitors for diabetic macular oedema; BMJ Clin Evid, 16, 702, Mar, 2016.
3. Michael W Stewart: Treatment of diabetic retinopathy: Recent advances and unresolved challenges, World J Diabetes, 25, 333-41, 2016.
4. Pieramici, and M D Rabena: Anti-VEGF therapy: comparison of current and future agents; Eye, 22, 1330-1336, 2008.
5. Giuliana Ribeiro De Carvalho, Vagner Loduca Lima, Glaucia Luciana De Veigo, et al: Effects of Intravitreal Bevacizumab Therapy in Patients with Proliferative Diabetic Retinopathy; Diabetes Metab Syndr, 10, 3149-3155, 2020.
6. Michael W. Stewart: A Review of Ranibizumab for the Treatment
7. Of Diabetic Retinopathy; Ophthalmol Ther, 6, 33-47, 2017.
8. Comyn, L Wickham, DG Charteris, et al: Ranibizumab pretreatment in diabetic vitrectomy a pilot randomized controlled trial (the RaDiVit study); Eye, 31, 1253-1258, 2017.

9. Mary B Kansora, and Raquel Goldhardt: Decision Making in Proliferative Diabetic Retinopathy Treatment; *Curr Ophthalmol Res*, 7, 45-50, 2019.
10. Jefferson Augusto Santana Riberio, Andre Messias, and Rodrigo Jorge: Antiangiogenic drugs and advanced proliferative diabetic retinopathy; *Arq Bras Ophthalmol*, 74, 143-6, 2011.
11. Victor M Villegse, Monica P Gonzalez, and Audina M Berrocel: Pharmacotherapy as an adjunct to vitrectomy; *Ther Adv Ophthalmol*, 23, May, 2021.
12. Tural Galbinur, Efrem D Mandelcorn, and Rajeev H Huni: The adjunctive use of pre-operative intravitreal bevacizumab in the setting of proliferative diabetic retinopathy; *Saudi J Ophthalmol*, 30, 217-220, 2016.
13. Reichel and J S Duker: Diabetic vitrectomy; *Curr Opin Ophthalmol*, Jun, 50-3, 1994.
14. -Mansour Homayouni: Vascular Endothelial Growth Factors and Their Inhibitors in Ocular Neovascular Disorders; *J Ophthalmol Vis Res*, Apr, 4: 105–114, 2009.
15. Fengo Dong, Chenying Yu, Haiyuan Ding, et al: Evaluation of Intravitreal Ranibizumab on the Surgical Outcome for Diabetic Retinopathy with Tractional Retinal Detachment; *Medicine*, Feb, 95, 2731, 2016.
16. Takuyuki Hattori, Hiroyuki Shimada, Hiroyuki Nakashizuka, et al: Dose of intravitreal bevacizumab (Avastin) used as preoperative adjunct therapy for proliferative diabetic retinopathy; *Retina*, 30, 761-4, 2010.
17. Kaivon Pakzad-Vaezi, David A Albiani, Andrew W Kirker, et al: a Randomized study comparing the efficacy of Bevacizumab and Ranibizumab as pre- treatment for pars Plana vitrectomy in proliferative diabetic retinopathy; *ophthalmic surg lasers imaging retina*, 45, 521-4, 2014.
18. Ondaer, MurateTunc, G Aktan, et al: Impact of blood pressure on re-hemorrhage after conventional vitrectomy in patients with proliferative diabetic retinopathy; *Retina – vitreous*, 21, 283-286, 2013.
19. Abdah Khairiahche, Evelyn Li Min Tai, Yee cheng Kueh, et al: Survival Time of Visual Gains after Diabetic Vitrectomy and Its Relationship with Ischemic Heart Disease; *Int J Environ. Res Public health*, 17, 310, 2020.
20. Michal Jan Stasiowski, Alekandra Platu, Anita Lyssek-Boron, et al: Adverse Events during Vitreoretinal Surgery under Adequacy of Anesthesia Guidance—Risk Factor Analysis; *Pharmaceuticals*, 15, 237, 2022.
21. Rohan W Essex, Mali Okada, Rodger Paul, et al: Daily tobacco smoking is associated with retinal detachment surgery failure; *Investigative Ophthalmology & Visual Science* June, 61, 1411, 2020.
22. Dean Elliott, Tomasz Pstryjewski, and Michael T anderioli: smoking is a risk factor for proliferative vitreoretinopathy after traumatic reinal detachment; *Retina*, 37, 1229-1235, 2017.
23. Kang Xiao, Yi-Chen Dong, Xin- Guang Xiao, et al: Effect of Pars Plana Vitrectomy with or Without Cataract Surgery in Patients with Diabetes: A Systematic Review and Meta-Analysis, *Diabetic Ther*, 10, 1859-1868, 2019.
24. Roy W Back, Pamela moke, Andrew Turpin, et al: A computerized method of visual acuity testing: Adaptation of the early treatment of diabetic retinopathy study testing protocol; *Americam J of Ophth*, 135, 194-205, 2003.
25. Travis J Good, Alan Kimura, Naresh Manddava, et al: Sustained elevation of intraocular pressure after intravitreal injections of anti-VEGF agents; *Br J Ophthalmol*.95, 1111-4, 2011.
26. Ron A Adelman, Qi Zheng, and Hylton R Mayer: Persistent ocular hypertension following intravitreal bevacizumab and ranibizumab injections; *J Ocul Pharma Ther*, 26, 105-10, 2010.
27. Daniel Y Choi, Maria Carolina Ortube, and Colin A Mcannel: Sustained elevated intraocular pressures after intravitreal injection of bevacizumab, ranibizumab, and pegaptanib; *Retina*, 31, 1028-35, 2011.
28. Joseph J Tseng, Susham K Vance, Kara E Della Torre, et al: Sustained increased intraocular pressure related to intravitreal antivascular endothelial growth factor therapy for neovascular age-related macular degeneration; *J Glaucoma*, 21, 241-7, 2012.
29. Petros E Carvounis and Jaafar El amin: Current Management of Vitreous Hemorrhage due to Proliferative Diabetic Retinopathy; *Int Ophth Clin*, 54, 141-153, 2014.
30. Taurn Sharm, Angie Fong, Timothy, et al: Surgical treatment for diabetic vitreoretinal diseases: a review, clinical and experimental ophthalmology, 44, 340-354, 2016.
31. Carvalho, C Jantrada, J Azevedo, et al: Comparison of peribulbar block and general anaesthesia in mechanical vitrectomy: A prospective observational study; *Ravista Espaniola de Anestesiologia y Reanimacion*, 67, 63-67, 2020.
32. Dogramaci, E J K Lee, and T H Williamson: The incidence and the risk factors for iatrogenic retinal breaks during pars plana vitrectomy; *Eye*, 26, 718-722, 2012.
33. Aliranza Mirshahi, Fabian Hoehn, and Katrin Lorenz: Incidence of posterior vitreous detachment after cataract surgery; *J of Cataract and refractive surgery*, 35, 987-91, 2009.
34. Chen, R Tzekov, F Z Jiang: Iatrogenic retinal breaks and postoperative retinal detachments in microincision vitrectomy surgery compared with conventional 20-gauge vitrectomy: a meta-analysis; *Eye*, 33, 785-795, 2019.

35. Sang Uk Park, Sang Beom Han, and Moo Sang Kim: Correlation between Intraocular Pressure and Bottle Heights during Vitrectomy; J Korean Ophthalmol Soc, 56, 727-731, 2015.
36. Bing Li, Meng-Da Li, Jun-Jie Ye, et al:Vascular endothelial growth factor concentration in vitreous humor of patients with severe proliferative diabetic retinopathy after intravitreal injection of conbercept as an adjunctive therapy for Vitrectomy; Chines Medical Journal, 6, 133, 2020.