



Giloy (*Tinospora cordifolia*) Extract Mediated Biochemical, Haematological and Histological Alterations in Mice

Bandita Baruwa¹, Akalesh Kumar Verma^{2*}, Bidisha Kataki³, Diksha Dutta⁴, Mamata Goswami⁵, Namram Sushindrajit Singh⁶

¹Research Scholar, Department of Zoology, Cell & Biochemical Technology Laboratory, Cotton University, Guwahati-781001, Assam, India Email: banditabarua@gmail.com

^{2*}Assistant Professor, Department of Zoology, Cell & Biochemical Technology Laboratory, Cotton University, Guwahati-781001, Assam, India Email: akhileshverma07@gmail.com

³Assistant Professor, Department of Zoology, L.T.K. College, Lakhimpur-787031, Assam, India Email: katakibidisha2@gmail.com

⁴Research Scholar, Department of Zoology, Cell & Biochemical Technology Laboratory, Cotton University, Guwahati-781001, Assam, India Email: dikshadutta2@gmail.com

⁵Associate Professor (Rtd.), Department of Zoology, Cotton University, Guwahati-781001, Assam, India Email: mamatag_adhikari@yahoo.com

⁶Assistant Professor, Department of Zoology, Cell & Biochemical Technology Laboratory, Cotton University, Guwahati-781011, Assam, India Email: ssdrajit@gmail.com

*Corresponding author's E-mail: akhilesh@cottonuniversity.ac.in

| Article History | Abstract |
|--|--|
| Received: 06 June 2023 Revised: 05 Sept 2023 Accepted: 14 Oct 2023 | <p><i>Tinospora cordifolia</i> (TC), a medicinal plant deeply integrated into India's folklore and Ayurvedic medical tradition, has been a reliable remedy for addressing various health concerns. Despite its proven efficacy in managing diseases, it is essential to exercise prudence regarding its dosage, as excessive consumption may result in undesirable consequences. This present study seeks to ascertain if the methanolic extract of TC triggers any adverse effects on organ function, haematological parameters, or biochemical profiles. The extract was administered intra peritoneally (IP) into the Swiss albino mice at a concentration of 300mg/kg body weight and observations were taken on 7th and 14th day. In comparison to control groups, the levels of haemoglobin (Hb), packed cell volume (PCV), red blood corpuscles (RBC), red cell distribution width (RCW), and platelet count increase. However, significant decrease was also observed in the levels of erythrocyte sedimentation rate (ESR) and lymphocytes. Blood biochemical analysis reveals a significant increase in urea but a subsequent decrease in blood sugar levels. The findings unequivocally illustrate the disruption in the seminiferous tubules of the testis, accompanied by a decrease in spermatid count. Furthermore, observable damage to kidney tissues was noted. Based on these observations, it can be inferred that, despite its multifaceted therapeutic applications, TC extract may exert toxic effects in mice.</p> |
| CC License CC-BY-NC-SA 4.0 | Keywords: Haemoglobin, haematology, packed cell volume, red blood corpuscles, toxicity |

1. Introduction

The growing interest among scientists worldwide lies in harnessing essential molecules or bioactive compounds obtained from medicinal plants and animals for disease treatment and prevention. The World Health Organization (WHO) reports that roughly 65% of rural India's population and 80% of the global population depend on traditional medicine as their primary healthcare solution (Mukherjee 2002; WHO 2003; Bodeker et al. 2005; Bandaranayake 2006; Singh et al. 2022). Since the 1950s, when the discovery and development of the Vinca alkaloids (vinblastin and vincristine) and the isolation of the cytotoxic podophyllotoxins began, the search for anti-cancer agents derived from plants has continued. One such plant is *Tinospora cordifolia* (TC), a native of India, Myanmar, and Sri Lanka belonging to the Menispermaceae family. Common names include giloy, guduchi, and heartleaf moonseed. Most plant parts, including the root, stem, and leaves, are used to treat diseases. Multiple bioactive chemical components have been extracted from this plant, which contribute to its medicinal properties (Reddy et al. 2015).

The methanolic, ethanolic, and aqueous extracts of TC exhibit high antioxidant activity. Additionally, these extracts have demonstrated metal chelation and reducing capabilities, as documented by Singh et al. in 2005. Furthermore, they have been found to enhance the production of essential enzymes such as superoxide dismutase (SOD), glutathione peroxidase (GPX), and glutathione (GSH) within the liver. Moreover, these extracts have the potential to inhibit enzymes like glucose 6-phosphatase and fructose 1,6-diphosphatase, thereby contributing to the restoration of glycogen levels in the liver, as reported by Sharma et al. in 2015. The dichloromethanoic extract of TC given to Ehrlich ascites carcinoma (EAC) mice results in tumor-free survival by reduction of GSH and glutathione-S-transferase (GST) with increased levels of lipid peroxidation and DNA damage to tumour cells (Rao et al, 2008). Aqueous ethanolic extract of TC is also used for differentiation based therapy of Glioblastomas (Mishra and Kaur 2013). Breast cancer cell line treated with methanolic extract of stem of TC install cell proliferation and migration of cancerous cells (Kamble 2015).

TC also have cytotoxic and immunomodulatory effects (Tripathi et al. 1997; Bishayi et al. 2002; Subramanian et al. 2002; Sharma et al. 2012). Treatment with TC extract in CCl₄-intoxicated rats can protect the liver and notable increase in the peritoneal macrophages' functional capabilities was seen (Bishayi et al. 2002). TC increases the production of reactive oxygen species (ROS) in human neutrophil cells and the phagocytic activity of macrophages (More and Pai 2012). In the immune system, IL-12 stimulates Th1 T-helper cell maintenance, and IL-18 boosts NK cell activity. By promoting the production of IL-12 and IL-18, TC therapy activates antigen-specific immunity and boosts the production of IFN-gamma (Nair et al. 2004).

The part of stem which is rich in isoquinoline alkaloid, jatrorrhizine, magnoflorine and palmatine have been reported for insulin-mimicking and insulin-releasing effect both *in vitro* and *in vivo* (Patel and Mishra 2011). The isoquinoline alkaloid rich fraction from stem includes palmatine, jatrorrhizine and magnoflorine which have been reported for insulin mimicking and insulin releasing effect both *in vitro* (using rat pancreatic β -cell line, RINm5F) and *in vivo* (Sharma et al. 2015). TC have property to protect against aflatoxin-induced nephrotoxicity because of the presence of alkaloids such as a choline, tinosporin, isocolumbin, palmatine, tetrahydropalmatine and magnoflorine. It was also found to show protective effect by lowering down the content of thiobarbituric acid reactive substances (TBARS) and enhancing the GSH, ascorbic acid, protein and the activities of antioxidant enzymes viz., SOD, catalase (CAT), GPX, GST and glutathione reductase (GR) in kidney (Gupta et al. 2011).

Additionally, TC possesses hepatoprotective and cardioprotective properties. Using a carbon clearance test as a metric, the functionality of Kupffer cells was evaluated in induced liver-damaged animal models treated with TC. The outcomes demonstrated a marked improvement in Kupffer cell function and a trend toward normalization (Naggarkatti et al. 1994). Prior treatment with TC in rats with ischemia-reperfusion-induced myocardial infarction decreased infarct size and serum and heart lipid peroxide concentrations in a dose-dependent manner (Rao et al. 2005). Alcoholic extract of TC can stimulate the growth of osteoblasts, as well as increase mineralization of bone-like matrix and differentiation of cells into osteoblastic lineage (Abhirsundari 2012). Different bark extracts of TC

(methanolic, ethanolic, and chloroform extract) have been studied using the BSA denaturation method and have shown the ability to inhibit protein denaturation and therefore act as an anti-arthritic agent (Ramya and Maheswari 2016).

Besides all the above mentioned properties, TC also have effect on some other diseases. TC was found to have anti-diuretic effects (Nayampali et al. 1988). The roots were found to have anti-stress and tonic property. A good response was reported in children with moderate degree of behavioural disorder and mental deficiency. It also increases IQ when treated with TC (Singh et al. 2003). The extract with some another formulation can decrease ulcer and total acidity with an increase in the pH of gastric fluid and ethanol-induced gastric mucosal injury in rats (Bafna and Balraman 2005). Research showed that TC is used as anti-leprotic agent and also used for different types of skin disorders (Ashthana et al. 2005). The extract has anti-HIV effect which function by reducing eosinophil, stimulating B lymphocytes, macrophages and polymorphonuclear leucocytes and haemoglobin percentage and thereby reduce the disease risk and proper management of the disease (Akhtar et al. 2010).

Upon an extensive review of scientific literature, it becomes evident that TC, the plant in question, exhibits efficacy against a wide array of human diseases and associated symptoms. However, there is a notable scarcity of established evidence regarding the potential organ toxicity and haematotoxicity of this plant extract in mouse models. Given that TC is utilized in the development of drugs for critical illnesses like cancer, ensuring its safety at both the cellular and genetic levels is paramount. In the present study, our objectives encompassed the extraction and analysis of TC's phytochemical properties, an examination of the impact of the methanolic extract on haematological parameters, and an investigation into any potential organ toxicity mediated by the extract.

2. Materials And Methods

Collection of the plant and extract preparation

The stem of TC was collected in the month of September, 2018 from the District of Kamrup metro, Assam, India. Fresh plant specimen was collected from Panjabari-Batahghuli area, Kamrup (Metro) district, Guwahati, Assam. The same plant was also collected from Arunachal Pradesh (East Kameng) but no differences in biochemical profile and biological activity was observed. The collected specimen was then hard dried and pressed by following proper procedures for preparation of herbarium. As per requirement, properly dried specimen was pasted and stitched (wherever necessary) on standard herbarium sheets. Details of collection were provided alongside the specimen on the herbarium. An herbarium sheet was submitted to the Herbaria House, Department of Botany, Gauhati University for identification and authentication. Another similar herbarium sheet was prepared, properly poisoned with mercuric chloride and submitted to the Herbaria house, Department of Botany, Cotton University for record.

For extraction purpose, the stem sample was washed properly with distilled water and cut into small pieces followed by drying under hot air oven at 40°C until it became fully dry. Then the dry stems were grounded and the extract was prepared by mixing 150g of TC stem powder with 500 mL methanol (70%). Extraction was carried out 3 times by incubating 72 h on the shaker. After extraction, the filtrate was collected and dried using rotary evaporator (Roteva Equitron, India, Model: 8766.V0) at 35°C. The obtained crude extract was kept in the refrigerator till further use.

Qualitative phytochemical screening

Priliminary phytochemical analysis was performed to detect the presence of phytochemicals like alkaloids, flavonoids, terpenoids, steriods, carbohydrates, proteins, fats and saponins etc. All the experiments were done by using the standard methods by Harborne (1973), Trease and Evans (1978) and Sofowara (1993).

High performance thin layer chromatography

High Performance Thin Layer Chromatography (HPTLC) was performed in suitable solvents for the qualitative analysis of various constituents in plant extracts. The crude extracts from leaves, fresh tender stem and hard dried stem of TC were prepared in Methanol, thoroughly mixed using a vortex and spotted using capillary tubes onto HPTLC plates. The solvents used for HPTLC plate development

were Chloroform, Chloroform: Ethyl acetate (4:1), Chloroform: Ethyl acetate (2:1), Methanol: Acetic acid: Water (8:1:1) and Chloroform: Ethyl acetate: Acetic acid (10:9:1) respectively. After the sample had been run, the HPTLC plate was placed in a chamber containing iodine vapor. After incubation in iodine chamber for 15 minutes the plate was removed and photographed followed by *Rf* value determination for separated spots using the following formula:

$$Rf = \frac{\text{Distance travel by the solute front (cm)}}{\text{Distance travel by the solvent front (cm)}}$$

Gas chromatography mass spectrometry

The GCMS analysis of plant extract was performed using Perkin Elmer Clarus 680 GC/600C MS. The sample was first introduced into a carrier gas tank having Helium as the mobile phase. From the pressurized carrier gas tank, a total flow of 49ml/min was injected into the column through an injector in split mode. The injector contains a heated chamber containing a glass liner into which the sample was injected through the septum. The sample then vaporized to form a mixture of carrier gas, vaporized solvent and vaporized solutes respectively. A proportion of this mixture passed onto the column, but most exited through the split outlet. While the instrument runs, the computer generates a graph from the signal, called a chromatogram. Each of the peaks in the chromatogram represents the signal created when a compound elutes from the GC column into the detector. The X-axis shows the RT and the Y-axis shows the signal intensity (abundance). Compounds that have similar properties often have the same retention times. As the individual compounds elute from the GC column, they enter the electron ionization (mass spec) detector. There, they are bombarded with a high-energy electron beam (70eV). Electron impact Ionization (EI) usually produces singly charged ions containing one unpaired electron. A charged molecule which remains intact is called the molecular ion. Instability in a molecular ion, due to the energy imparted by the electron impact cause that ion to break into smaller pieces (fragments). The fragments are charged ions with a certain mass. The mass of the fragment divided by the charge is called the mass to charge ratio (*m/z*). Since, fragments produced by EI have a charge of +1, the *m/z* represents the molecular weight of the fragment. The computer records a graph for each scan. The X-axis represents the *m/z* ratios and the Y-axis represents the intensity (abundance) of the signal for each of the fragments detected during the scan. This graph is referred to as a mass spectrum. The mass spectrum is essentially a fingerprint for the molecule which can be used to identify a compound. The computer on GC-MS has a library of spectra that can be used to identify an unknown chemical in the sample mixture. The library compares the mass spectrum from a sample component and compares it to mass spectra in the library. It reports a list of likely identifications along with the statistical probability of the match which are listed in the form of a table.

Experimental design, animal model and preparation of dose

Experiment were conducted both on male and female Swiss albino mice with body weight (30 ± 5 g) were maintained under standard conditions [natural light and dark cycle, food and water available *ad libitum*, (26 ± 1) °C]. The experiments were done with respect to the internationally accepted standards of ethical guidelines for laboratory animal use and care. The Institutional animal ethical clearance was obtained (6/IAEC/CU/05/01/2021) and study protocol was approved by the committee. For the present study, mice were randomly divided into 3 groups having 10 animals in each for histopathological, haematological and serological tests. The study groups were:

Group A: Control (drug vehicle alone)

Group B: (7day treatment at the dose of 300 mg/kg body wt. per day)

Group C:(14day treatment at the dose of 300 mg/kg body wt. per day)

The plant extract dose, 300mg/kg body weight was prepared by mixing the crude extract in PBS (pH: 7.4).

The groups B and C were treated with methanolic extract (300mg/kg body weight) by injecting intra peritoneally (i.p.) in all mice. After treatment for desired period, mice were sacrificed by cervical

dislocation and blood samples as well as different tissues viz., liver, kidney, lungs, ovary, testis, brain, spleen, intestine and heart were collected.

Behavioural study

Every day the behaviour of the animal was observed for 3 h after injection with the plant extract. The different characters chosen for the behavioural study were fur condition, swelling, body colour, breathing abnormality, colour of urine and faeces, sleepiness, eye dullness, aggressiveness, abdominal contraction and distention.

Biochemical and haematological study

The fresh blood from the mice was collected by pricking the orbital sinus present beside the eye. For serum, the collected blood was kept at room temperature in a vial without EDTA for half an hour. The different parameters taken for studying haematological profile of mice were haemoglobin, packed cell volume (PCV), red blood cell (RBC) count, mean corpuscular volume (MCV), mean corpuscular haemoglobin (MCH), mean corpuscular haemoglobin concentration (MCHC), red cell distribution width (R.D.W.), total leucocyte count (TLC), differential leucocyte count (DLC), platelet count, erythrocyte sedimentation rate (ESR) etc.

The parameters used for biochemical analysis were sugar, urea, creatinine, serum glutamic-oxaloacetic transaminase/aspartate transaminase (SGOT/AST), serum glutamic pyruvic transaminase/alanine transaminase (SGPT/ALT), alkaline phosphatase (ALP), albumin (ALB), Na⁺ and K⁺. All these experiments were done using auto analyser (CBC: BK-63005, Shandong, China).

Histopathological study

Histopathological analysis was done as per Gretchen L. Humason (1961). After treatment for 7 and 14 days, different organs such as liver, kidney, testis, heart, lung, ovary, spleen and brain were surgically removed and fixed in formalin and further processed for histology. The histological process including dehydration, clearing and embedding was carried out using standard method. The microscopic sections (5µm) were prepared and Hematoxylin and Eosin staining method was used. The histological photographs were captured by Motic camera and software (Moticam 2000, Spain).

Statistical analysis

All the data were analyzed post-blank normalization and quantitative data are reported as the mean ±SD of three measurements. Statistical analysis was performed by one-way ANOVA followed by bonferroni post hoc test using Graph Pad Prism. P ≤ 0.05 was considered significant.

3. Results and Discussion

Qualitative phytochemical screening:

The preliminary phytochemical analysis of the methanolic extract of the stem of TC showed the presence of alkaloids, carbohydrates, glycosides, phlobatanins, flavonoids, proteins and amino acids, phytosterols, fixed oils and fats, phenolic compounds and tannins, gums and mucilage, steroids and saponins.

Table 1: Table showing the presence of different phytochemicals in methanolic extract of TC:

| Sl. No. | Chemical constituent | Tests performed | <i>T. cordifolia</i> |
|---------|-----------------------|-----------------------|----------------------|
| 1 | Alkaloids | Mayer's Test | +++ |
| | | Wagner's Test | +++ |
| | | Dragendorff's Test | +++ |
| | | Molish's Test | ++ |
| 2 | Carbohydrates | Fehling's Test | +++ |
| | | Barfoed's Test | + |
| | | Benedict's Test | ++ |
| 3 | Glycosides | Borntrager's Test | ++ |
| 4 | Cardiac Glycosides | Keller-Killani's Test | ++ |
| 5 | Cyanogenic Glycosides | Sodium-picrate Test | - |

| | | | |
|----|------------------------------|---------------------------|-----|
| 6 | Phlobatanins | | + |
| 7 | Saponins | Foam Test | ++ |
| | | Millon's Test | +++ |
| 8 | Proteins & Amino Acids | Biuret Test | + |
| | | Ninhydrin Test | ++ |
| 9 | Phytosterols | Libermann-Burchard's Test | ++ |
| 10 | Fixed Oils & Fats | Spot Test | + |
| | | Saponification Test | ++ |
| | | Ferric Chloride Test | +++ |
| 11 | Phenolic Compounds & Tannins | Gelatin Test | +++ |
| | | Lead Acetate Test | +++ |
| | | Alkaline Reagent Test | +++ |
| 12 | Gum & Mucilage | | +++ |
| 13 | Flavonoids | Alkaline Reagent Test | ++ |
| 14 | Anthraquinone | | - |
| 15 | Terpenoids | Salkowski's Test | - |
| | | Salkowaski Test | +++ |
| 16 | Triterpenoids | Libermann-Burchard Test | +++ |
| | | Salkowaski Test | ++ |
| 17 | Steroids | Libermann-Burchard Test | ++ |

It was observed that alkaloids, carbohydrates, proteins and amino acids, phenolic compounds and tannins, gums and mucilages and triterpenoids were present in high concentration whereas the glycosides, cardiac glycosides, saponins, phytosterols, fixed oils and fats, flavonoids and steroids were present in moderate concentrations. Phlobatanins were found to be present in very low concentration. Cyanogenic glycosides, anthraquinone and terpenoids were found to be completely absent.

High performance thin layer chromatography

Out of all five solvents, the most productive solvent was found to be a mixture of Chloroform: Ethyl acetate: Acetic acid, taken in a ratio of (10:9:1). A total of 14 spots were observed in the lane of leaves, followed by 7 and 12 spots in lanes of fresh tender stem and dried hard stem respectively. Leaves yielded highest R_f value of ($=0.8214$) which means the interaction between the compound of interest present in the crude plant extract of TC and the surface is strong. It also means that the compound of interest has a high solubility in the mobile phase. Fresh tender stem yielded a maximum R_f of ($=0.7380$) and dried hard stem yielded a maximum R_f of ($=0.8095$).




Figure 1A: Comparison of HPTLC performed in different solvents.

Table 2: HPTLC profiling of TC extract showing different retention factors (*R_f*):

| Sl. No. | Solvent | Lanes | No. of Spots | Highest <i>R_f</i> value |
|---------|---|-------------------|--------------|------------------------------------|
| 1 | Chloroform : Ethyl acetate : Acetic acid (10:9:1) | Leaves | 14 | 0.8214 |
| | | Fresh tender stem | 7 | 0.7380 |
| | | Dried hard stem | 12 | 0.8095 |

The HPTLC performed in solvent combination of Chloroform: Ethyl acetate: Acetic acid in the ratio of (10:9:1) was further analysed using ImageJ software. Each lane (leaves, fresh tender stem and dried hard stem) produced a line graph upon plotting that indicates presence of various phytochemicals along with its abundance.

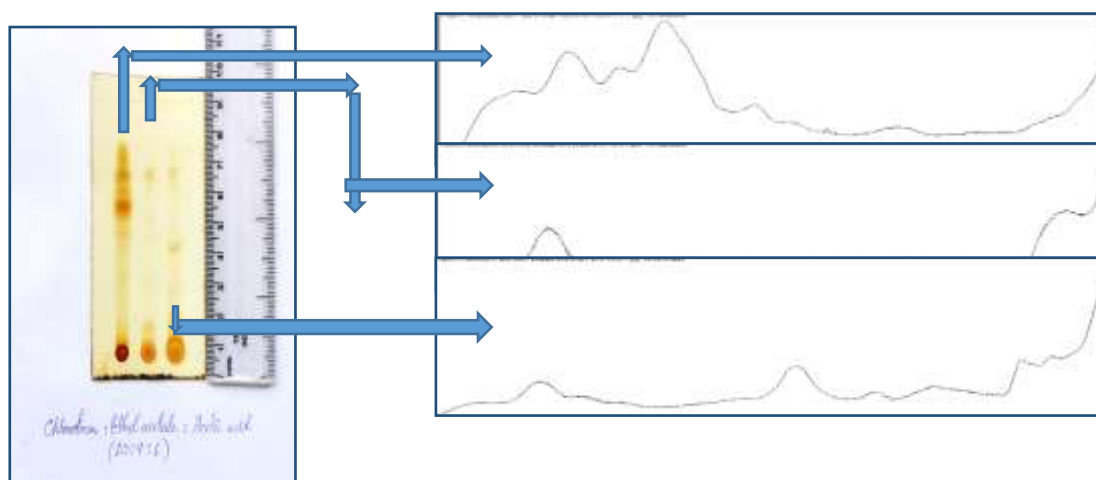


Figure: 1B: Lanes of HPTLC analysed by ImageJ software

Gas chromatography mass spectrometry:

GC-MS chromatogram showed presence of several compounds in the methanolic extract of TC

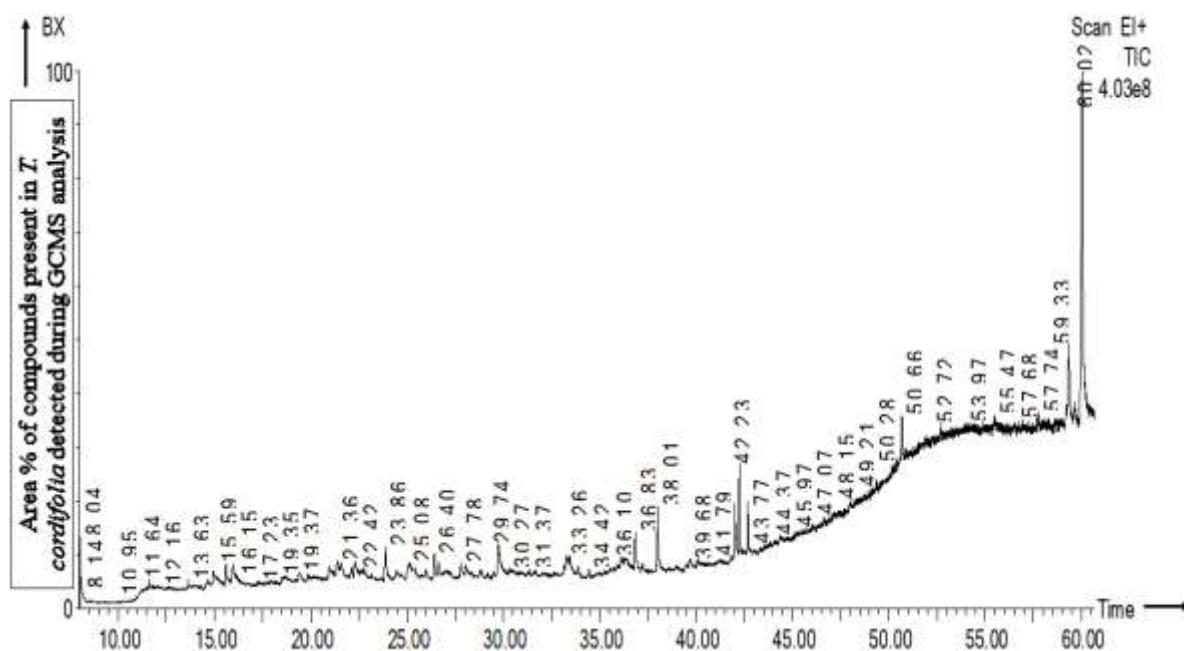


Figure 2A: Gas Chromatogram (GC) of TC extract (70% methanol).

The total time frame of GC analysis was of 60mins. The chromatogram reflected peaks from 8.04 RT (Retention time) to 60.024 RT. Out of all, a total of 12 peaks covering the maximum percentage (%) area of the chromatogram was individually analysed for probable compounds that are listed in the library.

Table 3: Compounds identified in the methanolic extract of TC in GC-MS.

| Sl. nos. | RT | Name of compounds | Mol. formula | Mol. wt. | Area % | CAS |
|----------|--------|--|----------------------------|----------|--------|-------------|
| 1. | 15.592 | 2-(4- CHLOROPHENOXY)-N-[2-(DIETHYLAMINO) ETHYL] ACETAMIDE (Clofexamide) | $C_{14}H_{21}O_2N_2C$ 1 | 284 | 0.626 | 1223-36-5 |
| 2. | 15.962 | (4E)-4-HEPTENAL (4-Heptenal) | $C_7H_{12}O$ | 112 | 0.944 | 62238-34-0 |
| 3. | 23.865 | PENTACOSAN-2-ONE (2-Pentacosanone) | $C_{25}H_{50}O$ | 366 | 0.826 | 75207-54-4 |
| 4. | 26.416 | 1-METHYLCYCLOHEXAN-1-OL (1-Methylcyclohexanol) | $C_7H_{14}O$ | 114 | 0.555 | 590-67-0 |
| 5. | 29.742 | 2-BUTAN-2- YLCYCLOPENTAN-1-ONE (Cyclopentanone, 2-(1-Methylpropyl)) | $C_9H_{16}O$ | 140 | 1.265 | 6376-92-7 |
| 6. | 36.835 | PHENOL, 2,6-DIMETHOXY-4-(2-PROPENYL) | $C_{11}H_{14}O_3$ | 194 | 0.578 | 6627-88-9 |
| 7. | 38.005 | METHYL 9-METHYLTETRADECANOATE | $C_{16}H_{32}O_2$ | 256 | 0.686 | 213617-69-7 |
| 8. | 41.997 | METHYL 13-OCTADECENOATE | $C_{19}H_{36}O_2$ | 296 | 0.750 | 900336-41-6 |
| 9. | 42.232 | METHYL 9,10-OCTADECADIENOATE | $C_{19}H_{34}O_2$ | 294 | 0.699 | 900336-45-7 |
| 10. | 42.667 | METHYL 11,14,17-EICOSATRIENOATE | $C_{21}H_{36}O_2$ | 320 | 0.427 | 900336-41-3 |

| | | | | | | |
|-----|--------|--|--|-----|-------|------------|
| 11. | 59.339 | VITAMIN A ALDEHYDE | C ₂₀ H ₂₈ O | 284 | 1.251 | 116-31-4 |
| 12. | 60.024 | ANDROSTAN-17-ONE, 3-ETHYL-3-HYDROXY-, (5.ALPHA.) | C ₂₁ H ₃₄ O ₂ | 318 | 2.763 | 57344-99-7 |

Library search results showed the presence of Androstan-17-one, 3-ethyl-3-hydroxy- (5 alpha) at the maximum level covering a % area of 2.763 at RT 60.024 having a molecular weight of 318 Daltons followed by 2-butan-2-cyclopentan-1-one (Cyclopentanone, 2-(1-Methylpropyl) covering a % area of 1.265 at RT 29.742 having a molecular weight of 140 Daltons and Vitamin A aldehyde covering a % area of 1.251 at RT 59.339 having a molecular weight of 284 Daltons. On a decreasing trend, (4E)-4-heptenal (4-Heptenal) covered a % area of 0.944 at RT 15.962 having a molecular weight of 112 Daltons, Pentacosan-2-one (2-Pentacosanone) covered a % area of 0.826 at RT 23.865 having a molecular weight of 366 Daltons, Methyl 13-octadecenoate covered a % area of 0.750 at RT 41.997 having a molecular weight of 296 Daltons, Methyl 9,10 octadecadienoate covered a % area of 0.699 at RT 42.232 having a molecular weight of 294 Daltons, Methyl 9-methyltetradecanoate covered a % area of 0.686 at RT 38.005 having a molecular weight of 256 Daltons, 2-(4- chlorophenoxy)-n-[2-(diethylamino)ethyl] acetamide (Clofexamide) covered a % area of 0.626 at RT 15.592 having a molecular weight of 284 Daltons, Phenol, 2,6-dimethoxy-4-(2-propenyl) covered a % area of 0.578 at RT 36.835 having a molecular weight of 194 Daltons, 1-Methylcyclohexan-1-ol (1-Methylcyclohexanol) covered a % area of 0.555 at RT 26.416 having a molecular weight of 114 Daltons and Methyl 11,14,17-eicosatrienoate covered a % area of 0.427 at RT 42.667 having a molecular weight of 320 Daltons. All the 12 compounds have been represented with the help of a graph against their percentage area in the chromatogram.

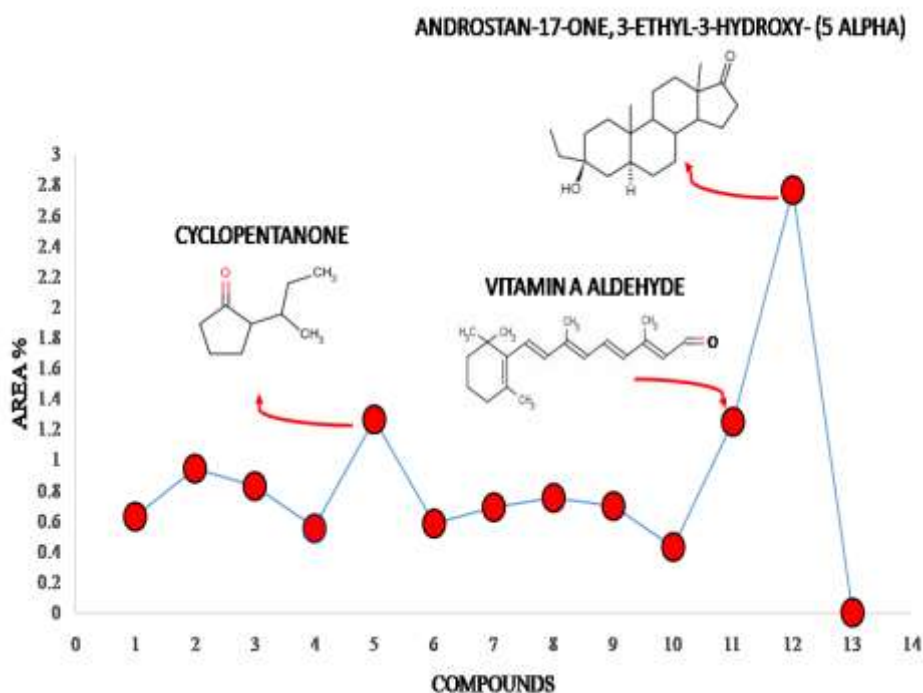


Figure 2B: Percentage area of major compounds (in table 3) obtained in crude extract of TC.

Behavioural analysis:

On the basis of observation, there were no significant changes in the normal behaviour of mice after treatment with TC extracts. The fur condition was completely normal. There was no swelling, change in body colour, normal breathing, change in colour of urine and faeces and eye dullness. The mice didn't show sleepiness and aggression in nature. Abdomen was also found to be normal as there was no distention and contraction.

Table 4: Study of behaviour of mice during 1st 3hrs of treatment with TC extract.

| Sl. No. | Parameters | Observations |
|---------|---|--------------|
| 1 | Fur condition | Normal |
| 2 | Swelling | No |
| 3 | Body colour | No change |
| 4 | Breathing abnormality | Normal |
| 5 | Abnormality in colour of urine and faeces | No |
| 6 | Sleepiness | No |
| 7 | Eye dullness | No |
| 8 | Aggressiveness | No |
| 9 | Abdominal distention | No |
| 10 | Abdominal contraction | No |

Biochemical analysis

Results showed significant changes in some parameters showing the effect of TC in mice groups. The significant difference is shown in blood sugar and urea ($F_{2,8}=24, p=0.0014$; $F_{2,8}=18, p=0.0031$, Fig.3A and B). There is significant decrease in sugar level among control ($95\pm 3\text{mg/dl}$) and 7day ($82\pm 0.57\text{ mg/dl}$; $p<0.05$) as well as control and 14day ($73\pm 6\text{ mg/dl}$; $p<0.01$) group. On the other hand, in case of urea, significant increase (Fig. 3B, $p<0.01$) was observed between the control ($26\pm 0.2\text{ mg/dl}$) and 7day ($27\pm 0.3\text{ mg/dl}$) as well as control and 14day ($27\pm 0.2\text{ mg/dl}$). There was no significant increase or decrease in creatinine, SGOT, SGPT, ALB, ALP, Na⁺ and K⁺ ions concentrations.

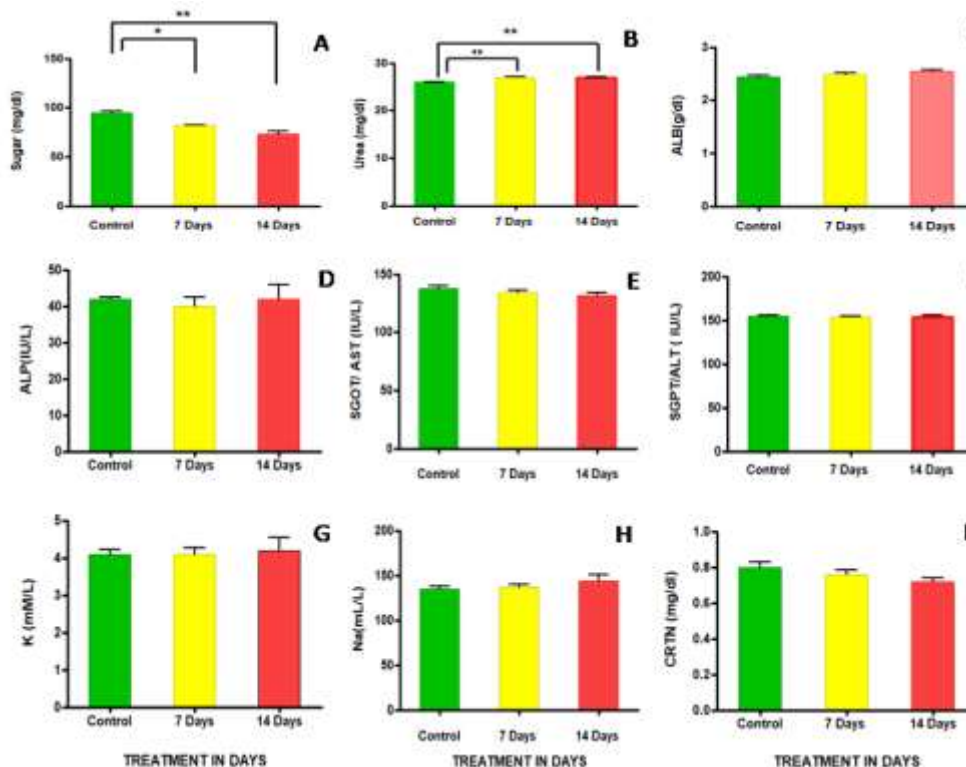


Figure 3: (A -I): Histogram presentation of biochemical parameters showing differences between control, 7 day treated and 14 day treated groups.

Haematology

Haematological analysis of different blood parameters show variation in results among control and treated groups of animals.

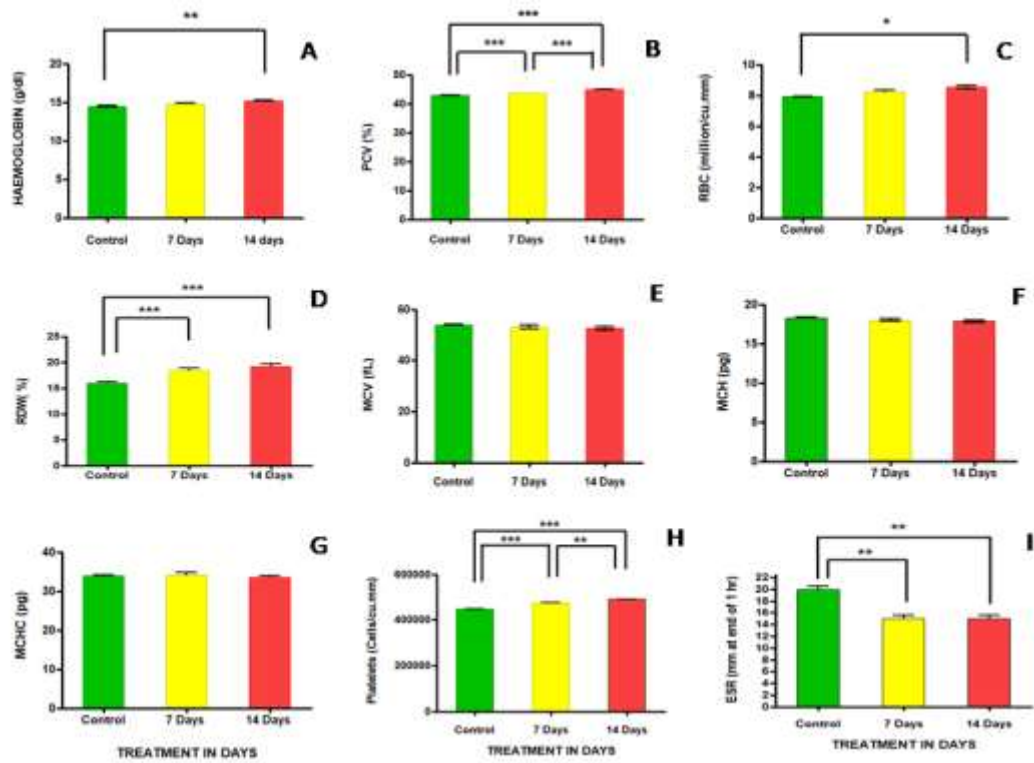


Figure 4A: (A-I): Histogram presentation of haematological parameters showing differences between control, 7 day treated and 14 day treated groups.

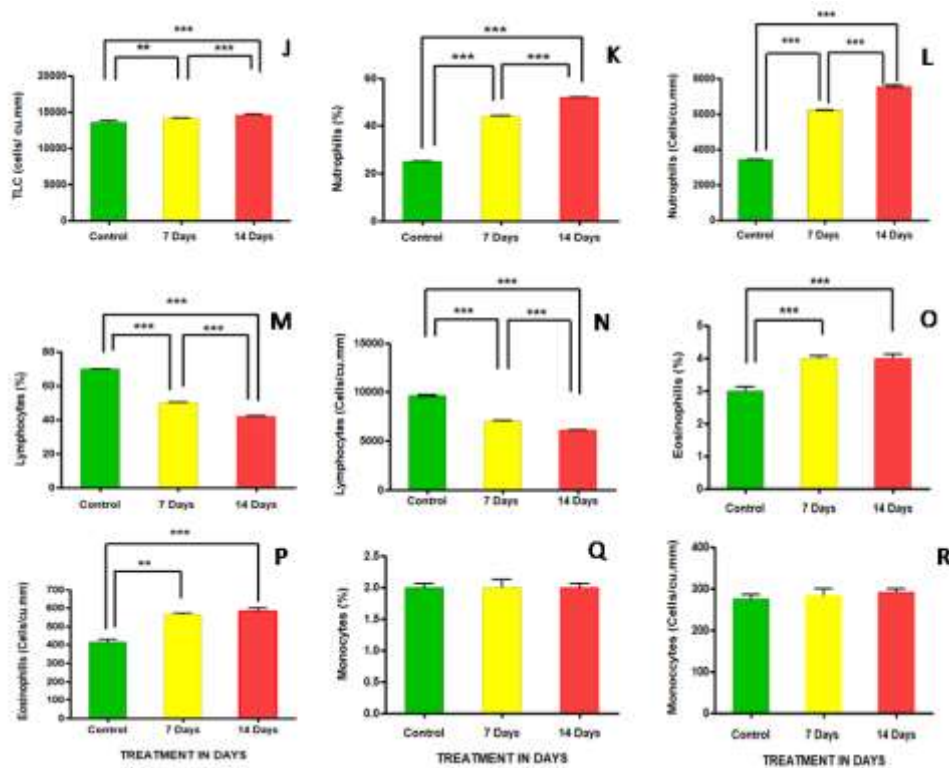


Figure 4B: (J-R): Histogram presentation of haematological parameters showing differences between control, 7 day treated and 14 day treated groups.

Results show significant increase in the haemoglobin count ($F_{2,8}=12$, $p=0.0075$; Fig. 4A), PCV ($F_{2,8}=460$, $p<0.0001$; Fig. 4B), RBC ($F_{2,8}=8.5$, $p=0.0175$; Fig. 4C), RDW ($F_{2,8}=15$, $p=0.0045$; Fig. 4E),

platelets ($F_{2,8}=110$, $p<0.0001$; Fig. 4H), TLC($F_{2,8}=10$, $p=0.0111$; Fig. 4J), neutrophils ($F_{2,8}=3200$, $p<0.0001$; Fig. 4K), % count of neutrophils ($F_{2,8}=6400$, $p<0.0001$; Fig. 4L), eosinophils ($F_{2,8}=37$, $p=0.0004$; Fig. 4O), % count of eosinophils ($F_{2,8}=33$, $p=0.0006$; Fig. 4P), while lymphocytes (differential- $F_{2,8}=1400$, $p<0.0001$; Fig. 4M) and absolute count- ($F_{2,8}=2200$, $p<0.0001$; Fig. 4N) and ESR ($F_{2,8}=25$, $p=0.0012$; Fig. 4I) significant decrease in 14days treatment. However, no significant changes were observed in the levels of MCV, MCH, MCHC and monocyte. Significant increase in haemoglobin was observed only after 14 days ($p<0.01$; Fig. 4A) of treatment although steady raise in the level was observed on 7day. Haemoglobin increased from 14.5 ± 0.20 g/dl to 14.8 ± 0.20 g/dl in 7day and 15.2 ± 0.10 g/dl in 14day. There was no significant difference between 7day treated and 14 day treated groups. The PCV levels of control group was ($42.8\pm 0.10\%$) which increased significantly in 7 days ($43.6\pm 0.03\%$) and also significantly increased in 14 day treated groups ($44.87\pm 0.10\%$) (Fig. 4B). It was observed that the PCV levels increased significantly ($p<0.001$) as observed on 7day and 14day of treatment indicating a dose-dependent increase. Significant increase ($p<0.05$) in number of RBC was observed only on 14 day treated groups (Fig 4C). There were no significant changes observed between the control and 7day treated group and also between 7day and 14day group. RDW increase (Fig 4D, $p<0.001$) was observed among the 7 day and 14 day treated mice as compared to control group. No significant difference was observed between the group of 7day and 14 day which indicated that the treatment with this drug increases RDW at a very steady rate. Long term treatment with TC will change the distribution of RBCs. Significant increase (Fig 4H, $p<0.001$) in platelet count among all the treated groups were revealed by the results. There was a significant increase (Fig 4J, $p<0.001$) in the TLC among control and 7day, 7day and 14day as well as control and 14 day treated mice. Such prominent increase in TLC contribute to the immunomodulatory property of TC. Similar observed in neutrophils and eosinophils. Total count of neutrophils significantly increased ($p<0.001$) among both treated group and also between treated and control group. Total as well as % count of eosinophils (Fig. 4P) increased significantly between control and 14 days ($p<0.001$) and total count of eosinophil increased between control and 7day ($p<0.01$) whereas in case of % count it increased at a rate slower rate ($p<0.05$). However, the total and % count of Lymphocytes decreased significantly among control and 7day ($p<0.001$) and 7 and 14day ($p<0.001$) and control and 14day ($p<0.001$) (Fig. 4N). Significant decrease ($p<0.01$) in the level ESR was also observed on 7day and 14 days as compared to control group (Fig. 4I).

Histology

The histological analysis of the organs from the control were compared with the results of the treatment groups. No changes took place in the histology of brain, heart, intestine, ovary, spleen, lungs and liver after the administration of methanolic extract of TC in the 7 day and 14day treatment groups. However, changes were observed in the histology of testis and kidneys.

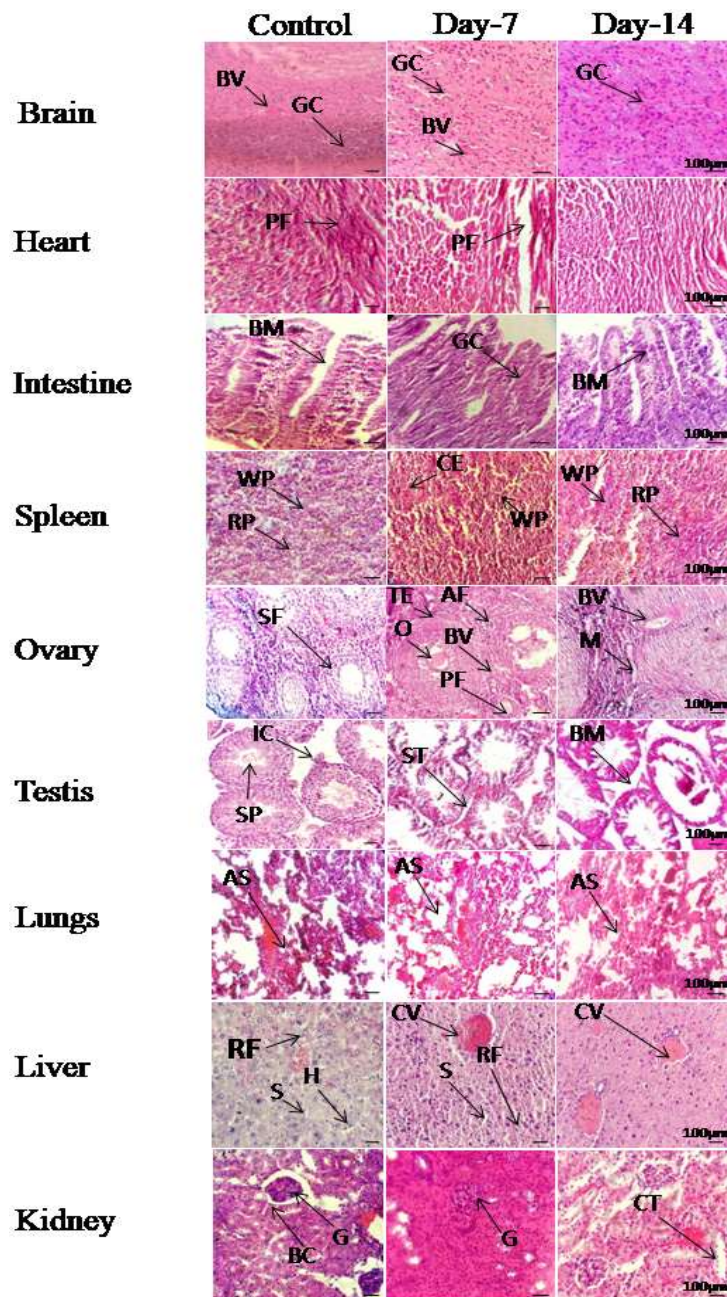


Figure 5: Histology of Brain. GC = Glial cells, BV = Blood vessel.

Histology of Heart. PF= Purkinje fibres.

Histology of Intestine. GC = Goblet cells, BM = Basement membrane.

Histology of Spleen. RP = Red Pulp, WP = White Pulp, CE = Central artery.

Histology of Ovary. BV = Blood Vessel, O = Oocyte, PF= Primary follicle, SF = Secondary Follicle, AF = Atretic follicle, M = Matrix, TE = Theca externa.

Histology of Testis. SP = Spermatids, ST = Seminiferous tubule, IC = Interstitial cells, BM = Basement membrane.

Histology of Lungs. AS = Alveolar Sac.

Histology of Liver. CV = Central vein, S = Sinusoids and H = Hepatocytes, RF = Reticular fibres.

Histology of Kidney. G = Glomerulus, CT = Collecting tubule, BC = Bowmann's capsule.

The histological sections of brain in control groups shows the cerebral cortex and the 3rd ventricle in the midbrain region. The cortex is slightly pink in stain with eosin and hematoxylin than the subcortical white matter which is darkly stained. No damage in any part of the brain was observed. There was no cell death in any region across the brain. There was no effect of the administered drug on the neurons and glial cells. The sections from both 7day and 14 day treated groups of animal shows similarity with the control group. No variation and cell damage took place in the brain. In the heart in control group shows long spindle shaped vascular nuclei, bundle of myocardial cells, few numbers of small blood vessels, bundle of purkinje fibers etc. The 7day and 14 day treated heart sections do not show any injury and are very similar to that of the control cells. There were no evidences of necrosis and any other changes in the cell composition. No visible changes in the intestine was observed after the treatment with TC. The 7 and 14 day treated sections show no difference with the control group. Highly folded mucosa were seen, fine smaller villi were present and intact microvilli present in the lining of columnar epithelial cells. Lamina propria underlying the epithelium show rich vascular network. The studies on the histology of spleen revealed that the drug doesn't have any toxic effect on spleen of mice. The control group of animals shows the red pulp as well as white pulp area. Similarly, both of the treated groups show similarity in red pulp and white pulp with definite visible boundary between them. Normal arrangement of cells across the section was observed. T. S. of ovary of mice from control groups shows the primary follicles, growing follicles and mature graffian follicles. No changes were found in the architecture of the cell and no damage took place inside the cell after treatment with the drug. The 14day ovary shows corpus luteum. Histopathological examination of testis revealed changes in the mice testis administrated with the drug. In control group, T.S. of testis show normal sperm producing seminiferous tubules, interstitial cells present in between 2 or 3 lobes. Lots of spermatids with distinct head are seen. But when observed under 7 day in the treated group significant decrease in the number of spermatid was observed. Also, the disruption of interstitial cells was clearly observed. In 14 days, the drastic decrease in spermatids as well as the disruption of germinal layer of the epithelium were observed. The epithelial membrane scattered all along the tubule and some of the seminiferous tubules form clump. Therefore, this drug has toxic effect on the testis of mice. Sections of lungs show an appearance of fine lace composed of thin walled alveoli. Between the alveoli, thin layers of connective tissue and numerous capillaries were also seen. The section contains many bronchioles of various sizes. The capillaries form a network like structure. The 7 day and 14 day treated groups also show similar structure and therefore no changes took place in the lung tissue of mice after treatment with TC. The hexagonal lobule structure of liver was seen in sections of each group of mice which was surrounded by 6 portal tracts and center on tubular central vein in both the treated and control group. Reticular fibers around the connective tissue line liver sinusoids between sinusoids and discontinuous endothelial cells and form a dense network of central vein. The hepatocytes are clearly seen. Minimal disintegration of hepatic nuclear membrane is evident in 7 day and 14 day treated mice. The area of central vein show distensions in both 7 days and 14 days treated group. Urotoxicity was observed prominently in groups treated with the extract. The 7 day treated sections show no capsular space between Bowman's capsule and the parietal layer due to fatty changes in the Bowman's capsule. Edema i.e., the accumulation of liquid in interstitial spaces or pre-existing cavity was visible.

The present study reveals the effects of TC methanolic extract on the Swiss albino mice in 7 and 14day treated groups. Phytochemical analysis of the extract revealed the presence of different primary and secondary metabolites such as alkaloids, carbohydrates, cardiac glycosides, phlobatanins, flavonoids, proteins and amino acids, phytosterols, fixed oils and fats, phenolic compounds and tannins, gums and mucilage, and steroids and saponins which can be correlated with the findings of Pradhan et al. 2017 where they reported the presence of same and also stated that the presence of phytoconstituents might differ with respect to variation in locations.

Biochemical parameters like Albumin, ALP, SGOT and SGPT and liver enzymes like ALP, ALB are below significant levels or almost absent which indicates absence of hepatotoxicity. Increase in amount of urea in both 7day and 14day might lead to carbamylated protein (CP) accumulation in organs like kidney which can be correlated with the findings of Pietrement et al. 2013 where they stated that the kinetics of the formation of plasma CPs was closely dependent on variations in uremia (increase in urea), since CP concentrations decreased between 5 and 10 weeks after surgery to the same extent as

uremia in mice. A dose dependent significant decrease in the sugar level in 7 and 14day treatment groups was observed in this study which is further supported by the studies conducted by different scientists like Sai et al., 2002 and Sharma et al. 2014 that manifested upon the potential anti-diabetic property of the TC extract with reference to reduction in blood sugar level.

Elevated levels of TLC are observed which may be due to the immunostimulatory property of TC which can be correlated with the findings of Mathew and Kuttan 1999 where they found that when swiss albino mice were treated with *T. cordifolia* extract, there was a significant ($P<0.001$) increase in the total count of leukocytes. The maximum count was found to be 13 083 cells/ml. The mice when treated with TC extract, the TLC increases significantly. The increase in WBCs is responsible for the stimulation of immune system. The neutrophil and the eosinophil counts also significantly increased which can be correlated with the findings of Mohamed et al., 2013 where they found that neutrophil count increased with increasing dose of TC extract and stated that as neutrophils are the first immune cells taken from the blood stream leading to the inflammation area therefore it might be due to the anti-inflammatory property of the plant.

Histological analysis of the organs treated with TC for 7 and 14 day showed no change in the histology of brain, heart, intestine, ovary, spleen and lungs. Slight structural disintegration of hepatic nuclear membrane and distensions visible in the area of central vein in 7 day and 14 day treated mice can be correlated with the findings of Balkrishna et al. 2023 where MNC infiltration in liver was evident. Morphological effects were visible only in the testis and kidneys. The histology of the testis showed disruption of interstitial cells, basal membrane of the seminiferous tubule with a reduction in the amount of sperm in the seminiferous tubules in the 7day treatment group as well as 14day treatment group. These findings can be correlated with the findings of Gupta and Sharma 2003 where they found that antifertility effect of TC in mice decreased in the weight of testes, epididymis, seminal vesicle and ventral prostate occurs after administration of the drug. Sperm motility along with sperm density was reduced. Testosterone level in serum decreases significantly. Leydig cell nuclear area, diameter of seminiferous tubules and cross sectional surface area of sertoli cells were reduced as compared to the control group. But, there is a conflict in results obtained where scientists used TC as a potential treatment for radiation induced toxicity in testis, where they got positive changes in testis which is contradictory to the findings of Sharma et al. 2011 where they found that TC administration before irradiation significantly ameliorated radiation induced elevation in lipid peroxidation and decline in glutathione concentration in testes. These observations indicate the radio - protective potential of TC extract in testicular constituents against gamma irradiation in mice. In kidneys, slight changes were seen. The cavity between bowman's capsule and the parietal layer may have disappeared due to fat accumulation in the bowman's capsule. Edema *i.e.*, the accumulation of liquid in interstitial spaces may also have taken place. The results can be also correlated with the haematological results where increase in blood urea takes place which is responsible for damage in kidney. But, there is conflict of observations where many researchers use TC as a drug to treat against kidney damage which can be inferred with the findings of Joladarshi et al. 2012 where they found that consumption of a diet containing TC at the 5 % level modulates changes in kidney CS/DS which were due to diabetes. The findings can also be correlated with the findings of Balkrishna et al. 2023 where some histological aberrations were observed in kidney like presence of basophilic and mineralized tubules in the kidney cortex. Overall, the fact regarding administration of TC as a drug can be validated with the histopathological findings of Balakrishna et al. 2023 where the above mentioned morphological fluctuations that show a match with our findings were reported as some random histopathological aberrations, such as, alveolar osseous metaplasia, MNC in filtration in liver, kidney, presence of basophilic and mineralized tubules in the kidney cortex as because they were noted but they did not exhibit any dose dependent corelation and therefore, considered as spontaneous/incidental and/or congenital in nature unrelated to TC administration. Moreover, such histopathological peculiarities have been widely reported as background pathology of laboratory rats in literature. Hence, TC extract doesn't exhibit any histopathological changes in the normal structure of brain, heart, intestine, spleen and ovary which can be correlated with the findings of Balkrishna et al. 2023 where no treatment related gross and histopathological observations were noted in giloy establishing the No-Observed-Adverse-Effect-Level (NOAEL) of TCWE at 1000 mg/kg body weight (high dose) when administered orally to male and female Sprague-Dawley rats for 28 consecutive days followed by a 14-day recovery period.

4. Conclusion

Evaluation of multiple parameters and comparison of the test extracts to the control extracts imply that the TC extract produces certain histopathological alterations at a dosage level of 300mg/kg body weight. The histological findings revealed unequivocally that the plant possesses potential to cause renal deformity as well as slight distortion in male gonads, which might result in alterations to normal physiological functions in the long run. Administration of TC extract at such a dosage level or even more than that might cause damage to Bowman's capsule, which is the primary part responsible for filtration of blood to produce urine which in turn may cause malfunction in urine production due to urotoxicity if not monitored properly. In addition, the biochemical analysis of urea reveals a significant rise that correlates with the histological condition. The decrease in blood sugar indicates the anti-diabetic property, whereas the changes in TLC provide evidence of the immunomodulatory property, thus supporting the prior research. To ensure the safety of patients consuming TC as a medication, there should be stringent controls on the presence of components in herbal medicine derived from this plant, as well as appropriate labeling of dosage and concentrations. Administration of TC may be combined with other drugs that are antagonistic to its effects in order to counteract the probable organ mutilation and dysfunction in practice.

Credit authorship contribution statement:

Bandita Baruwa: Conceptualization, experimental work, writing – original draft, Writing – review & editing.

Dr. Akalesh Kumar Verma: Conceptualization, Visualization, Supervision, Writing – review & editing.

Bidisha Kataki: Experimental work, writing – original draft, writing – review & editing.

Diksha Dutta: Writing – review & editing.

Dr. Mamata Goswami: Writing – original draft, writing –review & editing.

Dr. Namram Sushindrajit Singh: Writing – original draft, writing – review & editing.

Acknowledgement:

We acknowledge the Department of Biotechnology (DBT), Government of India for using resources of ongoing DBT project (No. BT/INF/22/SP45376/2022) in the present work. We also extend our regards to thank Cotton University Faculty of Life Sciences for providing animal house facility

Conflicts of interest:

Authors declare no conflicts of interest.

REFERENCES:

- Abiramasundari, G., Sumalatha, K. R., & Sreepriya, M. (2012). Effects of *Tinospora cordifolia* (Menispermaceae) on the proliferation, osteogenic differentiation, and mineralization of osteoblast model systems in vitro. *Journal of Ethnopharmacology*, 141(1), 474–480.
- Akhtar, S. (2010). Use of *Tinospora cordifolia* in HIV infection. *Indian Journal of Pharmacology*, 42(1), 57.
- Asthana, J. G., Jain, S., Mishra, A., & Vijaykant, M. S. (2001). Evaluation of antileprosy herbal drug combinations and their combination with dapsone. *Indian Drugs*, 38(2), 82–86.
- Bafna, P. A., & Balaraman, R. (2005). Anti-ulcer and antioxidant activity of pepticare: A herbomineral formulation. *Phytomedicine*, 12(4), 264–270.
- Bishayi, B., Roychowdhury, S., Ghosh, S., & Sengupta, M. (2002). Hepatoprotective and immunomodulatory properties of *Tinospora cordifolia* in CCl₄ intoxicated mature albino rats. *The Journal of Toxicological Sciences*, 27(3), 139–146.
- Gupta, R. S., & Sharma, A. (2003). Antifertility effect of *Tinospora cordifolia* (wild) stem extract in male rats. *Indian Journal of Experimental Biology*, 41(8), 885–889.
- Gupta, R., & Sharma, V. (2011). Ameliorative effects of *Tinospora cordifolia* root extract on histopathological and biochemical changes induced by aflatoxin-B(1) in mice kidney. *Toxicology International*, 18(2), 94–98.
- Harborne, J. B. (1973). *Photochemical Methods: A Guide to Modern Techniques of Plant Analysis*. Chapman & Hall. (p. 279).

- Joladarashi, D., Chilkunda, N. D., & Salimath, P. V. (2012). Tinospora cordifolia consumption ameliorates changes in kidney chondroitin sulphate/dermatan sulphate in diabetic rats. *Journal of Nutritional Science*, 1(1).
- Mathew, S., & Kuttan, G. (1999). Immunomodulatory and antitumour activities of Tinospora cordifolia. *Fitoterapia*, 70(1), 35-43.
- Mishra, R., & Kaur, G. (2013). Aqueous ethanolic extract of Tinospora cordifolia as a potential candidate for differentiation-based therapy of glioblastomas. *PLoS ONE*, 8(10), e78764.
- Mohamed, E., Dharmana, E., Suwondo, A., & Ausofro, M. (2016). Effect of Tinospora cordifolia Extract on Neutrophils, TNF α , and IFN γ Percentage in Balb/c Mice Infected with Salmonella typhimurium. *International Journal of PharmTech Research*, 9(4), 334-339.
- More, P., & Pai, K. (2012). In vitro NADH-oxidase, NADPH-oxidase, and myeloperoxidase activity of macrophages after Tinospora cordifolia (guduchi) treatment. *Immunopharmacology and Immunotoxicology*, 34(3), 368–372.
- Mukherjee, P. K., Rai, S., Kumar, V., Mukherjee, K., & Hylands, P. J. (2007). Plants of Indian origin in drug discovery. *Expert Opinion on Drug Discovery*, 2(5), 633-657.
- Nagarkatti, D. S., Rege, N. N., Desai, N. K., & Dahanukar, S. A. (1994). Modulation of Kupffer cell activity by Tinospora cordifolia in liver damage. *Journal of Postgraduate Medicine*, 40(2), 65–70.
- Nair, P. K., Rodriguez, S., Ramachandran, R., Alamo, A., Melnich, S., Escalon, E., Garcia, P., Wnuk, S., & Ramachandran, C. (2004). *International Immunopharmacology*, 4, 1645-59.
- Nayampalli, S. S., Ainapure, S. S., Samant, B. D., Kudtarkar, R. G., Desai, N. K., & Gupta, K. C. (1988). A comparative study of diuretic effects of Tinospora cordifolia and hydrochlorothiazide in rats and a preliminary phase I study in human volunteers. *Journal of Postgraduate Medicine*, 34, 233–236.
- Patel, M. B., & Mishra, S. (2011). Hypoglycemic activity of alkaloidal fraction of Tinospora cordifolia. *Phytomedicine*, 18(12), 1045–1052.
- Pietremont, C., Corisse, L., Jaisson, S., & Gillary, P. (2013). Chronic increase in urea leads to carbamylated protein accumulation in tissues in a mouse model of CKD. *PLoS One*, 8(12), 1-10.
- Pradhan, D., Ojha, V., & Pandey, A. K. (2013). Phytochemical analysis of Tinospora cordifolia (wild) Miers ex Hook F. & Thoms stem of varied thickness. *International Journal of Research in Pharmaceutical Sciences*, 4(8), 3051-3056.
- Ramya, R., & Maheswari, R. (2016). Antiarthritic activity of Tinospora cordifolia leaves by denaturation, 10-23.
- Rao, P. R., Kumar, V. K., Viswanath, R. K., & Subbaraju, G. V. (2005). Cardioprotective activity of alcoholic extract of Tinospora cordifolia in ischemia-reperfusion-induced myocardial infarction in rats. *Biological Pharmaceutical Bulletin*, 28, 2319–2322.
- Rao, S. K., Rao, P. S., & Rao, B. N. (2008). Preliminary investigation of the radiosensitizing activity of guduchi (Tinospora cordifolia) in tumor-bearing mice. *Phytotherapy Research*, 22, 1482–1489.
- Reddy, N. M., & Reddy, R. (2015). Tinospora cordifolia chemical constituents and medicinal properties: A review. *Scholars Academic Journal of Pharmacy*, 4(8), 364-369.
- Sai, K. S., & Srividya, N. (2002). Blood glucose-lowering effect of the leaves of Tinospora cordifolia and Saupos androgynus in diabetic subjects. *J Nat Remedies*, 2, 28-32.
- Sharma, P., Parmar, J., Sharma, P., Verma, P., & Goyal, P. K. (2011). Radiation-Induced Testicular Injury and Its Amelioration by Tinospora cordifolia (An Indian Medicinal Plant) Extract. 643847. doi: 10.1155/2011/643847.
- Sharma, R., Amin, H., Galib, & Prajapati, P. K. (2015). Antidiabetic claims of Tinospora cordifolia (wild) Miers: critical appraisal & role in therapy. *Asian Pacific Journal of Tropical Biomedicine*, 5(1), 68-78.
- Sharma, U., Bala, M., Kumar, N., Singh, B., Munshi, R. K., & Bhalerao, S. (2012). Immunomodulatory active compounds from Tinospora cordifolia. *Journal of Ethnopharmacology*, 141, 918–926.
- Singh, N., Singh, S. M., & Shrivastava, P. (2005). Effect of Tinospora cordifolia on the antitumor activity of tumor-associated macrophages-derived dendritic cells. *Immunopharmacology and Immunotoxicology*, 27(1), 1-14.
- Singh, S. S., Pandey, S. C., Srivastava, S., Gupta, V. S., Patro, B., & Ghosh, A. C. (2003). Chemistry and medicinal properties of Tinospora cordifolia (Guduchi). *Indian Journal of Pharmacology*, 35, 83–91.
- Singh, S., Saxena, S. S., & Saxena, N. (2022). Indigenous populations, ethnomedicine, and sustainability: The Indian perspective. *Indigenous People and Nature*, 257-272.
- Sofowora, A. (1993). Medicinal Plants and Traditional Medicines in Africa. Chichester: John Wiley & Sons, New York. 97-145.
- Sonkamble, V. V., & Kamble, L. H. (2015). Antidiabetic potential and identification of phytochemicals from Tinospora cordifolia. *American Journal of Phytomedicine & Clinical Therapeutics*, 3(1), 97-110.
- Subramanian, M., Chintalwar, G. J., & Chattopadhyay, S. (2002). Antioxidant properties of a Tinospora cordifolia polysaccharide against iron-mediated lipid damage and gamma-ray-induced protein damage. *Redox Report*, 7, 137–143.

- Tiwari, M., Dwivedi, U. N., & Kakkar, P. (2014). *Tinospora cordifolia* extract modulates COX-2, iNOS, ICAM-1, pro-inflammatory cytokines, and redox status in a murine model of asthma. *Journal of Ethnopharmacology*, *153*(2), 326-337.
- Trease, G. E., & Evans, W. C. (1978). *Pharmacology*. 11th Ed. Bailliere Tindall Ltd, London, 60-75.
- Tripathi, Y. B., Sharma, M., & Manickam, S. (1997). Rubia 5 din, a new antioxidant from *Rubia cordifolia*. *Indian Journal of Biochemistry and Biophysics*, *34*, 302–306.