

ORIGINAL RESEARCH

Real-Time Video-assisted Intraoperative Neuromonitoring in Vestibular Schwannoma Surgery, 10-year Experience in a Referral Center of Excellence in Iran

Mohammadreza Shahmohammadi¹, Sara Zandpazandi^{1*}, Farnak Behnaz²

1. Functional Neurosurgery Research Center, Shohada Tajrish Comprehensive Neurosurgical Center of Excellence, Shahid Beheshti University of Medical Sciences, Tehran, Iran.

2. Anesthesiology Department, Shohada Tajrish Hospital, Shahid Beheshti University of Medical Sciences, Tehran, Iran.

Received: March 2023; Accepted: April 2023; Published online: May 2023

Abstract: **Introduction:** Vestibular schwannoma (VS) is an extra-axial, benign tumor mostly located in the cerebellopontine angle. The goal of VS surgery is gross total resection of the tumor along with preservation of the cranial nerves' function. Intraoperative nerve monitoring is mainly rewarding in VS surgery.

Methods: This Cohort study was done retrospectively and prospectively from 2011-2021. Patients were divided into two groups; group one (n=19) underwent resection of the tumor with intraoperative neuromonitoring and group two underwent resection of the tumor without neuromonitoring based on patients' ability to economically afford neuromonitoring. In the neuromonitoring group, Somatosensory Evoked Potential (SSEP) was evaluated and recorded throughout the whole surgery. Motor Evoked Potential (MEP) was recorded at regular intervals as well. We compared tumor size, hemorrhage volume during surgery, length of surgery, and facial nerve preservation (HB score), with one-year follow-up.

Results: Facial nerve (FN) anatomical preservation rates were 100% and 75% in the neuromonitoring and control groups, respectively. The Gross Total Resection (GTR) rate in group one was 78.9%. The Subtotal Resection (STR) and Partial Resection (PR) rates in procedures without neuromonitoring were 50.0% and 12.5%, respectively. The House-Brackman (HB) level was good in all patients in group one, while 68.8% of patients in the control group had poor HB.

Conclusions: Intraoperative Neuromonitoring (IONM) in VS surgery helps increase anatomical nerve preservation rate and FN outcome. The coordination of a anatomically trained neurophysiologist along with real-time video-assisted nerve monitoring avoids and lowers any delay in nerve recognition.

Keywords: Intraoperative neurophysiological neuromonitoring; Vestibular schwannoma; Operating room technician professionalism; Nerve preservation

Cite this article as: Shahmohammadi M, Zandpazandi S, Behnaz F. Real-Time Video-assisted Intraoperative Neuromonitoring in Vestibular Schwannoma Surgery, 10-year Experience in a Referral Center of Excellence in Iran. Mens Health J. 2022; 6(1): e18.

1. Introduction

Vestibular schwannoma or the acoustic neuroma is an extra-axial, benign tumor that is mostly located in the cerebellopontine angle, near the internal auditory canal (1). The goal of vestibular schwannoma surgery is to perform gross total resection of the tumor while we consider preservation of the

Cranial Nerve VII (CN VII) and CN VIII function since these have a direct effect on patients' quality of life (2). In larger tumors, the facial nerve (FN) function preservation is difficult and is the goal of microsurgery (3), however, subtotal or near total resection is reported to have the better outcome in larger tumors (4). Since mortality is no longer a major concern in VS, neurosurgeons focus on reaching better outcomes or FN function (5). Recently, after the introduction of intraoperative neuromonitoring and after finding its place in microsurgeries, few studies have been done on intraoperative neuromonitoring for FN function evaluation during operation which eases accomplishment of the aim of surgery (6,7), i.e., gross total resection and FN function preservation

* **Corresponding Author:** Sara Zandpazandi; Address: Functional Neurosurgery Research Center, Shohada Tajrish Comprehensive Neurosurgical Center of Excellence, Shahid Beheshti University of Medical Sciences, Tehran, Iran. Email: sarapazandi@gmail.com, Phone: (+98)912-4641355.



rate, which has been increased after entry of neuromonitoring to VS surgery field and after that, it is reported that IONM should be used routinely to preserve nerve function (2). Achieving gross total resection and FN function preservation is more accessible in tumors with smaller size, however, for huge vestibular schwannomas, in addition to multidisciplinary cooperation, intraoperative nerve monitoring is mainly rewarding (5). After the introduction of IONM, Electromyography (EMG) has been reported to be a great help during tumor resection to save FN (8).

In this study, we report our experience of video-assisted intraoperative neuromonitoring on post-operation (Post-Op) facial nerve palsy and FN function preservation in 35 patients admitted to an Iranian tertiary neurological center.

2. Methods

2.1. Study design and patient selection

This study was conducted by the Declaration of Helsinki (as revised in 2013). The study was approved by the Ethics Committee of Shohada Tajrish Hospital and the Shahid Beheshti Medical University (SBMU) Ethics Committee with an ethics code of (IR.SBMU.RETECH.REC.1401.684). Informed individual consent was obtained from every patient who participated in this study. This study was a cohort study that evaluated prospectively records from 2011-2021. All patients were treated by the same operational team and a sole experienced senior neurosurgeon who had been trained in this regard. 35 patients undergoing surgical VS resection were referred to Shohada Tajrish Hospital from February 2011 to December 2021. They were divided into two groups based on the fact that the cranial nerves were subjected to neuromonitoring intra-operatively and regarding the ability to afford neuromonitoring, as in Iran due to economic issues, neuromonitoring can only be afforded by patients privately. To minimize the surgeon's skill, and decision-making bias and standardize the method, we performed all the operations by a sole qualified and skilled senior neurosurgeon.

2.2. Inclusion criteria

Patients diagnosed with acoustic neuroma on conventional Magnetic Resonance Imaging (MRI) underwent pre-operative audiometry for evaluation of a decrease in auditory function.

2.3. Exclusion criteria

Patients were excluded from the study if they had no interest in either participating in the study or pre-operative audiometry, they had a history of re-operation, neurofibromatosis-2 (NF-2), decrease in auditory function, either congenital or in the non-humoral setting such as virus infection, etc. Also, patients whose final pathology report was not vestibular

schwannoma are excluded.

Patients were divided into two groups, group one with intraoperative neuromonitoring and group two without neuromonitoring. 19 patients underwent resection of the tumor with FN intraoperative neuromonitoring under the supervision of a trained neurophysiologist. We compared tumor size, hemorrhage volume during surgery, length of surgery, and FN preservation (HB score) pre-op and post-op with one-year follow-up (at baseline, 2 and 6 months, one year).

2.4. Anesthesia protocol

For anesthesia, induction Midazolam (1–2 mg), Etomidate (0.15 mg/kg), and Sufentanil (0.3 μ g/kg) were used (9). When induction was achieved, the muscle relaxant use was terminated. For maintenance, Remifentanil (0.2–0.4 μ g/min), and Propofol (2–5 mg/kg/h) were used. To monitor the depth of the anesthesia during the surgery, the Bispectral Index (BIS) was used. It was maintained between 40 and 60 (10).

Nerve monitoring protocols during vestibular schwannoma surgery:

For nerve monitoring, we used constant neuromonitoring to evaluate SSEP alterations and intermittent neuromonitoring for places considering the size and proximity of the tumor to the roots and nuclei of the involved cranial nerves, during surgery and resection of direct adhesion to the paired seventh nerves and the proximity of other caudal roots, constant monitoring, and monitoring of the function of these nerves through free-run EMG and the response of the involved myotomes were needed. On the other hand, stimulation of the bipolar nerve of each nerve and observation of the response in the target myotome is recommended. This can be done with various protocols considering tumor location. Also, evaluation of paired fifth nerves complex by masticatory muscles monitoring is included in some protocols. On the other hand, the modern method of Auditory Evoked Potential (AEP) to study the auditory evoked response to some extent helps control the function of the elements of this nerve and its value is in creating a permanent auditory evoked potential (11).

2.5. Surgical technique

Patients were placed in the park bench position (3.4 people). After placing the neuromonitoring stimulating electrodes in the right place, checking the correct function of the device, and recording the action potentials of the facial muscles, a skin incision behind the ear was performed with the classical retro sigmoid approach. Lateral suboccipital craniotomy is done ipsilaterally. Surgical length and volume of hemorrhage were calculated and recorded since the microscopic tumor resection is started.

The tumor surface must be mapped by monopolar before debulking to avoid superficial facial nerve injury. Since,

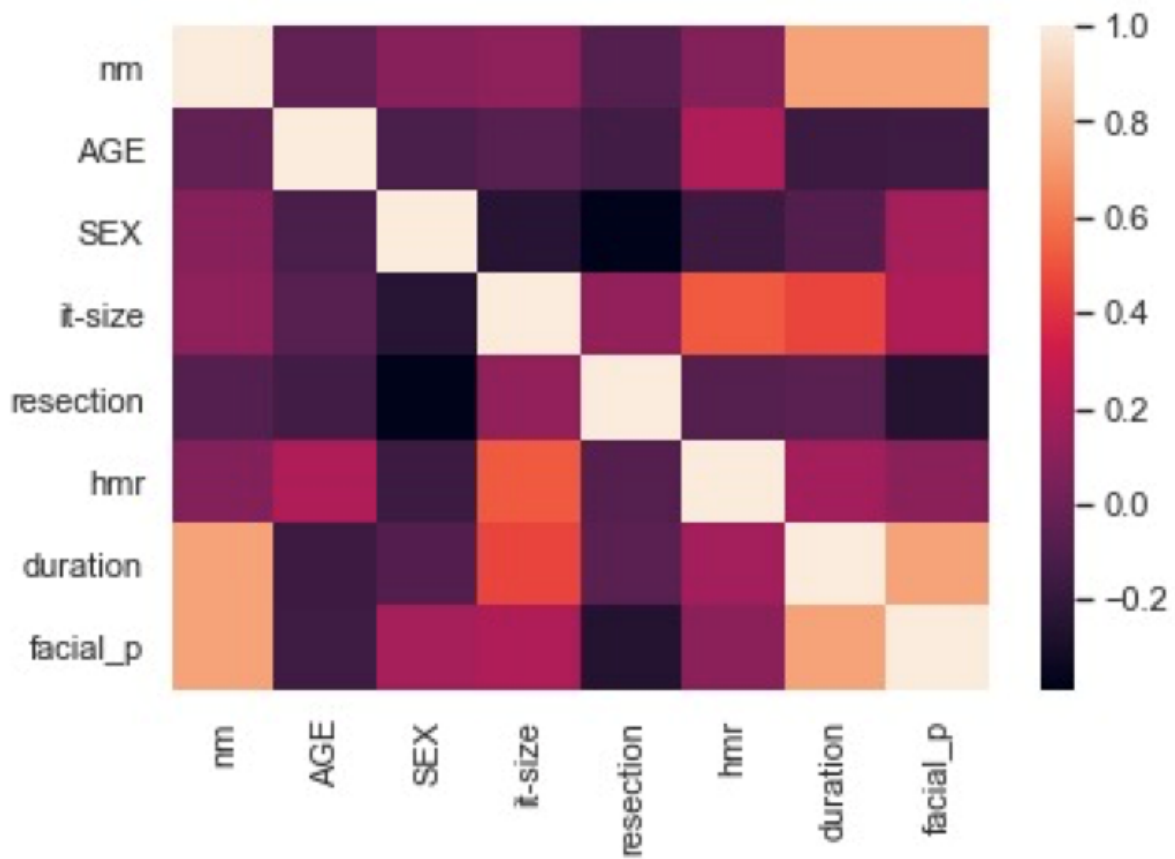


Figure 1: Python diagram of all results which shows the neuromonitoring impact on facial paresis (HB score). * hmr: hemorrhage; it-size: initial tumor size; resection: type of resection; duration: duration of operation; facial_p: facial paresis (Good HB score).

Table 1: Extent of tumor resection rate

	With Neuromonitoring	Without Neuromonitoring	Good HB	Poor HB
GTR	78.9	37.5	75.0	27.3
STR	21.1	50	20.8	63.6
PR	0.0	12.5	4.2	9.1
P value		0.036		0.014

Table 2: Group statistics of sample t-test for evaluation of the effect of the duration of operation on HB score

	neuromonitoring	N	Mean	Std. Deviation	Std. Error Mean
Duration	yes	19	86.8947	14.23179	3.26500
	no	16	124.5000	20.55562	5.13890

Monopolar is mainly used to first map the surface of the tumor, and assess the nerve sheath and the surroundings in greater scales. It works with greater stimulation voltage (11). We preferred using bipolar to configure the tumor-surrounded part of the facial nerve, especially in split facial nerve cases. Bipolar is more specific than monopolar for nerve distinction and also checking the motor part of the

nerve is working.

Although, we could not use bipolar for a long time because it can cause heat and thermal injury. Few studies have been done in this regard.

SSEP is evaluated and recorded throughout the whole surgery. In case of any significant change in SSEP, MEP is also recorded. MEP is recorded at regular intervals as well.



Table 3: Sample t-test for evaluation of the effect of the duration of operation on HB score

Independent Sam- ples Test		Levene's Test for Equality of Variances				t-test for Equality of Means				
		F	Sig.	t	df	Sig. (2-tailed)	Mean Dif- ference	Std. Error Differ- ence	95% Confidence Interval of the Difference	
									Lower	Upper
Duration	Equal variances assumed	1.518	.227	-6.372	33	.000	-37.60526	5.90185	-49.61266	-
	Equal variances not assumed			-6.177	26.021	.000	-37.60526	6.08839	-50.11965	25.59786

Table 4: Group statistics for evaluation of intraoperative neuromonitoring effects on HB score

Group Statistics					
	HB	N	Mean	Std. Deviation	Std. Error Mean
Duration	1.00	24	93.5000	19.24216	3.92779
	2.00	11	127.1818	22.78955	6.87131

Table 5: Sample t-test for evaluation of intraoperative neuromonitoring effects on HB score

Independent Sam- ples Test		Levene's Test for Equality of Variances				t-test for Equality of Means				
		F	Sig.	t	df	Sig. (2-tailed)	Mean Dif- ference	Std. Error Differ- ence	95% Confidence Interval of the Difference	
									Lower	Upper
Duration	Equal variances assumed	.305	.584	-4.538	33	.000	-33.68182	7.42144	-48.78085	-
	Equal variances not assumed			-4.256	16.822	.001	-33.68182	7.91470	-50.39385	18.58279

In this study, we benefit from the cooperation of a neuro-physiologist with Cerebellopontine Angle (CPA) knowledge and surgical site anatomy, brain stem and cranial nerve, and their relationship with vestibular schwannoma (12,13).

Whilst, real-time access to the operation's video via the microscope's camera was provided.

If there were nerve stimulation recorded in constant neuromonitoring, the probability of nerve injury was evaluated considering the following matters:

1. Comparison of tumor retraction/surgical manipulations site with the probable anatomical location of facial nerve through watching a real-time video of the surgery
2. Nerve stimulation of possible location of nerve injury by a neuromonitoring probe to evaluate MEP.

In some cases, tumor dissection from the brain stem accompanies stimulation of cranial nerve nuclei. Discrimination

of the stimulation and nerve injury is not distinct-able normally. So, the surgeon verifies by MEP alteration (descending pattern) and surgical anatomy and then decides on continuing the surgery.

3. Results

In this study, 35 patients with vestibular schwannoma underwent resection. Included 18 females and 17 males. The mean age was 52.8 in this study. Patients were divided into 2 groups of cases (i.e., intraoperative facial nerve neuromonitoring applied): 19 patients, and control: 16 patients. We compared the two groups with respect to sex, age, duration of operation, initial tumor size, surgical resection, hemorrhage volume, and facial nerve outcome regarding the intraoperative neuromonitoring application. Facial nerve outcome is assessed with the House-Brackmann grading system, which

is well known, i.e., grade 1st HB is the best outcome, and the 6th grade is complete paralysis of the nerve. A good level HB score is defined as 1, 2, and 3 while HB scores of 4 and 5 are defined as poor.

In this study as affording neuromonitoring is dependent on the patient and one's financial status and the hospital cannot afford to perform all the operations with neuromonitoring, dividing patients into two groups were without bias and the study was double-blinded.

3.1. Demographics

All demographic data were registered. The two groups were not significant in the matter of sex and age. Demographics had no significant effect on HB grading (Age P value 0.136, Sex P value 0.088).

3.2. Initial tumor size

We provided a simple t test on initial tumor size and its effect on house Brackmann grade for facial nerve outcome, which was not significant. The initial mean tumor size in Group 1 was 33.5 (SD=8.50), and in Group 2, it was 33.3 (SD=8.44, P value 0.952).

3.3. Facial Nerve Anatomical preservation

We could perform anatomical preservation of facial nerves in 31 patients. FN anatomical preservation rate in the neuromonitoring group was 100% and in the control group, it was 75%.

3.4. The extent of tumor resection

The surgery aimed to resect the whole tumor along with saving the facial nerve. So, the resection continued to the facial nerve sheath until the nerve capsule was safe. The extent of tumor resection was divided into 3 groups based on the neurosurgeon's judgment and the post-op MRI. GTR is defined by the neurosurgeon intraoperatively or by the MRI performed 1-3 months post-op which both MRIs revealed no residual tumors. Subtotal resection, there is a small portion of the tumor remaining, and the post-op MRI revealed a little contrast-enhancing area. Partial resection is defined as the situation when a large portion of the tumor could not be resected. The rate of GTR in patients operated on using neuromonitoring was 78.9%. The rate of STR and PR in procedures without neuromonitoring was 50.0% and 12.5% respectively. The P-value was 0.036 which was significant. The GTR rate was 75.0% indicating a good level of House-Brackman grading for facial paresis (grades 1, 2, and 3). STR and PR rate in poor HB grade (4, 5) was 72.7% (for both??) (P=0.014, Table 1).

3.5. Duration of operation

We used t test to evaluate the duration of the operation's effect on the HB score. It had a significant effect. In 62.5% of the patients with good HB grading, the duration of surgery was less than 100 minutes. Also, 81.8% of the patients with poor HB grades had an operation duration of more than 120 minutes. As the time of surgery decreases the facial paresis grading improves (P<0.001).

It is good to notice that the surgeon's expertise and skills are also involved in this regard. We performed all the operations with one sole skilled neurosurgeon to lower this kind of bias (Tables 2 and 3).

3.6. Hemorrhage during operation

We measured Hemorrhage during the operation and performed a simple t test and no significant effects were found on facial paresis grading (P=0.574).

3.7. Intraoperative neuromonitoring

In 100% of the patients with intraoperative neuromonitoring (case group), the HB level was evaluated as good. 68.8% of the patients without neuromonitoring (control group) had poor HB (P<0.001). Also, in 79.2% of patients with good HB, intraoperative neuromonitoring was applied. In all patients with poor HB, neuromonitoring was not used (P<0.001, Tables 4 and 5, Figure 1).

4. Discussion

Facial nerve function conservation is one of the main goals of VS surgery because of its effect on the patient's quality of life (2,3,14). The advantages of using neuromonitoring intraoperatively in vestibular schwannoma surgery is proven previously (2,15). Our results in Tehran, Shohada Tajrish Hospital are quite consistent with the literature while we report our 10-year experience in video-assisted intraoperative neuromonitoring in an Iranian tertiary neurosurgical center. Initial tumor size and the hemorrhage did not have any effect on neuromonitoring and facial nerve function. Using intraoperative video-assisted neuromonitoring with a trained neurophysiologist can reduce the duration of the operation and can increase the HB score for facial nerve function. It can help the surgeon increase the ratio of the gross total resection of the tumor with preservation of the function of the seventh cranial nerve (2).

Recent use of intraoperative nerve monitoring technologies led to higher GTR rates and preservation of facial nerve function. If VS surgery is neuromonitoring assisted, the surgeon can reach GTR with a higher calmness and self-esteem.

In surgical microscope monitoring along with the neuromonitoring method, a non-trained neurophysiologist (not educated on anatomical basis) any alterations in SSEP re-



duces the surgeon's risk-taking in the resection of the tumor because of possible cranial nerve injury. A trained neurophysiologist with access to the surgical site with the surgical microscope via microscope screen monitor can distinguish and indicate brain stem retraction signals, stimulation of other nerves, and facial nerve injury impulses.

Here in this paper, we are going to discuss less-talked issues in literature. One is the important role of the neuromonitoring provider/technician in the surgery. It is believed that as much as the surgeon's interference regarding accuracy and excellency of the neuromonitoring (due to education in neuroanatomy) is continuous, the better result of the surgery is obtained. On the other hand, since the main responsibility of the surgeon is to excel in performing the surgical technique, we recommend neuromonitoring technician education based on nerve anatomy and physiology and also, his/her observation of the surgical field via a monitor.

Our study was performed with the cooperation of a neurophysiologist with CPA anatomy education, the position of cranial nerves, and their relationship with vestibular schwannoma. To evaluate the efficacy of trained neurophysiologists in facial nerve monitoring, a comparison to the studies with non-trained neuromonitoring technicians is needed. However, it is not ethical to use untrained neurophysiologists in surgeries, comparison between two groups of untrained and trained neurophysiologists is impossible.

We think it is good for the surgeon to comprehend the neuromonitoring and the wave patterns and alarming changes in waves, etc., but we do not agree that the surgeon should perform all the work for several reasons. First, if we assign many tasks to one person, the performance efficacy could decrease. Also, when the surgeon is busy performing the precise surgery, it would be hard to consider all the aspects of various subjects and a moment of undesired neglect could injure the nerve. We want to emphasize that no monitoring is better than poor neuromonitoring.³ Some references suggested vocal double checks of the neuromonitoring patterns with the surgeon could be beneficial. This matter is straight concerning efficient comprehension of neurosurgical anatomy and the process of ongoing surgery. Since the anatomic place of the 5th and 7th cranial nerves is close, it is important to that the technician be trained to distinguish the two nerves and inform the surgeon. We suggest a real-time video-assisted protocol of milestones in the surgery process in which the surgeon could check the waves and also the technician could stay updated during the surgery and tumor debulking steps while the technician is fixed by the screen of the neuromonitoring monitor and surgical microscope's monitor, both. Milestones of checking the tumor surface, scan for split facial nerve, nerve sheath surroundings, approximating proximal and especially distal part of the nerve. In the matter of tumor removal steps, we suggest debulking

the main tumor body, then the residual around the nerve sheath which needs the most concentration, and continuous neuromonitoring and multiple monitor checks by both surgeon and technician.

It is also important to note that during electrocautery, nerve monitoring is disabled because of the production of high-intensity electrical artifacts which can hide the EMG activity. So, the debulking procedure should progress slowly with multiple checking.

With respect to operation duration, our surgeries were quite short because of the surgeon's expertise, in long surgeries of CPA it has been suggested to involve more than one technician who can reposition on definite milestones and prevent technician boredom and neglect from looking fixedly to the monitor.

Intraoperative neuromonitoring for VS resection is inevitable. So, the profound knowledge of techniques and interpretation of nerve monitoring in addition to a comprehensive understanding of neuroanatomy and the facial nerve surroundings in VS surgery is needed to avoid poor neuromonitoring which is worse than no monitoring (3) and puts patients at risk for morbidities (2). In 2012, Kircher and colleagues suggested that the operating surgeon should better learn the technical and interpretive aspects of nerve monitoring to be able to provide real-time modification in surgery. Since, during electrocautery, nerve monitoring is disabled due to high-intensity electrical artifact production, which can hide the EMG activity.

It is important to mention that the position of the cranial nerves 7 and 8 in the auditory channel is approximate, which is critical, especially in tumor resection of the distal part of the tumor (intracanalicular). To have better results in nerve preservation, we must avoid any delays in nerve recognition. So, we recommend using cranial nerve 8 SSEP to predict cranial nerve 7 MEP. We postulate since SSEP is more real-time; MEP changes that need nerve stimulation can be recognized faster.

Also, in some cases, cranial nerve 7 (facial nerve) is misinterpreted with cranial nerve 5 which misleads the surgeon to have enough confidence to continue the resection. Some cases with these issues are when the facial nerve is split, mostly in large tumors. The narrow part of the facial nerve is surrounded by the tumor and EMG signals misinterpret with the Trigeminal nerve. The trigeminal nerve is responsible for the sensation of the face and injury to this nerve may cause an interruption in touch, temperature, and a painful feeling of the face. Using cranial nerve 8 SSEP to predict cranial nerve 7 MEP would also be useful in this regard.

5. Conclusion

The benefit of IONM in vestibular schwannoma surgery is to increase anatomical nerve preservation rate and facial nerve function outcome. The value of coordination of anatomically trained neurophysiologists is to avoid and lower any delay in nerve recognition which has more importance in complex cases.

6. Appendix

6.1. Acknowledgment

The data collected for this study was from the patients who were willing to participate in this research study and gave informed written consent. Since there is no data registry for this information in Iran, all data is collected and documented by the authors mentioned, personally. We can send data to the journal, or we can authorize private access to this data via a private link by request.

6.2. Conflict of interest

The authors declare no conflict of interest to declare. The authors certify that they and their family members have NO affiliations with or involvement in any organization or entity with any financial interest (such as honoraria; educational grants; participation in speakers' bureaus; membership, employment, consultancies, stock ownership, or other equity interest; and expert testimony or patent-licensing arrangements), or non-financial interest (such as personal or professional relationships, affiliations, knowledge or beliefs) in the subject matter or materials discussed in this manuscript. The authors have no conflict of interest to declare.

6.3. Funding support

This research received no specific grant or funding from any funding agency in the public, commercial, or not-for-profit sectors.

6.4. Author's contributions

Mohammadreza Shahmohamadi designed the study concept and performed theoretical research, performed the surgeries, revised the neuromonitoring process, and wrote the first draft of the manuscript. Sara Zandpazandi, the corresponding author collected the data, documented the information, performed the statistical analysis and critically revised the first draft of the manuscript, and wrote the final draft. Faranak Behnaz did patient selection and preparation, performed anesthesia, and wrote the first draft of the manuscript.

References

- Greene J, Al-Dhahir MA. Acoustic Neuroma. InStatPearls [Internet] 2022 Jun 4. StatPearls Publishing.
- Starnoni D, Giammattei L, Cossu G, Link MJ, Roche PH, Chacko AG, Ohata K, Samii M, Suri A, Bruneau M, Cornelius JF. Surgical management for large vestibular schwannomas: a systematic review, meta-analysis, and consensus statement on behalf of the EANS skull base section. *Acta neurochirurgica*. 2020 Nov;162:2595-617.
- Li X, Bao Y, Liang J, Chen G, Guo H, Li M. Electrophysiological mapping and assessment of facial nerve functioning during acoustic neuroma operations. *Annals of Translational Medicine*. 2021 Mar;9(5).
- Monfared A, Corrales CE, Theodosopoulos PV, Blevins NH, Oghalai JS, Selesnick SH, Lee H, Gurgel RK, Hansen MR, Nelson RF, Gantz BJ. Facial nerve outcome and tumor control rate as a function of degree of resection in treatment of large acoustic neuromas: preliminary report of the Acoustic Neuroma Subtotal Resection Study (ANSRS). *Neurosurgery*. 2016 Aug 1;79(2):194-203.
- Huang X, Xu J, Xu M, Chen M, Ji K, Ren J, Zhong P. Functional outcome and complications after the microsurgical removal of giant vestibular schwannomas via the retrosigmoid approach: a retrospective review of 16-year experience in a single hospital. *BMC neurology*. 2017 Dec;17(1):1-9.
- Matsushima K, Kohno M, Sakamoto H, Ichimasu N, Nakajima N. Intraoperative continuous neuromonitoring for vestibular schwannoma surgery: real-time, quantitative, and functional evaluation. *World Neurosurgery*. 2022 Feb 1;158:189.
- Olson JJ, Kalkanis SN, Ryken TC. Congress of neurological surgeons systematic review and evidence-based guidelines on the treatment of adults with vestibular schwannomas: executive summary. *Neurosurgery*. 2018 Feb 1;82(2):129-34.
- Bhimrao SK, Le TN, Dong CC, Makarenko S, Wongprasartsuk S, Westerberg BD, Akagami R. Role of facial nerve motor-evoked potential ratio in predicting facial nerve function in vestibular schwannoma surgery both immediate and at 1 year. *Otology & Neurotology*. 2016 Sep 1;37(8):1162-7.
- Liu SW, Jiang W, Zhang HQ, Li XP, Wan XY, Emmanuel B, Shu K, Chen JC, Chen J, Lei T. Intraoperative neuromonitoring for removal of large vestibular schwannoma: facial nerve outcome and predictive factors. *Clinical neurology and neurosurgery*. 2015 Jun 1;133: 83-9.
- Ling M, Tao X, Ma S, Yang X, Liu L, Fan X, Jia G, Qiao H. Predictive value of intraoperative facial motor evoked potentials in vestibular schwannoma surgery under 2 anesthesia protocols. *World Neurosurgery*. 2018 Mar



1;111: e267-76.

11. Husain AM, editor. A practical approach to neurophysiologic intraoperative monitoring. Demos Medical Publishing; 2014 Dec 11. 12. Tatagiba M, Roser F, Schuhmann MU, Ebner FH. Vestibular schwannoma surgery via the retrosigmoid transmeatal approach. *Acta neurochirurgica*. 2014 Feb;156:421-5.

13. Aref M, Kunigelis K, Cass SP, Youssef AS. Retrosigmoid approach for vestibular schwannoma. *Journal of Neurological Surgery Part B: Skull Base*. 2019 Jun;80(S 03):S271-.

14. Link MJ, Lund-Johansen M, Lohse CM, Driscoll CL,

Myrseth E, Tveiten OV, Carlson ML. Quality of life in patients with vestibular schwannomas following gross total or less than gross total microsurgical resection: should we be taking the entire tumor out?. *Neurosurgery*. 2018 Apr 1;82(4):541-7.

15. Bloch O, Sughrue ME, Kaur R, Kane AJ, Rutkowski MJ, Kaur G, Yang I, Pitts LH, Parsa AT. Factors associated with preservation of facial nerve function after surgical resection of vestibular schwannoma. *Journal of neuro-oncology*. 2011 Apr;102:281-6.