

Comparative anatomy of the forelimb veins in humans and non-human primates

Thesis submitted in accordance with the requirements of the University of Liverpool for the degree of Doctor in Philosophy by Rajani Thiranagama.

September 1986

Comparative anatomy of the forelimb veins in humans and non-human primates

Rajani Thiranagama

The forelimb venous system is one of the least investigated areas of primate anatomy, and has been considered to be too variable to be used for systematic studies. It has also been suggested, and traditionally accepted, that the human limb (especially hind limb) venous system is specially adapted to posture and locomotion. This study investigated the forelimb venous system in a selection of primates from all major taxonomic groups. Both macroscopic and microscopic methods were used to investigate the morphology of anatomical structures including the superficial, deep, and perforating veins and the venous valves.

In all primates examined the adult anatomy was studied, while in humans both embryos and foetuses were also studied. A quantitative description of morphology was attempted wherever possible. The distribution of character states of the superficial venous system was analysed using the pattern of phylogenetic relationships established by published molecular studies. The polarity of characters was determined using both the outgroup and ontogenetic arguments. The pattern of veins for the various groups of primates was established.

The African great apes, Pongo and humans each presented a distinct pattern of homologous structures. The primitive pattern for the primates as a whole, for anthropoids, for hominoids and for the African ape/human clade were inferred. The number of perforating veins was shown to correlate allometrically with arm length (surrogate for overall body size) within the primates. The density distribution and the constancy and position of the human forelimb perforating veins was also established. The number of valves in the primate superficial veins were shown to correlate with the length of vein rather than an overall size dimension (the length of the arm). The valve index of Vankov was found to be an appropriate measure of the density of valves within the primates.

When establishing character distributions the ontogenetic evidence proved crucial. The human superficial veins, which presented a suite of primitive characters, were hypothesised to reflect a heterochronic process of retardation, and it was argued that heterochrony is a process that has possibly affected the morphological evolution of other structures in the human forelimb. The hypothesis of the specialisations of the limb venous system for posture was challenged by the findings in this study.

ACKNOWLEDGEMENTS

First of all I want to thank my supervisor Professor Bernard Wood who with tolerance endeavoured, and I hope succeeded, in giving me the inspiration to see beyond traditional descriptive anatomy and to tackle modern concepts in comparative biology. To him, and especially to Alison Wood, I also owe something greater than a thank you as they are friends who have supported me through these difficult years as a lone woman in an alien land.

I am grateful to Professor J. Peggington for permission to dissect specimens in the Department of Anatomy, University College, London, and I am indebted to Dr Audrey Smith and the staff at the Department of Anatomy, Alder Hey Children's Hospital, without whose help one of the most important sections of my study could not have been achieved. My thanks are due to Dr. Wilson for translating at length from articles written in the German language. The assistance of Dr Sissons and his colleagues in the Department of Pathology, University of Liverpool is gratefully acknowledged. Members of staff in the Department of Anthropology, University College London, at the Department of Anatomy, The Royal Free Hospital Medical School, and at the Zoological Societies of London and the North of England (Chester) were most generous in donating primate specimens. My thanks are also due to the technical staff of the Anatomy Departments of The Middlesex Hospital Medical School, University College London and the University of Liverpool. I would like to make a special mention of Ted Joughin without whose help histology would have been a mere dream

and Raymond Burniston whose willing help with the wet specimens, made the life in the mortuary easier. Ken Walters and Julian Fletcher helped with the photographs.

Most of all I want to acknowledge the support given by all my women friends for whom my achievement was their vindication. Words cannot express the tremendous support and the strength offered by my dearest friend Amrit Wilson in my continual fight to prove that a black woman can do it against all odds. I owe much of my knowledge and most of the confidence in the ideas I am handling to my friend Andrew Chamberlain. The long hours of discussion and argument from Darwin to Hennig and his eloquent defence of numbers as expression of form in almost Pythagorean fervour impelled me to explore many concepts and make them part of myself. Knowing my frustrations and rebellion against what I perceived as the oppressive nature of western scientific tradition he brought to my notice the alternative trends and made it possible for me to articulate scientifically my own ideas. Last, but not least, I remember my people's immeasurable suffering, my sister's courage and the loneliness of those who light the 'fires on the mountains': they constantly remind me of my duties.

Table of Contents

	<u>Page</u>
Abstract	2
Acknowledgements	3
Table of Contents	5
Chapter 1: Introduction	6
Chapter 2: Gross Morphology: Main Veins, Perforators and Valves	14
Chapter 3: Gross Morphology: Ontogeny of Main Veins	74
Chapter 4: Phylogenetic Inferences	120
Chapter 5: Functional Hypotheses	143
Chapter 6: Conclusions	154
Tables	160
References	170

CHAPTER 1: INTRODUCTION

The venous system of the extremities is one of the least researched topics of both human and comparative primate anatomy. In comparison with the forelimb, the hind limb has been relatively better researched. This discrepancy highlights a significant bias in human anatomical studies for the majority of the anatomical studies of the hindlimb veins in humans concern the anatomy related to the clinically-important condition of varicose veins. Therefore, it is not surprising that the forelimb veins, in which disease is rare, have received rather less attention. There is, however, a current reawakening of interest in human forelimb venous anatomy that stems in part from recent advances in plastic and vascular surgery.

If human anatomists have not been impelled by any clinical attraction towards further investigation of the forelimb veins, comparative morphologists and functional anatomists also seem to have neglected these structures. There has been a regrettable tendency to view the forelimb venous system as an inferior structural copy of that of the hind limb. This view, and the belief that the forelimb veins are very variable, has apparently justified the notion that the forelimb venous structures lack adaptive significance. This, together with the lack of clinical interest, perhaps explains why scientific investigation of the forelimb venous system has made slow progress.

Any attempt to study such a supposedly variable system as forelimb veins must be carried out in a comparative context. The apparent lack of specialisation in the primate forelimb, which perhaps might

have acted to dissuade the functional morphologist from proceeding further, is paradoxically an incentive for the student whose primary interest lies in the phylogenetic history of a structure, rather than in its adaptive significance. As Darwin argued, in retracing history we must look for imperfections and oddities, because any perfection in organic design or ecology obliterates the paths of history. Putting the human system in its comparative context, to show the evolutionary trends in design and organisation, has the potential to provide a valuable phylogenetic insight. Such a quest is infrequent in the human anatomical literature, in contrast to its greater importance for zoologists and primatologists.

A central concept used in this study is that of homology, and it is necessary to present, as clearly as possible, contemporary ideas on this single most important concept in comparative morphology.

Homology

The recognition of the existence of homology is the basic premise under which organisms are made comparable. Biologists, however, differ in their definition and usage of this important concept: to some workers homology means essential structural correspondence, regardless of how such similarity has arisen while to others it is only structural similarity due to common ancestry that deserves to be called homology. More recent authors have sought to define homology cladistically, and to equate homology with synapomorphy: the sharing of derived characters (the term 'character' is used here, and subsequently, to refer to a structure of an organism, in any or all

of its possible homologous versions, each of which can be regarded as a 'character state').

Patterson (1982a) has argued that although there are a number of ways of defining homology (classical, evolutionary, phenetic, cladistic and utilitarian), in practice the cladistic definition is the most appropriate and can encompass all the other definitions. Cladistically, homology is defined on the basis of monophyly: homologous features are those which characterise a monophyly, and monophyletic groups are those containing all, and only, the descendants of a common ancestor (Patterson, 1982a). Therefore monophyly is defined by common ancestry, and homology is in turn defined in terms of monophyly. Patterson further argued that homologies are synapomorphies, and that as a byproduct of his definition there are also homologies which are symplesiomorphies. Symplesiomorphies are synapomorphies of a larger group which stands in hierarchic relation to the group under study.

If we follow Patterson (1982a) in adopting a cladistic definition of homology, how do we recognise such homologies? First, it is crucial to be able to distinguish homology from homoplasy, i.e. from similarities which can be mistaken for homologies. Homoplasies arise from parallelism and convergence. Patterson proposed three tests of homology: any putative homology must pass the tests of 'similarity', 'conjunction' and 'congruence' (the latter term 'congruence' is equivalent to the concept of 'consistency' as used by many phylogenetic systematists). The test of similarity, that the features should resemble each other (topographically, histologically,

ontogenetically etc.), is shown by Patterson to have low resolving power between homology and non-homology. The second test of homology is called the conjunction test. This test rejects characters as homologous features of two organisms if the characters can be shown to occur together ('conjunction') in one organism. The third and most reliable of Patterson's tests is that of congruence. The test of congruence is based on the fact that since homologies are characters only of monophylies, it follows that a test of the homology of a feature or character would be to demonstrate consistency with other homologies or synapomorphies. This latter test primarily exemplifies the axiom order versus disorder: conflicts between homologies (where, for example, two sets of homologies support different patterns of relationships) can be resolved by criteria such as maximum likelihood, or that of parsimony.

The above tests of homology allow a distinction to be made between characters which might have been products of convergent or of parallel evolution. Convergent characters fail both the similarity and congruence tests, because the apparent similarity of such characters does not stand up to detailed scrutiny (failing the similarity test) and such characters also conflict with other homologies (failing the congruence test). Parallelisms pass the similarity test (their similarity is 'true' similarity, inherited from a common ancestor) but they fail the congruence test, and are thus rejected in this analysis as homologies only because they are incongruent with other characters and thus do not characterise a monophyletic group.

Patterson distinguished a further group of characters which he called 'homonomies'. These homonomies are 'anatomical plurals' (Riedl, 1979) that characterise mass or multiple homologies: examples include red blood cells and DNA, which occur as multiple entities in any one organism. Although homonomies may pass the tests of similarity and congruence and may be used to define monophyletic groups (as in the case of phylogenies based on DNA comparisons) homonomies, according to Patterson, fail the conjunction test. However, such failure is apparent rather than real because the aim of the test of conjunction is to prevent homologies being proposed between different parts of two organisms: failure of the test of conjunction is the finding that two versions of a feature, hypothesised as homologous between two organisms, are in fact present together (as separate features) in one organism. The test of conjunction presupposes that one can distinguish between the proposed homologues, and insofar as homonomies are indistinguishable within any given organism they should not be considered as failing the test of conjunction. Patterson also included in this category serial homologies, which he regarded at best as untestable homonomies.

Therefore according to Patterson's definition a feature, or character, can only be considered homologous between two organisms if it passes the similarity and the congruence tests, and if the two homologous versions of the character do not occur together (in 'conjunction') within the same organism.

In the present study, in which evidence from ontogenetic series and adults, from a wide range of primates and non-primate mammals, forms

the data base, it is important to observe the criteria of homology carefully. Le Gros Clark (1959), in his definition of primates, states that primates are characterised by the preservation of generalised limb structure with primitive mammalian pentadactyly. In embryonic studies the fore- and the hind limb have been considered serially homologous (Hochstetter, 1891; Lewis, 1905) and veins in the fore- and hind limb were shown and described as such. Geddes (1912), however, contested the generally accepted theory of serial homology in which the preaxial and postaxial borders of the fore- and hind limb were regarded as serially homologous. Geddes proposed that the limbs were actually mirror images of each other so that, for example, the thumb is homologous to the little toe.

In modern texts the latter view is hardly referred to, and the serial homology concept is generally accepted. However, this serial homology should not be regarded as implying that the fore- and the hind limb of the primates are similar, in the sense that true homologies are similar (see above). Martin, in his recent taxonomic definition of primates, emphasised the following shared derived character complex: "the grasping foot, tarsifulcrumation, elongation of the distal segment of the calcaneum and hindlimb domination together constitute a complex of locomotor features unique to primates among the living placental mammals" (Martin, 1986 p.11). Martin's definition implies that the primate hindlimb has a unique history, and by implication that these hindlimb structures are important homologies found in all primates. This point is underlined here as a note of caution when one considers serially homologous structures.

For example, in a recent review of homology by Roth (1984) it was argued that the fore- and hind limbs of many tetrapods are "strongly homologous" and that their development proceeds by a single set of developmental controls. The experimental embryological evidence that she cites in support of this 'strong homology', however, is precisely where one sees, at an early stage of development, the unique specialisations of the individual fore- and hind limb structures (true homology). Roth considered the differences in the numbers of digits between the fore- and hind limbs of an animal (occurring in many groups of animals) to be non-homologies: according to Roth the strength of the homology between the two limbs is measured solely by the degree of developmental similarity. Such a measure of homology ignores any consideration of the uniqueness of structures like the hand or the digits, which are among the earliest structures to differentiate in the primates, and emphasises instead an aspect of developmental control that is symplesiomorphous (primitive for mammals, or even for tetrapods).

The 'strength' of such serial homologies is basically the similarity in design and perhaps the possession of a single central control for developing. Geddes (1912) drew attention to design in drawing analogies between the developing tetrapod limb and a hypothetical mechanical construction. He likened the proximal portion of the limb to a three pronged grapple attached to the body wall, while its distal growth added a terminal piece (rod-like or plate-like), secondarily differentiated into digits. Further rod-like connections develop linking these two structures. The use of serially homologous

structures as true homologies seems to rest on arbitrary decisions on what is strongly and weakly homologous and arguments for and against could always be put forward. I find, contra Roth, that Patterson's definition is more objective and therefore more useful. The fore- and hind limbs are different versions of a pentadactyl tetrapod limb structure found in the same organism: however "useful" their similarity is, they are homonomies and not homologies.

While recognizing the constraints, these definitions made it straightforward to establish comparisons between the veins of different primates, and between the different ontogenetic stages within primates. Both macroscopy and simple microscopic methods were used to obtain anatomical information. Quantification was attempted wherever possible, in order to bring objectivity and clarity to an area hitherto considered too variable for worthwhile systematic research. In this study, phylogenetic analysis of the characters was undertaken without making any a priori functional assumptions. Functional hypotheses were examined after the evolution of the characters had been defined, and function was inferred as an aspect of design, or as the correlate of overall size both within, and between, different animal types.

CHAPTER 2: GROSS MORPHOLOGY: MAIN VEINS, PERFORATORS AND VALVESMAIN VENOUS CHANNELS

LITERATURE REVIEW.

It is a well-established practice, both in teaching and research, to consider the veins of the extremities of primates as belonging to two groups, or systems: superficial and deep. These two systems are defined in relation to the deep fascia of the limbs, and they are considered to be connected by a system of perforating veins which pierce through the deep fascia.

Superficial venous system

Human (Figure 2.1)

The superficial venous system of humans comprises autonomous veins, in contrast to the deep veins which usually accompany arteries and which are frequently paired (as venae comitantes). Though earlier anatomists used a complicated nomenclature, the current view is to consider the superficial venous system of the forelimb as having two main veins and a complex network of connecting superficial veins. The two main veins are the cephalic, on the lateral side, and the basilic on the medial side. A third vein (the median vein of the forearm) is frequently mentioned, though this is not as constant and

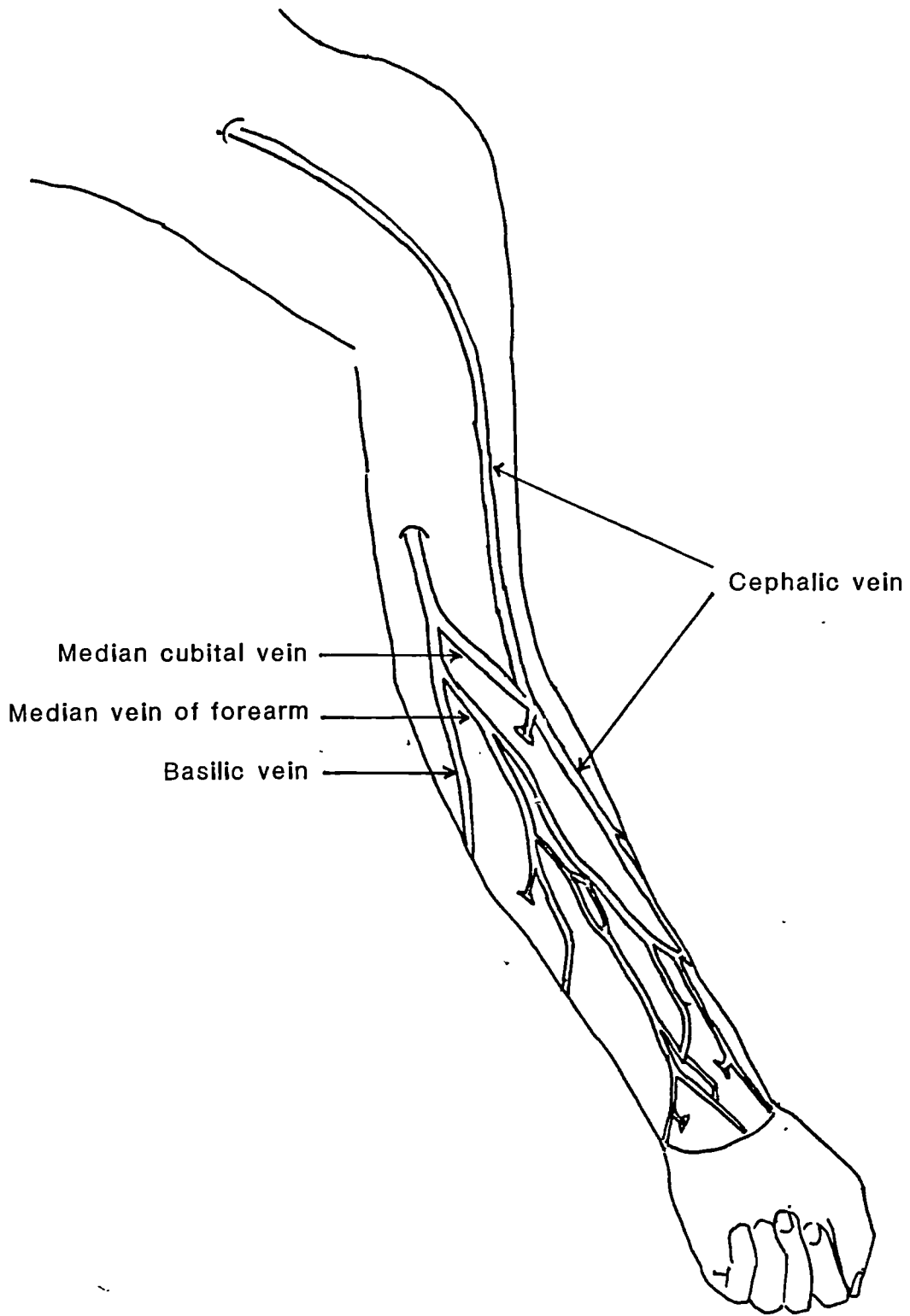


Figure 2.1

well- defined as the other two.

The classical description of the cephalic vein, found in anatomy textbooks, states that it originates on the radial side of the dorsal venous network as the vein that drains the thumb, then runs proximally along the radial side of the forearm. In its course it becomes more anteromedial, moving almost to the middle of the cubital fossa. From there onwards it ascends along the lateral border of the upper arm (usually the lateral border of the biceps brachii, a good landmark). In the upper part of the upper arm it lies in the deltopectoral groove, from where it runs into the infraclavicular fossa. Turning medially it pierces the clavipectoral fascia and opens into the axillary vein. In the cubital fossa it has a tributary, the median cubital vein, connecting it with the medial vein (basilic).

The basilic vein begins in the dorsal venous network of the hand. It ascends along the ulnar border of the dorsum of the forearm for about two thirds of its course in the forearm and then inclines anteriorly to reach the medial side of the tendon of the biceps brachii. At the middle of the upper arm it pierces the deep fascia and continues upwards along the medial side of the brachial artery to the axilla, where it becomes the axillary vein.

The median vein of the forearm, when it is present, begins in the the palmar venous plexus and runs to the the cubital fossa, where it may join the median cubital vein or it may divide into median cephalic and median basilic veins which join the main cephalic or basilic

veins respectively.

Apart from the description found in the textbooks of anatomy, the morphology of the main veins have not been studied in any great detail. Kakkar (1969) proposed that the cephalic vein could be used as an alternative to the saphenous vein in bypass surgery. Kakkar's brief description of the cephalic vein is similar to the description above, except that Kakkar does not describe the upper arm portion of the cephalic. Several authors have investigated the use of arm veins in bypass surgery (Stipa, 1971; Dardik & Dardik, 1974; Clayson et al 1976; Campbell et al 1979; Graham and Lusby, 1982; Schulman and Badhey, 1982), but these studies have assumed the conventional description of the morphology of the cephalic and basilic veins.

The only major challenge to this description comes from Bardeleben (1880a) and Bouchet et al (1973). Furthermore, a different nomenclature has been used on the Continent. Bouchet et al restrict the name 'cephalic' to the upper arm portion of the lateral vein, and refer to the forearm part as the 'accessory radial vein' (Bouchet et al 1973). Bardeleben, the German anatomist of late 19th century, studied human foetuses and concluded that there is only one main superficial vein (Figure 2.2), termed 'vena capitalis brachii', to which all other forearm veins are tributaries. The major vein, according to Bardeleben, is that which drains the radial side of the dorsal venous network ('cephalica pollicis' and 'vena salvatella') and ascends along the radial border of the forearm. As it ascends it becomes more anteromedial and comes to lie almost in the middle of the cubital fossa. It continues onwards on the medial side of the

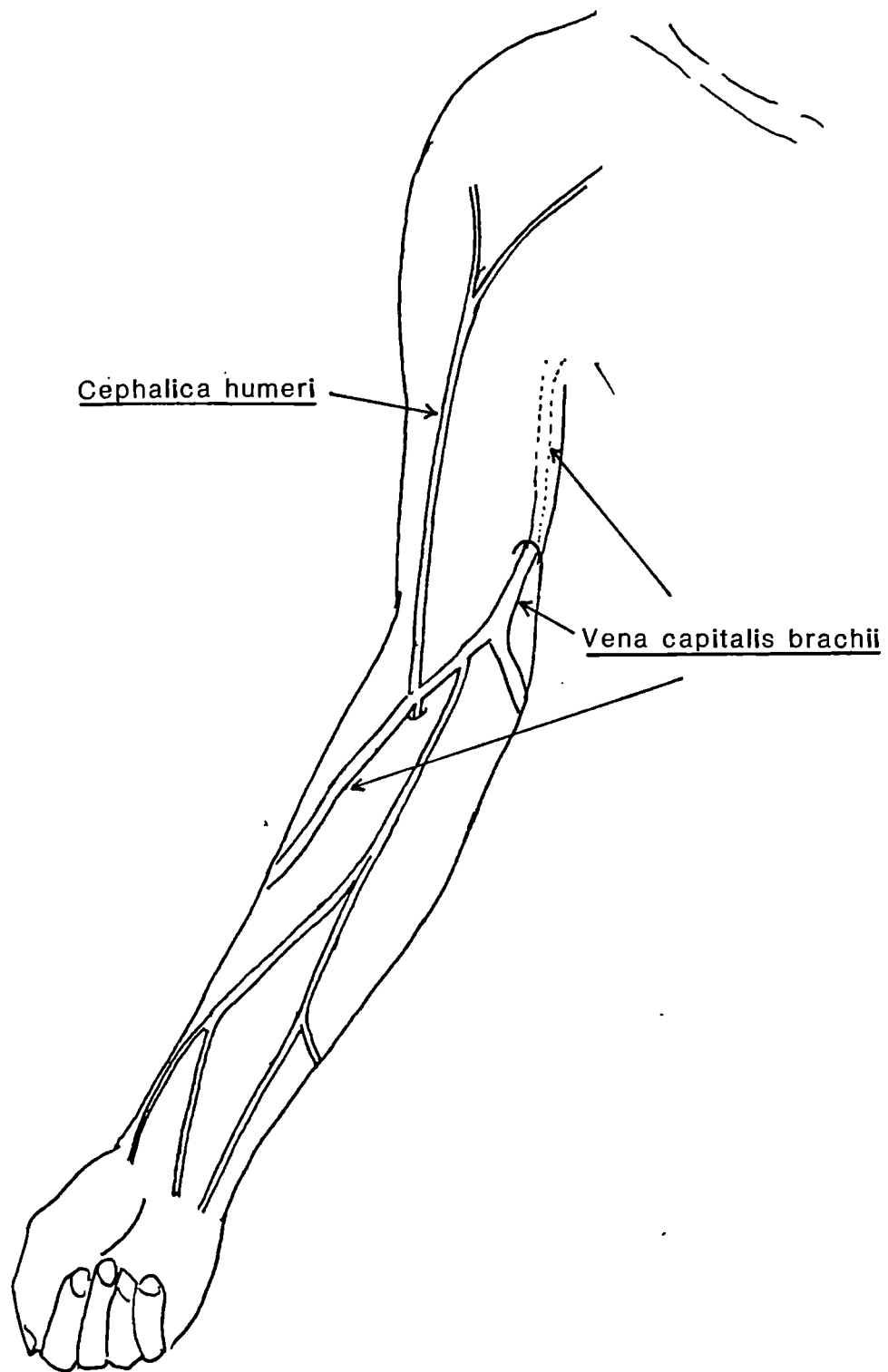


Figure 2.2

upper arm to the axilla and finally joins the external jugular vein in the base of the neck.

A study of the form of the proximal part of the cephalic (Bouchet et al 1973) found it to be variable and in six out of fifty six arms dissected the proximal part was absent. In another two arms only the axillary portion was found. Singh et al (1982), in a study of tourniquet application to 400 living arms in Nigerians, found 20 per cent of the arms had no upper arm part of the cephalic. Bouchet et al (1973) also described considerable variation in the calibre of the different parts of the lateral venous system.

Non-human primates.

In non-human primates there are no studies which concentrate on the venous system and most of our information comes from brief comments made as part of descriptive accounts of the anatomy of the whole animal. For the prosimian Nycticebus (slow loris) Davies (1947) describes the superficial venous system as consisting of the cephalic and its tributaries. Davies describes the origin and the course of the cephalic in the fore- and upper arm as similar to that in the modern human. Furthermore, he noted a strongly developed channel at the cubital fossa connecting the cephalic with the radial rete mirabile (deep veins). Davies also described a communication with the external jugular from the cephalic before the latter's termination in the axillary vein. On the ulnar side of the limb he noted the absence of the basilic and observed that the ulnar side of

the deep venous arch drains by a oblique vein into the cephalic. Woollard (1925) described a reversed pattern in Tarsius, i.e. the presence of the basilic and absence of the cephalic.

There are no accounts of the venous system of the forelimb in ceboid (New World) monkeys, although Beattie (1927) commented that the forelimb veins in the common marmoset correspond to the "general primate pattern". There is slightly more information about the Old World monkeys. In Papio Swindler and Wood (1973) describe the superficial venous drainage as consisting of the cephalic vein, with no basilic being found. The course of the cephalic is similar to that of humans, running from the radial side of the dorsal venous network to the clavipectoral fascia, perforating it and opening into the axillary vein. Moreover they describe a median cubital vein from the deep vein in the cubital fossa region to the cephalic. In his studies of Semnopithecus, Ayer (1948) described a long cephalic vein, the lack of a basilic and a communication with the deep veins in the cubital fossa from the cephalic above the elbow. Ayer also described the termination of the Semnopithecus cephalic into the external jugular. There are contradictory accounts of the forearm venous system in Macaca. Hill (1974) described a long cephalic running from the dorsal venous arch to the clavipectoral fascia and an absent, or at least a very small, basilic as well as a median cubital vein of considerable calibre. Linebeck (1933) described both autonomous channels, i.e. cephalic and basilic.

In Pan the cephalic is described as being short (Sonntag, 1923;

Swindler and Wood, 1973). It is said to originate from the dorsal venous network on the radial side, and then to wind round the radial side of the forearm to the anterior, or volar side, and course up to the cubital fossa on the radial side, becoming more anteromedial proximally. No basilic was found. A median antebrachial vein was also described by Swindler and Wood in Pan. In his dissection of one Gorilla, Raven (1950) described a similar pattern to that of Pan.

Deep venous system

Human

The deep veins are those that lie beneath the deep fascia and are usually paired and accompany arteries. The only unpaired vein is the axillary, the others are the venae comitantes of the brachial, radial, ulnar arteries and their branches. The brachial venae comitantes join the deep portion of the basilic before it becomes the axillary. The radial and the ulnar venae comitantes drain the superficial and the deep palmar arch veins and unite in the depths of the cubital fossa to form the brachial venae comitantes (Williams and Warwick, 1980).

Non-human primates

There is very little information on the deep veins of non-human primates, but as they are usually considered to be companions of the arteries it is relevant to review what is known of the the arterial

pattern in these animals. Manners-Smith (1910 a & b), in an extensive review of the arterial system in primates, named the main arteries in the upper arm as the axillary, and the deep and superficial brachial (brachialis superficialis and brachialis profundus). Note that the use of the adjectival term 'superficial' does not correspond to the way in which the term 'superficial' is used in describing the veins: in the arteries the 'superficial' brachial artery is within the deep fascia and the term 'superficial' describes the artery's location in relation to the median nerve. In the forearm the main arteries are the radial and ulnar.

Manners-Smith (1910a) discusses at length the origins of the major branches like the profunda brachii and circumflex humeri, but the present description will be confined to recounting the pattern of the main arteries only. The two brachial arteries are defined in relation to the median nerve. The brachial artery, which is crossed by the median nerve superficially, is referred to as the brachialis or the brachialis profundus. The apes have a single brachial artery in the upper arm, but it crosses the median nerve superficially, and is thus considered by Manners-Smith as the brachialis superficialis. Among cebids and cercopithicoids both brachial arteries are usually present. These animals only differ in the level at which brachialis superficialis is given off. A similar pattern is seen in the prosimians, the two arteries being well defined even if there is a rete mirabile as occurs in Nycticebus.

In the forearm in all primates for which there is information the main arteries are the radial and ulnar. The radial is the direct

continuation of the brachialis superficialis (in those animals which possess it), while the ulnar and the common interosseous are the continuation of the brachialis profundus. In the apes the single superficial brachial artery gives rise to both ulnar and radial, while in humans the single brachial which lies deep to the median nerve gives rise to both.

Published accounts of the deep venous system in non-human primates are confined to descriptions of the apes. Sonntag (1923) describes a single brachial vein in the upper arm in Pan, while in his discussion of Pongo he described a paired brachial vein (Sonntag, 1924). Raven (1950) described brachial venae comitantes in Gorilla. In the latter account the medial of the two accompanying veins is the larger of the two and is called the brachial vein.

Forelimb venous drainage in non-primates.

Nickel, Schummer and Seiferle (1981) investigated a range of domestic animals (cat, dog, pig, goat, sheep, ox, horse) and described the vena cephalica as a subcutaneous vein. It begins on the radial side of the forelimb on its anterior or flexor aspect, and more proximally it runs in the lateral thoracic groove to drain into the external jugular. Its important tributaries include the vena cephalica accessoria, which drains the dorsal digital veins; in the cat this vein communicates with the dorsal branch of the vena ulnaris (a deep branch). The other tributary of note is the vena mediana cubiti which is given off near the elbow, and runs medially through the deep

fascia to join the brachial vein. The vena cephalica at the distal end (i.e. carpal end) communicates with, or originates from, the deep radial vein. These veins are autonomous. There is no basilic vein.

Bouchet et al (1973), who studied 16 dog forelimbs, stated that the cephalic vein is the main superficial vein in these animals. They claimed that the vena mediana, a tributary from the cephalic at the elbow, is the homologue of the human basilic. The vein which they described, however, resembles the vena mediana cubiti which would be a more reasonable homologue of the human median cubital vein than of the human basilic.

The deep venous pattern of domestic mammals is thus as follows: an axillary vein, vena brachialis (paired), vena mediana (paired), and vena radialis (paired). The vena ulnaris is only found in the cat and the dog. The vena brachialis is the continuation of the vena mediana of the forearm. The vena brachialis receives the vena brachialis superficialis, vena transversa cubiti and vena interossea communis (Nickel, Schummer and Seiferle, 1981).

MATERIALS

Previous studies have made a general morphological distinction between the superficial, deep and the perforating systems of veins. This tripartite division of venous drainage of the forelimb was used as the basic plan for the dissections and the morphometric data were recorded according to this scheme.

Human

Fifty one human upper limbs were dissected: all, apart from two which were from different individuals, were the right and left limbs of the same individuals. The specimens were from adult Caucasian cadavers, prepared for anatomy classes in British medical schools. All specimens, apart from six dismembered limbs, were of known sex (Table 2.1)

In the 51 limbs the superficial venous system was carefully exposed and stylised diagrams were used to record the extent, course and position of the various components of this system. In eleven out of the 51 limbs the deep venous system was also dissected.

Non human primates

Sixty three forelimbs from 16 primate genera were dissected (Table 2.2). A similar procedure to that adopted for the human limbs was used. The deep venous system was documented in at least one limb of each genus except for Papio and Macaca, in which four limbs each were dissected.

RESULTS

Superficial venous system

Human

The superficial venous system consisted of two main venous channels, one on the lateral side, the cephalic, and the one on the medial side, the basilic. There is a complex and variable network of connecting veins between these two channels.

In all of the 51 limbs the medial, or basilic vein, was present (Figure 2.3 a-d, vein M). The basilic had a constant origin from the ulnar side of the dorsal venous network. It then passed along the ulnar side of the distal part of the forearm, either on the posterior surface or along the ulnar border, and passed to the anterior aspect of the proximal forearm near the elbow. From here it traveled along the medial border of the upper arm, or the medial border of the biceps brachii, and pierced the deep fascia midway along the upper arm. Here it left the superficial system but continued on the medial side of the brachial artery and became the axillary vein.

Two major types of lateral, or cephalic vein, were found (Table 2.3); in this description they are called 'long' (designated LL) and 'short' (designated LS). In the majority of cases (39 out of 51, or 76%) a 'long' vein (LL) was found, and it is described as follows (Figure 2.3a, vein LL). The 'long' vein originated on the lateral side of the dorsal venous network or arch, also draining the veins of the thumb. It passed proximally along the lateral border of the

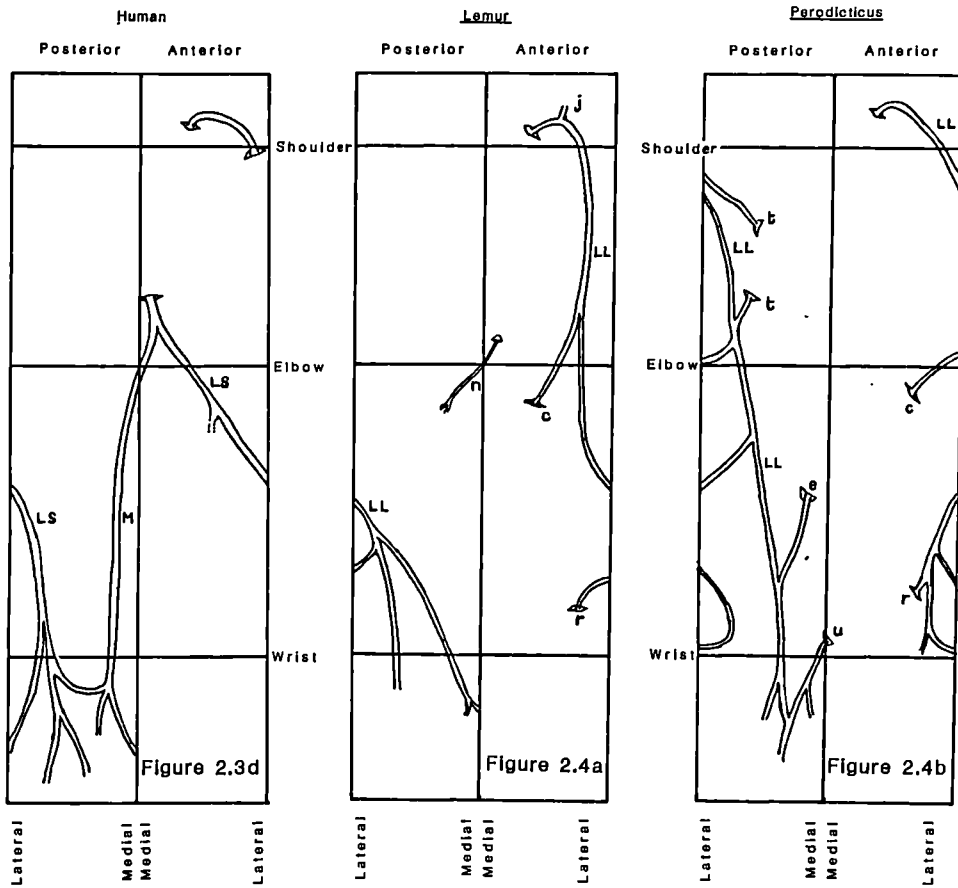
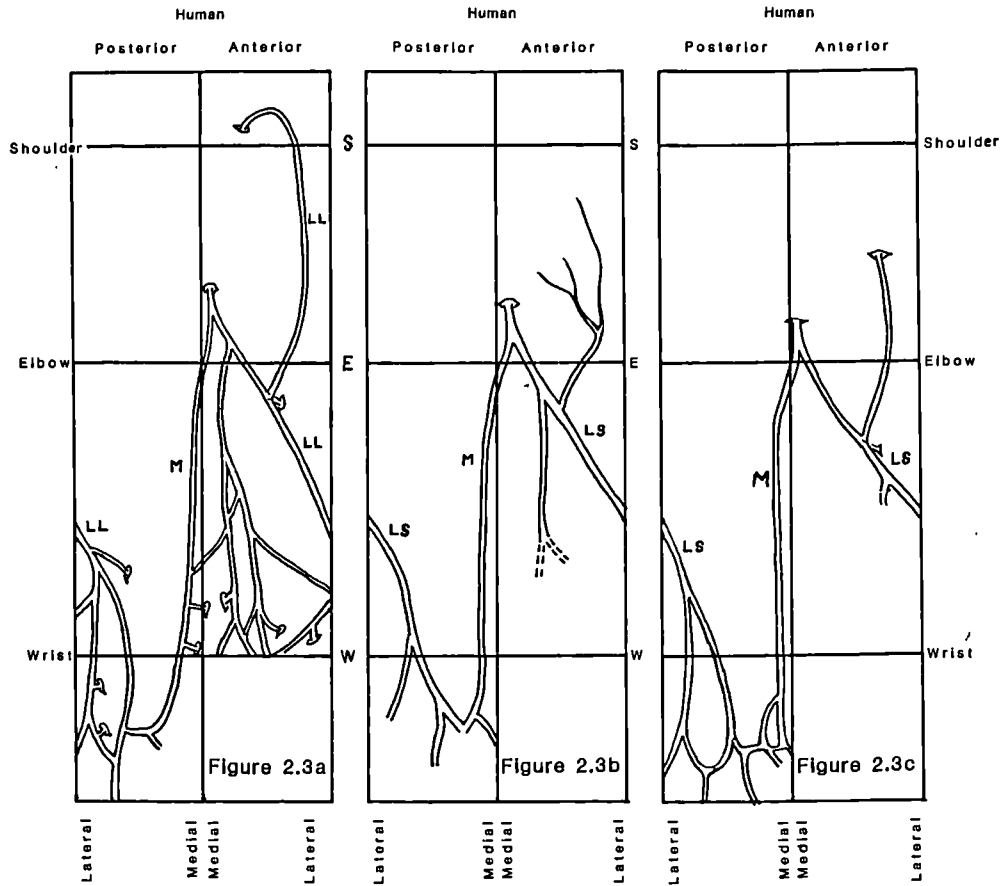
Key to Figures 2.3-2.10 and 2.17

Main superficial venous channels in primate forelimbs. These maps are a stylised representation reduced to two dimensions and scaled to unit shoulder-wrist length. Each map can be visualised as a 'wraparound' view of the arm with skin removed.

LL Long Lateral Vein

LS Short Lateral Vein

M Medial Vein



distal forearm and then passed more anteromedially in the proximal part of the forearm, achieving the middle of the limb at the cubital fossa. It passed along the anterolateral border of the upper arm or along the lateral edge of biceps brachii, and thereafter lay in the deltopectoral groove. It ended by piercing the clavipectoral fascia and entering the axillary vein.

In the second, or 'short' type (LS), the upper arm part of the cephalic was variable. In eight limbs the upper arm cephalic was absent and its place was taken by an ill-defined network of veins (Figure 2.3 b, vein LS). Of the other four limbs, in three the upper arm cephalic terminated in the brachial vein in the region of the deltoid (Figure 2.3 c, vein LS), and in one limb the cephalic was only found proximal to the deltopectoral groove (Figure 2.3 d, vein LS).

It should be noted that in the 'short' type, the origin and course of the cephalic vein in the forearm was similar to that of the 'long' type. Both types can occur within the same individual.

Non-human primates

Prosimians: Six limbs from three genera of prosimians were dissected, Lemur catta, Nycticebus coucang and Perodicticus. All three genera had a long lateral vein which originated on the lateral side of the dorsal venous arch, and then ascended on the lateral side of the fore- and upper arm (Figure 2.4 a & b, vein LL). In its course it

passed along the deltopectoral groove: the vein then terminated in the axillary vein by piercing the clavipectoral fascia in the infraclavicular fossa. Just before its termination it communicated with the external jugular vein, via a vein which ran superficial to the clavicle (Figure 2.4 a, vein j). The other well-developed connection of the lateral vein was in the region of the cubital fossa. This vein ran downwards and medially (except in one Potto limb in which it ran horizontally) from the lateral vein and pierced the deep fascia in the middle of the cubital fossa (Figure 2.4 a & b, vein c).

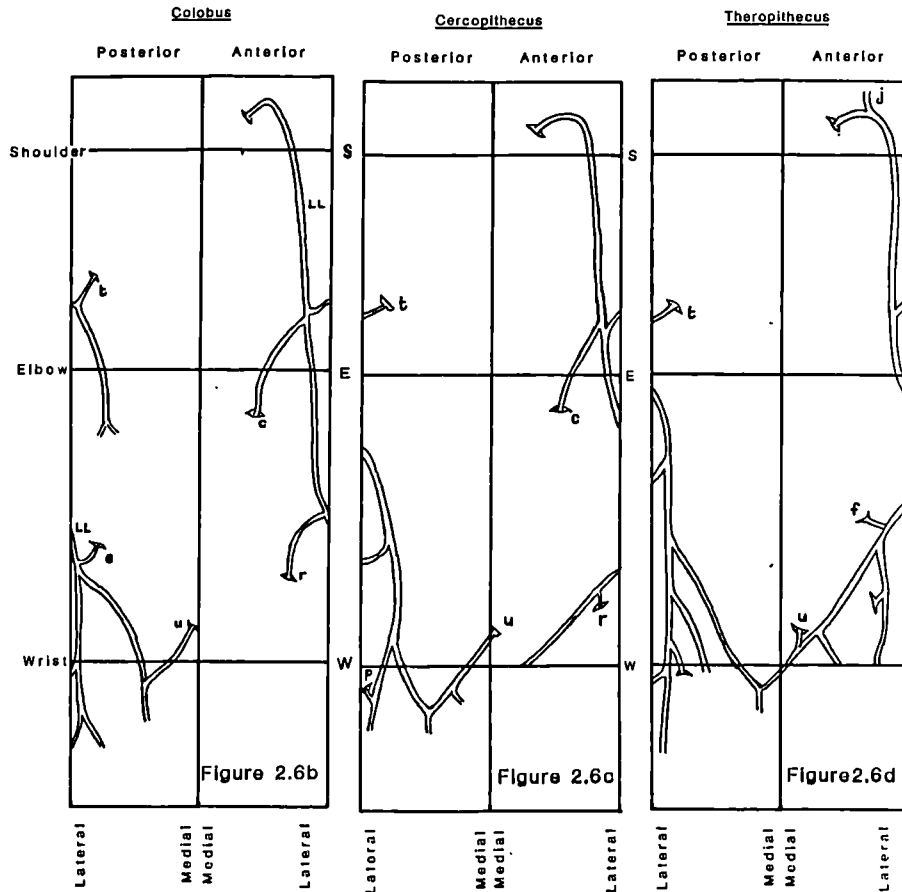
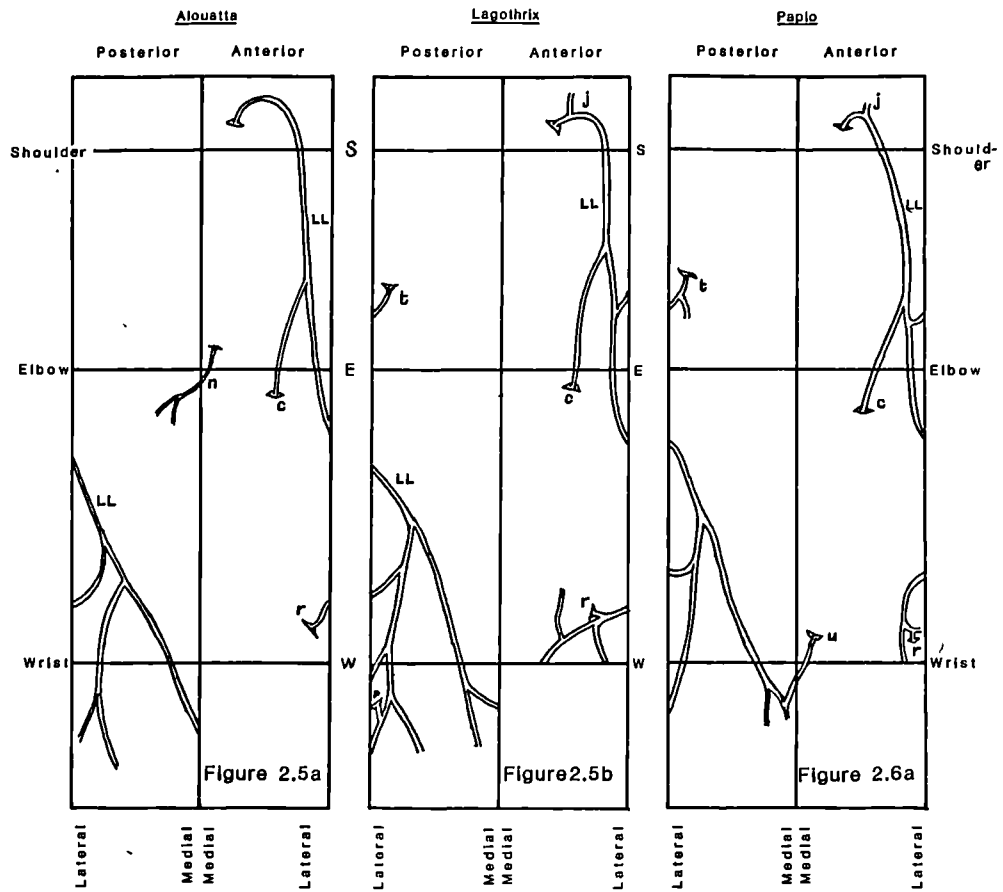
The medial side of the limb did not show any consistent superficial vein. Instead the medial side of the dorsal venous arch drained into the lateral vein. Moreover in Perodicticus there was a small perforating vein from the medial side of the dorsal venous arch connecting to the deep vein on the medial side near the wrist (Figure 2.4 b, vein u). In the two lemur forelimbs, on the medial side there was a small vein which originated from the posterior side of the proximal forearm, ascending anteromedially and piercing the deep fascia on the medial side of the upper arm (Figure 2.4 a, vein n).

The lateral vein in prosimians could, by its position, be considered to be homologous to the human cephalic vein. There is no equivalent homologue of the human basilic vein on the medial side of the prosimian forelimb.

Anthropoids

Ceboids: Seven limbs from three genera of ceboids were dissected: Alouatta caraya, Saimiri sciureus and Lagothrix lagothricha. All three genera had a long lateral vein (Figure 2.5 a & b, vein LL), draining the dorsal venous network, and then ascending dorsolaterally along the radial border of the forearm. This vein passed more anteriorly in the proximal part of the forearm and continued proximally to the upper arm along the anterolateral border. In the upper arm it ran along the lateral border upto the deltoid region. Then it coursed along the deltopectoral groove, turning medially to the infraclavicular fossa and there piercing the clavipectoral fascia to terminate in the axillary vein. In all limbs except a single Aloutta (088 right side) there was a vein which passed superficial to the clavicle connecting the lateral vein to the external jugular vein (Figure 2.5b, vein j). All specimens had a vein connecting the lateral vein to the deep veins in the region of the cubital fossa (Figure 2.5, vein c). On the medial side of the limb there was no well-defined venous channel. In Saimiri, and one Aloutta limb (088 right side) there was a small vein from the upper part of the posterior surface of the forearm, passing to the anteromedial side of the upper arm where it pierced the deep fascia and entered the deep veins (Figure 2.5a, vein n).

The lateral vein of ceboids is considered to be homologous to the human cephalic vein due to its anatomical disposition. No vein homologous to the human basilic vein was found.



Cercopithecoids: Thirty four limbs from six genera of cercopithecoids were dissected: Papio sp., Macaca fascicularis, Mandrillus sphinx, Theropithecus gelada, Cercopithecus sp. and Colobus guereza. All the limbs had a long lateral superficial venous channel (Figure 2.6 a-d, vein LL). It arose on the lateral side of the dorsal venous network, and ascended along the anterolateral border of the forearm and upper arm. In the distal part of the upper arm a connecting vein ran downwards and medially from the lateral vein, pierced the deep fascia in the middle of the cubital fossa and connected with the deep veins (Figure 2.6 a-c, vein c). In the proximal part of the upper arm the lateral vein ran in the deltopectoral groove. In Macaca, Papio, Theropithecus and one Cercopithecus limb (086 leftside) a tributary ran superficial to the clavicle and connected the terminal part of the long lateral vein to the external jugular vein (Figure 2.6 a & d, vein j). None of the limbs had a continuous venous channel on the medial side. The medial side of the dorsal venous network drained into the lateral vein by tributaries and by a perforating vein to the deep vein near the wrist (Figure 2.6 a-d, vein u).

In cercopithecoids, the lateral vein can be considered to be homologous to the human cephalic in its anatomical disposition; homologue of the human basilic vein was not found.

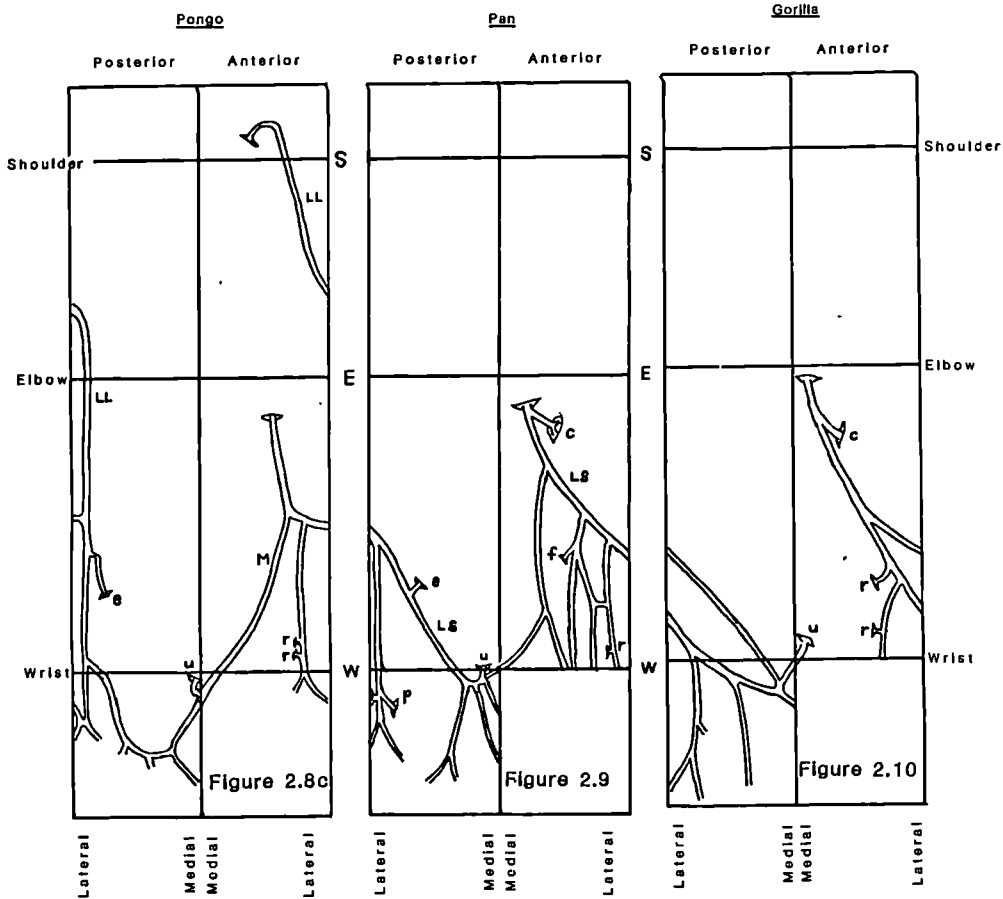
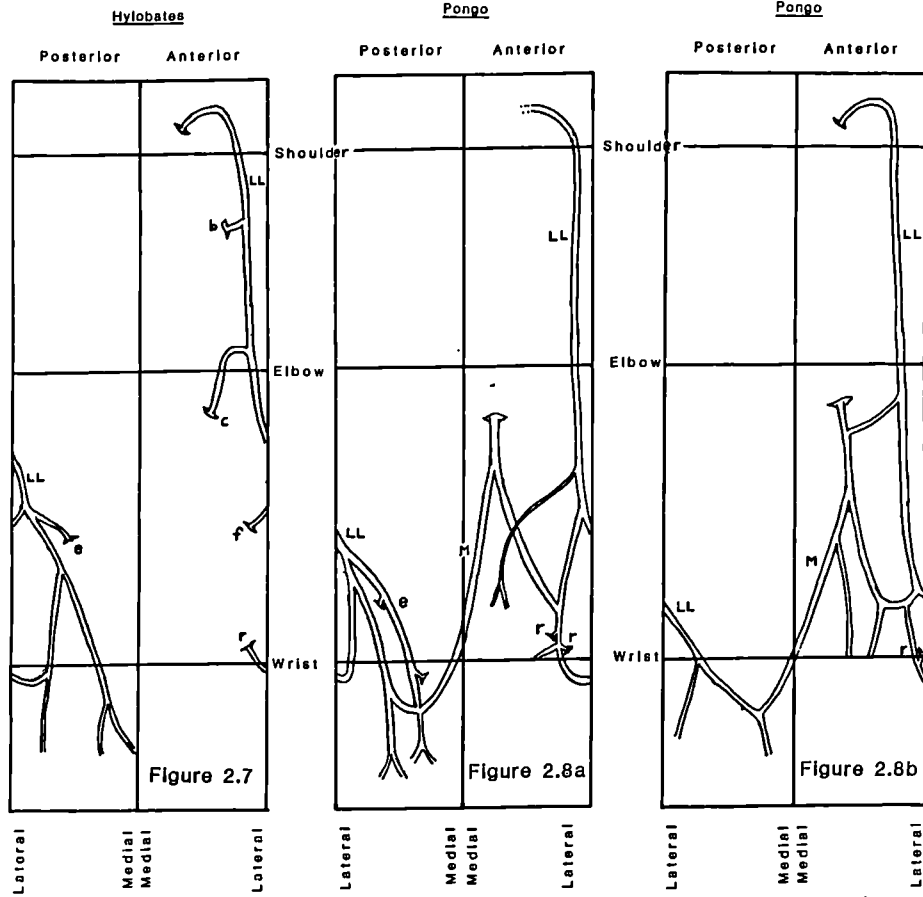
Hominoids

Hylobates sp.: Six upper limbs were dissected. In all the limbs there was a long lateral vein (Figure 2.7, vein LL). The lateral

vein originated on the radial side of the dorsal venous network and ascended along the anterolateral side of the fore- and upper arms. In the proximal part of the upper arm it lay in the deltopectoral groove, then turned medially to the infraclavicular fossa, pierced the clavipectoral fascia and terminated in the axillary vein. In three limbs (025 left, 024 both sides) the lateral vein had a connection with the external jugular. In all limbs there was a connecting vein from the lateral vein to the deep veins in the region of the cubital fossa (Figure 2.7, vein c). There was no medial channel. The medial side of the dorsal venous network drained to the lateral vein through tributaries.

The lateral vein of Hylobates can be considered homologous to the human cephalic vein in its anatomical disposition. No homologue of the human basilic vein could be found.

Pongo: One adult and three immature Pongo limbs were dissected. All had a long lateral vein (Figure 2.8 a-c, vein LL). The vein started on the lateral side of the dorsal venous network, ascended along the anterolateral side of the fore- and upper arm and came to lie in the deltopectoral groove in the proximal part. From here the vein turned medially to the infraclavicular fossa. In the immature limbs the vein terminated by piercing the clavipectoral fascia and opening into the axillary vein (in the adult, termination could not be traced because the specimen was damaged by previous dissection in the base of the neck region).



In all the limbs the medial side of the dorsal venous arch was drained by a well-developed medial channel, which terminated in the upper part of the forearm (cubital fossa region) by piercing the deep fascia (Figure 2.8 a-c, vein m). The immature limbs differed from the single adult limb only in the apparent by more lateral disposition of the medial vein. This difference may be attributed to the small size of the specimen.

In Pongo, the lateral vein can be considered homologous to the human cephalic vein, while the medial vein found in the limbs resemble the human basilic vein in its origin and course. Thus (see below) Pongo shows the only sign of the medial channel in the non-human primates.

Pan troglodytes: In all of the five limbs (adult) dissected the lateral vein was short, i.e only found in the forearm (Figure 2.9, vein LS). The upper arm lacked any major superficial veins. The lateral vein drained the radial side of the dorsal venous network, and passing over to the anterior side ran along the lateral border of the forearm. It ascended on the lateral side of the forearm, becoming more anteromedial in its proximal part. It terminated almost in the middle of the cubital fossa, by piercing the deep fascia. There was no vein on the medial side of the forearm, and the medial side of the dorsal venous network drains into the lateral vein via multiple tributaries and also a perforating vein (Figure 2.9, vein u) into the deep vein on the ulnar side.

Gorilla: Only a single adult limb was available for dissection: the venous pattern resembled that of Pan (Figure 2.10).

Deep venous system

Human (Figure 2.11 a)

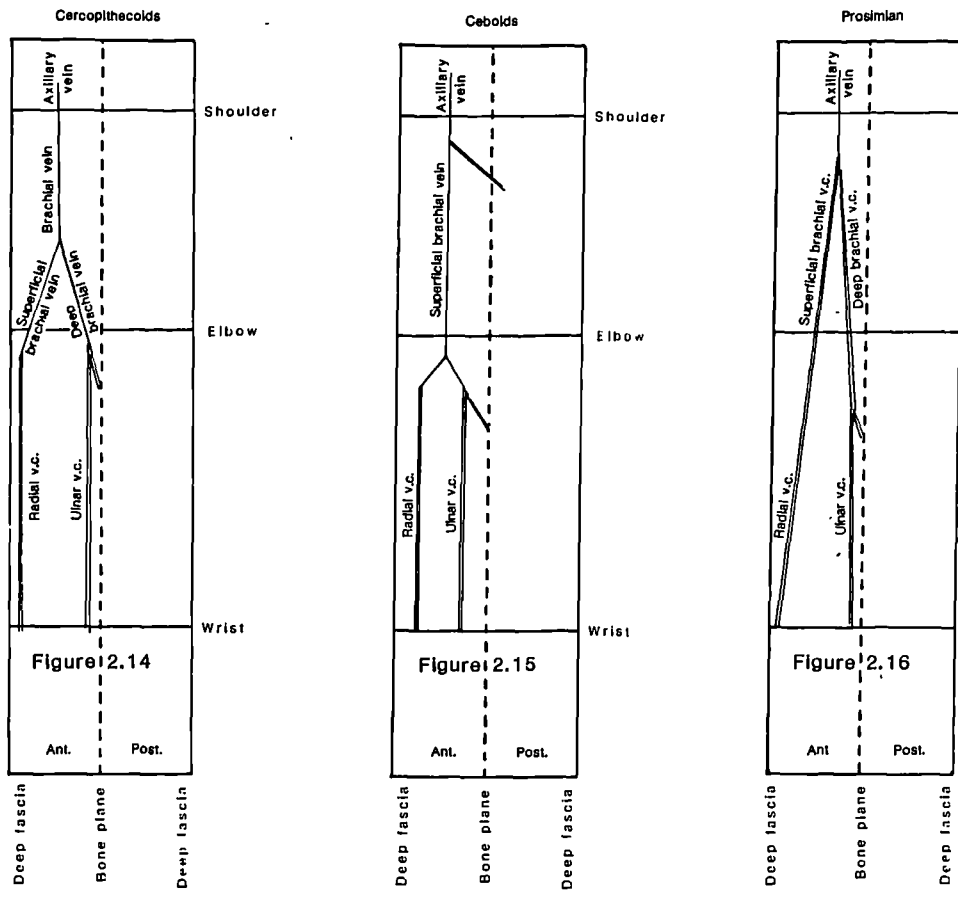
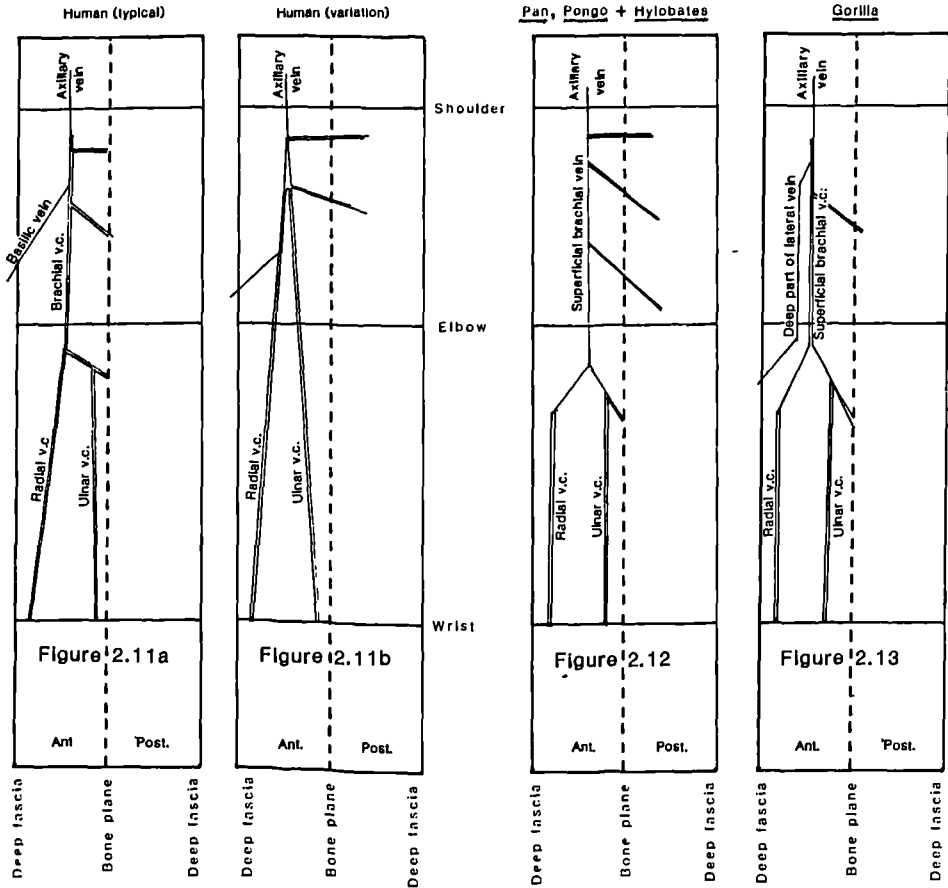
Eleven human upper limbs were dissected to observe the deep venous system. The axillary vein was the only unpaired vein: the other veins were paired venae comitantes of arteries. The axillary was the continuation of the deep part of the basilic vein and the brachial venae comitantes. The brachial venae comitantes were formed by the union of the radial and ulnar venae comitantes, in the depths of the cubital fossa. In the forearm the main veins were the radial venae comitantes and the ulnar venae comitantes. The ulnar venae comitantes received the veins accompanying the common interosseous artery. All the main veins received many muscular tributaries, as well as those veins which accompanied the branches of the major arteries.

In three out of eleven specimens there were two large arteries in the upper arm: these were the brachial artery and a large branch of the brachial artery which was superficial to the median nerve; the latter was given off just above the middle part of the upper arm. These two arteries had their accompanying veins. The basilic vein joined the veins accompanying the artery superficial to the median nerve (Figure

Key to Figures 2.11-2.16

Main deep venous channels in primate forelimbs. These maps depict the veins of the anterior compartment of the arm and the main entries to veins in the posterior compartment (the latter are tributaries of the former). The views are not 'wraparound' but show the connections of the deep veins and their relationships to the deep fascia and the bone plane.

v.c. Venae Comitantes



2.11 b). In the forearm the arterial pattern was 'classical'. However the radial artery was the direct continuation of the superficial branch of the brachial and the ulnar artery was the continuation of the brachial proper. Thus the radial venae comitantes continued directly as the veins accompanying the artery running superficial to the median nerve, while the ulnar venae comitantes continued as the veins accompanying the brachial artery proper. In the forearm the main veins are the radial vena comitantes and the ulnar vena comitantes.

Non-human primates

Hominoids: The upper arm had a variable pattern of main deep veins. There was a single vein accompanying the brachial artery which ran superficial to the median nerve in Hylobates, Pongo and Pan (Figure 2.12). This vein could be termed the superficial brachial vein, following Manners-Smith's nomenclature for the artery (note that, as in the arterial system described above, the term 'superficial' should not be confused with the same term used to describe veins external to the deep fascia, the superficial veins proper; here the defining relationship is with the median nerve). In Gorilla, apart from the venae comitantes of the superficial brachial artery, there was also the continuation of the lateral superficial vein after it passed from the superficial to deep systems in the cubital fossa in the distal part of the upper arm. This vein was large, and ran medial to the venae comitantes (Figure 2.13). In the forearm all specimens had radial venae comitantes and ulnar venae comitantes.

The hominoid deep veins received the veins accompanying arterial branches: in the upper arm these included the profunda brachii, circumflex humeral and the collateral ulnar, while in the forearm the ulnar venae comitantes received the veins accompanying the common interosseous artery. The radial and ulnar venae comitantes received the perforating veins as well. Also of note was the large perforator opening into the superficial brachial vein in the Hylobates specimens. There were also numerous muscular venous tributaries.

Cercopithecoids: In the forearm these animals had both radial and ulnar venae comitantes. In the upper arm there was the vein that accompanied the superficial brachial artery and the vein that accompanied the deep brachial artery. The superficial brachial vein was continuous with the the radial venae comitantes and the deep brachial vein was continuous with the the ulnar venae comitantes. The two brachial veins united around the middle part of the upper arm and gave rise to a single brachial vein which continued as the axillary vein (Figure 2.14).

These veins received the veins accompanying the major arterial branches (e.g. ulnar venae comitantes received those accompanying the common interosseous, the deep brachial the profunda brachialis). They also received numerous muscular branches. Moreover the radial venae comitantes received perforating veins, usually in the cubital and wrist region. In all specimens except Macaca the ulnar vena comitantes also received a perforating vein.

Ceboids: In the upper arm there was a superficial brachial vein and in the forearm, radial and ulnar venae comitantes. In the cubital fossa both pairs of venae comitantes fused to form two separate single veins and these veins subsequently joined and continued as the superficial brachial vein in the upper arm (Figure 2.15). The main deep veins in the upper and forearm, received the veins accompanying the major arterial branches and also numerous muscular veins. The radial vena comitantes also received the perforating veins in the cubital fossa and distal forearm.

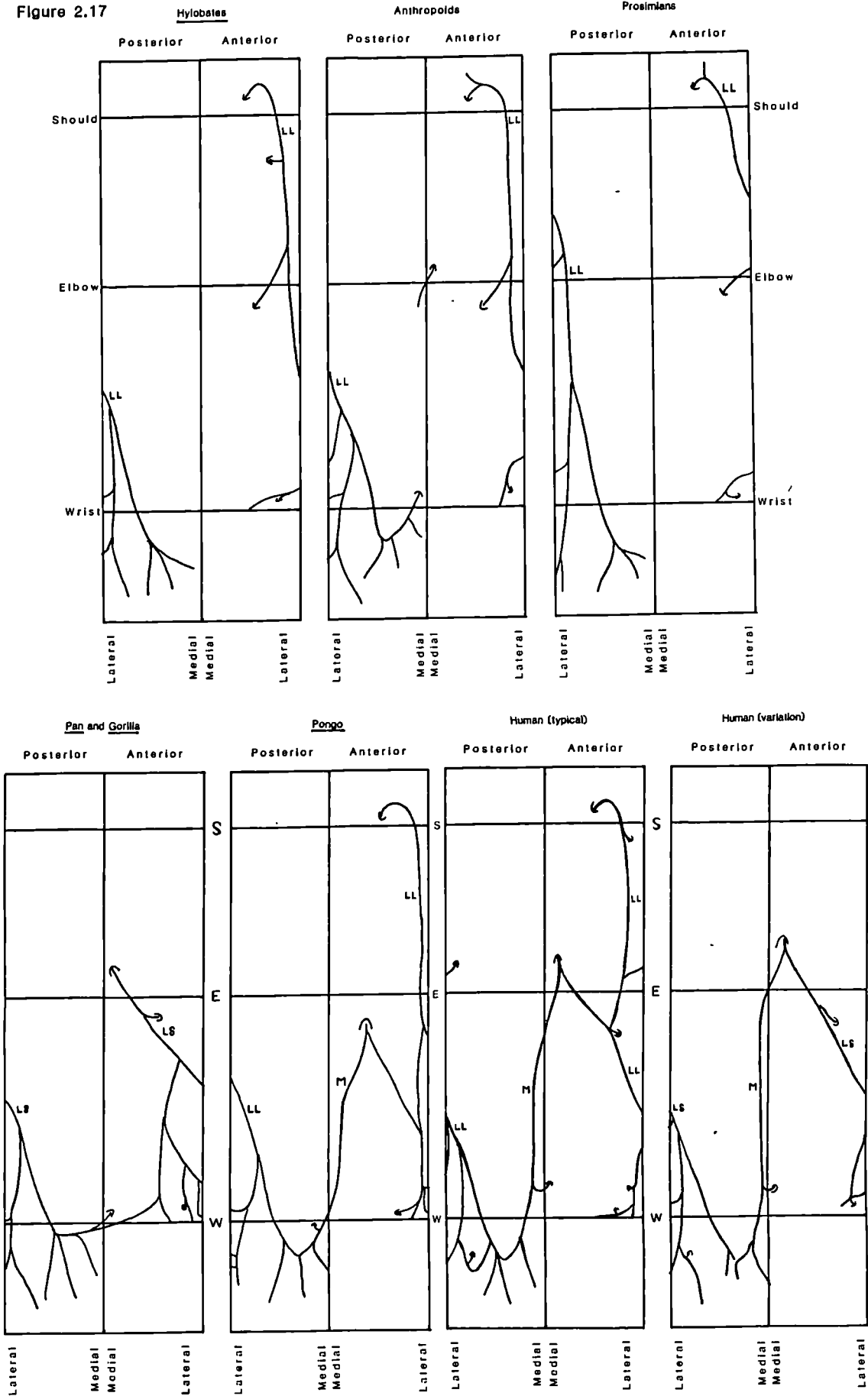
Prosimians: The only unpaired vein was the axillary. The axillary vein received the veins accompanying the branches of the axillary artery. In the upper arm there were the venae comitantes of the superficial brachial and the deep brachial arteries (Figure 2.16). In the forearm there were the radial and ulnar venae comitantes. The radial venae comitantes was continuous with the superficial brachial venae comitantes and the ulnar venae comitantes was continuous with the deep brachial venae comitantes.

These main venae comitantes received the veins accompanying the major arterial branches and also numerous muscular veins. The radial venae comitantes also received the perforating veins in the cubital fossa and the distal forearm.

Summary of results: (Figure 2.17)

The human superficial venous system consists of two autonomous main

Figure 2.17



veins, one on the lateral side of the limb and the other on the medial. The lateral vein presents in two ways. It is usually 'long' i.e. running from the carpal to the clavicular region (denoted lateral-long, LL). A minority are designated as 'short' (lateral-short, LS) and are well-defined only in the forearm. A medial vein is usually present in the forearm terminating in the middle or distal part of upper arm. In the non-human primates the lateral vein (except in Pan and Gorilla) is long(LL). Pan and Gorilla have a lateral vein only in the forearm (LS). A medial vein is not found in the non-human primates, except in Pongo.

The deep veins accompany the arteries and therefore reflect the some of the specific differences in arterial morphology found among the different primate taxa.

PERFORATING VEINS

LITERATURE REVIEW

The perforating, or communicating veins are vessels that connect the superficial veins with deep ones, and in doing so perforate the deep fascia. In the human forelimb Fabricius (1603) noted the presence of perforators. A perforator found in the region of the antecubital fossa is noted in anatomy texts; Jones (1946) refers to it as the deep median vein or the 'black vein'. Fournol et al (1985) describe the perforators in the forearm, in the regio radialis (in the radial region) from the wrist to the elbow. The perforating veins of the lower limb of humans have been relatively well researched but little is known of the perforating veins of the forelimb.

The number, position, structure and constancy of human lower limb perforators have been documented (Kuster et al 1968; Thomson, 1979), and Thomson has produced detailed maps of the sites of the perforating veins of the lower limb. He categorised these perforators as either 'direct' or 'indirect' on the basis of whether they connected directly with the saphenous system (the main lower limb superficial venous system) or to the subcutaneous network. Kuster et al (1968) established the detailed anatomy of the perforators around the ankle, using the medial and lateral malleoli as reference points; they also noted the consistency with which each type was found.

Chapple and Wood (1980) studied the venous system of the hindlimb of

Macaca fascicularis. They mapped the perforators and also categorised them on the basis of their connections. They used two categories, 'constant' and 'inconstant', the former connecting the saphenous system (in the case of the Macaca, the small saphenous only) to the deep veins. The perforators were further divided into three types based on their deep connections.

MATERIALS AND METHODS.

In eighteen human and forty five non-human primate limbs, detailed dissections were carried out to locate the perforators. The position of each perforator was determined with respect to bony landmarks such as the greater tuberosity, the medial and lateral epicondyles of the humerus, the radial styloid and the ulna head. The use of these bony points across range of primates studied was justified both on anatomical and pragmatic grounds: not only are these points assumed to be homologous across the range of primates studied, but they are also easily identifiable surface landmarks in all the animals studied. The total thickness (external diameter) of each perforator was estimated by matching the perforator with a metal gauge of known thickness: a feeler gauge graduated in millimetres was used for this purpose. Perforators down to a diameter of 0.15 mm were thus identified and recorded.

For each primate forelimb dissected the total number of perforators, excluding the terminations of the main veins, was determined. In the analysis of data the arithmetic mean number of perforators was

determined for species where more than one limb was available for dissection. In order to allow an investigation of the relationship between body size and number of perforators, the mean arm length was determined for each species (arm length of each specimen was measured between the greater tuberosity of the humerus and the radial styloid, with the arm in extension). Mean body weight values, used in many allometric studies, were not used in this study because for many specimens the sex, age and species were not known and the cadavers were in most instances incomplete: thus neither published body weight data (e.g. Harvey and Clutton Brock, 1983) nor estimates of body weight based on the wet specimens themselves, are appropriate measures of size in the present study.

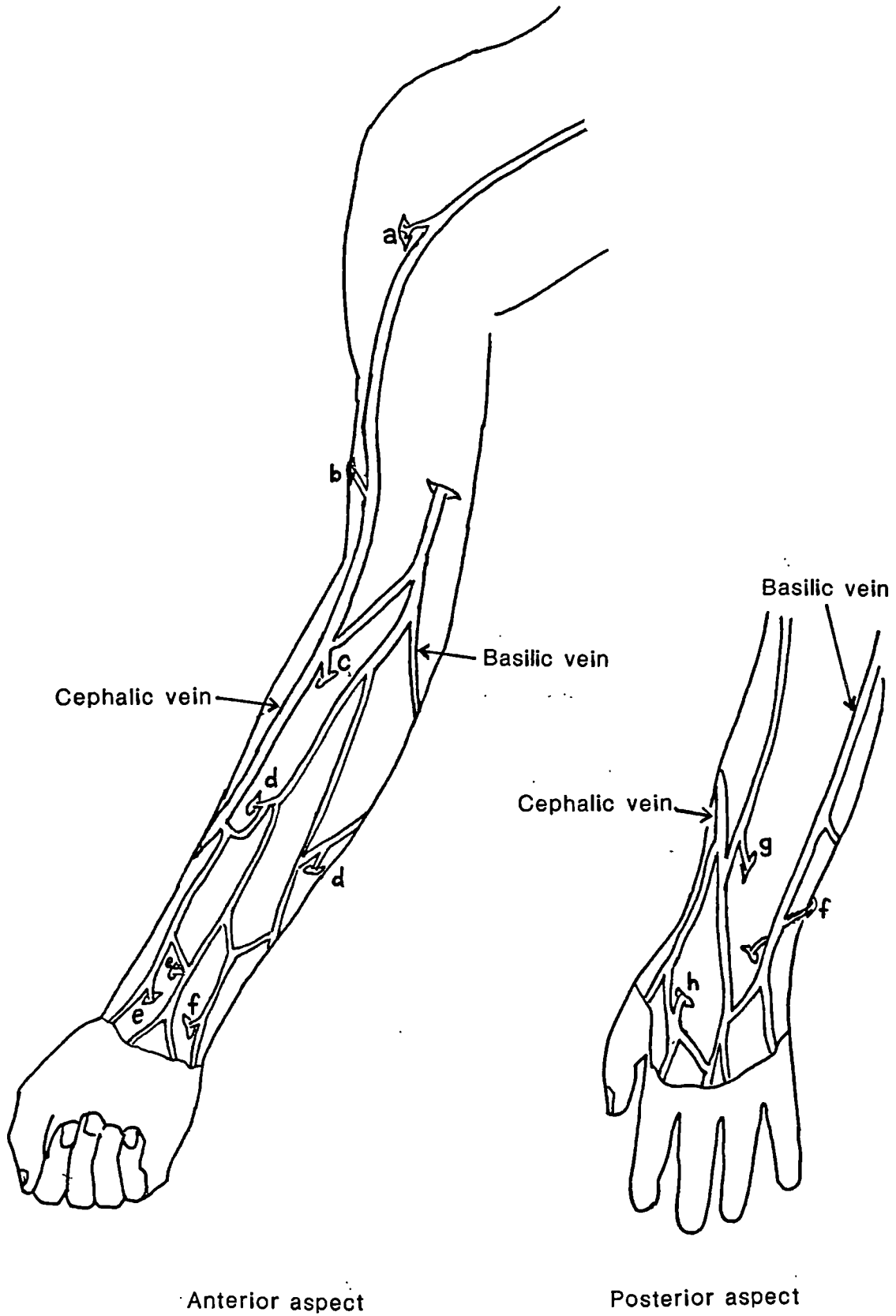
For the 18 human limbs dissected the perforator positions were plotted on stylised two-dimensional diagrams scaled to a unit shoulder-wrist length, to allow the density distribution along the length of the limb to be investigated.

RESULTS

Humans

In humans the perforators were found scattered throughout the length of the limb and their main locations are noted in Figure 2.18. The numbers of perforators in each limb are given in Table 2.4. The maximum number was found in specimen 31 left side ($n=15$), and the minimum in specimen 39 left side ($n=7$); the average number per limb

Figure 2.18 Distribution of the perforating veins in the human forelimb



is 10.7. The number of perforators did not appear to correspond to the length of the cephalic vein, for example, those limbs which have a short cephalic (specimen 32, both limbs, and specimen 40 right side) have close to the average number of perforators (32 r, n=13; 32 l, n=10; 40 r, n=13). Superposition of the scaled stylised diagrams (Figure 2.19) shows a distalwards increase in the density of perforators, apparently reaching a maximum density around the wrist (Figure 2.20).

Connections; There were perforators running between the main superficial veins and the deep veins, and between the network of superficial veins in the forearm and back of the hand, to the deep muscular, metacarpal, or the dorsal carpal rete veins. The scatter of these veins, their relative consistency, position and the range of their diameter are given in Table 2.6.

In 44% of the limbs there was a connection between the cephalic and the muscular veins of the deltoid (perforator 'a' in Figure 2.18). The position of this vein is quite variable (standard deviation of position, relative to the greater tuberosity = 1.83 cm). Further distally in the upper arm, there are one or more perforators connecting the cephalic and the muscular veins in the triceps in 33% of the limbs. This type (denoted 'b' in Figure 2.18) is more consistent in position (s.d. = 0.99 cm), and their median diameter was 0.9 mm. On the flexor aspect of the upper arm there were scattered perforators in 44% of the limbs. They were either connecting the basilic or the cephalic and the upper arm flexor muscle veins or the deep part of the basilic. Their position was very

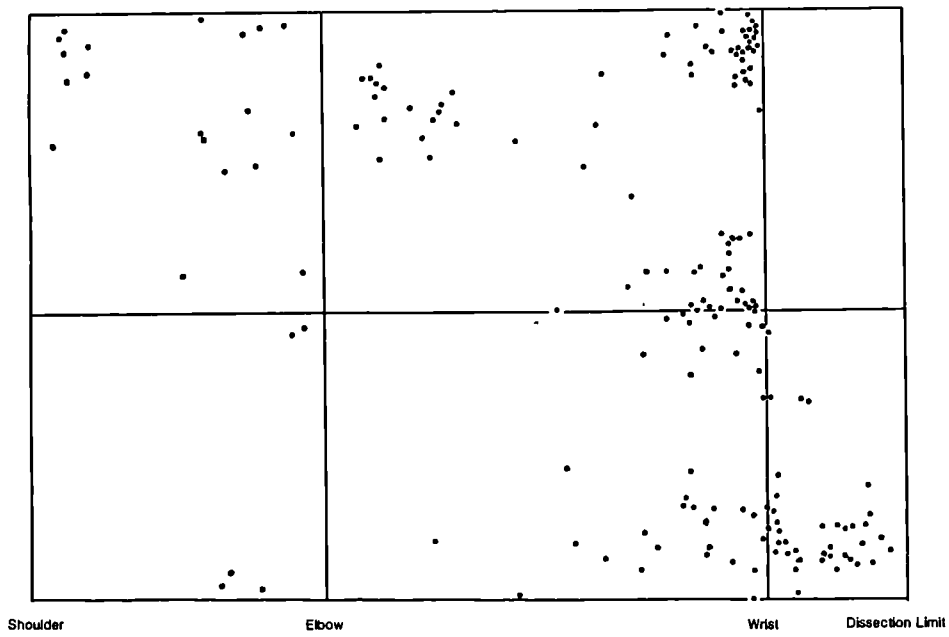


Figure 2.19

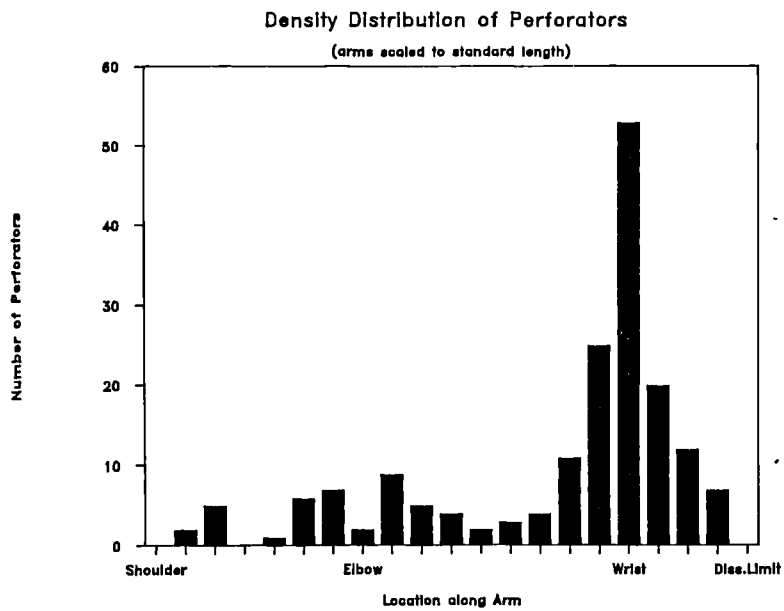


Figure 2.20

variable (s.d. = 3.58 cm).

In all limbs (100%) there was a well defined perforating vein connecting the cephalic or the median cubital and the radial and ulnar venae comitantes in the cubital fossa (denoted 'c' in Figure 2.18). Its position was quite consistent (s.d. = 0.96 cm) and the median diameter was 2.5 mm. In the forearm, as Figure 2.19 shows, there is a distalward increase in concentration of the perforating veins. Though there were perforators in the middle part of the forearm both anteriorly and posteriorly in 33% of limbs, the scatter was wide especially on the posterior surface. In the case of the anterior aspect, perforators usually connected the superficial network veins to the ulnar and radial venae comitantes. These type (denoted 'd' in Figure 2.18) were more common on the ulnar region (ulnar region n=7, radial n=2). The veins in the ulnar region whenever found were consistent in position (s.d. = 0.79 cm) and their median diameter is 0.4 mm. On the posterior aspect, in a broadly similar region the veins were those which connected the superficial venous plexus and the muscular veins in the extensor compartment. These veins were inconsistent in position (s.d. = 3.13 cm).

In the distal part of the forearm numerous perforators were found. On the anterior aspect they were connections mainly of the radial and ulnar venae comitantes (denoted 'e' and 'f' respectively in Figure 2.18) to the main or the network superficial veins. These were found in all limbs and were fairly consistent on the radial side (radial s.d. = 0.93 cm), though the same cannot be said about those on the ulnar side (s.d. = 1.08 cm). Their median diameters were 0.6 mm. On

the posterior surface of a broadly similar area, the perforators were found in 83% limbs on the radial side, and in 33% on the ulnar side. They connected the superficial network veins and the posterior continuation of the cephalic and basilic to deep muscular veins or to the carpal rete veins (they are denoted 'g' on Figure 2.18). They were inconstant in position (radial side s.d. = 1.54 cm, ulnar side s.d. = 1.07cm).

On the posterior surface of the hand there were one or more perforating veins on the radial, or the lateral, side in all limbs (100%). On the ulnar side perforators were only found in three limbs (16%). Lateral perforator was usually connected the superficial dorsal veins radial side of the dorsal venous arch to and the veins accompanying the dorsal artery of the index or pollex. (denoted 'h' in Figure 2.18). These veins were fairly consistent (s.d. = 0.94 cm) and had a median diameter of 0.9 mm.

Non-human primates

Prosimians (Figure 2.4 a & b): In all limbs dissected, (Lemur, Nycticebus, Perodicticus) there was a perforating vein running from the lateral superficial vein to the radial venae comitantes in the cubital fossa region (Figure 2.4a&b vein c. In Lemur and Perodicticus there was a vein that connected the lateral superficial vein or a small tributary of it to the radial venae comitantes on the anterior aspect of the distal forearm (Figure 2.4 a & b, vein r). In the Perodicticus limbs, additionally the ulnar side of the dorsal venous

network veins had a connection to the ulnar venae comitantes on the posterior aspect of the distal part of the forearm (Figure 2.4 b, vein u). Also in one Perodicticus limb (008 left) there were two perforators from the lateral superficial vein in the upper arm running posterolaterally into the triceps to connect with muscular veins (Figure 2.4b, vein t).

Ceboids (Figure 2.5 a & b): In all specimens studied (Alouatta, Lagothrix, Saimiri) the forelimbs had a perforator in the cubital fossa connecting the lateral superficial vein to the deep radial venae comitantes (Figure 2.5 a & b, vein c). In Lagothrix and Alouatta limbs in the distal part of the forearm there was a perforator connecting the lateral superficial vein to the radial venae comitantes (Figure 2.5 a & b, vein r). In addition, on the radial side in the Lagothrix there was a perforator in the first interosseous space (Figure 2.5 b, vein p), Lagothrix also had a perforator in the distal upper arm running from the lateral superficial vein into the triceps region to connect with muscular veins (Figure 2.5 b, vein t).

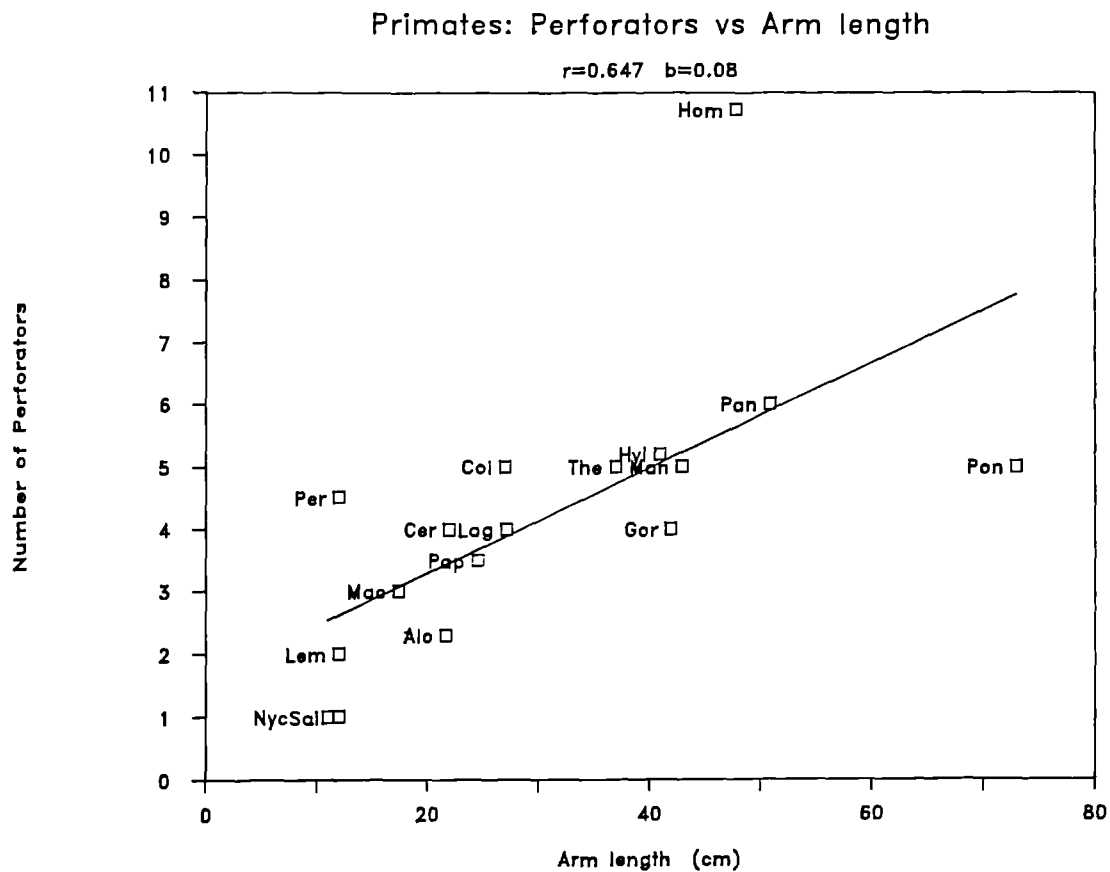
Cercopithecoids (Figure 2.6 a-d): All limbs (Papio, Macaca, Cercopithecus, Colobus, Mandrillus) apart from the single Theropithecus limb, possessed a perforator in the region of the cubital fossa, connecting the lateral superficial vein to the radial venae comitantes (Figure 2.6 a,b and c, vein c). All the limbs had a perforator in the distal part of the forearm connecting the lateral

superficial vein to the radial venae comitantes (Figure 2.6 a-d, vein r). In all except some of the Papio limbs (069, 003) the medial side of the dorsal venous network veins connected to the ulnar venae comitantes on the posterior aspect adjacent to the ulna head either proximal or distal to it (Figure 2.6 a-d, vein u). In all limbs except those of Macaca and two of the Cercopithecus limbs (086 left, 065 right) there was a perforator piercing the triceps connecting the lateral superficial vein to the veins in the triceps (Figure 2.6 a-d, vein t). Additionally in Mandrillus, Theropithecus, and Colobus there was a perforator on the posterior aspect of the forearm connecting the posterior superficial veins to muscular veins in the (Figure 2.6 b & d, vein e) extensor compartment.

Hominoids (Figures 2.7, 2.8, 2.9 and 2.10): Of the limbs dissected (Hylobates, Pongo, Pan and Gorilla), except for two of Pan (084 left, 091 right) and Pongo limbs, all possessed at least one and sometimes two perforators in the cubital fossa region (Figure 2.7, 2.9 and 2.10, vein c). This connected the lateral superficial vein to the radial venae comitantes. In all the limbs, the distal part of the forearm on the radial side had a perforator connecting the lateral superficial and the radial venae comitantes (Figure 2.7, 2.8, 2.9, 2.10, vein r). This area frequently had two perforators in Pan, Gorilla and Pongo. In one specimen of Hylobates (024, right), and in one of Pan (084 right), there was a perforator in the mid-forearm region which connected the lateral superficial and the deep veins (Figure 2.7 and 2.9, vein f). In Pan there were also perforators connecting the dorsal superficial veins on the radial side and the

deep metacarpal vein in the first or second interosseous space (Figure 2.9, vein p). In Pongo, Pan and Gorilla limbs the medial side of the dorsal venous network communicated with the ulnar venae comitantes in the region of the wrist adjacent to the ulna head (Figures 2.8, 2.9 and 2.10, vein u). In Pongo and Hylobates (except both limbs of the Hylobates 096) and Pan there was a perforator connecting the posterior forearm superficial veins and the deep muscular veins (Figures 2.7, 2.8 a & c, 2.9, vein e) In all Hylobates there was a large vein connecting the lateral superficial vein to the deep vein of the upperarm, the superficial brachial (Figure 2.7, vein b). In the Hylobates additionally a perforator piercing the triceps connecting the lateral superficial vein to the deep veins in the muscle (Figure 2.7, vein t).

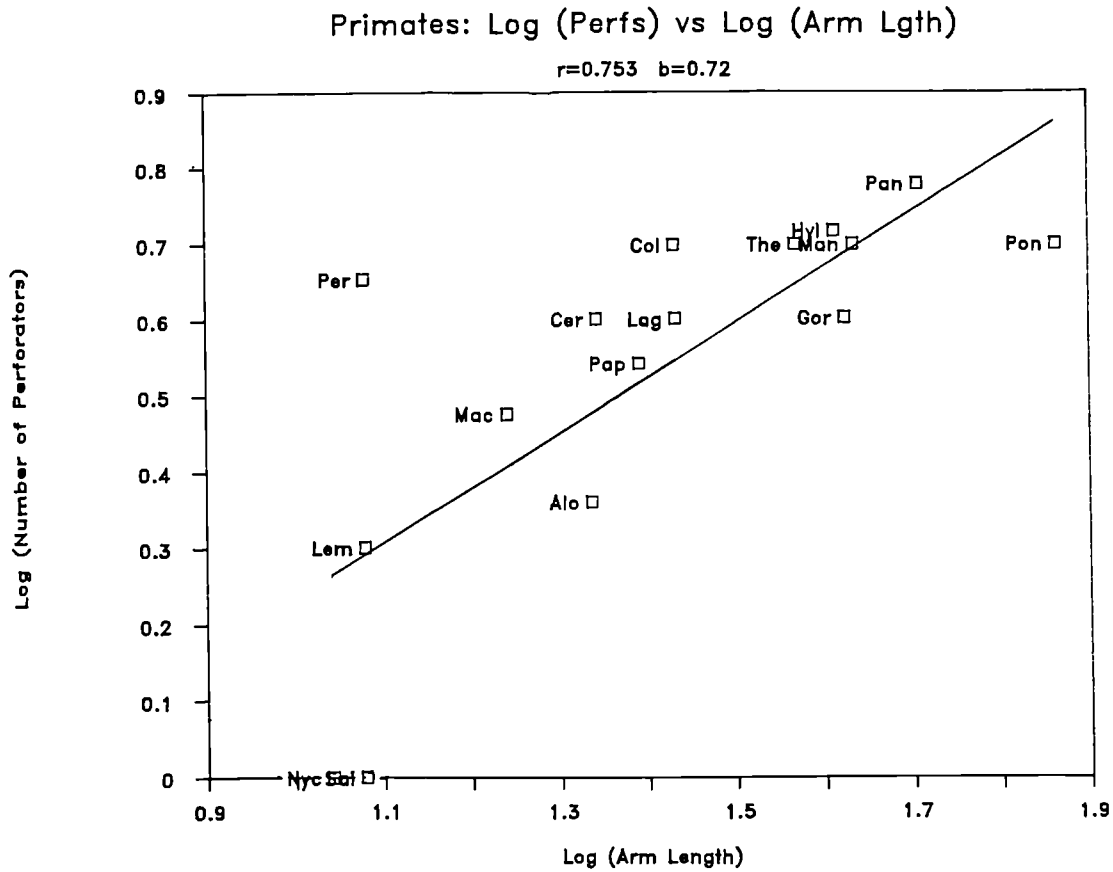
The number of perforators in the human and non-human primates are given in Tables 2.4 and 2.5. The relationship between the primate perforator systems are traced by looking at the covariation of the number of perforators with arm length. The individual arm length (measured as the distance between the greater tuberosity of the humerus to the radial styloid) was used as a surrogate for body size. The number of perforators was plotted as the dependant variable, while arm length was the independent variable. On the linear plot of number of perforators vs. arm length (Figure 2.21) the human value was a significant outlier. Therefore the human value was left out when the general allometric equation was derived for the primates. The raw data was transformed into logarithms before plotting on bivariate axes. Figure 2.22 shows the relationship between number of perforators and arm length. The correlation coefficient (r) is 0.75



Species and Number of Specimens

Species	No.	Species	No.		
Alo	<u>Alouatta</u>	3	Cer	<u>Cercopithecus</u>	4
Col	<u>Colobus</u>	2	Gor	<u>Gorilla</u>	1
Hom	<u>Homo</u>	18	Hyl	<u>Hylobates</u>	4
Lag	<u>Lagothrix</u>	2	Lem	<u>Lemur</u>	2
Mac	<u>Macaca</u>	4	Man	<u>Mandrillus</u>	1
Nyc	<u>Nycticebus</u>	1	Pan	<u>Pan</u>	6
Pap	<u>Papio</u>	12	Per	<u>Perodicticus</u>	2
Pon	<u>Pongo</u>	1	Sai	<u>Saimiri</u>	1
The	<u>Theropithecus</u>	1			

Figure 2.21



Species and Number of Specimens

Species	No.	Species	No.		
Alo	<u>Alouatta</u>	3	Cer	<u>Cercopithecus</u>	4
Col	<u>Colobus</u>	2	Gor	<u>Gorilla</u>	1
Hom	<u>Homo</u>	18	Hyl	<u>Hylobates</u>	4
Lag	<u>Lagothrix</u>	2	Lem	<u>Lemur</u>	2
Mac	<u>Macaca</u>	4	Man	<u>Mandrillus</u>	1
Nyc	<u>Nycticebus</u>	1	Pan	<u>Pan</u>	6
Pap	<u>Papio</u>	12	Per	<u>Perodicticus</u>	2
Pon	<u>Pongo</u>	1	Sai	<u>Saimiri</u>	1
The	<u>Theropithecus</u>	1			

Figure 2.22

and the slope (allometry coefficient) is 0.72. Nycticebus, Saimiri, Pongo and Gorilla are single specimens and though they seem to deviate from the line a statistical effect, which may be due to the smallness of the sample, cannot be excluded. On the linear plot the deviation of humans and Perodicticus need to be noted (see discussion Chapter 5).

VENOUS VALVES

LITERATURE REVIEW

The valves are the most controversial subject in the whole of the venous system. Functionally they have been a focus since Harvey in 1628 demonstrated the direction of blood flow in veins and the function of the valves. Before Harvey, Fabricius (1603) had produced detailed illustrations of the venous valves. Two centuries later, Roden (1839) wrote "the valvular structure of the veins anatomically and physiologically considered, with a view to exemplify or set forth by instance or example, the wisdom, power, and goodness of God, as revealed and declared in Holy writ". Thus the speculation about the valves has varied from their status as God's ingenious creation (Roden), and to the functional perspective of their being seen as specialised structures in those veins that encounter changes in hydrostatic pressure (Franklin, 1937; Shepherd and van Houtte 1975). Contemporary studies have noted their of an irregular occurrence along the course of veins (Kosinski, 1926; Edwards and Edwards, 1940; Haeger, 1967; Cotton, 1961; Chapple and Wood, 1980 - the latter in Macaca), and some works have suggested that they are developmentally and structurally (i.e number, position) unconnected to hydrostatic pressure, e.g. Kampmeir (1926) in his studies of the human foetal valves, Chapple and Wood (1980) in their primate study, and Williams (1954) in his studies on primates and domestic animals like the cat and dog.

In 1880, the German anatomist Karl Bardeleben undertook a massive study into the valves of the limb veins and put forward the theory of the "valve distance law". According to Bardeleben, the randomness of the valves is apparent and not real. His law says that the distance between valves represents an integer multiple of a certain constant unit termed the "Grunddistanz" (a basic distance), which in turn is an expression of the stature of the individual or of the length of the limb. Bardeleben thus searched for periodicity in valve distances; his "Grunddistanz" for the upper limb of an adult human was 5.5 mm, for the lower limb of an adult human 7 mm, and for the lower limb of a human child (81 cm tall) 3 mm. This law was never pursued by later researchers, who continued to emphasise the irregularity of the valves, though producing some range for the average distances between the valves. However, Bardeleben's search for order, before concepts like probability were well understood, and during a time when scientists were looking for "ideal numbers" (perhaps a persisting Platonic influence) seems worthy of comment.

Bardeleben's number, or basic distance, is so small that the chance of valves not occurring at multiples of that basic distance seem rather slim. However the idea of an order and the massive collection of data undertaken by Bardeleben have been studiously ignored by later workers. The Russian scientist Vankov (1968) established the concept of a "valve index", the number of valves per unit length. This concept has not been used by western scientists, who have favoured stochastic hypotheses in explaining valve numbers, rather than relating the number of valves to the length of vein or vein segment in which they occur. The fact that valves do not occur at

regular intervals along veins has been accorded much importance, though the concept of probability has not been fully explored, and the correlation with length of vein (as Vankov's indices have warranted) has not been seen as important. The literature reveals a wide range for valve numbers and their averages (Kosinski, 1926; Cotton, 1961) and comparisons between these raw numbers of valves have been made between humans and other animals (Chapple and Wood, 1980).

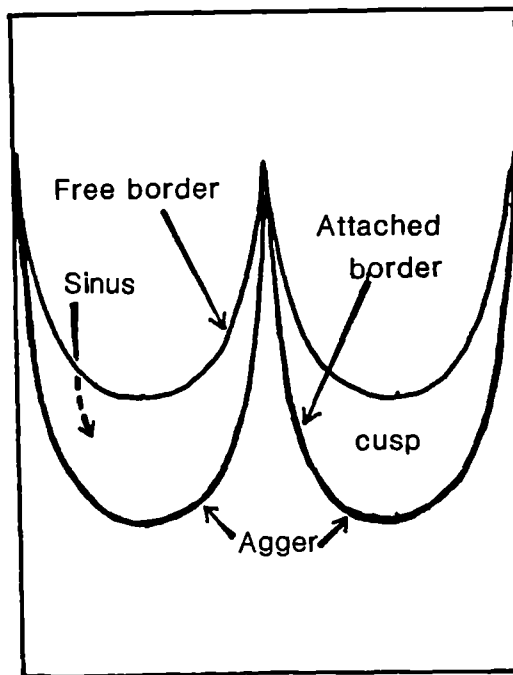
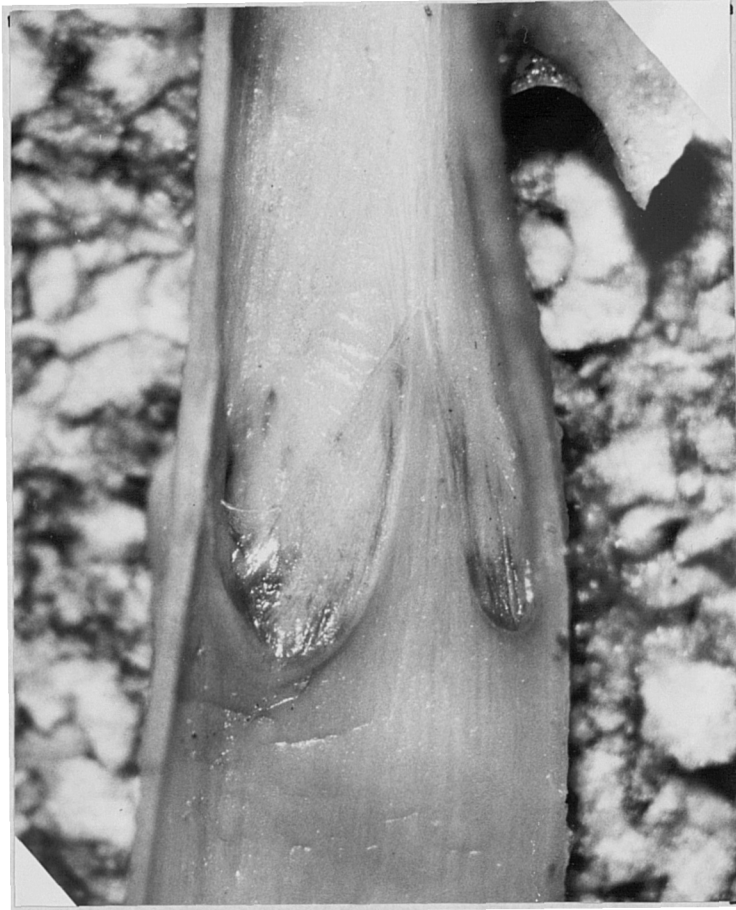That hardly any structure in an organism exists as a isolated entity is 'intuitively' understood by scientists and therefore it seems sensible to look for some correlation (Bardeleben was the first to look for it, but under the presumably mistaken theory of ideal numbers). Vankov's use of the valve index seems interesting. When the data of the other researchers are presented as valve indices (Table 2.7) it is seen that there is quite a good correspondence between different researchers, except for Chapple and Wood, whose index of 0.62 valves per cm for the Macaca short saphenous seems extraordinarily high. It is interesting to note that Chapple and Wood compare their valve numbers in Macaca short saphenous vein to Kosinski's human short saphenous and conclude that they are in the same range (Macaca SSV = 5-10 valves; human average = 8 valves). However, when these data are converted to valve indices there is no agreement between the studies, although Kosinski's converted data seemed to fit with that of the others (Bardeleben's SSV valve index = 0.25, Marinov = 0.22 and Kosinski = 0.23). Conversion of data was done in the following way: in Kosinski and Williams, who provide an average distance between valves, the index is simply the reciprocal

of this average distance. Marinov states that the valve density of SSV is twice that of LSV, therefore twice the mean number in LSV, together with the latter's length, was used to arrive at an approximate index. Bardeleben gives measures of the length of vein and number of valves, hence a valve index can be derived from his data. Therefore, with regard to the position and number of valves it would seem pertinent to attempt to answer two questions. Is the randomness true? Are valves correlated to any other size dimension such as length of vein, length of arm or body weight?. A further question has also been raised: whether different methods of identifying valves might influence the total numbers of valves discovered (Chapple and Wood 1980).

The perforating veins of the upper limb are reported to have no valves. Fabricius (1603) first reported the lack of valves in human upper limb perforators, a view corroborated by Fournol (1985) in his oral presentation at the XIIth International Anatomical Congress, London, 1985.

Description of venous valves

Valves are structures projecting into the lumen of the vein and are usually formed by two cusps (bicuspid). The cusps are diaphanous membranes, crescentic in shape. Each cusp has a free border and an attached border. The valve cusps are attached to the vein wall transversely and lie parallel to the tangent drawn to the overlying skin. The vein wall where the cusps are attached is called the



Venous valve

Figure 2.23

"agger" of the valve and above this agger is the sinus of the valve, which is thin-walled (Figure 2.23). The above description and nomenclature used is from Franklin (1937).

The attachment of the cusp to the vein wall lies close to that of its fellow in its proximal part, but diverges distally. The region between the attachment is called the commissure and the vein wall is thickened and is termed the commisural mound (Edwards and Edwards, 1940). Edwards and Edwards also give a good account of the structure of the saphenous valve. The cusps, according to ^{them} are composed of collagen, smooth muscle and elastic tissue. This is covered by endothelium, both on the sinus and the contact surfaces. The collagen is concentrated at the base, thinning out toward the free edge of the cusp. The muscle is found at the basal quarter, or third, of the cusp. The elastic tissue lies on the contact side of the cusp and is continuous with membrane between the endothelium and the remainder of the cusp substance. No elastic tissue was found on the sinus side (Edwards and Edwards 1940).

MATERIALS AND METHODS

In twenty nine human limbs the cephalic and the basilic veins were removed from the specimen, opened out using fine scissors, and examined under a dissecting microscope. The number of valves together with their position along the length of the vein were noted. In sixteen nonhuman primate limbs from seven genera the lateral vein was removed and a similar procedure to that of the humans was adopted

to count the number of valves and to note their their position along the vein. The sixteen non-human lateral veins included one from Macaca to allow comparison to be made between gross and microscopic methods of examination. Macaca was one of the smallest primates whose lateral vein could be opened by gross dissection. If discrepancies occurred between the number of valves found by gross dissection and the numbers found by microscopy, we might expect such a discrepancy in the veins obtained from a small primate such as Macaca.

In four Macaca fascicularis (eight limbs) the superficial lateral vein, the deep and the perforating veins were removed to be examined microscopically. The veins were divided into two centimetre segments, each segment dehydrated in a series of alcohols and then embedded in paraffin wax. Each blocked segment was cut into 10um thick serial sections and one in five sections were mounted and stained using Verhoeff and VanGieson's staining method. It should be noted that owing to the rather poor condition of preservation of the material ad hoc modifications to the classical staining procedure had to be adopted.

Sections were examined under the light microscope. A similar histological procedure was carried out with perforating veins obtained from fresh postmortems of 10 human limbs.

RESULTS

Figure 2.24 Human Cephalic Vein: Vivs vs Vein Lgth

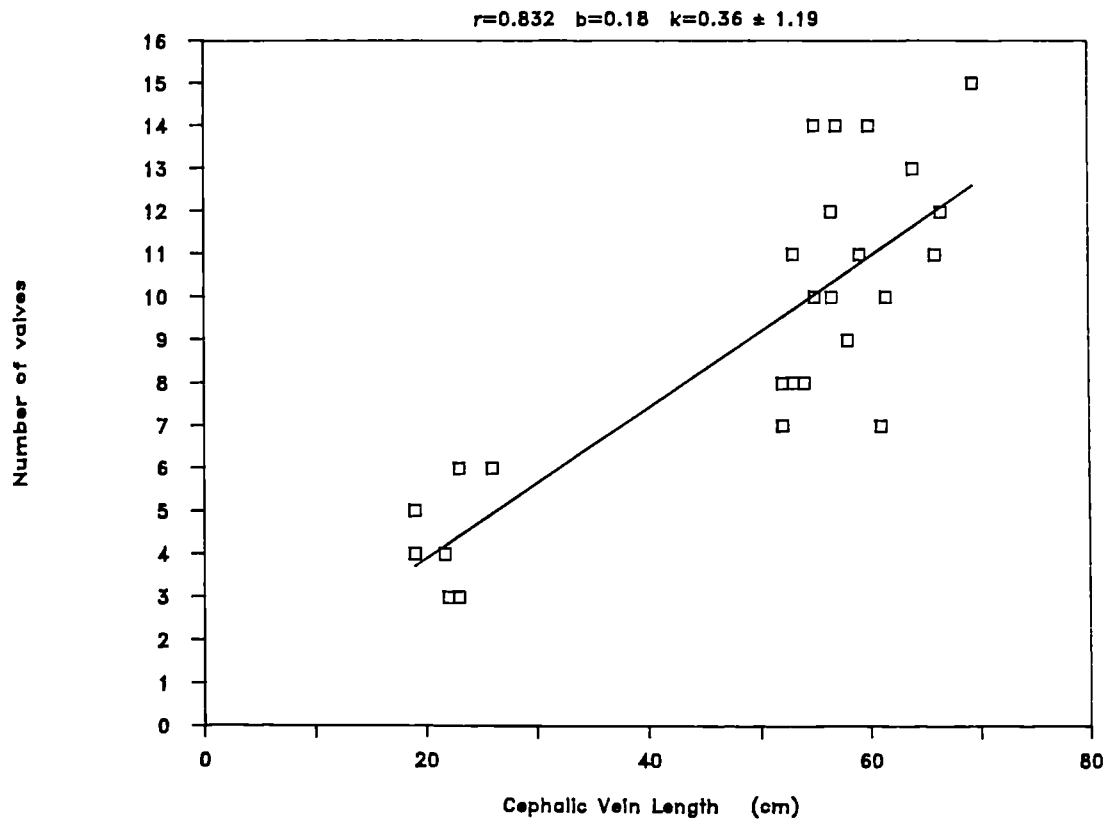
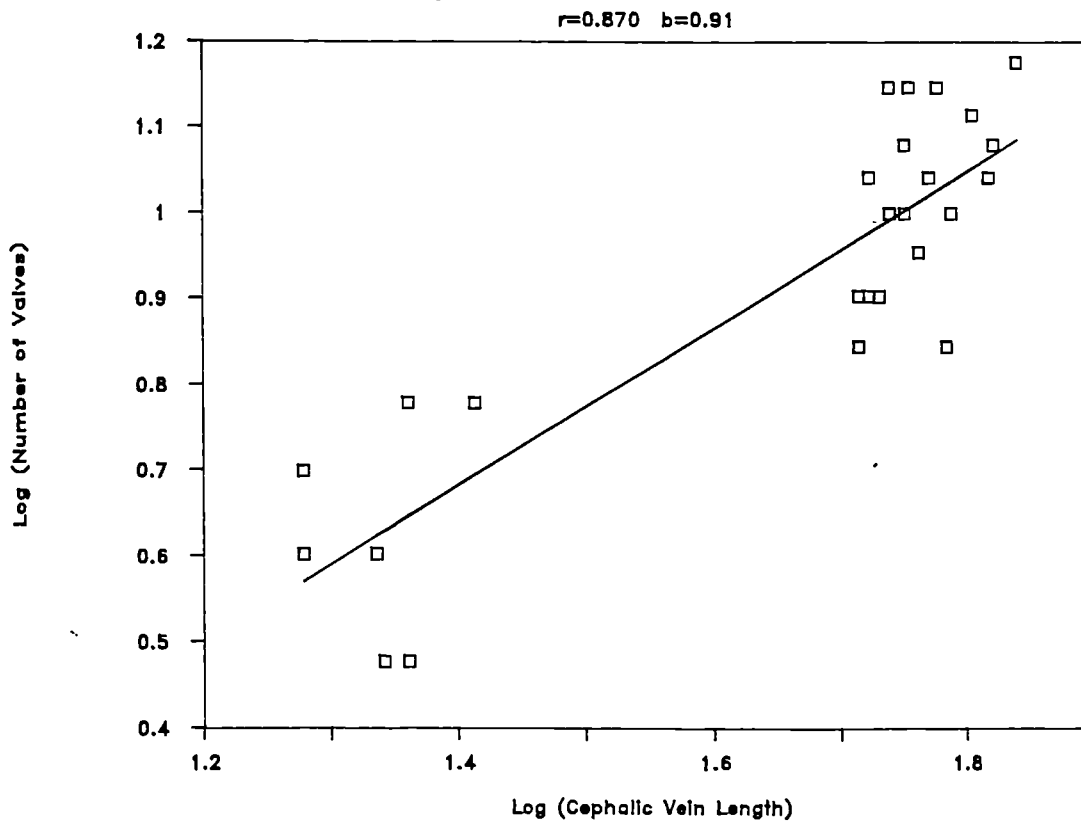


Figure 2.25 Log (Cephalic Vivs) vs Log (Vein Lgth)



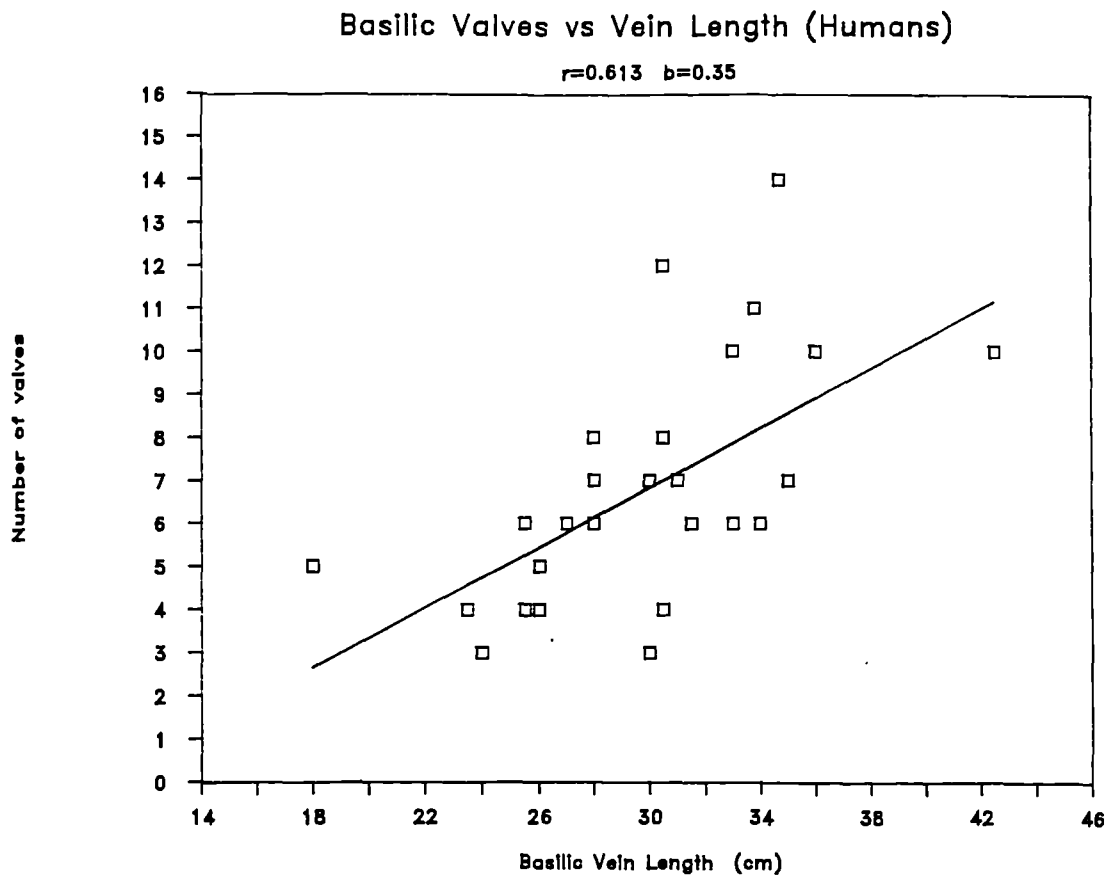


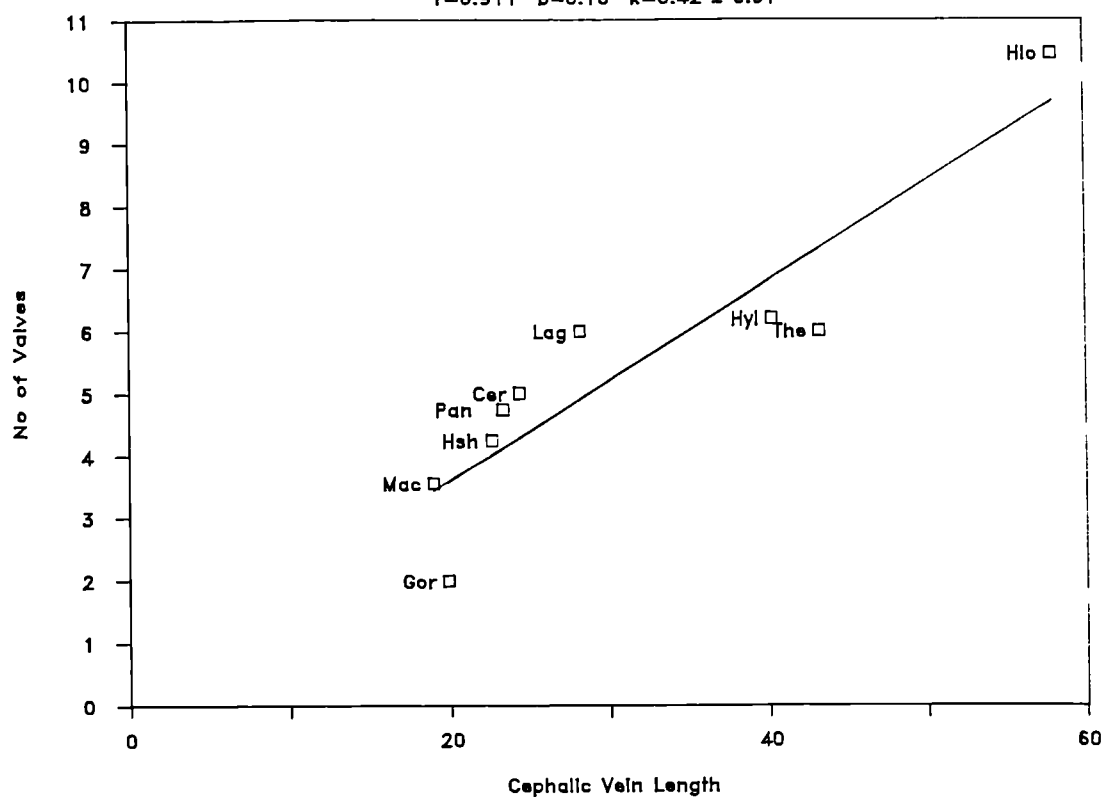
Figure 2.26

The number of valves and the length of the vein of the human cephalic and basilic are given in Table 2.8. Table 2.9 gives the number of valves in the lateral superficial vein in the non-human primates. Figure 2.24 shows the relationship of the number of valves to the length of the human cephalic vein. The linear regression of valve number on vein length has a high correlation coefficient ($r = 0.83$, perhaps artificially high because of the bimodal distribution of cephalic vein length) and the regression line has a y-intercept that is not significantly different from zero ($k = 0.36$, s.e. = 1.19). Thus the relationship between the number of valves and the length of vein is linear and isometric in the human cephalic vein, and the valve index is an appropriate measure of the density of valves. Figure 2.24 shows that there are two clusters of values, corresponding to the presence of long and short cephalic veins, though this morphological distinction appears to have no effect on the underlying relationship of the number of valves to the length of the vein. The log transformed data of the above (Figure 2.25) shows the almost isometric relationship ($b = 0.91$) between the number of valves and the length of vein. For the basilic vein (Figure 2.26) the relationship is not so marked, and the correlation coefficient is 0.61, perhaps because the range of length of basilic vein is much smaller than the range of cephalic vein length in humans, and the distribution of basilic vein length is unimodal.

In the primates the relationship between the number of valves and the length of the lateral superficial vein (in the case of humans the cephalic, the homologue of the lateral superficial) is shown in Figure 2.27 (raw data) and Figure 2.28 (log transformed data). The

Cephalic Vein, Valves versus Vein Length

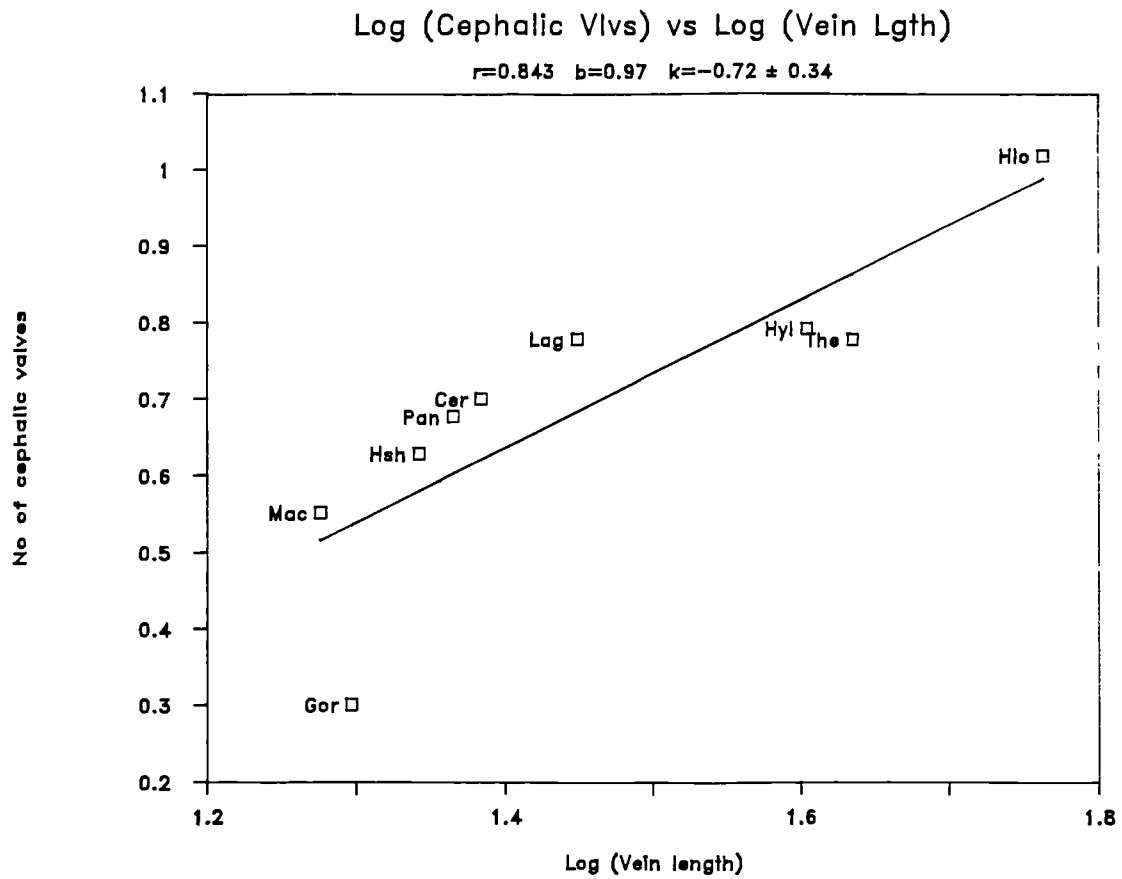
$$r=0.911 \quad b=0.16 \quad k=0.42 \pm 0.91$$



Species and Number of Specimens

Species	No.	Species	No.		
Cer	<u>Cercopithecus</u>	2	Gor	<u>Gorilla</u>	1
Hsh	<u>Homo 'short'</u>	7	Hlo	<u>Homo 'long'</u>	22
Hyl	<u>Hylobates</u>	5	Lag	<u>Lagothrix</u>	2
Mac	<u>Macaca</u>	9	Pan	<u>Pan</u>	4
The	<u>Theropithecus</u>	1			

Figure 2.27



Species and Number of Specimens

Species	No.	Species	No.		
Cer	<u>Cercopithecus</u>	2	Gor	<u>Gorilla</u>	1
Hsh	<u>Homo 'short'</u>	7	Hlo	<u>Homo 'long'</u>	22
Hyl	<u>Hylobates</u>	5	Lag	<u>Lagothrix</u>	2
Mac	<u>Macaca</u>	9	Pan	<u>Pan</u>	4
The	<u>Theropithecus</u>	1			

Figure 2.28

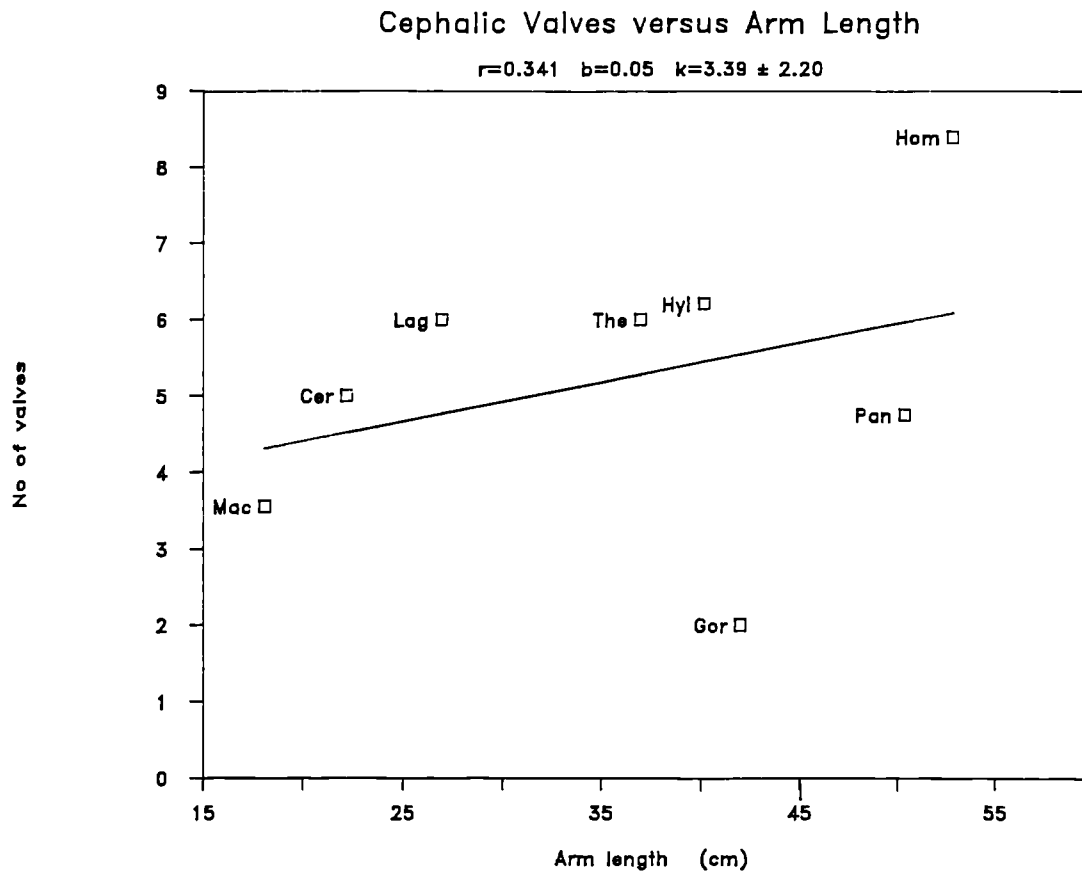


Figure 2.29

log plot shows the isometric ($b = 0.98$) relationship of the number of valves to the length of vein in all the primates examined. The plot of the raw data also shows linearity by way of the high correlation coefficient ($r = 0.91$). Figure 2.29 shows the lack of relationship of the valves to the arm length (surrogate for overall size). Figure 2.27 shows not only the linearity of the relationship but also that the line passes very close to the origin ($k = 0.42$, $s.e = 0.91$). Therefore the use of Vankov's index is appropriate in the non-human taxa as well. Table 2.10 gives the valve index of Vankov (number of valves per unit length) for the lateral superficial veins of the different primate taxa examined in this study.

The deep veins of the Macaca also had well-defined valves (Table 2.11). No comparison was made in this species between the valve indices of deep and superficial veins as the lengths of the deep veins were not obtained.

Valves in the perforating veins: In the Macaca specimens 078 (both limbs), 070 left limb and 077 left limb perforators have valves. Table 2.12 gives the specific perforators and the presence of valves. Table 2.13 gives the presence of valves in the human perforators examined. These findings show that only 26% of the Macaca perforators and 14% of the modern human perforators examined have valves. This result is discussed in Chapter 5.

Summary of results

The number of valves in the primates, as far as the lateral superficial and the homologous human cephalic is concerned, is apparently a function of the length of the vein and the relationship is linear. The valve index therefore is a good measure for predicting the probability of valves within primates. The overall size of the limb seems to have no direct bearing on the number of valves within the main superficial veins. Some perforating veins, both in Macaca and in humans, do have valves but they are a minority.

There did not appear to be any great difference between microscopic and macroscopic methods for identifying venous valves. The single Macaca vein that was examined macroscopically (specimen 081 R) had three valves, compared to an average of 3.6 valves among the 8 Macaca veins examined microscopically (Table 2.9).

CHAPTER 3: ONTOGENY OF THE MAIN VEINS

Ontogenetic studies not only document the developmental history of organisms but also assume a wider importance by their relevance to phylogenetic and evolutionary studies. The ontogeny-phylogeny connection has recently been reviewed by Gould who develops an argument for the existence of parallels between stages of ontogeny and phylogeny due to changes in developmental timing (Gould, 1977). Gould is principally concerned with analysing the processes that lead to evolutionary change. He shows that an alteration of developmental timing (heterochrony) on the characters already present in an ancestor can induce "new" characters to appear in the descendants. Moreover Bonde (1984), quoting Nelson's biogenetic law, uses the ontogenetic information for another important purpose - the determination of polarity of character states (primitive/derived) in cladistic studies. Details of cladistic method will be given in the next section.

In this presentation of the ontogeny of the human upper limb veins I will outline the developmental history, and then go on to show how these data can throw light on the results of comparative studies of the mammalian forelimb venous system.

LITERATURE REVIEW

A search of published sources has revealed that two hypotheses have

been advanced for the development of the forelimb veins. Karl Bardeleben (1880b), working on human foetuses, proposed one while Hochstetter (1891) and F. T. Lewis (1905) another. Though the developmental theories of the veins have not been evoked in recent literature, Bardeleben's view seems to have been accepted by some recent students of the veins of the upper limb (Bouchet et al. 1973). The evidence and the details of the two hypotheses will be set out in detail below.

Bardeleben examined 36 human foetuses ranging from Crown Rump Length (CRL) 24mm to CRL 245mm (corresponding to 45 days-26 wks.) and came to the following conclusions: (Figure 3.1)

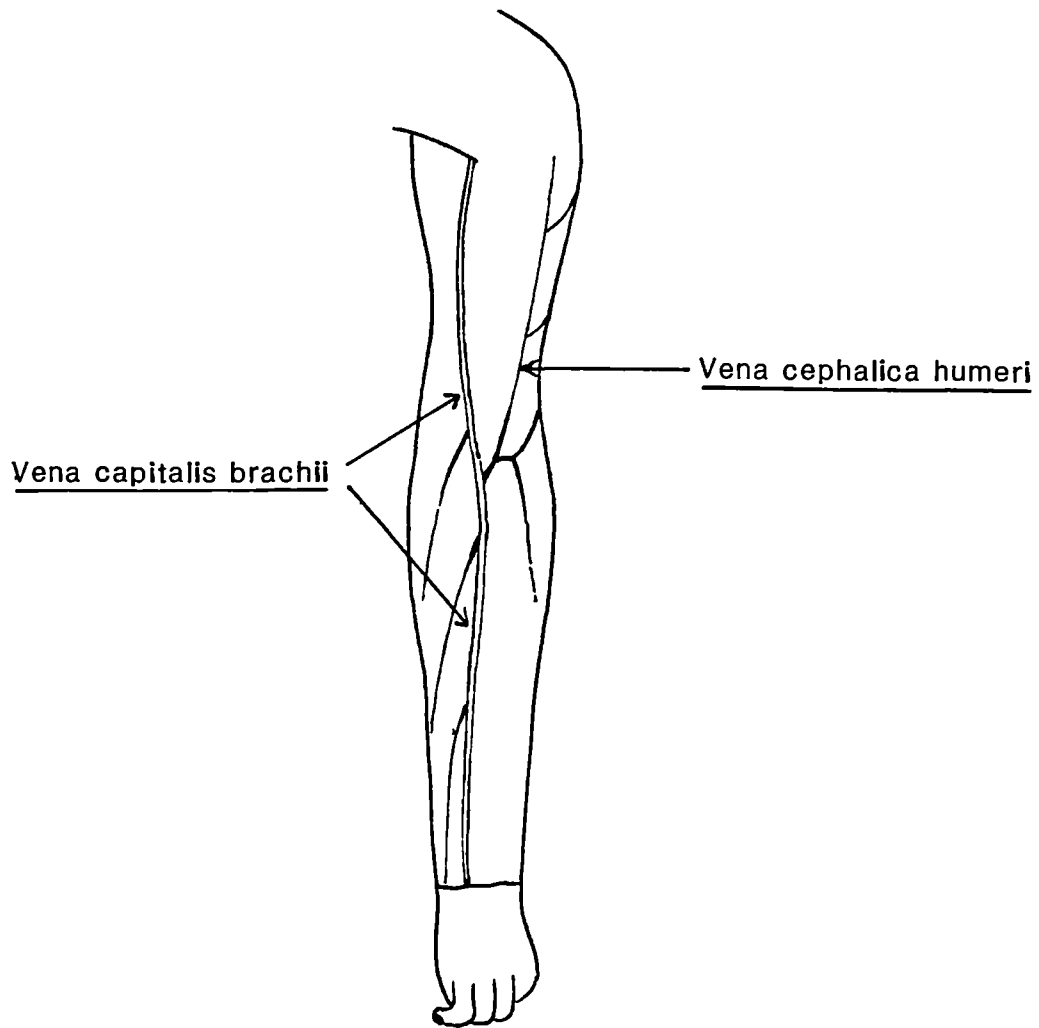
- 1) in the foetal upper limb there are not two superficial veins (cephalic and basilic) but one i.e the vena capitalis brachii.
- 2) the cephalica humeri (cephalic of the upper arm) embryologically consisted of two parts:
 - a) an ascending vein which opens into the axillary or subclavian vein.
 - b) a descending vein opening into the vena capitalis in the region of the cubital fossa.
- 3) the deep veins in the embryos opened into the superficial veins.

Bardeleben's observations on the cephalica humeri (2 above) are repeated virtually unmodified by Bouchet and co-workers: "the

cephalica humeri is formed of two elements: brachial, flowing in the embryo into the transverse of the elbow. The other, deltoid draining into the axillary" (Bouchet et al, 1973, p. 983).

The main vein (Figure 3.1, vena capitalis brachii) of Bardeleben is the vein that drains the radial side of the dorsal venous arch (cephalica pollicis and vena salvetella) and ascends along the radial border of the forearm. As it ascends it becomes more anteromedial and comes to lie almost in the middle of the cubital fossa. Then it continues proximally on the medial side of the upper arm to the axilla and finally joins the jugular. Bardeleben describes this vein as a skin/subcutaneous vein. Bardeleben consolidates his theory of the main vein by postulating a mechanical reason, that when the limb is held at right angles to the body the line of the main vein is the straightest and thus the shortest and fastest route for venous return.

The cephalica humeri of Bardeleben is that part of the cephalic proximal to the cubital fossa. Regarding this vein he states (Bardeleben, 1880b .p 597) that this branch collects blood from the posterior surface of the upper arm and brings it to the main vein in the cubital fossa region. This collecting vein, though initially descending, at a later stage of development in the majority of embryos becomes the "ascending vena cephalica". Of course it is not as simple to change the direction of the flow in a vein (especially where valves are present) as it is to change its name. The valves in the veins of the upper extremity start developing at the CRL 8 5mm (10-12 wks.) stage and by the CRL 105mm stage (12-13 wks.) their



Redrawn from Bardeleben (1880b: Figure 11)

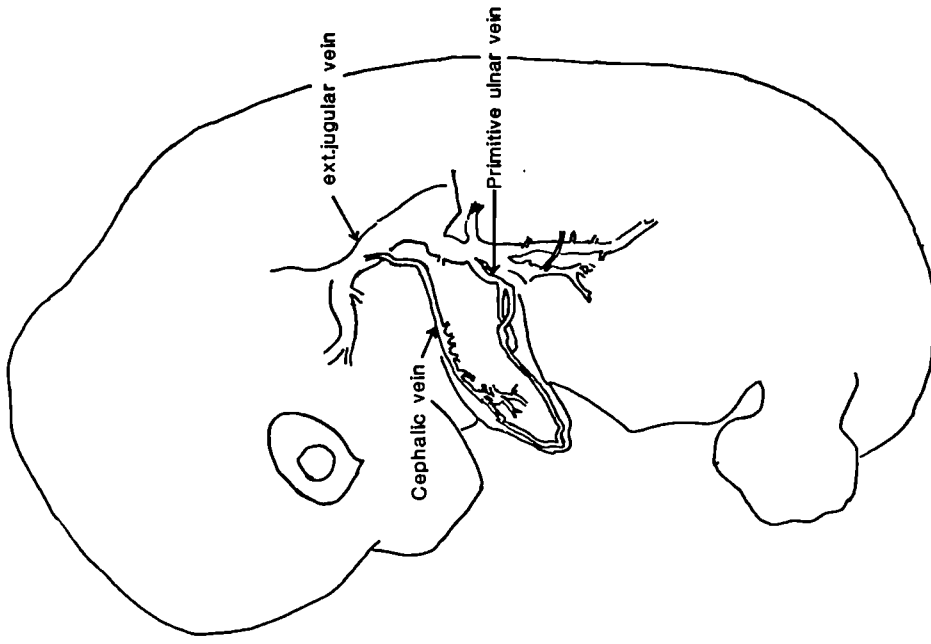
Figure 3.1

development is complete (Kampmeir, 1926). Bardeleben confronted the problem of the directionality of the valves by proposing that they degenerate, leaving the distal part of the cephalica humeri valveless. Despite Bardeleben's own reservations (Bardeleben, 1880b p 600.), in a recent study, the distalward flow of blood in this vein in the embryo was apparently accepted without question (Bouchet et al, 1973).

Most of Bardeleben's sample of human embryos (28 out of 36) are larger than CRL 75mm (10-12 wks.). In all these cases a cephalica humeri is noted, although in six, or perhaps seven, it is only noted as far proximally as the shoulder, and in an equal number, of cases it was seen to pass to the clavicle. Bardeleben's hypothesised that vena capitalis brachii appears first in development (i.e. it is primitive) and that the other veins (including the cephalica humeri) are all its tributaries (Bardeleben, 1880b p 598.). Bardeleben supports this by a significant and possibly real finding that stems from his analysis of early foetuses. Among his eight foetuses ranging from CRL 24mm to CRL 68mm (45 days -10wks.), six of these did not have a cephalica humeri. But the case is jeopardised by the presence of the lateral vein along with the medial in the upper arm of the 42mm foetus, leaving only the 24mm embryo earlier than this in the sample to justify the primitiveness of the vena capitalis brachii.

Hochstetter and Lewis

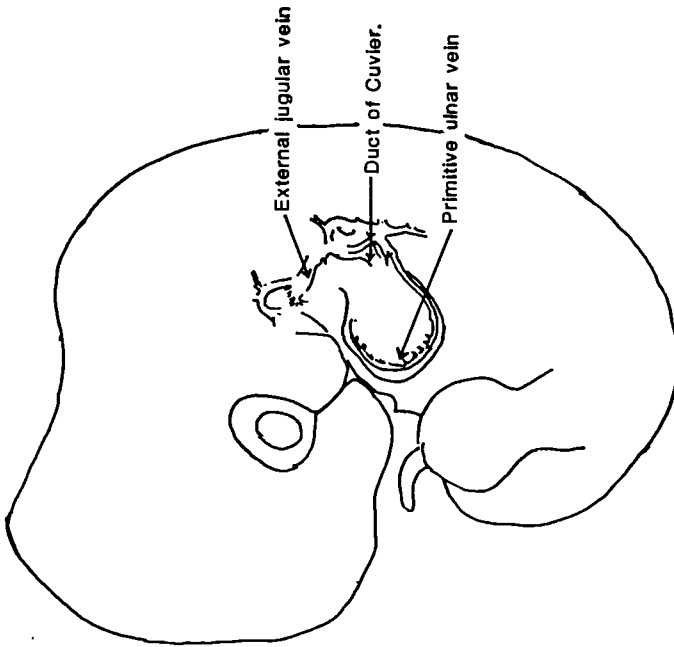
Hochstetter (1891) and Lewis (1905), studying the early embryos of rabbits, questioned Bardeleben's view and concluded that there are two embryological veins, one on the ulnar side (postaxial side of the embryo) and the other on the radial, or preaxial, side of the embryo. Though both the veins appear early in development, Lewis showed that it is the postaxial, or the ulnar, vein that is the more primitive of the two. The primitive ulnar vein, which he noted in the twelve day old rabbit embryo, runs along the outer border (postaxial border) of the limb bud. This vein passes dorsal to the brachial plexus and enters the external jugular, later acquiring an opening ventrally (Figure 3.2) In the next stage (14 days and 18 hrs.: 14.5mm) rabbit embryo, where further differentiation of the hand plate and pronation of the arm is seen, interdigital veins have formed. There is now the primitive ulnar vein along the postaxial border and a new vein along the radial, or the preaxial, side of the limb is seen running from the external jugular to the hand, connecting with the interdigital vein (Figure 3.3). In the 17 day old rabbit the authors state that the radial or preaxial vein is the chief vein of the limb and the primitive ulnar vein becomes reduced by the loss of its distal, or forearm, portion in the rabbit (Figure 3.4). According to Hochstetter (1891) the forearm portion of the primitive ulnar vein in the rabbit seems to disappear, while in humans the corresponding vessel is preserved throughout, to form the basilic, brachial and axillary veins. By 17 days the rabbit's cephalic vein has its new orifice into the axillary and the jugulo-cephalic vein marks the former outlet (Figure 3.4). The differentiation of the forearm veins that accompany the arteries (deep veins of the forearm) follows after these primary developments.



[Redrawn from Lewis, 1905].

Figure 3.3

Rabbit, 14 days, 18 hours, 14.5mm.



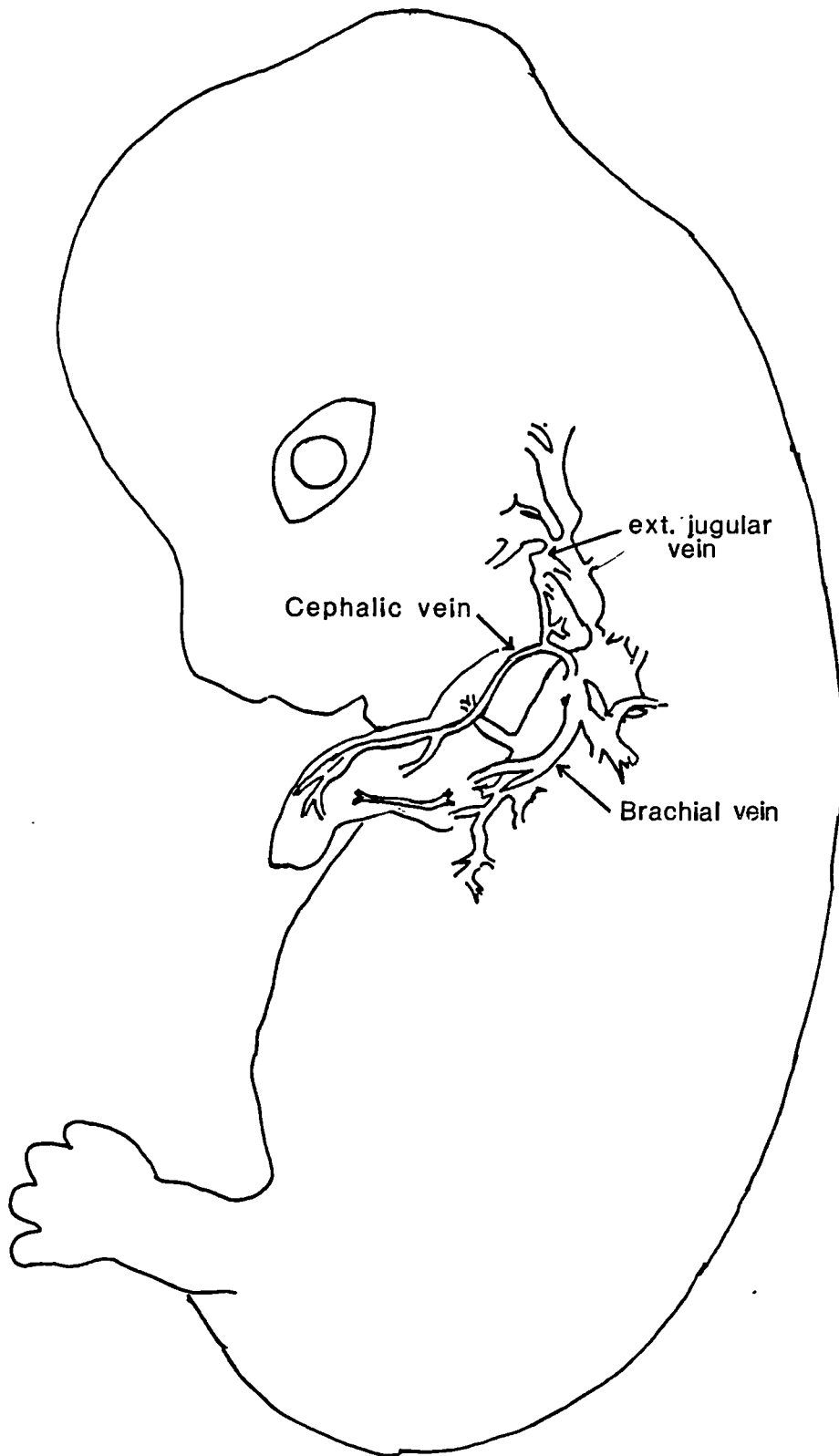
Rabbit 14 days, 10mm. (Redrawn from Lewis, 1905).

Figure 3.2

Subsequent to his work on rabbit embryos, Lewis (1909) studied four human embryos (10mm, 11.5mm, 16mm and 22mm). At the 10mm stage he noted the primitive ulnar vein on the postaxial side of the limb bud which united with the thoraco-epigastric vein proximally. Lewis stated that at this stage there were no vessels larger than capillaries along the radial, or preaxial border. He first noted the venous channel on the radial side of the limb bud at the 16mm stage. This vein was described as running along the radial side of the forearm, and was termed the radial side of the 'primitive ulnar vein'. It received a connection from the primitive ulnar vein at the elbow and from this junction continued up to the shoulder (Lewis, 1909, p.32). By the 22mm stage the connection with the external jugular was noted. The primitive ulnar vein of Lewis appears to be topographically similar to the vena marginalis of later authors (see below).

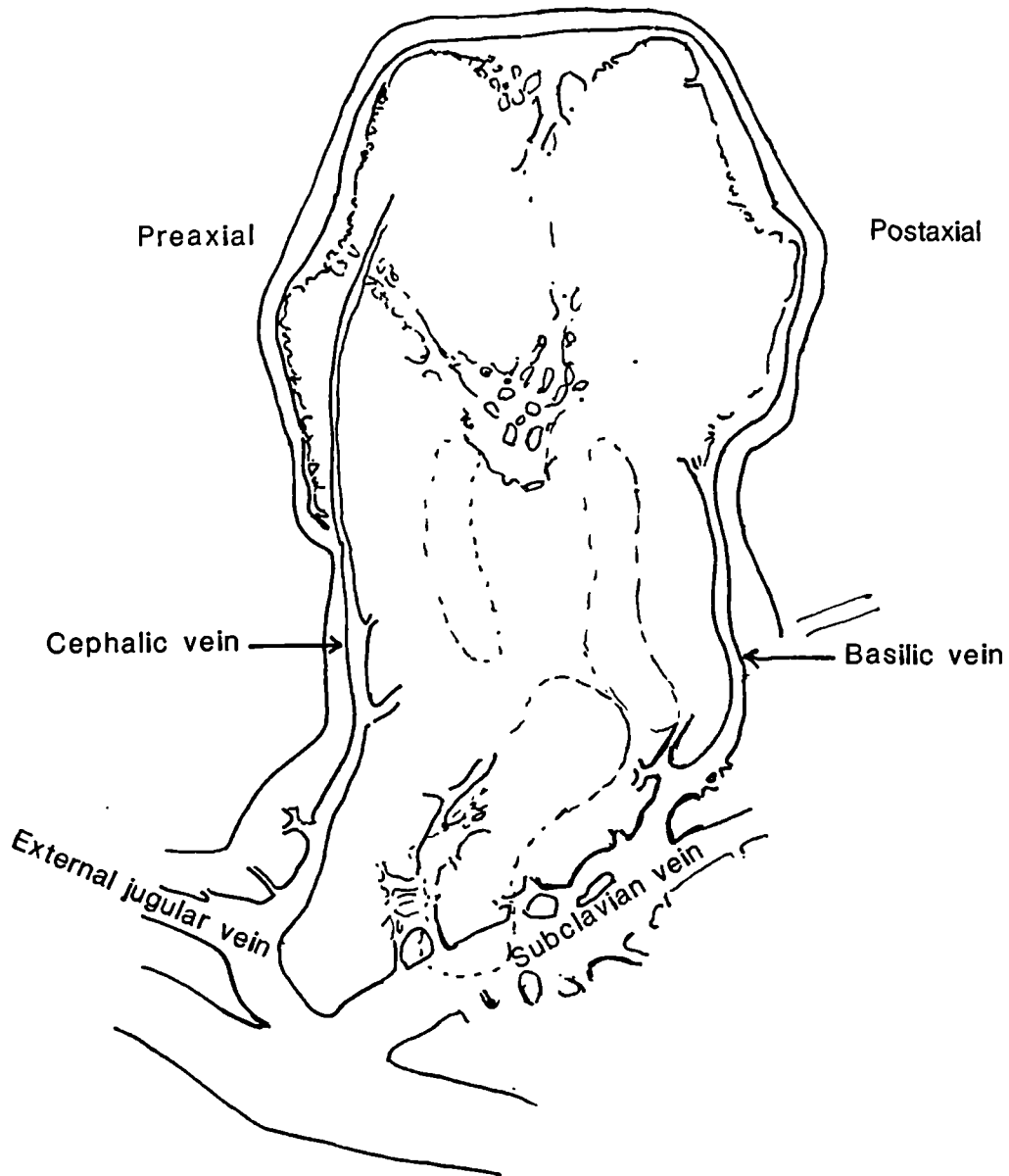
The primitive ulnar vein of Hochstetter and Lewis's rabbit embryos and the vena basilica of the pig embryos seem to correspond to the vena marginalis found on the postaxial side of the human embryonic limb bud described by Blechschmidt (1961) (Figure 3.6). Boyd (1960) noted the presence of a vena marginalis in the CRL 6mm embryo and in

Woollard (1922), in his investigation of the development of the forelimb arteries in early pig embryos, also made detailed observations on the veins. He found a marginal vein along the margins of the limb bud by CRL 8.5mm stage. This marginal vein was well developed on the ulnar or the caudal side of the pig embryo, while on the cranial side it was ill-defined. The marginal vein on the ulnar side was termed, by Woollard, vena basilica. Tracing the development of the veins in the CRL 12mm embryo he noted the complete marginal vein with the vena basilica on the caudal, or ulnar, side and a vena cephalica on the radial, or cranial, side. The vena basilica was larger, and ran along the developing subclavian artery before it terminated in the cardinal vein. The vena cephalica was described as ending in the external jugular. The development of these marginal venous vessels preceded the development of the forearm arteries and their accompanying veins. In the CRL 19mm embryo (Figure 3.5) he noted the digital veins draining mainly into the vena cephalica, while the vena basilica, which directly continued as the subclavian vein, received the veins accompanying the axial arteries of the arm. The fate of the ulnar vein could not be ascertained because this study, unlike those of the rabbit, did not include later embryos.



Rabbit, 17 days. (Redrawn from Lewis, 1905.)

Figure 3.4

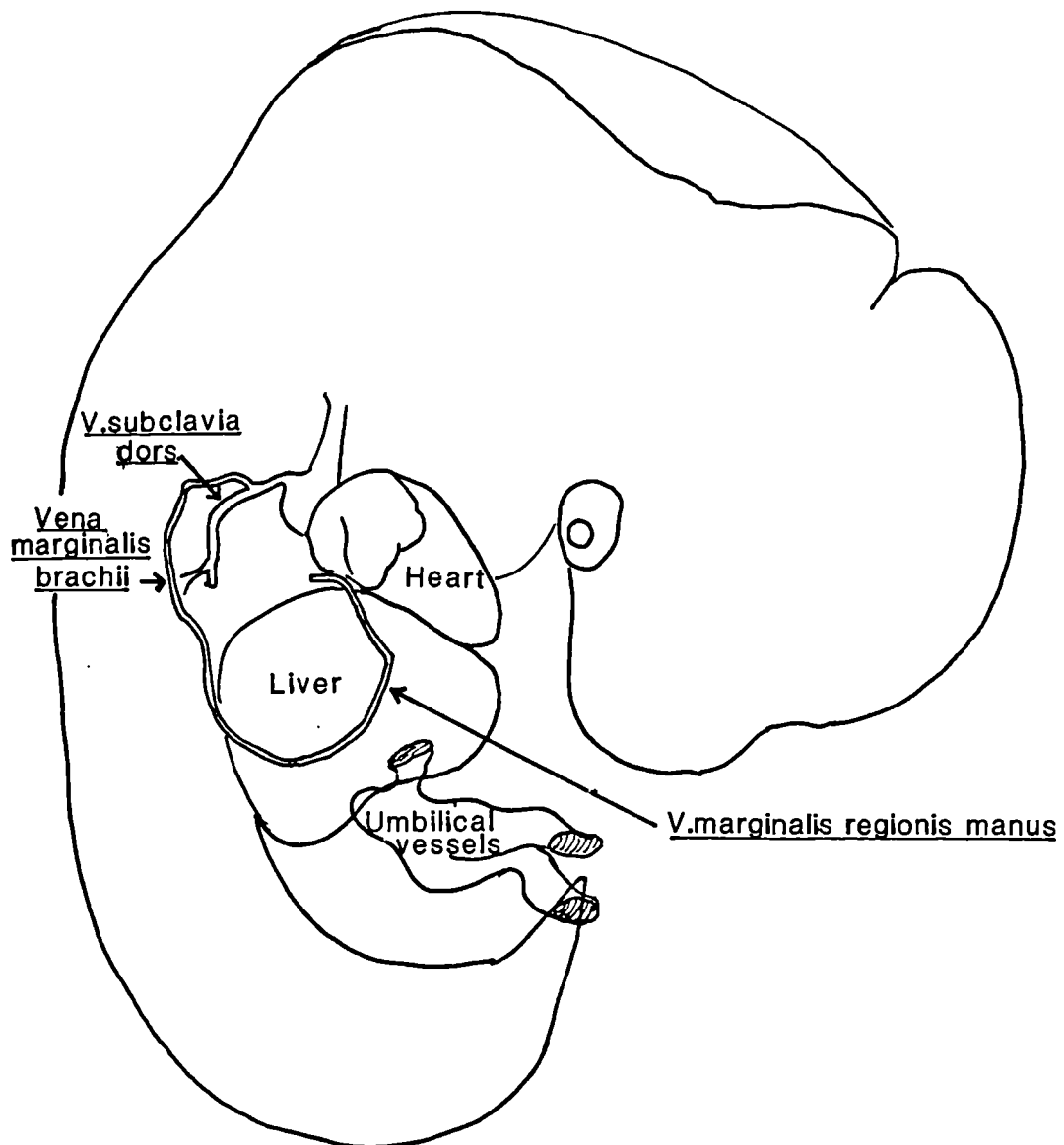


Pig embryo 19mm. (Redrawn from Woollard, 1922, Fig. 5)

Figure 3.5

the 17mm embryo. In the atlas of human embryos depicting the Carnegie and Hooker Humphrey collections of embryos, Raymond Gasser (1975) also notes the vena marginalis. This structure is consistently seen in sections and reconstructions from CRL 10mm (35 days) onwards. Blechschmidt (1961) stated that veins appear in the canalisation zones which are loosened by directional vacuolisation, and that the vena marginalis starts forming when the embryonic skin in the distal end of the limb bud is displaced distally and detached from its support. Boyd considered that the marginal vein, along with the apical ectodermal ridge, may be of considerable importance in the mechanism of growth and differentiation of the bud. According to Boyd (1960) the vasculogenesis is apparent in the early stages. Capillaries appear between the mesodermal cells: these vessels become confluent to form a fine-meshed plexus which taps the differentiating segmental artery at the base of the limb bud. This plexus drains into a vein which passes round the margin of the limb bud and is a striking feature in the embryonic limb bud (Boyd, 1960).

Streeter et al. (1951) in CRL 9 to 10mm human fetuses noted the presence of the primary marginal vein in the digital plate. The reconstructions of the CRL 10mm embryo (Blechschmidt, 1961) show the various parts of this vein (vena marginalis regionis manus, vena marginalis brachii) draining into the vena subclavia dorsalis (Figure 3.6). In the atlas of human embryos (Gasser, 1975) containing the sections from the CRL 18mm embryo (Hooker Humphrey collection) the vena marginalis is noted in the distal as well as the proximal ends of the embryonic limb. In the CRL 30mm embryo, Gasser noted the opening of the cephalic vein under the clavicle. Therefore these



Embryo CRL 10mm

(From Blechschmidt 1961, Fig 84.) Figure 3.6

reconstructions and sections show the presence of a long vein along the postaxial, ulnar, border called the vena marginalis from CRL 10mm (35 days) stage, and a cephalic vein in the 30mm stage (52 days).

The primitive ulnar vein of the rabbit appears to be homologous to the human vena marginalis, and the basilic (the postaxial vein in the adult human) is probably the later presentation of this vena marginalis. Furthermore the hypothesis of Bardeleben that the forearm part of the radial, or preaxial, vein constitutes the primitive vein of the upperlimb is contested by the earlier appearance of the vena marginalis, which is a postaxial vein. The developmental history of the human cephalic (the radial or preaxial vein) is unclear.

The development of the veins can be better understood if one also has an overall view of the major external changes in the limb bud and its orientation to the rest of the body in the rapidly developing embryo. The following account of the external appearance of the limb bud in the embryonic stages are from Streeter's descriptions and the classifications are those of the Carnegie embryo collection.

The development of the limb bud

The limb bud is seen as a definite ridge in Streeter's horizon XIII (CRL 4 or 5mm). In horizon XIV (CRL 6 to 7mm) the arm buds are rounded projecting appendages curving forward and inward. They taper toward the tip, the terminal rim of which will become the hand plate.

(Streeter, 1945, Horizon XIII, XIV). In the CRL 7 to 8mm embryo (Horizon XV) the limb bud becomes regionally subdivided into a distal hand segment and proximal arm and shoulder regions. At CRL 9 to 10mm (Horizon XVI) the rounded hand region has become differentiated into a central carpal part, around whose edge there projects a thick crescentic flange which is to form the digital plate. In transparent specimens one can see the primary marginal vein coursing along the digital plate. By CRL 11 to 13mm (Horizon XVII): the hand plate has now developed finger rays. The hand plate externally begins to show a crenated rim due to the projecting tips of individual digits. At CRL 14 to 16mm (Horizon XVIII) the hands have distinct finger rays, with interdigital notches on their rims; the elbow region can be identified. In CRL 15.5-18mm (Horizon XIX) embryos the axes of the arms are almost at right angles to the dorsal line of the body of the embryo. At a later stage, CRL 21mm-23mm (Horizon XX), the arms are increased in length and slightly bent at the elbows. The hands with their short, stubby, fingers are still far apart, but they are curving slightly over the heart region and approach the lateral margins of the nose. By CRL 22-24mm (Horizon XXI), the fingers are longer and extend farther the ventral body wall than they did in the previous Horizon. The terminal phalanges are swollen and show the beginning of the touch pads. The hands are slightly flexed at the wrist and nearly come together over the heart eminence. At CRL 25 to 28mm (Horizon XXII) the extremities have increased in length, and the digits touch or overlap. Later (CRL 28 to 30mm, Horizon XXIII) the extremities have markedly increased in length and show advancement in the differentiation of their subdivisions. The forearm rises upward to or above the level of the shoulder (Streeter et al 1951).

Comparative studies of limb development in primates

There are few studies on the prenatal ontogeny of forelimb of the non-human primates, though primatologists of an earlier era have made careful studies of the material available. Regarding the development of the the venous system of the limbs, there is no detailed information though the general development of the anterior limb and its skeletal structures are dealt with at fair length. The very early development, from the initial appearance of the limb buds, are reported by Osman Hill (1937) for the Grey Langur (Presbytis entellus). The limb bud appears by CRL 9mm (Hill estimates that this stage corresponds to a 5th week human embryo). The anterior limb buds at this stage are flattened flipper-shaped structures laid closely against the embryo's trunk. By CRL 15mm the forelimbs are more elongated and cylindrical, and the distal third has been flattened out and moulded into the hand plate. The five digits are differentiating in the hand plate, and their extreme tips are free, the rest being completely webbed. By CRL 24.5mm the forelimbs show further elongation and joint formation. The elbow is now evident and the hand plate has given rise to digits. The digits also show the ventral swelling in their terminal portion. The nail beds are seen, though no nails are yet visible. These changes show that the early development of this primate's forelimb bud follows the same stages as humans in proceeding from general to special.

However, other ontogenetic studies, mainly by Schultz on Colobus (1924), Macaca (Schultz, 1937), Pan (Schultz, 1940) and Pongo

(Schultz, 1941) also throw some light on the general trends within the primates. Schultz found that the ontogenetic decrease in the relative length of the thumb is the rule among the primates (Schultz 1926, 1933) but can occur at different periods of growth and can assume widely differing intensities in the different taxa. In Colobus (Schultz, 1924) and in Presbytis (Hill, 1937) the thumb is rudimentary and is small compared to the other digits quite early in development. However in Pan and Pongo this relative shortness occurs gradually and is fully established only later in prenatal ontogeny. In all primates, including humans, there seems to be an increased growth of the forearm relative to the upper arm in pre- and postnatal ontogeny. This also occurs gradually, with the least difference being in the early stages (Schultz, 1926, 1933). These comparative studies show the gradual development of specificities, of the structures in the forelimb in these primates. Moreover comparative ontogenetic studies are valuable in providing a basis for understanding the general trends in the development of forelimb structures and are necessary framework for interpreting any study of the veins of the forelimb.

MATERIALS AND METHODS

Serial sections were stained with Hemotoxylin and Eosin and Masson's trichrome (aniline blue was used instead of light green). Fifteen embryos and early foetuses ranging from CRL 6mm to CRL 31mm were examined under the light microscope. Eight formaline fixed foetuses were dissected with the aid of a dissecting microscope (magnification

x 10), these specimens ranged from CRL 60mm (10weeks) to CRL 140mm (17 weeks), together with one nearly full term foetus. The sample deliberately included a high proportion of early embryos in order to supplement the data available to Bardeleben and because information about such early stages is essential if the ontogeny is to be properly understood. The serial sections studied were part of earlier series made for other purposes, and the collection, particularly from CRL 14mm and above, did not have sections from the whole length of the limb bud. The parts of the limb bud which by chance got included in the sections had a varying orientation. While recognizing the limitations of the lack of complete serial sections and reconstructions as suggested by previous workers (Lewis, 1905), I have attempted to glean as much information as possible from these serial sections. All specimens except two were from the Alder Hey Children's Hospital Department of Anatomy; the exceptions belonged to the Department of Human Anatomy, University of Liverpool. The estimation of the age of the embryos was made on the basis of their crown rump length (CRL). In human prenatal phases of ontogeny the embryonic period is defined as up to the seventh week or 48 days, while the foetal period runs from the eighth week to birth. The pre- and postaxial sides of the limb bud are defined in relation to their proximity to the cephalic or caudal poles of the embryo respectively.

RESULTS

CRL 6mm, 30 days (Specimen No. H 2097): Upper limb bud is seen on the lateral side of the embryo as a mesenchymal elevation (Figure 3.7).

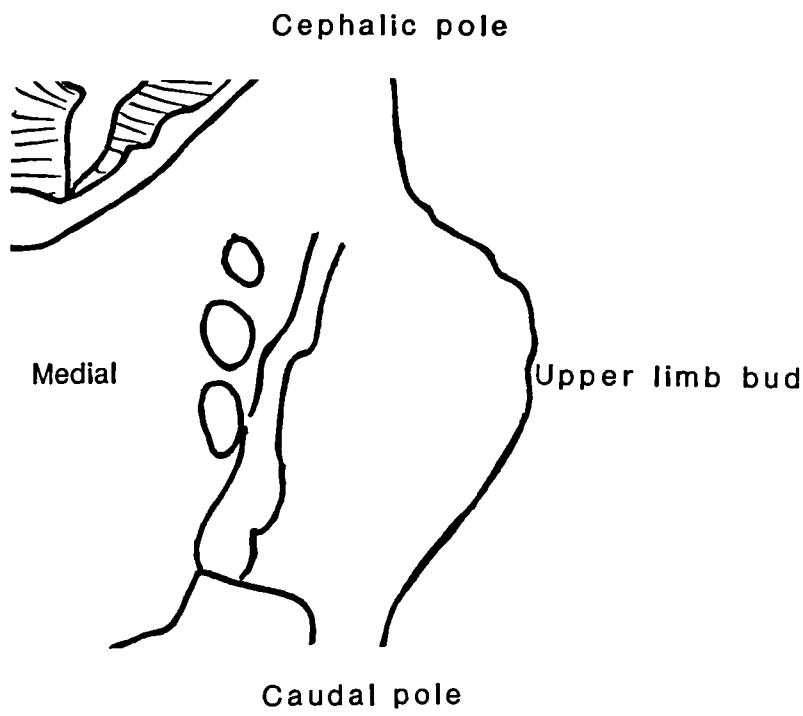
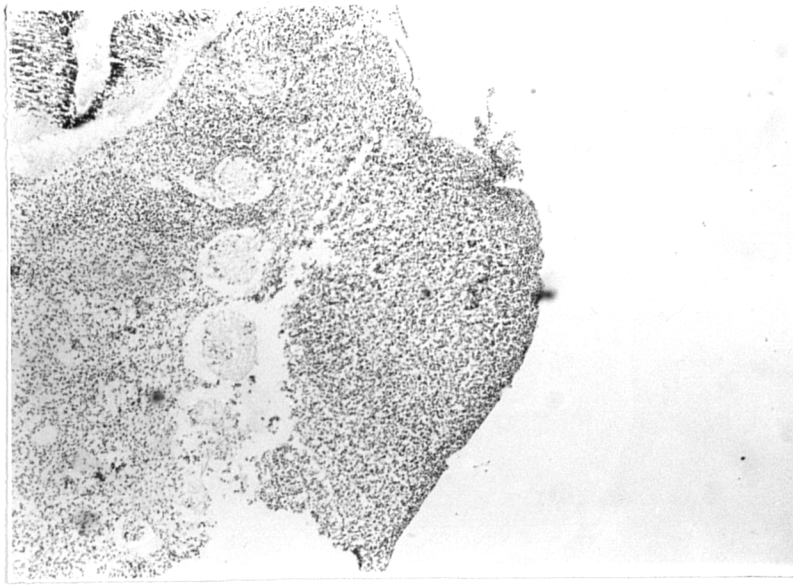


Figure 3.7 CRL 6mm X16

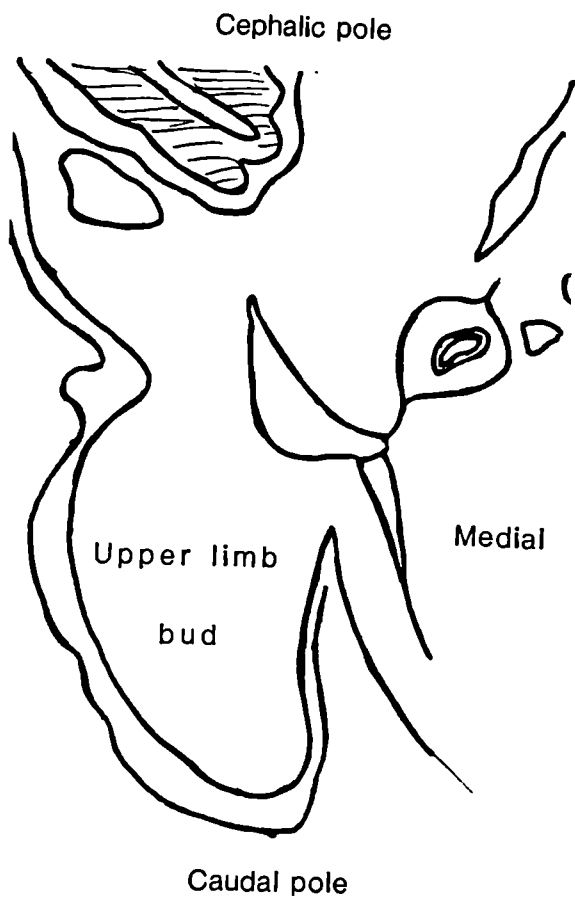
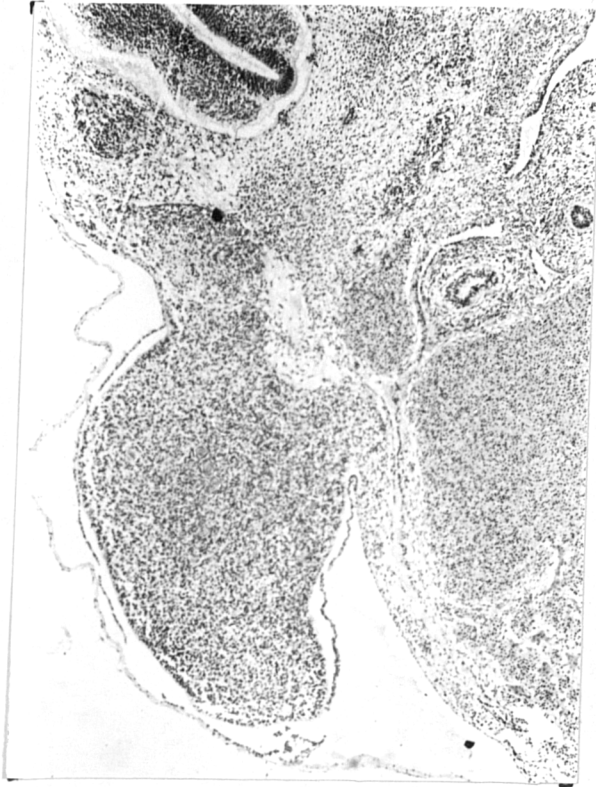


Figure 3.8 CRL 9mm X 16

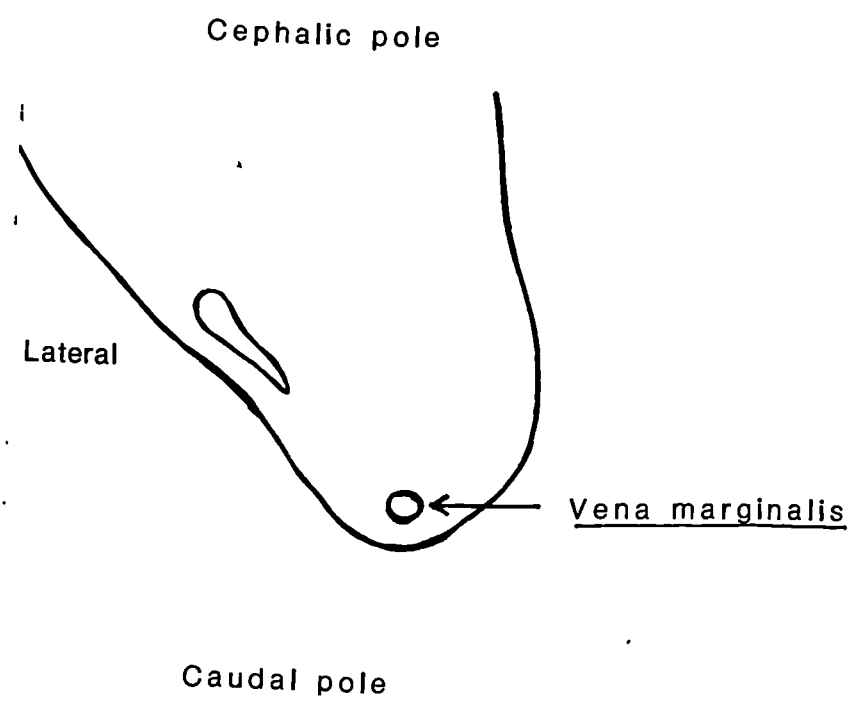
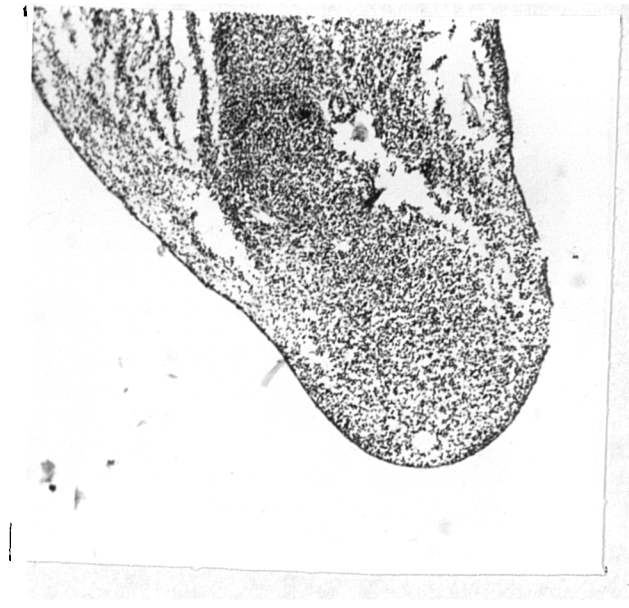


Figure 3.9 CRL 11mm Upper limb bud X 16

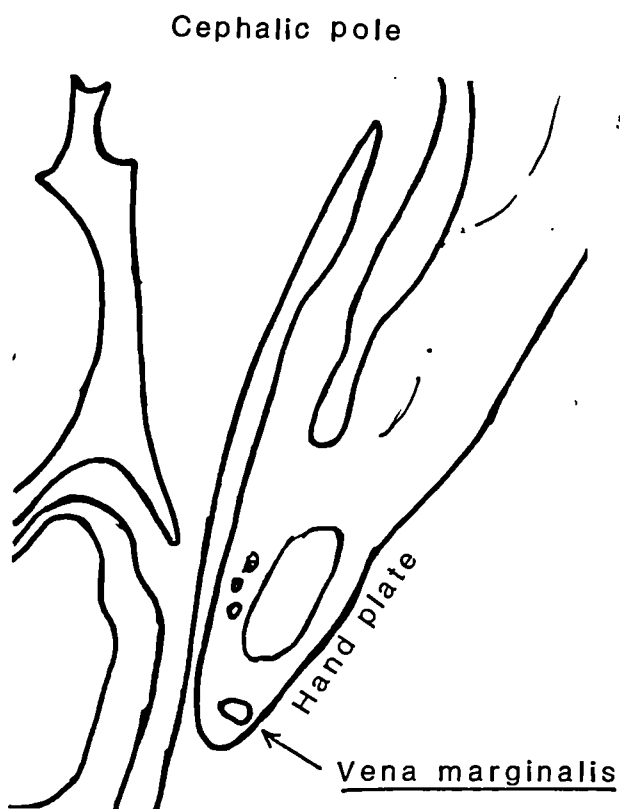
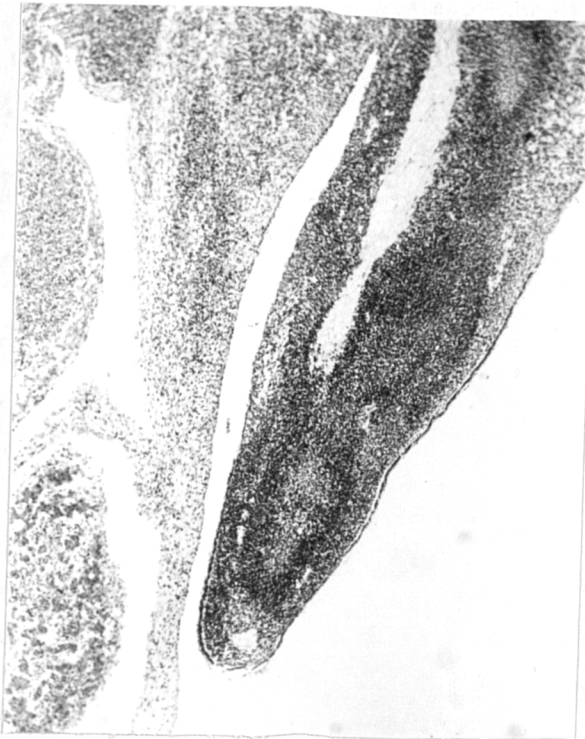

Figure 3.10

CRL 14mm

X 16

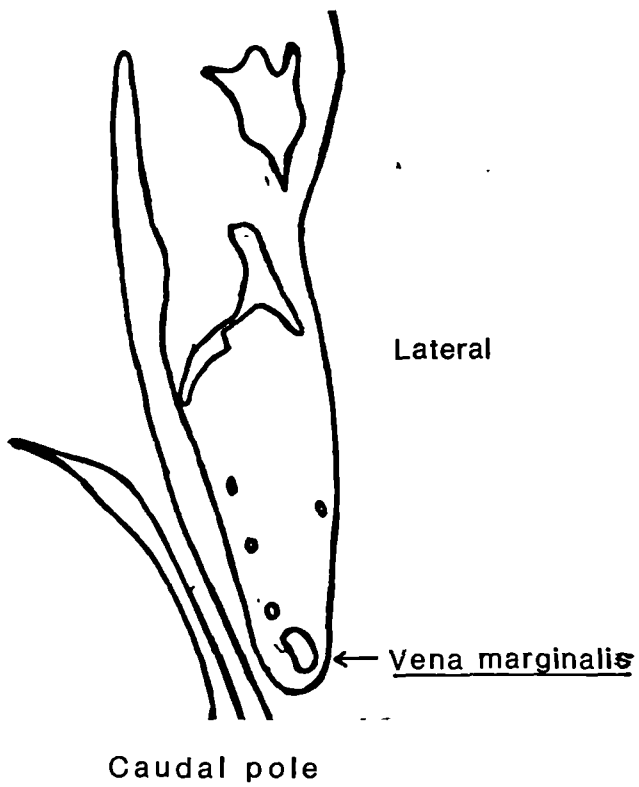
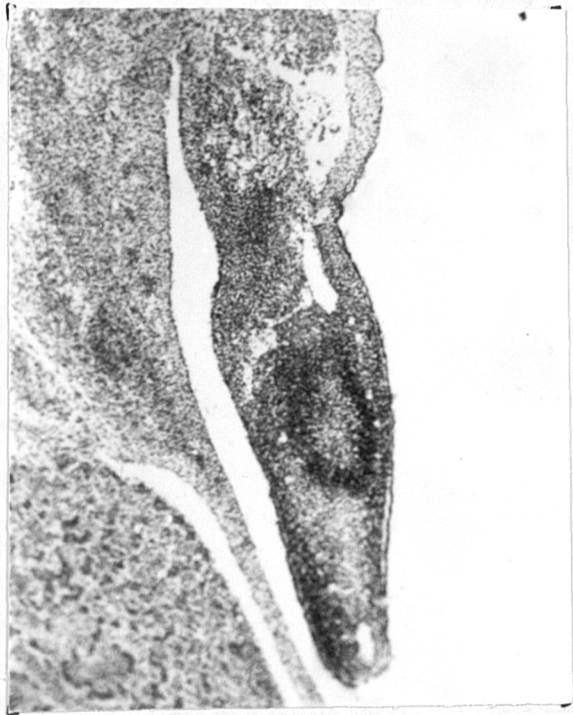

Figure 3.11

CRL14mm

X 16

CRL 9mm, 33 days (Specimen No. 425): The limb bud is filled with dense mesenchyme and covered by the ectoderm (Figure 3.8).

CRL 11mm, 35 days (Specimen No. H 944): The marginal vein is seen under the ectoderm at the distal edge of the limb bud section (Figure 3.9).

CRL 14mm, 37 days (Specimen No. 343): The primitive hand plate is the most developed area and the vena marginalis is seen as an area of canalisation along the hand plate (Figures 3.10, 3.11).

CRL 16mm, 37-40 days (H 1847, H 1923): Arm, forearm and hand areas become evident. In the hand plate skeletal elements are well seen, as are the veins on the dorsal surface. Also seen are veins following the digital grooves which can be noted both on the preaxial (lateral) and postaxial (medial) sides (Figure 3.12, H 1923). These veins are seen external, or superficial, to the developing muscle masses. In the distal part of the upper arm (Figure 3.13, H 1847) veins on both the postaxial (medial) and preaxial (lateral) side are seen; the nerves are also seen on the medial side. More proximally in the upper arm (Figures 3.14 and 3.15, H1847) veins are seen on the lateral and medial sides of the arm. The sections show the medial vein connecting with larger vessels in the axillary region and it is related to the nerves medially (Figures 3.14 and 3.16). Further proximally or cephalically (Figure 3.16, H 1923 and Figure 3.15, H 1847) the lateral, or preaxial, vein is seen to connect with the veins in the superficial region of the neck as well as to a larger

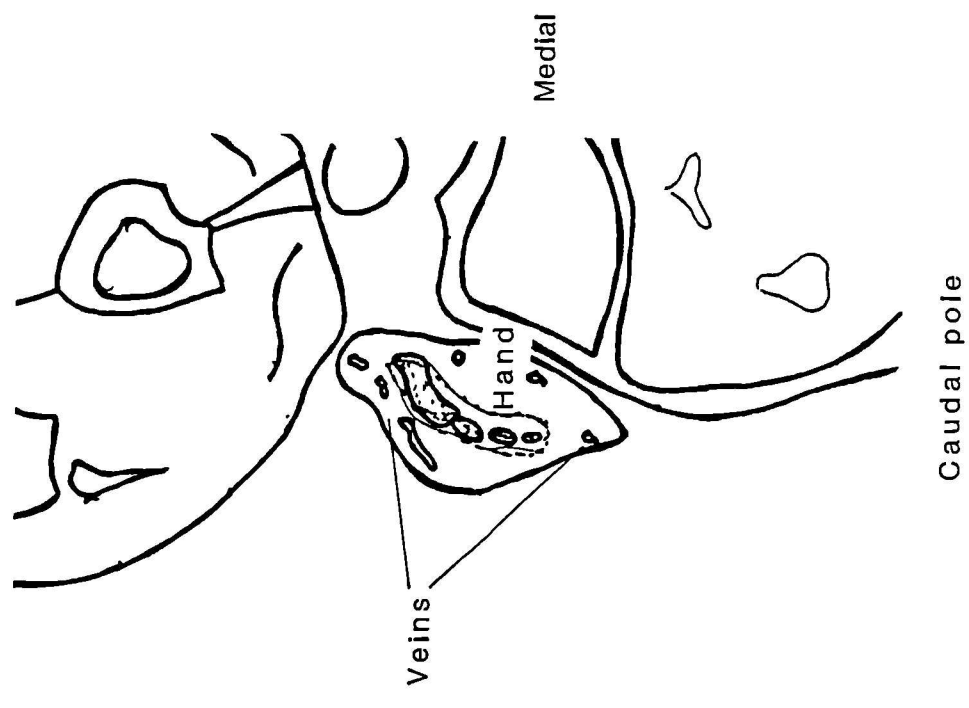
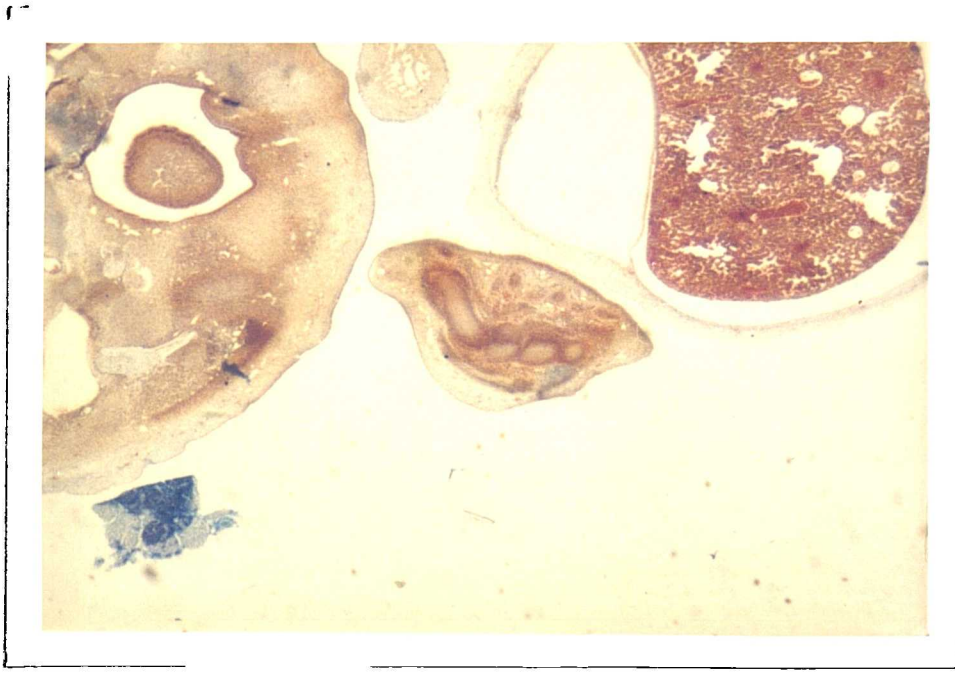


Figure 3.12

CRL 16mm

X 6.3

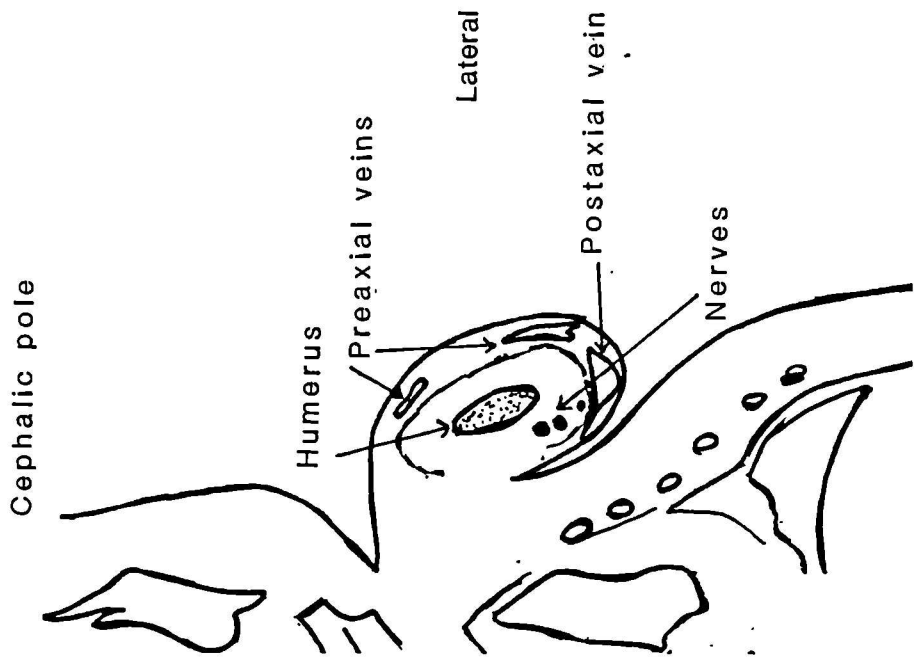
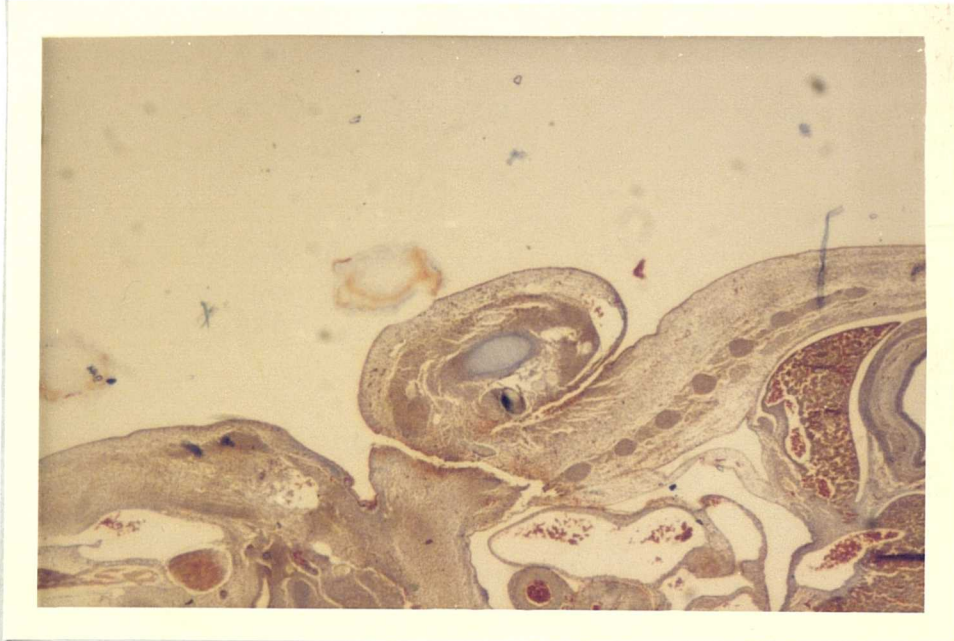


Figure 3.13

CRL 16mm

X 6.3 :- Distal upper arm

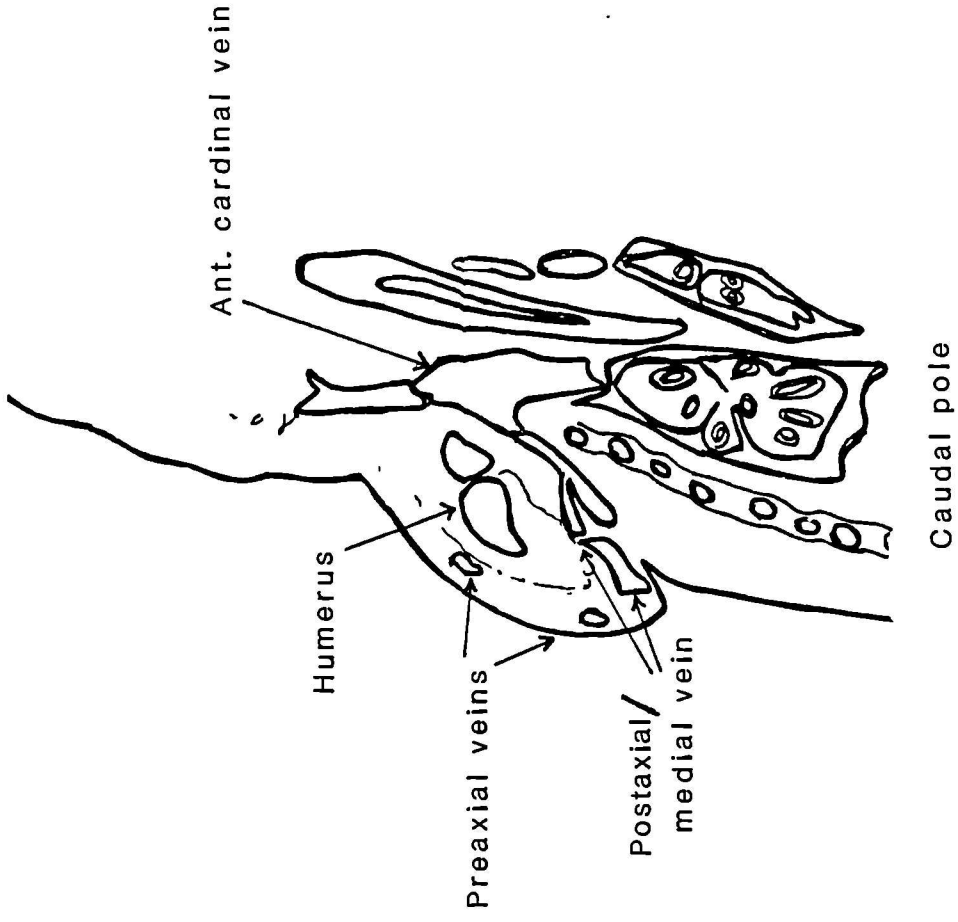
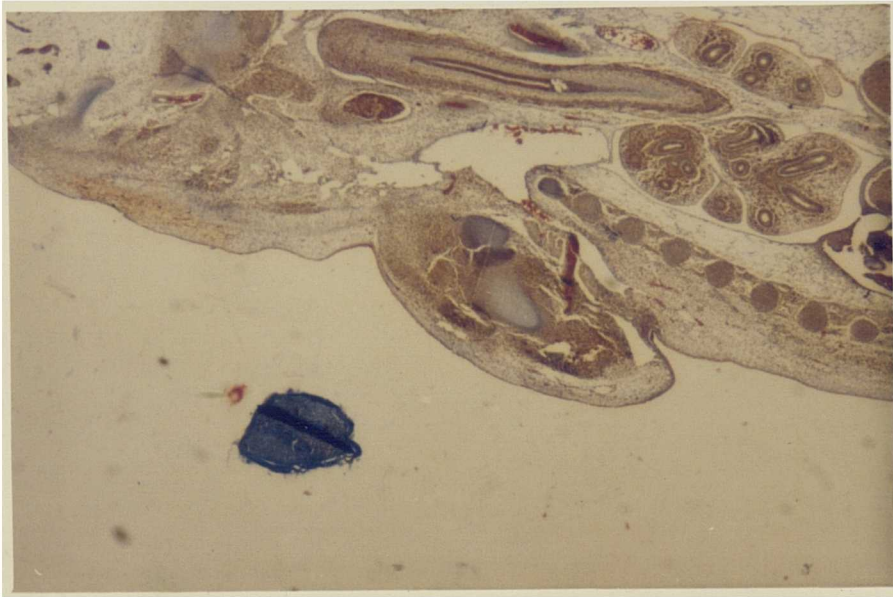


Figure 3.14 CRL 16mm

X 6.3

Shoulder region

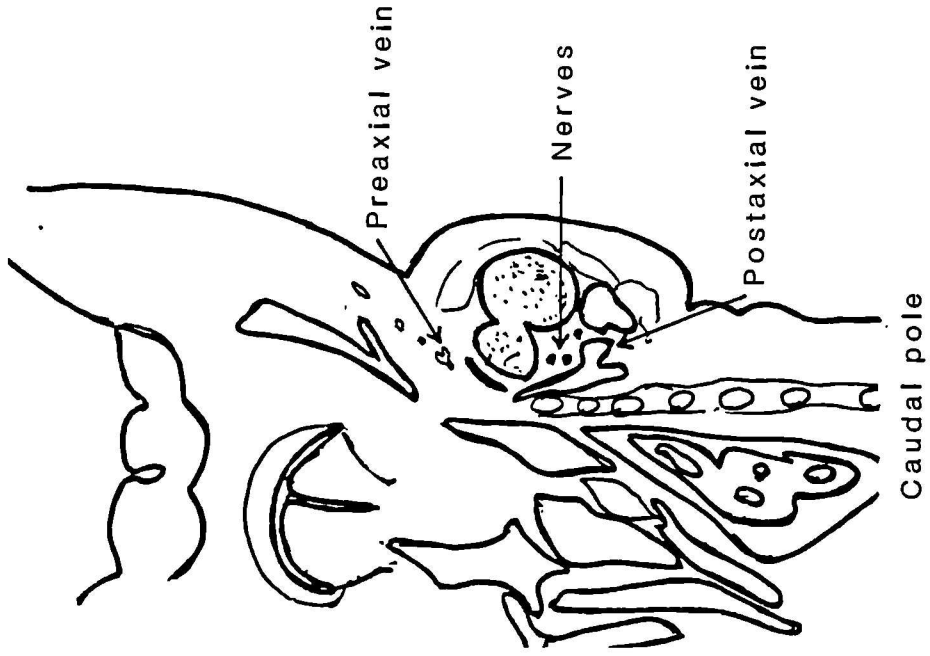
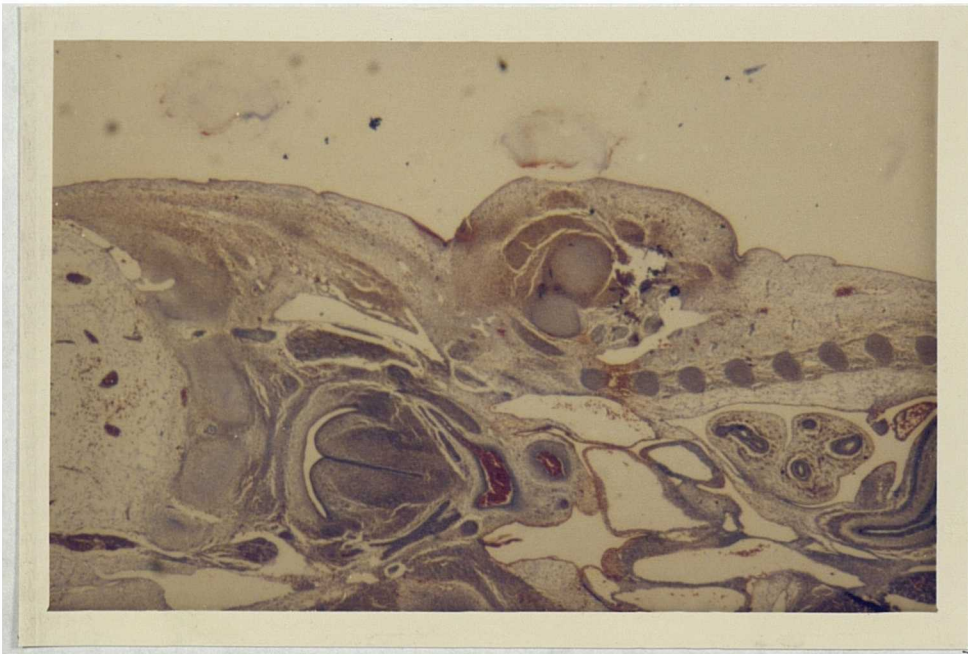


Figure 3.15

CRL 16mm

X 6.3

Shoulder region

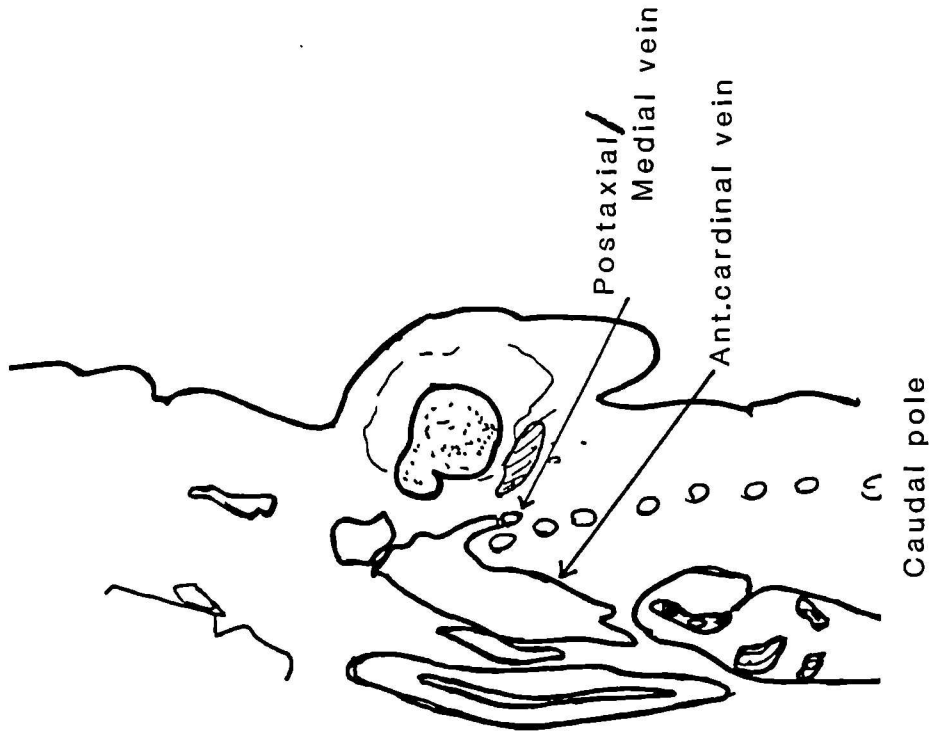
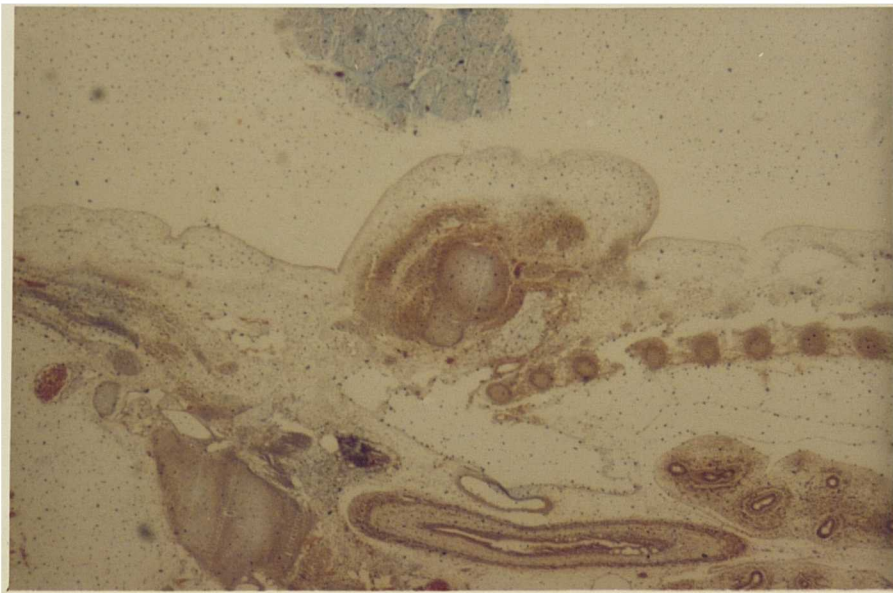
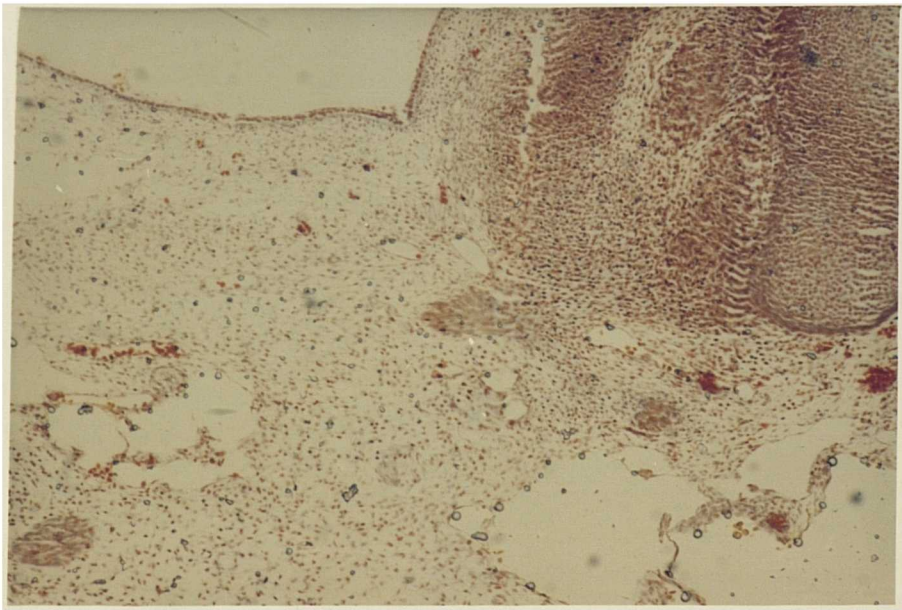
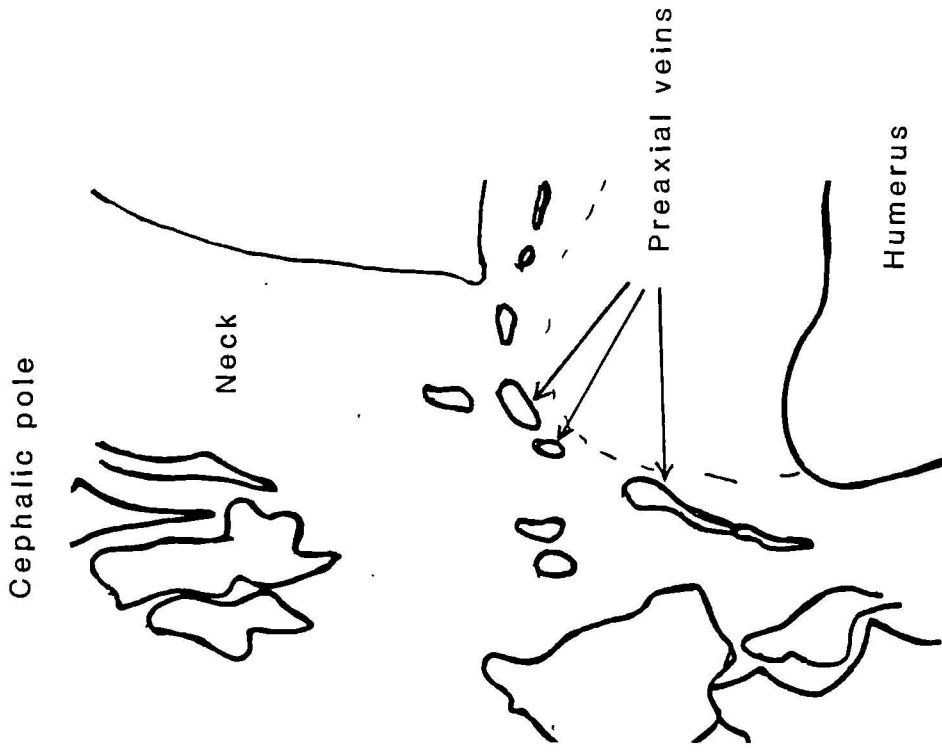


Figure 3.16

CRL 16mm

6.3

Shoulder and axillary region



Shoulder region

X 16

CRL 16 mm

Figure 3.17

vessel in the base of the neck. A higher power view of this region is seen in Figure 3.17, H 1923, showing the connection between the lateral, or preaxial veins (running superficial to the developing muscle masses) and a larger vein in the base of the neck region.

The sections of the proximal part of the upperarm at this stage (CRL 16mm) show the independent connection of both pre-and postaxial venous lines. This finding could be assumed to indicate that by this stage there might be two venous channels pre-and postaxial with their separate termination points into larger axial veins.

CRL 18mm, 37-40 days (H 1901): Veins on the lateral (preaxial) and medial (postaxial) sides of the limb. (Figure 3.18, H 1901). The medial vein continues as the large vessel on the medial side of the upper arm along with the nerves (Figure 3.19, H 1901). A higher-powered view of the cephalic pole of the developing humerus shows the lateral, or preaxial, venous line leading medially superficial to the developing muscle masses covering the cartilaginous skeleton (Figure 3.20, H 1907).

CRL 21mm. 40 days (H 2155, H 2214): The sections available show the digital superficial veins (Figure 3.21, H 2155) and in the sections of the upper thoracic region the developing clavicle and the infraclavicular opening of the vein (presumably the opening of the cephalic, or lateral, vein of the limb) (Figure 3.22, H 2214).

CRL 25mm, 45 days (H 1624): At this stage the veins are clearly delineated. The section of the hand shows the venous arch and the

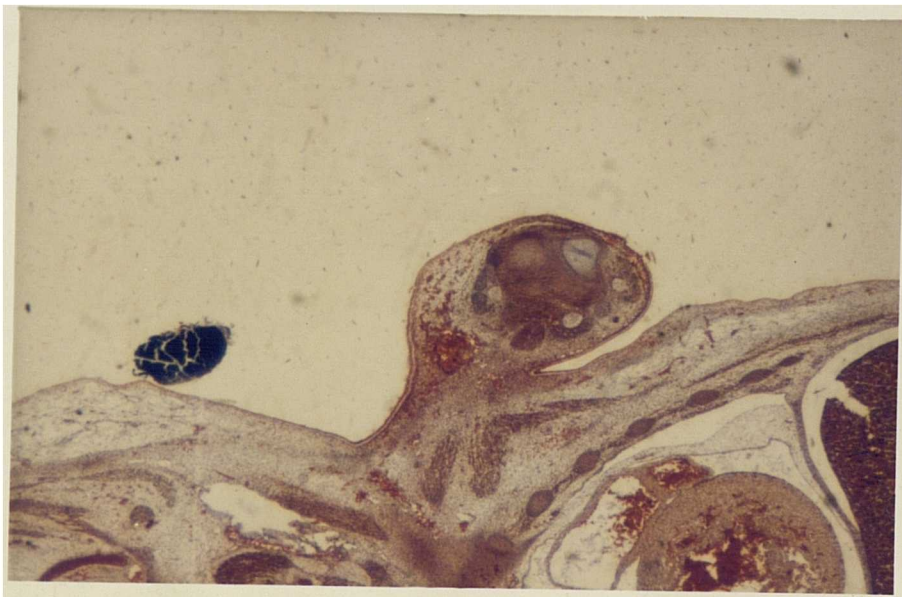
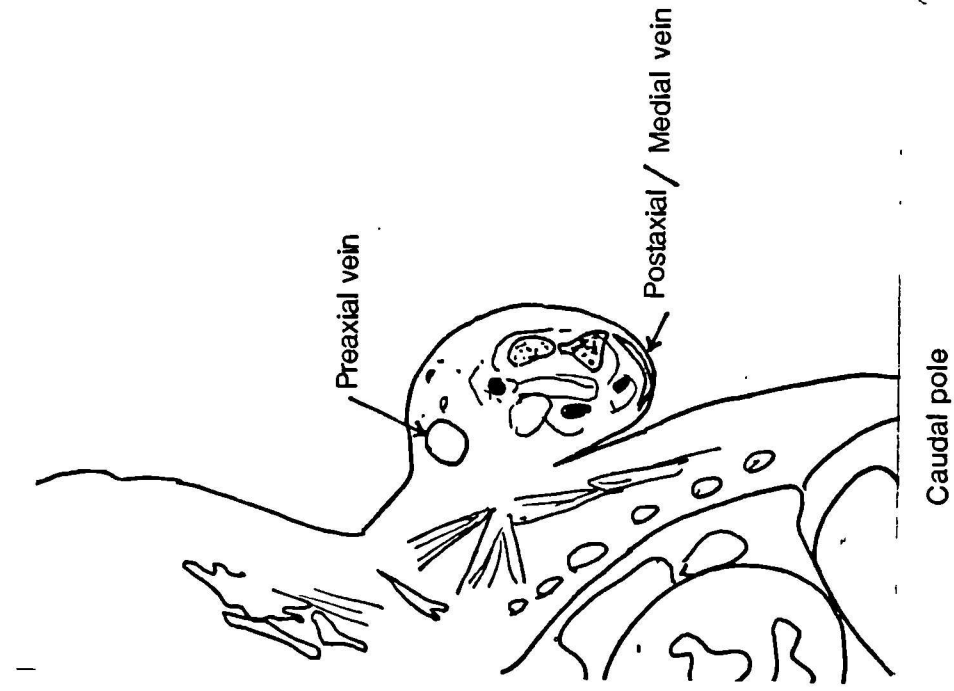


Figure 3.18

CRL 18 mm

X 6.3

Distal upper arm

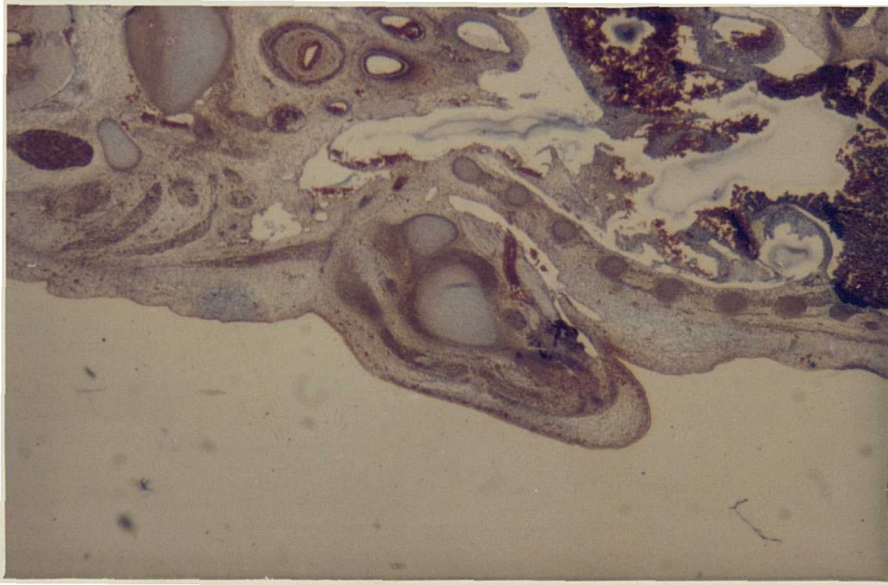
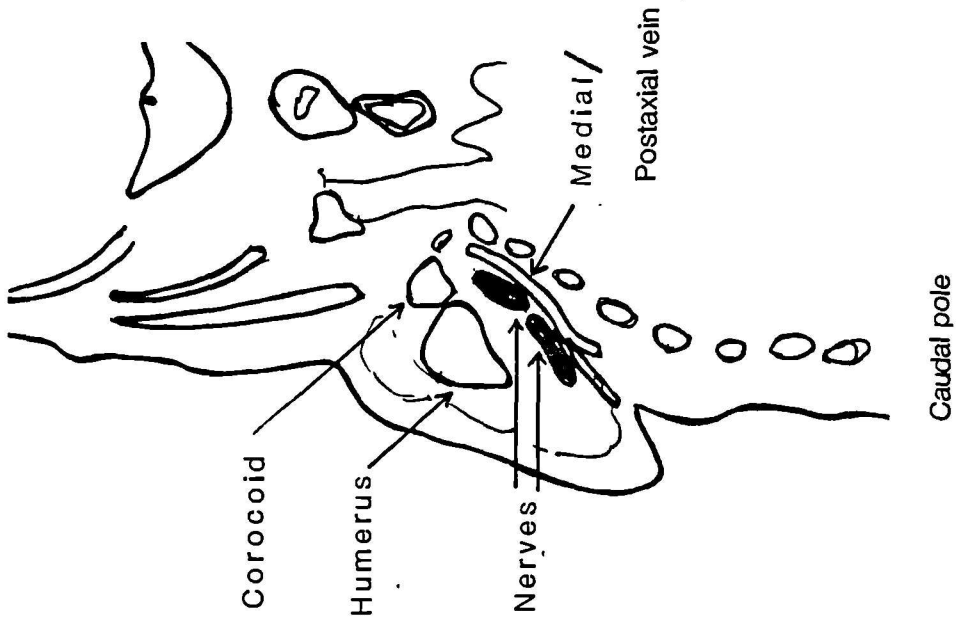
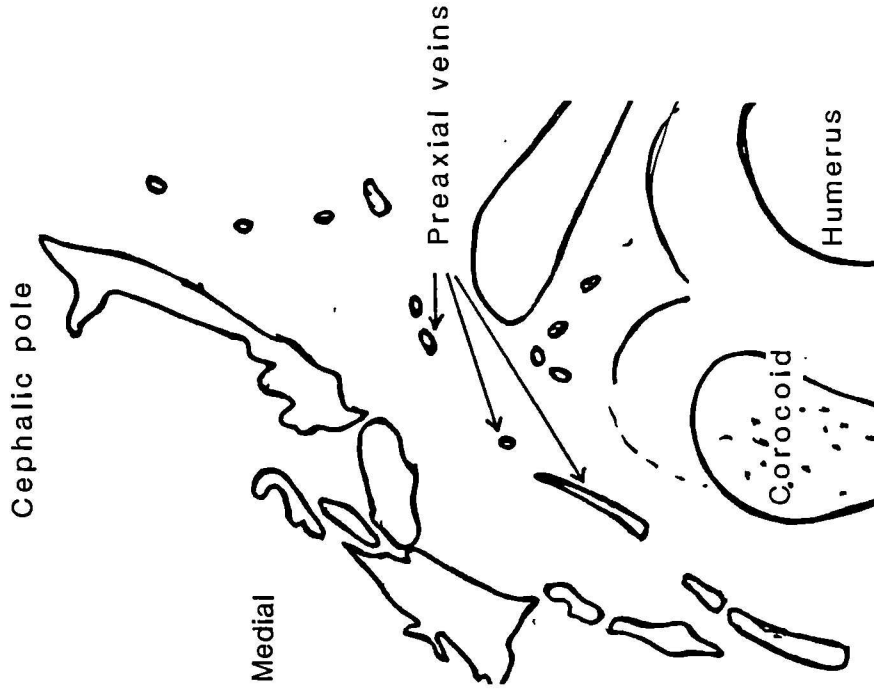
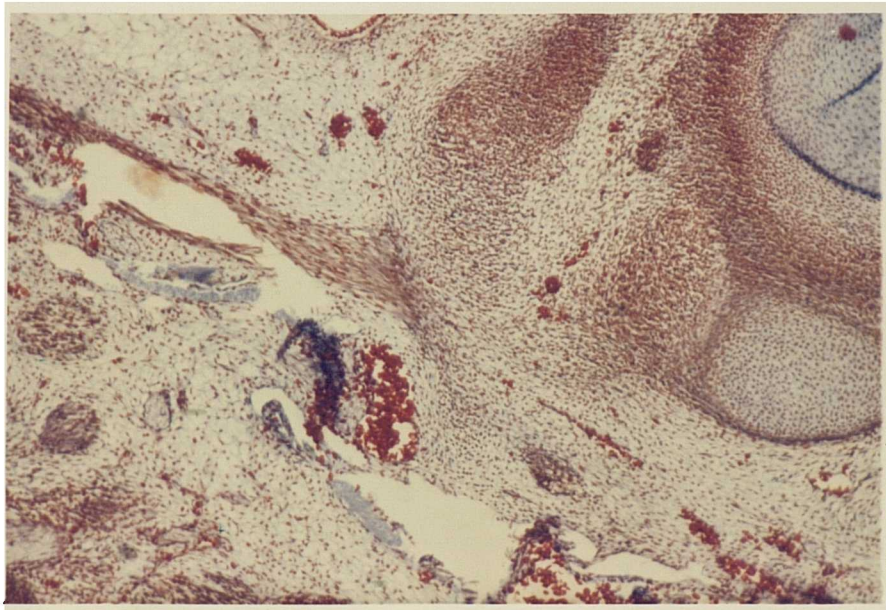


Figure 3.19 CRL 18mm X 6.3

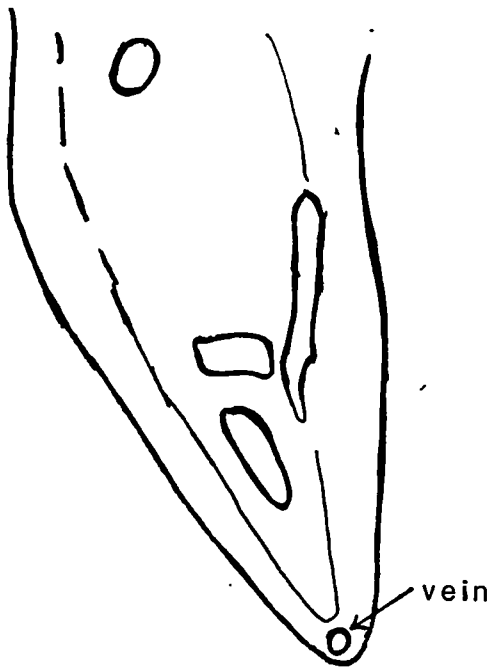
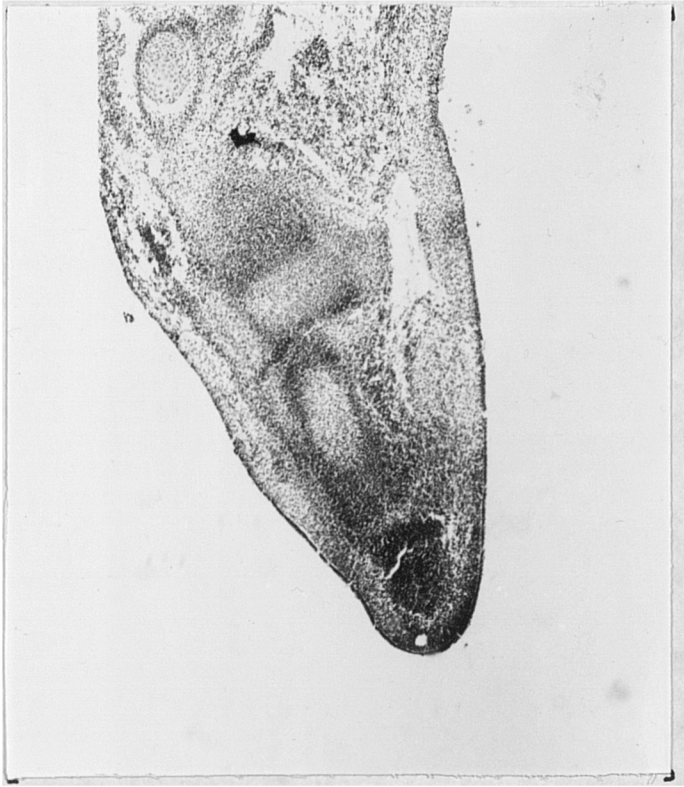

Shoulder region

X 16

CRL 18mm

Figure 3.20



Caudal pole

Figure 3.21

CRL21mm

X 16

Digit

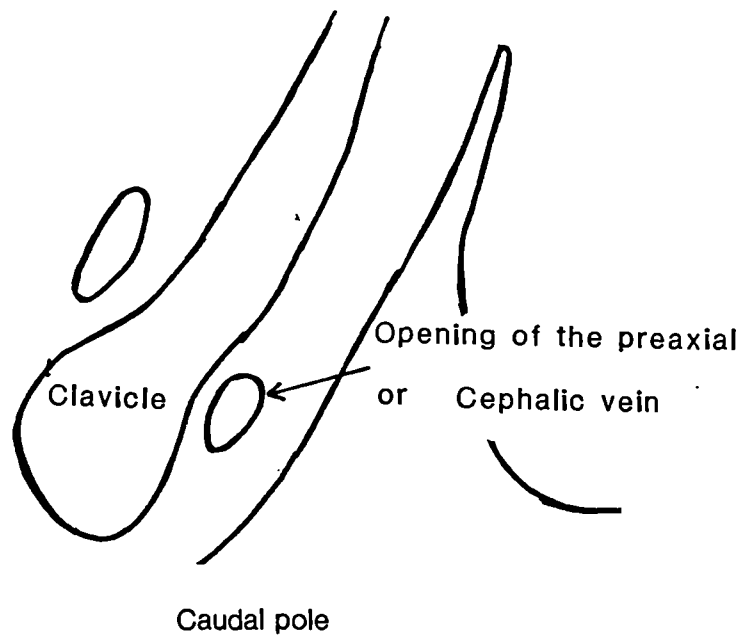
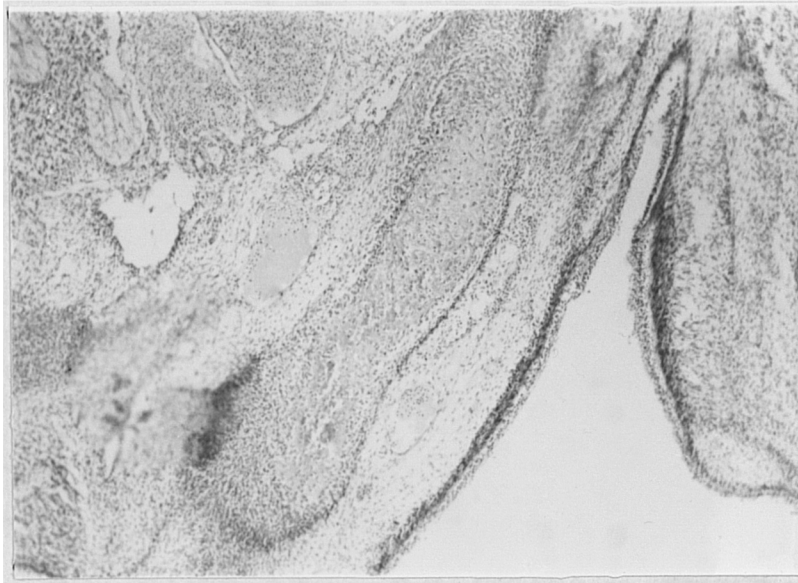


Figure 3.22

CRL21mm

X 16

Upper thoracic region

well-defined veins on the lateral, or preaxial, and the medial, or postaxial, side of the carpus (Figure 3.23). In the upper arm region the veins in the deltopectoral groove, and those superficial to the deltoid along with their interconnections are clearly seen (Figures 3.24).

CRL 31mm, (H 1848) and CRL 31mm, (H 2156), 48-56 days: The available sections are those of the upper arm. H 1848 (Figure 3.25) shows the vessels on the lateral, or preaxial, and medial, or postaxial, sides of the upper arm in the superficial region. More detailed information could not be obtained from this specimen as there were no sections available of more ventral regions of the upper arm. The upper thoracic region sections of H 2156 (Figure 3.26) show the developing clavicle, the developing muscle masses of deltoid and the pectoralis major and the cephalic vein in the deltopectoral groove and its infraclavicular opening.

Macroscopic anatomy of Foetuses aged 10 weeks and older

Foetus 10 wks. (CRL approx 60mm): All three foetuses (Nos. 2864, 2525 and 2646), i.e. six limbs, showed extensive superficial venous plexuses in the upper limb. The plexuses over the deltoid were continuous with those in the neck. They also showed a long preaxial, or lateral, (cephalic) vein running from the dorsal venous arch to the clavicular region. The postaxial or medial vein (basilic) in the forearm was also clearly visible.

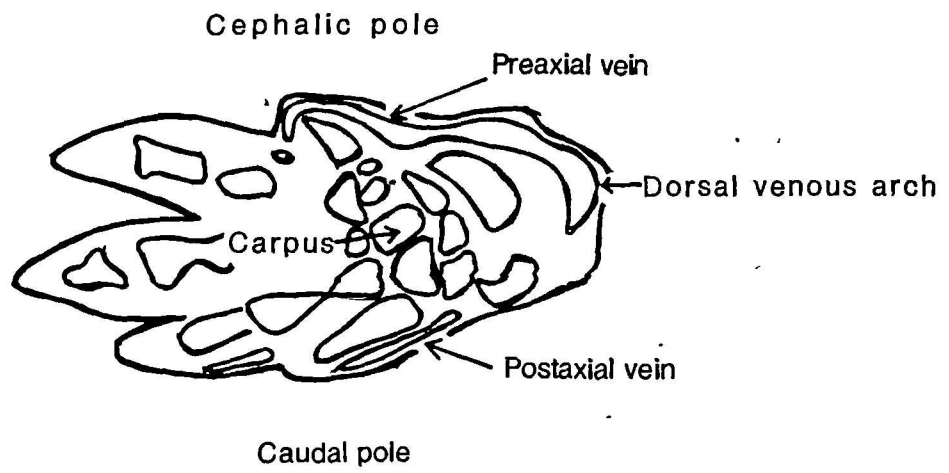
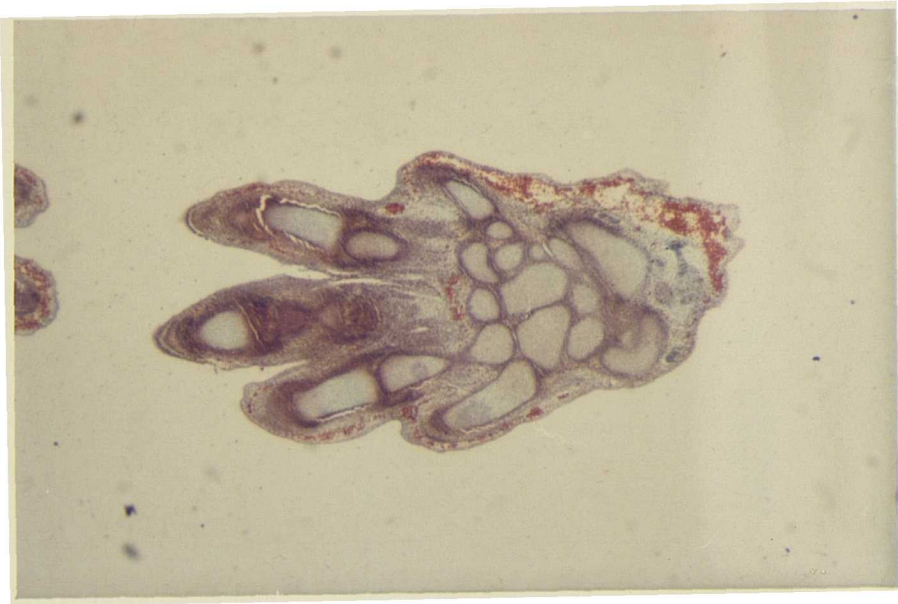

Figure 3.23

CRL25mm

x 6.3

Hand

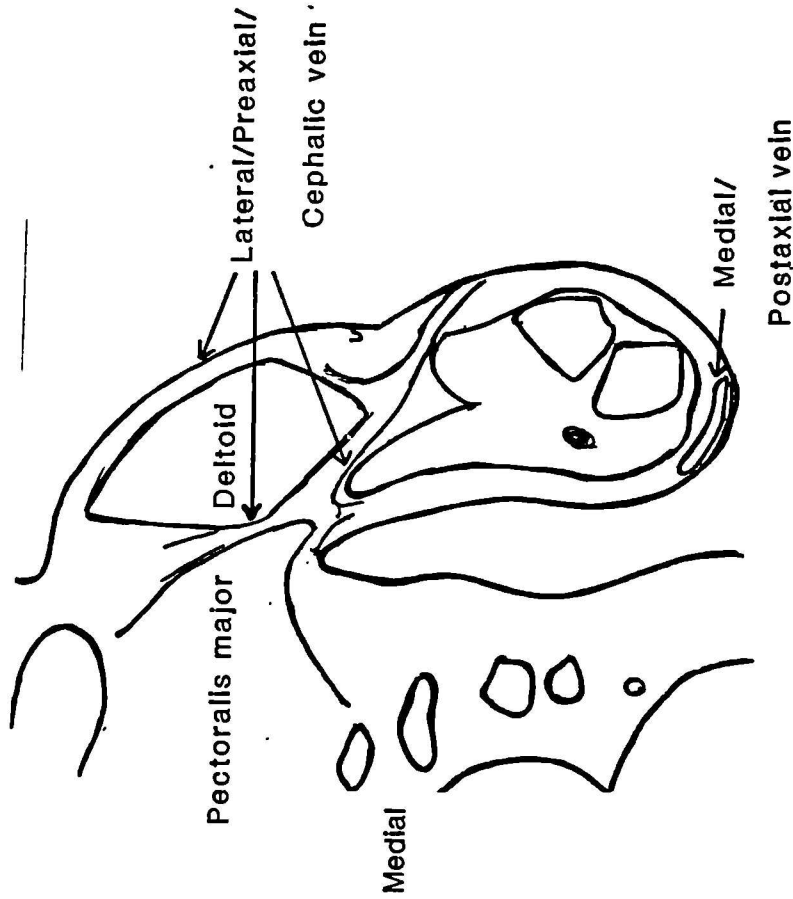
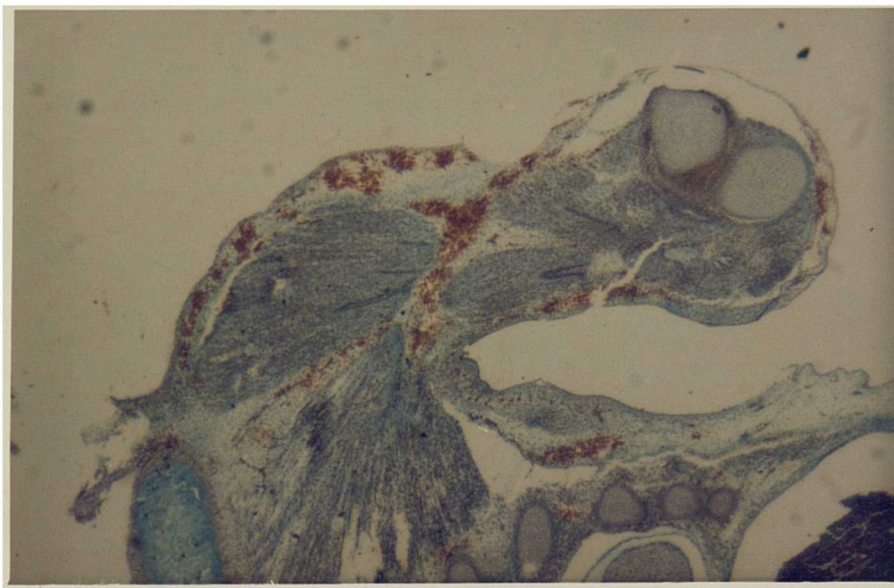
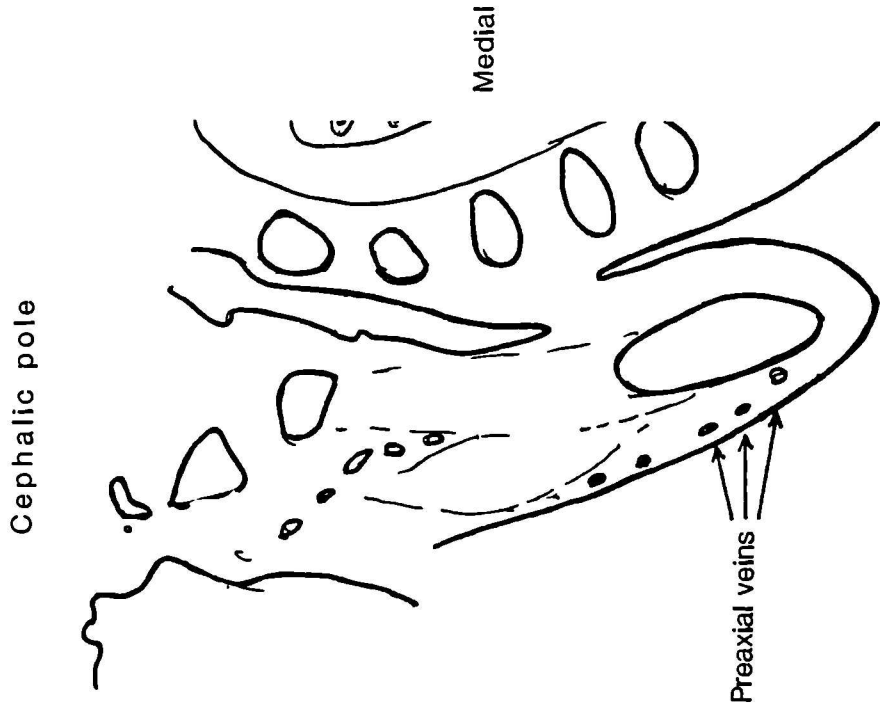
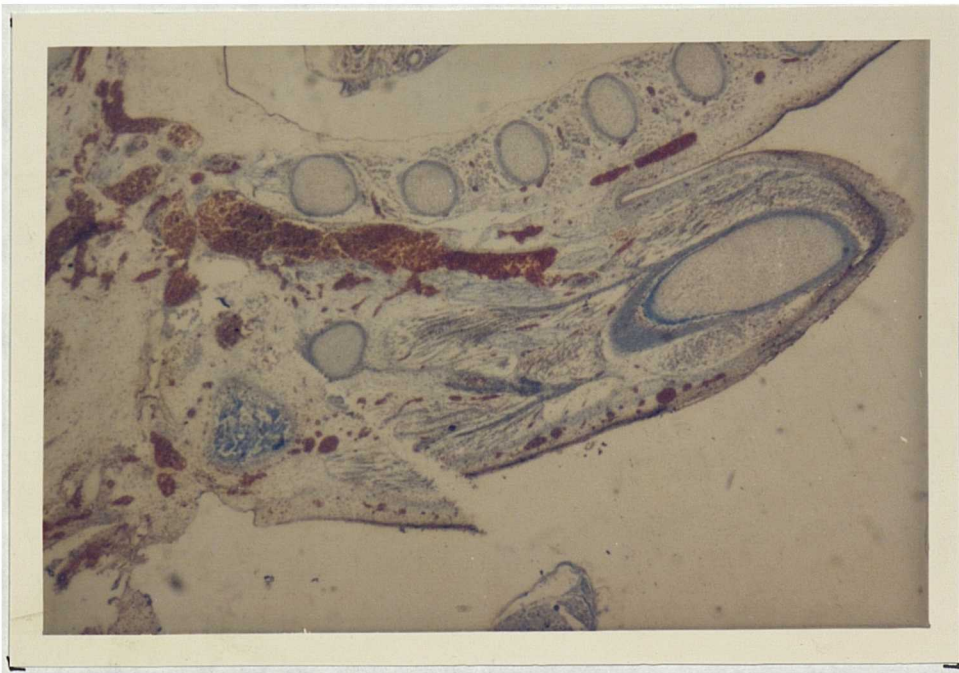


Figure 3.24 CRL 25mm X 6.3 Upper arm



upper arm

X 6.3

CRL31mm

Figure 3.25

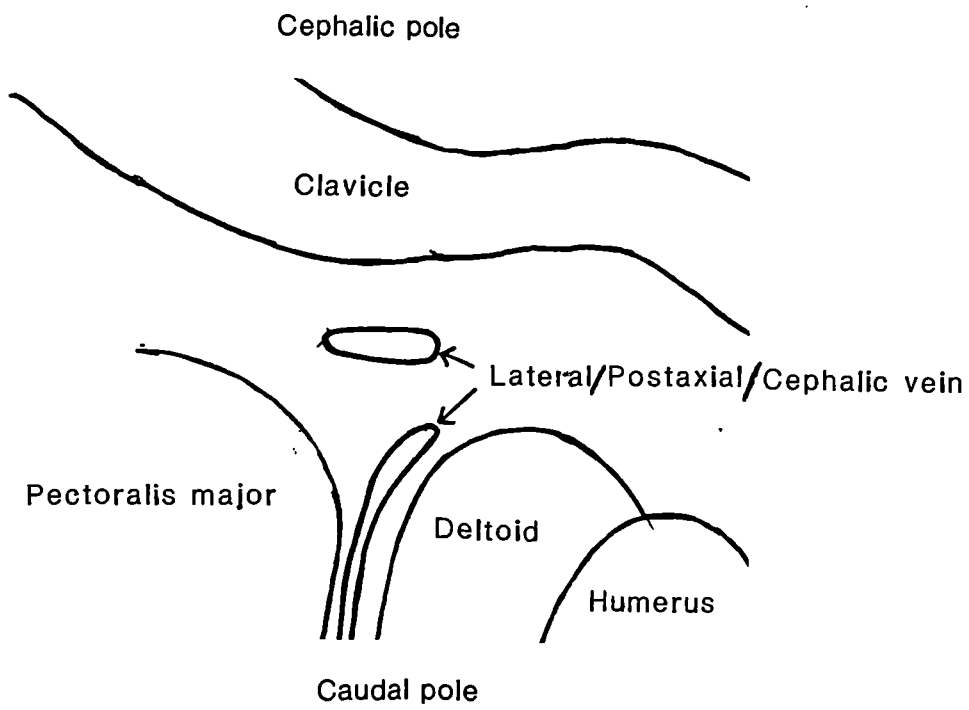
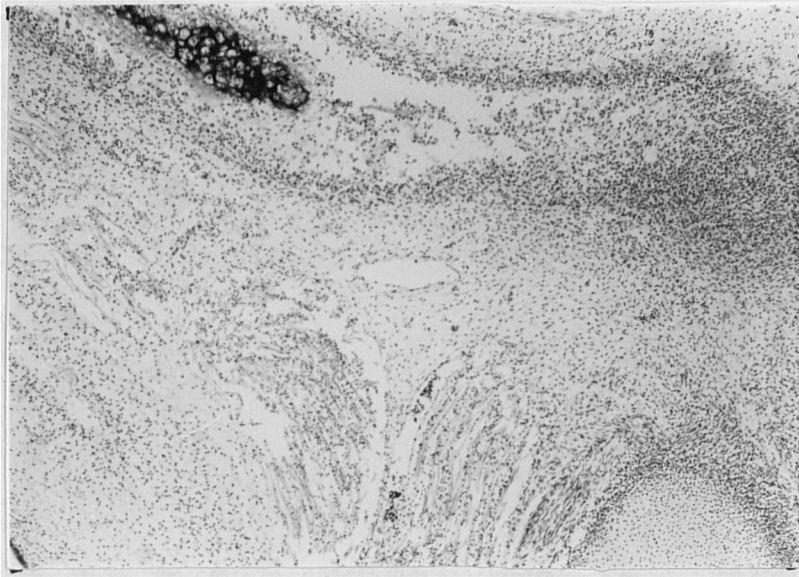


Figure 3.26

CRL 31mm

x 16

Upper thoracic region

Foetus 11 wks. (CRL 80mm, No. 2581): Both limbs had a single long preaxial, or lateral, (cephalic) vein (up to the clavicle). The single postaxial or medial vein (basilic) was also seen in the forearm. Apart from these two veins there were plexuses of veins interconnecting them.

Foetuses (2) 12 wks. (CRL approx 90mm, Nos. 2867, 2832, Anat. F1): In all six limbs the preaxial vein (cephalic) coursed up to the clavicle. In one pair of limbs (those of foetus No. 2832) the preaxial vein (cephalic) had a connection with the external jugular. On the medial side the postaxial vein (basilic) was noted in the forearm and upper arm where it continued as the axillary.

Foetus 13 wks. (CRL 115mm, No. 2860): The right limb showed a preaxial (cephalic) vein extending up to the clavicle, while on the left side the same vein travelled only as far as the deltoid. The postaxial (basilic) vein was also observed along with its continuation into the upper arm to the axilla; this medial vein continued as the axillary.

Foetuses 14 wks. (CRL approx 120mm, Nos. 2830 and 2918): The preaxial (cephalic) extended up to the clavicle. The postaxial (basilic) vein and the deep vein in the cubital fossa were also noted. For the first time veins accompanying the radial and ulnar arteries were seen.

Foetus 17 wks. (CRL 140mm, No. 2840): Both limbs presented all the components described above,

Foetus 3B wks. (CRL 360mm, No. F.2): The limb presented with a cephalic or lateral vein extending proximally to the infraclavicular fossa. A medial or basilic vein was also present, and the lateral vein connected with the deep veins in the cubital fossa. There was also an extensive plexus of veins establishing connections between the main veins in the superficial fascia.

Summary

In the present series of embryos studied, the veins are one of the earliest structures seen in the developing limb bud. The earliest vein develops under the ectoderm and can be demonstrated from the CRL 11mm stage (33-35 days). The anatomical position of this vein in the CRL 11mm, and subsequent, embryos studied corresponds to that of the structure described as the vena marginalis by Boyd (1960), Bleschmidt (1961) and Gasser (1975).

In the CRL 16mm (37 to 40 days) embryos, the sections studied show a vein on the preaxial side in addition to the postaxial vena marginalis. At this stage the long axes of the arms are almost at right angles to the dorsal line of the body of the embryo and the three regions (hand, forearm and upper arm) have become demarcated. The hand exhibits an early stage of formation of the digits, or the finger rays, in the hand plate. Thus the CRL 16mm embryo is the earliest to show a preaxial vein in this series. All subsequent embryonic stages show this preaxial vein and its position relative to

the axis of the limb bud. The preaxial vein unlike that of the postaxial vein, lies superficial to the developing muscle masses throughout (i.e. in the hand, forearm and upper arm). The postaxial vein in the hand and in the distal upper arm also lies superficial to the developing muscle masses in the 16mm CRL embryo, but in the proximal upper arm it is closely related to the deeper nerves and connects with larger venous vessels in the axilla.

In later embryos, further development of the preaxial, or lateral, vein is seen. The opening for the vein in the infraclavicular fossa, and its course in the deltopectoral groove, are noted in the CRL 21, 25 and 31mm embryos. Superficial venous development is a generalised phenomenon in the areas studied in these embryos; there are many superficial veins present in the neck and there is a continuity between them and the superficial veins of the limb bud.

Both the preaxial, or lateral (cephalic), vein and the postaxial, or medial (basilic), vein are well-defined by 10 weeks and the medial vein in the upper arm continues as the axillary vein. In the forearm, though the radial and ulnar artery were clearly seen, it was only between 13 to 14 weeks that their accompanying veins could be readily visualised. One of the later foetuses presented a variation in that one of its limbs had a preaxial, or lateral, (cephalic), vein up to the deltoid while the contralateral limb in the same foetus had a preaxial, or lateral, (cephalic) vein up to the clavicle. Such an arrangement i.e. cephalic up to the deltoid, was noted in six limbs by Bardeleben (1880b) in later foetuses.

The pre- and postaxial veins develop in the early embryonic stages, the postaxial being the earliest. These veins resemble their adult presentation by the end of the 7th week. The postaxial vein of the embryo is homologous with the adult basilic of the fore- and upper arm and the continuation the axillary vein. The preaxial is homologous in the cephalic vein in the adult.

The 'short' type preaxial vein i.e preaxial vein only in the forearm, or up to the deltoid was noted by Bardeleben (1880b) in 12 out of 36 foetal limbs. In this study a vein extending only up to the deltoid was noted in one foetal limb (CRL approx 115mm). Moreover the limbs showing the 'short' type were all from embryos and fetuses later than CRL 24mm stage (Bardeleben's earliest embryo was CRL 24mm). This study shows that in all the embryos from stages CRL 25mm and earlier, the preaxial vein presents with the connection to the veins in the base of the neck or infraclavicular region. Therefore as far the analysis of early embryos are concerned it is reasonable to conclude that the preaxial vein is a long vein and extends from hand region to the base of the neck, or the infraclavicular fossa when clavicle could be well delineated in the sections. This finding is supported by the description of the preaxial vein in the rabbit and the pig as extending to the external jugular by Hochstetter (1891) and Lewis (1905) and Woollard (1922).

The findings in this study support the findings of Hochstetter (1891) and Lewis (1905) and Woollard (1922) by showing that the postaxial, or the medial, vein preceded the preaxial or lateral, vein. This therefore contradicts Bardeleben's (1880b) hypothesis of the

primitiveness of the forearm part of the lateral vein which he names vena capitalis brachii. Moreover the findings of the present study support the development of a long (from hand to clavicle) preaxial, or lateral, vein as one entity. This contradicts Bardeleben's (1880b) hypothesis that the upper arm part (cephalica humeri) of the lateral vein is a tributary of the main forearm part and that it is a later development. The findings in the present study on the developmental history of the preaxial, or lateral vein is in agreement with Lewis's (1905) and Woollard's (1922) findings in the rabbit and pig embryos respectively where it is noted that the preaxial vein extends to the external jugular from the first instance of appearance. Furthermore, these findings are in agreement with those of Lewis (1909) who identified the postaxial vein in human embryos from the 10mm stage, while the preaxial vein first appeared in a 16mm embryo in which the fore- and upper arm parts were well defined. Therefore the present study corroborates the hypothesis of Hochstetter (1891) and Lewis (1905) rather than the hypothesis of Bardeleben (1880b) on the developmental history of the forelimb veins.

CHAPTER 4: PHYLOGENETIC INFERENCES

"Relationships and types of relationships between man and nature, between man and his environment. Relationships and types of relationships among the individual or collective components of society. To speak of these is to speak of history, but it is also to speak of culture."

Amilcar Cabral

INTRODUCTION

Character phylogeny

The study of comparative anatomy allows us to establish the extent of any morphological similarities between species. These similarities can be classified into two distinct kinds. Similarities may be homologies, shared by simple reason of descent and history. Alternatively, similarities can be analogies developed independently, but having the same form and thus effect. Such characters often develop as evolutionary responses to common situations (Gould, 1986). The latter derive from a range of evolutionary processes often subsumed under the term "convergence", meaning the independent evolution of similar structures in different lineages. Examples of such processes are "homoiology" (analogies on a homologous base: e.g. the wings of birds and bats - Riedl, 1979), mimicry, chance similarity and "true" convergence (e.g. fins in sharks and marine mammals).

Homology is any similarity between organisms that is inherited from a common ancestor of the organisms. Thus, homologies are the basis of establishing phylogenetic relationships, since relationship between organisms speaks only of this genealogical or historical relationship and nothing else. Methods of establishing homologies and the means of testing them have been described by Patterson 1982a (see introductory chapter). Hennig clearly stated how the concept of phylogenetic relationship should be articulated. According to Hennig "Phylogenetic relationship" is thus a relative concept. It is pointless (since it is self-evident) to say, as is often said, that a species or species-group is "phylogenetically related" to another. The question is rather one of knowing whether a species or species-group is more or less closely related to another than to a third. The measurement of the degree of phylogenetic relationship is, as the definition of the concept shows, "recency of common ancestry". (Hennig, 1965, pp.97-8).

Thus, as Hennig shows, it is not simply any homologous structures that will establish the phylogenetic relationship between organisms but those homologous characters that have been inherited from the most recent common ancestor. For example, two relatively unspecialised species may appear similar to each other (due to both inheriting many primitive homologous structures from a distant common ancestor), yet may have a closer common ancestor with a different (more specialised) species that has lost some, or all, of the primitive structures that characterise the first two.

Phylogenetic systematics (classifying organisms based on their phylogenetic relationship) attempts to reconstruct the phylogenetic history of a group of species by discovering evolutionary novelties (specialisations, apomorphies) that are shared by some members of the group and not others. Each member of the group is found to have a 'sister group', that is one other to which it is most closely related, as indicated by their mutual possession of so-called shared derived, or synapomorphic, characters that are not found in other groups. These sister group pairs will be related in larger groupings signified again by different sets of shared derived characters. Such groupings are not only united by common ancestry, but they must constitute all the descendants of that ancestor. The distribution of a series synapomorphies across the group defines a nested pattern that can be represented as a cladogram. The branching pattern of the cladogram depicts the order of divergence of the lineages leading from the common ancestor of the groups right up to the individual species themselves. Each branching point on the cladogram will be defined by one or more synapomorphies that must be possessed by all descendants of that node. This methodology, using only genealogical connections and shared special, or derived, characters for the basis for such connections, underlines the primacy of historical processes in analysing the relationships between organisms and establishes a framework for tackling questions of function and adaptation.

Given that the identification of shared derived characters is the key to successful phylogenetic reconstruction, how can we decide which of two homologous character states is primitive, and which is derived? According to Szalay (1977) this is the single most important

theoretical issue of phylogenetic inference. Nelson (1978) and Bonde (1984), among others, consider that two methods are of prime importance in polarity determination: these are ontogeny and the outgroup comparison method. Nelson calls the ontogenetic argument the 'direct' method. The ontogenetic argument, which he regarded as a restatement of the biogenetic law (of Haeckel) is that "given an ontogenetic character transformation, from a character observed to be more general to a character observed to be less general, the more general character is primitive and the less general advanced" (Nelson, 1978, p.327). By 'generality', Nelson means the occurrence of character x (more general) in species A and B, in contrast to the occurrence of character y (less general) only in species B.

Patterson (1982b) also states that embryology is the only direct evidence of transformation of form, but he attributes this insight to Karl E. von Baer (1828) rather than to Haeckel. It was von Baer who stated that in development the general characters appear before special ones, and Patterson clearly states that the resolution by ontogeny of character polarity depends on the latter and not Haeckel. Haeckel's biogenetic law was based on the mistaken theory that ancestral adult states are squeezed into the descendants' ontogenies by terminal addition and condensation. In contrast, von Baer had already stated that in their development the embryos of animals pass through no adult stage of another animal. To Nelson the profound differences between von Baer's and Haeckel's theories are of little consequence: their relevance to systematics is minimal as the inferences from both the ideas could be used for phylogenetic inference in the form of his restated biogenetic law (Nelson, 1978).

The laws of development of von Baer can be summarised as follows (after Gould, 1977):

- 1) The general features of a larger group of animals appear earlier in the embryo than the special features.
- 2) Less general characters are developed from the most general, and so forth, until finally the most specialised appear.
- 3) Each embryo of a given 'species' ('Thierform'), instead of passing through the stages of other animals, departs more and more from them.
- 4) Fundamentally therefore, the embryo of a higher animal is never like (the adult of) a lower animal, but only like its embryo.

Patterson's example of the pectoral fin and the hyomandibular of a fish, and the wing and stapes of a bird illustrates clearly how von Baer's law, not Haeckel's, is the appropriate basis for polarity determination (Patterson, 1982a, p.52). Therefore von Baer, and not Haeckel, provides the starting point for investigating comparative embryology, and for the use of ontogenies of related organisms to determine the evolution of characters.

Nelson, Bonde and Patterson thus emphasise the importance of the ontogenetic argument and state it as an a priori principle (Bonde 1984) in character based phylogeny reconstruction, or character analysis. Nelson (1978) and Bonde (1984) also allow a second method (the 'indirect' method) to be used in the determination of polarity - this is also known as the outgroup method. In the outgroup method the polarity of a character is inferred, not from observing a

character transformation within a species, but from observing the generality of the characters in one or more groups related to the one studied. Thus, if two characters are present in the group under study then the character that is more general, more widely distributed, among the outgroups (groups related to the one studied) is the more primitive of the two.

Other methods of polarity determination include the functional and palaeontological arguments. The former is that the directions of changes should be determined in terms of the functional adaptation and selective value for the organisms. Bonde (1977), in discussing the merit of this argument, shows that this is entirely a subjective decision and thus unreliable. The merits of the other method, that palaeontologically older character states are primitive, are also debatable and since I am not dealing with fossil material the argument here is redundant. An important axiom in this type of character analysis is the principle of parsimony, that is that the evolution of a character should be hypothesised to occur as simply as possible, with the least possible number of changes. Of the methods reviewed I propose to use the ontogenetic and outgroup methods in this study.

Evolutionary and ontogenetic processes

Gould (1977), in an extensive review, establishes parallels between ontogeny and phylogeny. He distinguishes on the one hand those embryonic structures and features that are widely shared in early

development (von Baer's law; in Darwin's (1859) terminology, community of embryonic structures revealing community of descent). On the other hand he recognizes features which reveal the direct parallels between ancestral and descendant ontogenies being products of generalized evolutionary mechanisms (the latter proceeding by altering the later stages of ontogeny). According to Gould (1977, p.214) "Evolutionary changes must appear in ontogeny, and they can arise only by [A] the introduction of new features or by [B] the displacement of features already present". Thus, Gould, following earlier biologists (e.g. Garstang, 1928) sees the above two mechanisms as those which characterise the course of morphological evolution: in contrast to the introduction of de novo changes during ontogeny, it is the displacement, or heterochrony, which produces the types of changes which have parallels in the ontogeny of the ancestors.

The hypothesis put forward by Gould (1977) is thus that parallels in ontogeny and phylogeny are produced by heterochrony, i.e alteration in developmental timing, and that this heterochrony proceeds by both acceleration and retardation. Gould also analysed the process of heterochrony by comparing the ontogenies of ancestors and descendants, simultaneously taking into account the interaction of differing criteria of size, shape and developmental stage. Gould developed a clock model to depict the criteria of size, shape and developmental stage together in comparing ancestral and descendant ontogenies. From these clock models he showed that the relevant processes are acceleration and retardation and that the end results are pedomorphosis and recapitulation. However, there is no

one-to-one correlation between the processes and the results. Retardation can lead to paedomorphosis (neoteny, by slowing down of somatic development) or to recapitulation (hypermorphosis, by retardation of maturation). Acceleration may also result in paedomorphosis (progenesis, by speeding up of maturation) or recapitulation (by acceleration of the growth of somatic organs).

Using the ideas expressed above, I intend to place the morphology of the primate forelimb venous system (both ontogenetic and adult) in its phylogenetic and evolutionary perspective. Gould, while recognising the possible importance of recapitulation by acceleration, viewed human morphological evolution primarily in a "matrix of retardation" (see Gould, 1977, pp.365-396): he proposed that the two aspects of the retardation process, neoteny and hypermorphosis, might both be active in human evolution and stated "mosaic evolution operates within it (matrix of retardation) to bring forward by neoteny the adaptive traits of ancestral juveniles and to develop by hypermorphosis the advantageous traits of an extended ontogeny". Although not all agree with his arguments (see Dean and Wood, 1984) I find Gould's ideas a comprehensive framework for primate morphological evolution, and it is this framework within which I intend to interpret my own results.

Example: evolution of the primate forelimb.

Among the forelimb structures of primates it is the hand which has fascinated morphologists and it therefore dominates the published

evidence, both ontogenetic and adult. Schultz observed that in the early ontogeny of primates and humans, at the stage when digits are just separated on the embryonic plate-like hands and feet, the thumb and the great toe show as yet no sign of rotation. The well known rotation of the first digit, needed for effective opposability, develops gradually during ontogeny and reaches widely different degrees of perfection in the adult hand and feet of various groups of primates (Schultz, 1949, after Gould, 1977).

In an extensive comparative study of the carpal bones of primates and marsupials, Lewis (1977) found that the trapezium and trapezoid of the apes and human are set differently. Lewis found that in Pan the orientation of the trapezium within the carpal arch is different to the orientation of this bone in humans. In the ape, the homologue of the human palmar surface of the trapezium faces almost directly medially and as a consequence the trapezium is 'offset' from the remainder of the carpal row. Lewis considered the setting of the ape's trapezium to be determined by the acutely wedged shape of its neighbouring bone, the trapezoid. The latter bone, in the ape, barely reaches the anterior surface of the carpus, and has its articulation with the capitate posterior to the interosseous ligament, as in all primates other than humans. In the human hand he found the volar aspect of the trapezoid to be relatively enlarged resulting in a 'readjustment' of the set of the trapezium, making the trapezium lay back towards the plane of the rest of the distal carpal row. Lewis also described how the enlarged volar aspect of the trapezoid has facilitated the trapezoid in establishing an anterior diarthrosis with the capitate in front of the thick interosseous

ligament. Lewis further argued that this is a 'morphological marker' of the human power grip.

Though Lewis's description incorporates an assumption that the African ape hand is primitive relative to that of humans, his data shows that the modern humans have a less rotated thumb than does Pan. This is achieved principally by the modelling of the bones of the carpus: the 'flatter' carpus allowing the possibility of developing new articulations between the bones (i.e. the capitate and trapezoid).

Lewis's data for adult apes and humans, taken together with Schultz's ontogenetic evidence for the rotation of the thumb, leads logically to the argument that the less rotated thumb is an earlier, more juvenile condition. The evidence from comparative primate embryology is that the starting point for all primates is a totally unrotated thumb. If the less rotated thumb (as found in humans) is a reflection of a 'flatter' carpus, and the rotation of the thumb occurs gradually in primate ontogeny, it is reasonable to argue that the human carpus is modelled on a juvenile condition, and thus that the human carpus is paedomorphic in comparison with the apes. The human hand could be neotenuous, facilitating the joint 'remodellings' suggested by Lewis (1977).

The argument for neoteny in the human hand is supported by the results of Napier (1980, p.70), who gives a formula for expressing the length of the thumb; it is termed the opposability index (total length of the thumb X 100/total length of the index finger). The

shortest thumb and the longest forefingers are found in the great apes and the longest thumbs and shortest forefingers are exhibited by modern humans. Schultz (1940), following studies of the development of the chimpanzee, observed that "the shortness of the thumb characteristic of adult anthropoids appears only gradually during ontogeny at least in the chimpanzee". All primates, including humans, in ontogeny start with a plate-like hand and almost homomorphic digits, and as development proceeds the human condition remains closer to its early embryonic digital pattern, in contrast to other hominoids like the chimpanzee. Although the above-cited evidence only pertains to the hand it illustrates how in ontogeny the general process of retardation might have operated positively in the human forelimb.

In this introductory review I have attempted to show how phylogenetic inferences can be drawn from the study of comparative morphology, both ontogenetic and adult, by pursuing the implications of character phylogeny, and by the analysis of evolutionary processes acting in ontogeny. I am binding these two aspects with due apologies to my mentors in character phylogeny, the modern cladists, who criticise the speculation into evolutionary processes as untestable. I prefer to work on the premise that evolution is history and see it as aphoristically enunciated by Gould "If the primacy of history is evolution's lesson for other sciences, then we should explore the consequences of valuing history as a source of law and similarity, rather than dismissing it as narrative unworthy of the name of science" (Gould, 1986 p.68).

MATERIALS AND METHODS

The gross morphology of the main veins of the superficial venous system of human and non-human primates was determined from dissections. Fifty one human upper limbs and sixty three non-human primate limbs from sixteen primate genera were examined (details of the different primate taxa dissected are given in Table 2.2). Published data were obtained on the superficial veins of the cat, dog, pig, goat, sheep, ox and horse.

The ontogeny of the superficial veins of humans was studied using serial sections of embryos from CRL 6mm to CRL 31mm together with dissections of fetuses ranging from CRL 60mm to CRL 145mm (10 weeks to 17 weeks). Published data on the development of the superficial veins in the rabbit and pig embryo were also studied.

The outgroup comparison method and the ontogenetic argument were used to determine the polarity of the characters of the main superficial veins. The phylogeny established by molecular data for the primates was used as the reference in determining the distribution of characters. The molecular phylogeny used, as given in Hasegawa *et al* (1985) and Bishop and Friday (1986), is based on the most reliable evidence to date.

RESULTS

Outgroup comparison

Prosimians:	Long lateral vein (LL)	No medial vein
Ceboids:	Long lateral vein (LL)	No medial vein
Cercopithecoids:	Long lateral vein (LL)	No medial vein
<u>Hylobates</u>	Long lateral vein (LL)	No medial vein
<u>Pongo</u>	Long lateral vein (LL)	Medial vein present
<u>Gorilla</u>	Short lateral vein (LS)	No medial vein
<u>Pan</u>	Short lateral vein (LS)	No medial vein
Human (76%)	Long lateral vein (LL)	Medial vein present
Human (24%)	Short lateral vein (LS)	Medial vein present

Lateral vein

The character long lateral vein (LL) is the most common among the primates. However, the short lateral vein appears in Pan, Gorilla and in 24% of humans. On the basis of the prevalence of this character state among primates the long lateral vein (LL) should be

considered general or primitive, while the short lateral vein (LS) would be the derived state.

Looking at a wider outgroup comprising a range of different mammals (cat, dog, goat, sheep, ox, pig and horse), published data on the superficial veins shows the ubiquitous presence of a long lateral vein (Nickel, Schummer and Seiferle, 1981). These observations in mammals support the inference that the character state long lateral (LL) is general, or primitive, for mammals as well as for primates.

The determination of the pattern of change in the character states of the lateral vein is complicated by the presence of polymorphism within humans. It could be argued that this character is 'unreliable' among hominoids because the small sample sizes obtained for the non-human taxa might mask the potential occurrence of polymorphism among these species. However, if we take the case of Pan the probability of obtaining 5 limbs exhibiting LS from a population in which LS and LL is equally prevalent, is only 3% (0.5^5), thus it is unlikely that Pan is significantly polymorphic in this character. Furthermore, other studies have indicated that both Pan and Gorilla have short lateral veins. There is, of course, the possibility that Gorilla might be polymorphic since only one limb of this species was sampled in the present study, but the results from several other primate species studied here, in which a number of limbs were sampled in each species, provides no support for the view that polymorphism of the lateral vein is a common occurrence among primates, notwithstanding its occurrence in humans.

The character state of a short lateral vein is seen only in the African apes, and as part of the polymorphic condition in humans. Fig. 4.1 gives the hominoid phylogeny established by molecular data, upon which the distribution of the character states of the lateral vein have been superimposed. If we follow the molecular cladogram in regarding Pan as the sister group of Homo, then the presence of both LS and LL as character states in Homo (i.e. that Homo is polymorphic) makes it equally parsimonious to regard their morphotype (node 4) as either LS or as polymorphic for LS and LL (Figure 4.2a & b). However, Gorilla possesses the character state LS, and thus LS is the most parsimonious interpretation of the morphotype of Pan, Homo and Gorilla (node 3), and hence of the common ancestor of Pan and Homo (node 4, Figure 4.3). The other possibilities are shown in Figures 4.4 and 4.5: if node 3 and node 4 had LL and LS (Figure 4.4), or if node 4 alone has LL and LS and node 3 having LS (Figure 4.5). The latter two possible distributions show how it is more parsimonious to interpret the morphotype at node 3 and 4 as having the character state LS. Having established LS as the most parsimonious condition for node 3, it is most parsimonious to regard node 2 (the common ancestor of great apes and humans) as having the primitive hominoid state LL which is retained in Pongo. It should be noted that this particular analysis for the African ape/human clade depends on an acceptance of the molecular phylogeny.

Medial vein

All primates except for Pongo and modern humans have no medial vein.

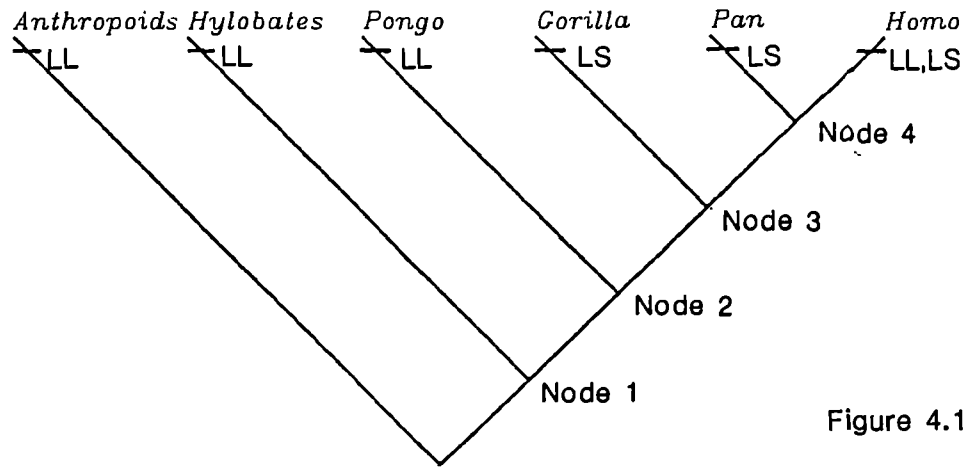


Figure 4.1

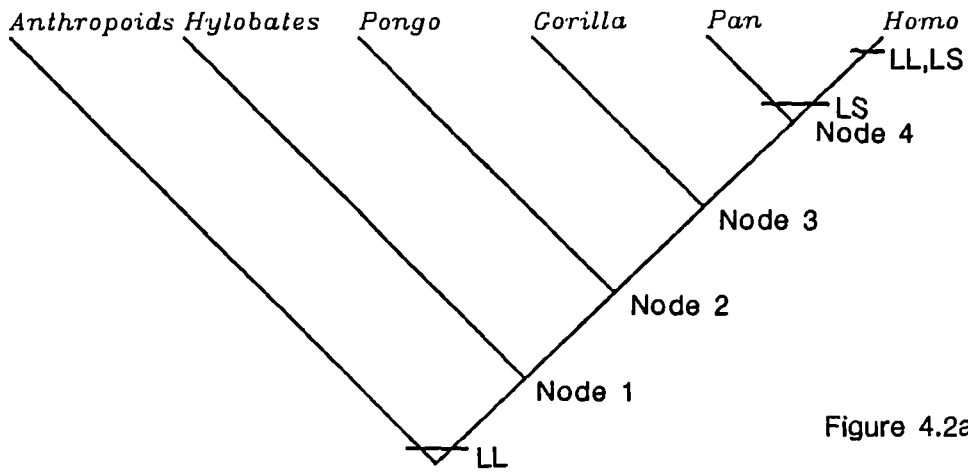


Figure 4.2a

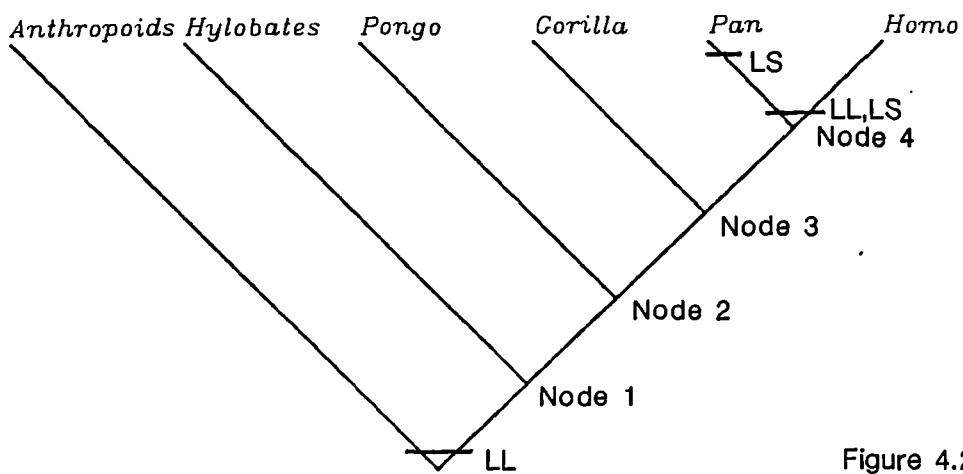


Figure 4.2b

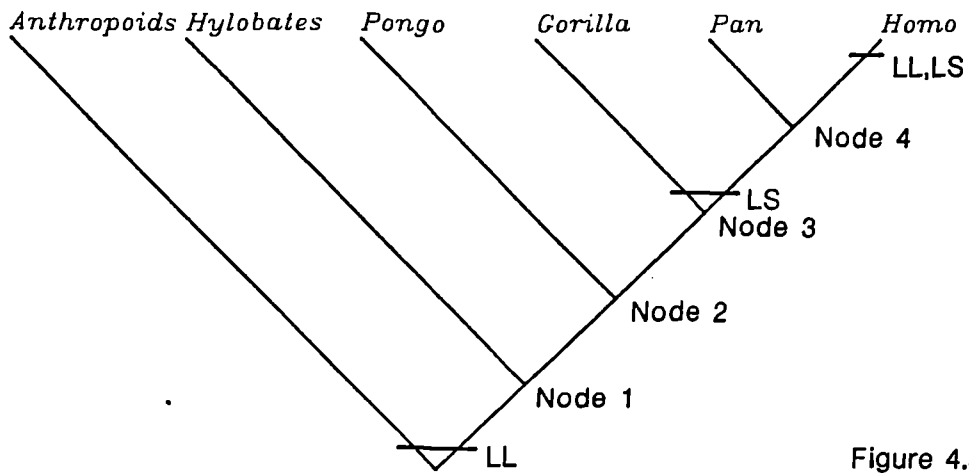


Figure 4.3

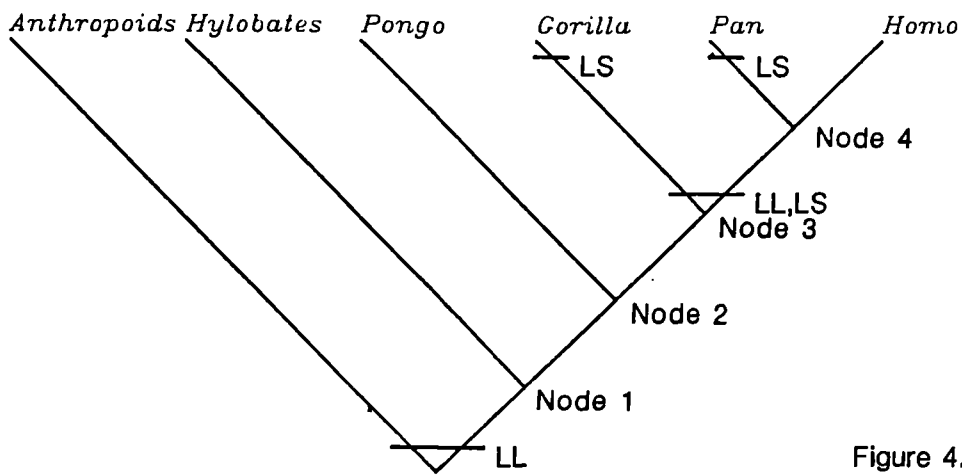


Figure 4.4

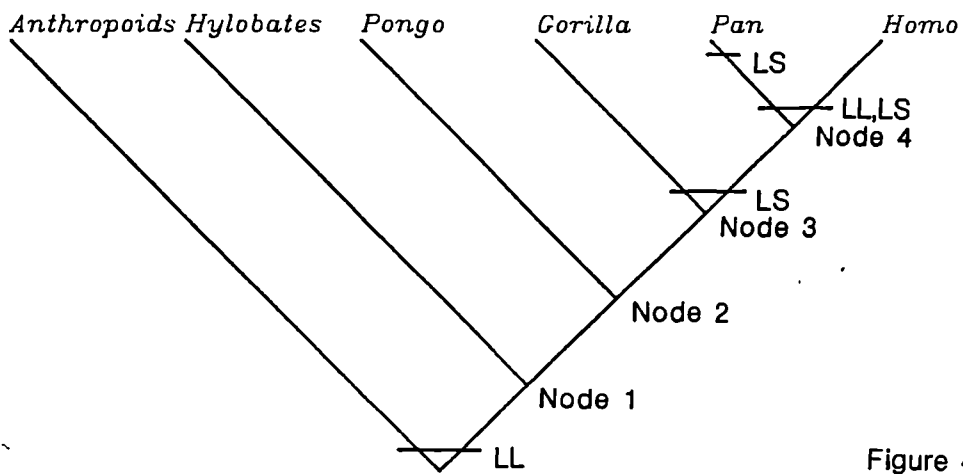


Figure 4.5

Therefore the absence of the medial vein could be assumed to be primitive for the primates. The distribution of this character is shown upon the molecular cladogram (Figure 4.6). This is supported by published information for other mammals: in the cat, dog, ox, goat, sheep, pig and horse this vein is absent. Therefore by outgroup comparison the presence of the medial vein can be determined to be a derived character while its absence is primitive.

Ontogenetic or the direct argument

The ontogenetic evidence for humans examined in the present study shows that though both the medial (postaxial) and the lateral (preaxial) vein are present in the early embryo it is the medial (postaxial) vein that appears first. Thus, the embryo starts with both medial and lateral veins and retains the two-veined state in the adult. The preaxial vein in the early embryos start as a 'long' vein, hand to the base of the neck or clavicle. The 'short' lateral vein condition is noted in the later foetuses both in this study and in that of Bardeleben (1880b). Thus it could be tentatively decided that in the ontogeny of human the 'long' versus 'short' argument to be resolved as 'long' state to be the more primitive condition.

The published data on the rabbit embryo (Hochstetter, 1891; Lewis, 1905) reveals that in the rabbit the medial vein appears in the early embryo and later in ontogeny disappears, while the lateral vein, which appears subsequent to the medial vein, persists after the medial vein's disappearance. The published evidence for the pig

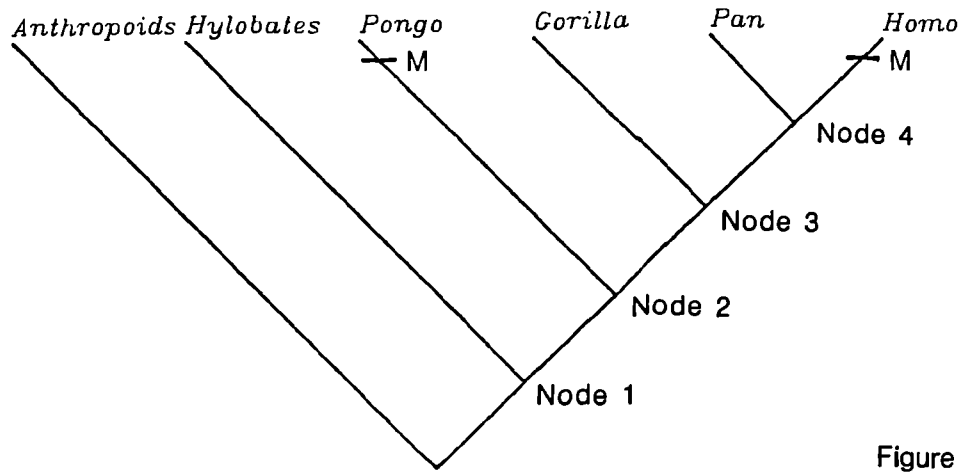


Figure 4.6

embryo (Woolard, 1922) shows that in this animal the medial vein is well defined before the cephalic appears. The subsequent fate of the medial vein is, however, not given in this study which did not consider later embryos.

These findings logically lead to the conclusion, by the direct or ontogenetic argument, that the possession of both medial and lateral veins (the post and the preaxial veins) is the general condition, appearing as it does in the early embryonic stages of both rabbit and human. The later loss of the medial vein in the rabbit is thus an advanced, or derived state, while the human embryo by continuing to possess the post- and the preaxial veins into adulthood, is manifesting the primitive, or general, condition.

PHYLOGENETIC INFERENCES

By the outgroup comparison method the possession of the long lateral vein (LL) is the primitive condition for primates, while the primitive state for the African ape/human clade is the short lateral vein, as the most parsimonious interpretation.

In the ontogenetic study the possession of the lateral vein is again seen as the general or primitive state, at the level of the primates as a group. But any assumption that this state is also primitive for the more exclusive African ape /human clade has yet to be tested using embryos of the African apes. However, it can be suggested tentatively from the ontogenetic data of humans that the 'long' state

LL is primitive and those human foetuses which presented with the 'short' LS state could have started with a 'long' preaxial vein in the very early stages. If this argument is taken to its logical conclusion it could be predicted that the common morphotype of the African ape /human clade could have had an ontogeny where the character transformation from a 'long' to 'short' would have occurred.

By outgroup comparison the possession of the medial vein is predicted as a derived feature found only in Pongo and humans. However, the ontogenetic evidence shows that the possession of the medial vein is a primitive condition. Thus, there is a contradiction between the predictions made by outgroup comparison and by the ontogenetic argument regarding the polarity of the medial, or the postaxial, vein. Nelson (1978), Patterson (1982a) and Bonde (1984) consider the ontogenetic argument to have precedence, hence it is termed the 'direct' argument. Nelson argued that while the other methods i.e. comparative anatomy and palaeontology require prior assumptions of relationships, ontogeny does not: the character transformation from primitive to derived is observed directly in ontogeny.

If the ontogenetic argument is taken as the direct evidence of character transformation, as Nelson and Bonde have suggested, then the possession of the medial vein in humans is the primitive character state. It follows that the loss of the medial vein, shown in the ontogeny of the rabbit, is a derived state. If the argument is taken further, to predict the state of this character in other primates, it could be postulated that the absence of the medial vein in all primates except Pongo and humans is a shared derived feature

of a larger monophyly at the mammalian level. The ontogeny of the primates would then be expected to present the same ontogeny as the rabbit.

Ontogeny shows that the possession of the medial vein is a primitive character and thus eliminates the possibility of using this character as a shared derived one between Pongo and humans as the outgroup method could have suggested. If the outgroup comparison alone had been taken as the proper interpretation, the possession of a medial vein could have been added to the list of characters compiled by other researchers (e.g. Schwartz 1984a, 1984b) in support of a Pongo/ human clade. However, ontogeny suggests that this is not the case and that the possession of a medial vein is a primitive condition, and thus could not be used in establishing patterns of relationship. It is notable that Schwartz offers no ontogenetic evidence to support the polarity of his assumed synapomorphies between Pongo and humans.

Having interpreted the superficial veins, both medial and lateral, as primitive features brought forward in the ontogeny of humans, one can view these results not in isolation but in the perspective of processes affecting the characters or features of the entire forelimb. As I have shown in the introductory review in this section, certain other features of the human forelimb - like the rotation of the thumb and the length of the thumb relative to the length of the forefingers - in comparison with other apes are features that are evidence of a retarded growth, or neoteny. Furthermore, the human forelimb also retains as a general feature

foetal growth rates late into its postnatal ontogeny by retarding or delaying its maturation, as shown in the comparative data on the late fusion of the epiphyses of the long bones of the human forelimb (Schultz, 1956, 1968). This is seen to be not a unique possession but a process which is evident in primates in comparison with mammals, and is further extended in a pronounced form, within the primates, by humans (Gould, 1977).

While one should not totally exclude the process of acceleration and its consequence, recapitulation, it is suggested here that retardation (including both neoteny and hypermorphosis) is a process which affects many aspects of the human forelimb in comparison with other hominoid forelimbs. Under this hypothesis, the possession of a primitive superficial venous system could be a byproduct of a more extensive process, and should thus perhaps be considered a pleiotropic effect (that is, the consequence of a change in a gene complex whose primary expression is in other, adaptively significant aspects of the phenotype). Thus, the superficial venous system may be adaptively neutral for humans, and their retention of the primitive pattern a consequence of retardation of limb morphology.

CHAPTER 5: FUNCTIONAL HYPOTHESES

Bock and von Wahlert (1965) show that a feature, or part of an organism, can have a form (or sometimes several forms, for example vessels may be distended or constricted vessels, and muscles flaccid or tense), and several functions which are attributes of the physical and chemical properties of the feature. These two aspects of the feature (form and function) may have one or several biological roles, these being the actions, or uses, of the form-function complexes in the course of the, life history of the organism. Hypothesised functions and biological roles of the upper limb venous system and its components are considered here.

Function of the venous system as a whole

The venous system of the organism serves to return deoxygenated blood to the heart, but veins also act as the capacitance vessels in any vascular circuit. The venous system has a much greater capacity than the arterial system, both because the number of vessels is greater, and because at any particular level the cross-sectional area of the veins draining a vascular bed tends to be larger than the corresponding arteries supplying it. The physical properties of veins, including their distensibility (especially at low transmural pressures) and their thin walls mean that veins add very little to the total resistance of the vascular circuit. The venous system can undergo large changes in capacity by changing the luminal configuration and diameter of individual veins. This allows the venous system to act as a reservoir (80% of the systemic circulation

in humans) but also provides a way to redistribute blood rapidly. Ludbrook (1972) proposed an additional function for the subcutaneous veins of the hands and feet, in thermoregulation.

One dominant theme in anatomical studies of the venous drainage of the extremities, especially studies in humans, has been an emphasis on the effect of hydrostatic pressure. It has been suggested that the structure and distribution of the limb veins, particularly those of the lower limb, reflect adaptations to changes in hydrostatic pressures. For example the differential composition of the wall of the long saphenous vein, where the inferior segment (segment near the ankle) is composed of more muscle and less collagen and elastin than the superior segment (near the entry into the femoral vein), has been noted by Svejcar et al (1962). The presence of valves as an adaptation to raised hydrostatic pressure is suggested by Franklin (1937) and Shepherd and van Houtte (1975). Shepherd and van Houtte state that in humans there are more valves in the lower limb than in the upper limb. These proposed form-function links, especially those relating to the valves, have been challenged (Chapple and Wood, 1980).

In order to assess the potential influence of hydrostatic pressure on the veins of the extremities it is necessary to consider the vascular system in its entirety. Figure 5.1 shows the venous and arterial pressures acting at different points in the circulation of an upright human individual. The hydrostatic pressure affects the arterial and the venous sides of the dependant limb circuit equally, and therefore does not directly affect the driving pressure of the venous

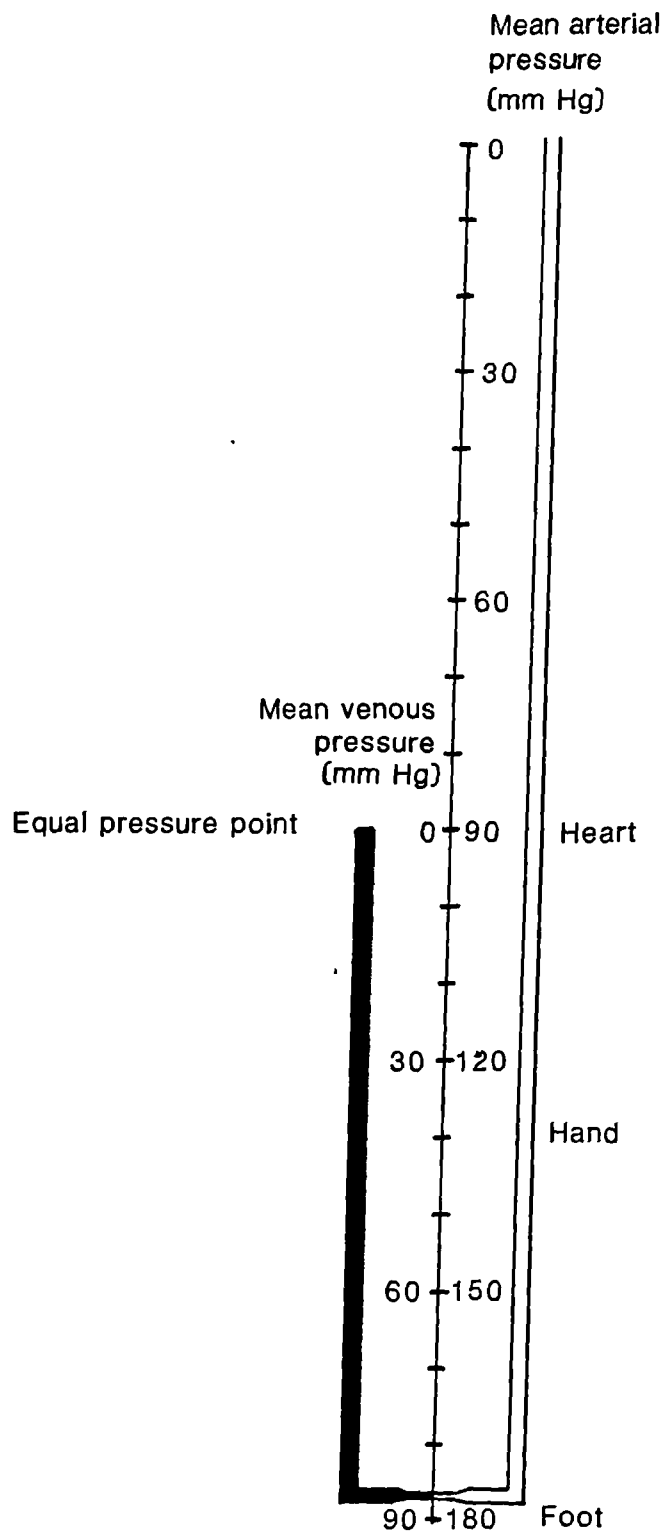


Figure 5.1

circulation or the mean venous flow itself (Folkow and Neil, 1971; Caro, Pedley, Schrotter and Seed, 1978). However, the effect of the hydrostatic pressure manifests itself as an increase in transmural pressure, which affects the distensible limb of the circuit, causing distension of veins, pooling of blood and an increased 'residence time' for the venous blood. The often quoted situation of fainting when standing upright from supine or sitting position is due the sudden pooling of the blood in the dependent extremity and is not due to the uphill task of veins having to send blood against hydrostatic pressure as is sometimes implied.

Robinson, Factor and Sonnenblick (1986) have recently proposed an alternative model for diastolic filling of the heart in terms of the heart acting as a suction pump. The adoption of such a model, in which active and not passive filling of the heart is emphasised, might have a profound implication for models of flow in the venous circulation and might enhance our understanding of the form and function of the venous system and the role of venous valves and similar structures within the venous system. Such implications are not pursued in the present study.

Function of particular features of the veins of the extremities

Valves

Valves are said to direct flow, for example immediately below entry of a tributary (Ludbrook, 1962; Shepherd and van Houtte, 1975). The

hypothesis of this role for valves stems mainly from anatomical studies which showed the correlation of number and arrangement of valves with afferent tributaries (Bardleben, 1880; Kosinski, 1926). However, other researchers have shown that in many cases there seemed to be no particular relationship between the position of valves and the entrances of tributaries (Chapple and Wood, 1980) and that valves are both associated with tributaries and scattered along the vein length, apparently independently of the occurrence of tributaries (Cotton, 1961).

The valves of limb veins have been seen as a specialisation of the veins of the extremities to counteract the raised hydrostatic pressure. The hydrostatic pressure is proportional to the dependent distance below the level of the heart or equal pressure point. In the present study it has been shown that the number of valves in the forelimb veins bears no relation to the length of the arm in the primates studied (Figure 2.29, Chapter 2). These data seem to question the premise of a correlation between hydrostatic pressure and number of valves, a premise that also lacks theoretical support (see below).

Table 5.1 gives the valve indices (valves per unit length) obtained in the present study for the superficial veins of the human forearm (cephalic and basilic). These values are contrasted with the valve indices for Macaca (lateral superficial vein) and with the valve indices derived from data published by other workers who have studied the same veins of the forelimb in humans and Macaca. Table 5.2 gives the valve indices of the saphenous veins (hind limb superficial

veins) of modern humans and Macaca. The following can be noted from Tables 5.1 and 5.2:

- a) The valve indices obtained in the present study for the forelimb veins are broadly consistent with the indices derived from the results of other studies (Table 5.1). Valve indices derived from Bardeleben's data are somewhat higher than those of the present study.
- b) In the lateral vein of the forelimb, which is homologous in Macaca and modern humans, there is no significant difference in valve index between the two species.
- c) There are significant differences in the valve index between different veins within each limb in modern humans e.g. basilic has a higher valve index than cephalic (Table 5.1), and the short saphenous appears to have a higher valve index than does the long saphenous vein (human).
- d) The range of valve indices calculated for the forelimb veins (Table 1) is broadly similar to the range of indices found in the veins of the hindlimb (Table 5.2) in both Macaca and modern humans.

These findings refute the hypothesis that the valve numbers reflect structural specialisations that counteract an elevation in hydrostatic pressure by breaking up the column of blood and thus decreasing the load on lowest point. One would expect hydrostatic pressure to be (A) greater in human veins than in those of Macaca, and (B) for there to be a greater effect in the hindlimb than in the forelimb in the modern human material. One would also expect veins at the same level within a limb to be exposed to a similar degree of

hydrostatic pressure. None of these predictions are met by the data obtained in this study: modern human indices are similar to those of Macaca, the hindlimb valve pattern resembles that of the forelimb in both species and the only notable, consistent differences in valve index appear to be between different veins of the same limb at the equivalent hydrostatic level.

Valves are also said to prevent reverse flow in veins, as in the case of the perforators. Although direct observations and histological examination of the hind limb perforators in humans suggest that the perforating veins contain valves whose cusps are orientated to allow blood flow from superficial to deep (Cotton, 1961; Thomson, 1979), evidence from dynamic studies suggests that blood flow is bidirectional, with merely the net flow being inwards (Bjordal, 1977). In the present study the perforating veins of humans and Macaca show that only 26% of the Macaca perforators and 14% of the modern human perforators examined had valves. Thus it difficult to ascribe the role of preventing reverse flow, or directing flow in the forelimb perforators, to the valves.

Valves have also been seen as functional components of the muscle pumps; these pumps are intermuscular in the case of the forelimb. Muscle pumps are regarded as an important mechanism in the reduction of transmural pressure in the dependent parts of the extremities. A muscle pump acts by squeezing a segment of distended vein, so that the pressure from surrounding skeletal muscle pushes blood out of that segment of vein. The displaced blood moves towards the heart because, according to this model, the valves permit only

unidirectional i.e. afferent flow. This 'milking' away of blood from the distended veins reduces the transmural pressure in these segments of vein. Thus the presence of valves is an important component of the muscle pump and hence part of the mechanism aiding the reduction of transmural pressure.

However, Caro et al (1978) show that valves, while possibly assisting the pump by more effective maintenance of the lowered transmural pressure, are not essential for the determination of the direction of the displaced blood (and even the qualitative reduction in the pressure) which is probably determined by the impedance of either ends of the compressed tube. In the case of the muscle pump, the upstream impedance is always greater than the downstream (towards the atrium) because of the presence of a larger flexible chamber downstream, thus the venous blood is pumped towards the heart even in the absence of valves.

The muscle pump primarily serves to lower venous transmural pressure. Due to the action of the pump compressing the vein the velocity (distance per unit time) of the venous blood is increased while the average flow (volume per unit time) remains unchanged because the vein is on average less distended and thus contains, on average, less blood. Therefore this mechanism does not serve primarily to improve the flow, but it does decrease the mean time of residence of the blood in the veins in the dependent parts of the extremities.

The muscle pump thus only partially 'explains' the role of the valves in the deep veins but it does not, however, explain the presence of

numerous valves in superficial veins. Caro et al (1978) suggest that one of the possible roles of these valves may be to prevent pressure waves propagating distally along veins so that in the more distal segments they are attenuated and a steady afferent flow is maintained. Such a biological role could be claimed for valves in both the superficial and the deep veins of both limbs, and is consistent with the findings of this study which suggest that the numbers of valves are determined by the length of the vein rather than by overall size or by considerations of hydrostatic pressure.

System of superficial, deep and connecting perforating veins

The arrangement of the venous system of primate limbs as two primary systems, connected by perforating veins, could be seen as a means of draining structurally different and separated anatomical regions, but this explanation is not exhaustive of the role the venous system plays. The two interconnected routes, superficial and deep, most probably also ensure alternative routes of drainage for each region in case of occlusion injury, or indeed during normal activity, when veins might be occluded by muscle activity, joint flexion etc.

Out of the three types of channel it is the perforating veins which have been singled out as being important so-called "functionally". Perforators are stated to have valves facing one direction only, and are indispensable to models such as the muscle pump, in that they normally ensure drainage of venous blood from the superficial veins into the deep and not vice versa. If the perforators are one of the

main suppliers of blood to the deep vein muscle pumps, concentration of perforators in the wrist in the forelimb of modern humans (Chapter 2) would apparently support such a role since the muscle pump must receive blood distally and discharge it proximally. The allometric increase in perforator number with forelimb length in primates would also support this hypothesised role.

It has been noted earlier (Chapter 2) that both Perodicticus and modern humans have a greater number of forelimb perforators than expected for primates of their respective body sizes. The excess perforators in both species are concentrated in the wrist area, thus the high residuals for humans and Perodicticus may reflect separate specialisations of the forearm and hand in both these forms. According to Osman-Hill, the pectoral musculature of Perodicticus is well developed and the forearm muscles of this animal are particularly bulky (Osman-Hill, 1953, p.183): the species also apparently has a strong grip (Napier and Napier, 1967, p.259). Perodicticus may therefore have well-developed forearm muscle pumps, and hence a need for extra perforators. There is no convincing explanation for the excess perforators in the forelimb of modern humans, but there is a comparatively well-developed blood supply to the human hand, from which venous drainage must mainly be via the superficial veins of the forearm.

Summary of Functional Hypotheses

In published studies, several functional hypotheses have been proposed to explain various aspects of the venous system. The

proposed functions include capacitance, the provision of alternative routes of venous return, and the active assistance of such return via muscle pumps. Some features, such as the orientation of valves, have been cited as supporting these hypothesised functions, while it has been argued that other features (such as the number of valves) are part of a physiological adaptation to hydrostatic pressure in the dependent limb. In this study it was shown that the number of valves was linearly related to the length of vein, and that the valve index (number of valves per unit length) was relatively constant between species and between limbs within a species. These results do not support the hypothesis that valves are related to hydrostatic pressure.

The number of forelimb perforators was determined for a range of primates of different body size, and it was found that the number of perforating veins is allometrically related to size in these animals. In humans the forelimb perforators are concentrated at the wrist, with a secondary concentration at or below the elbow. These findings are consistent with the perforators playing an important role in the supply of venous blood to muscle pumps.

CHAPTER 6: CONCLUSIONS

The present study was undertaken to fill a gap in our knowledge of the veins of the primate forelimb. It showed that though the forelimb venous structures are variable, their complexity and variation do not reflect a lack of order. It was shown how morphological data can be used not only in the description of anatomical structures, but also to quantify the relationship of such structures to differences in overall size, and to facilitate the phylogenetic and functional interpretations of these structures.

Comparative anatomical description of gross morphology

The human superficial venous system consists of two autonomous main veins, one on the lateral side of the limb and the other on the medial side. The lateral vein, termed the cephalic vein, presents in two ways. In a majority of subjects (about 75% of individuals) it is 'long', i.e. running from the carpal to the clavicular regions. In a minority (about 25% of individuals) the cephalic vein is 'short', being well defined only in the forearm. A medial vein called the basilic vein is usually present in the forearm with its termination in the middle or distal part of the upper arm.

In the non-human primates the 'long' lateral vein is present, except in Pan and Gorilla, which have a lateral vein only in the forearm. A medial vein is not found in the non-human primates, with the sole exception of Pongo.

The deep veins accompany the arteries in all primates and therefore their pattern reflects specific differences in arterial morphology found among the different primate taxa.

A survey of the literature concerning a wide range of non-primate mammals showed that in the mammalian superficial venous system the 'long' lateral vein is a wide-spread condition. The non-primate mammals also lacked the medial vein found in the modern human and Pongo superficial venous system.

Ontogenetic evidence of gross morphology

In humans the earliest superficial forelimb vein to develop is the medial, or postaxial, vein; the vena marginalis. The preaxial, or lateral, vein develops next, also at an early stage of ontogeny. The human postaxial vena marginalis persists to adulthood as the forearm part of the basilic (which is superficial) and as the deep upper arm part of the basilic and the axillary. The preaxial usually develops as a long vein and persists into adulthood as the cephalic vein. The deep veins accompanying the ulnar and radial arteries develop later in ontogeny than the other veins described above.

The above findings are in agreement with those of Hochstetter (1891) and Lewis (1905) on the embryonic development of the veins of the anterior limb of the rabbit. Hochstetter and Lewis show the development of the postaxial vein to be the earliest, followed by a

preaxial vein extending to the external jugular. They also show that the forearm part of the postaxial vein in the rabbit embryo disappears in later ontogeny and therefore this animal has no medial superficial vein in adulthood.

Phylogenetic interpretation of gross morphology

The evidence obtained from comparative anatomical studies, both adult and ontogenetic, was used to draw some inferences concerning character phylogeny and to formulate possible evolutionary mechanisms and pathways for the development of the forelimb venous system morphology. Many phylogenetic studies have used skeletal characters rather than soft tissue evidence, and have concentrated on adult comparative anatomy rather than the combination of ontogenetic and adult evidence to resolve character polarity. The present study uses soft tissue characters and also shows the utility and importance of the ontogenetic evidence in resolving problems in character phylogeny.

By studying the comparative anatomy of the superficial veins for an 'outgroup' analysis, the lateral 'long' (LL) vein has been shown to be the more general, or primitive, character state for primates. Furthermore, it is suggested that it is marginally more parsimonious to predict that the 'short' (LS) lateral vein character state, rather than the polymorphic condition of modern humans or the LL state of other primates, is the primitive condition at the level of the African ape/human clade. That the 'long' lateral character state is

present as the more general, or primitive, condition for primates is corroborated by ontogenetic studies in the development of this vein in humans and in mammals. The absence of developmental evidence on the forelimb venous system in the African apes precludes any ontogenetic confirmation of the prediction that the 'short' (LS) lateral forearm vein characterises the common ancestor of African apes and modern humans.

The possession of the medial, or postaxial vein, suggested by outgroup analysis as a derived or advanced condition in humans and in Pongo, was rejected as a synapomorphy because the ontogenetic evidence showed that the possession of it was a more general, or primitive, condition. It could have been argued that the possession of the medial superficial vein, supported by outgroup analysis as a derived character, would advance the case of a hominoid phylogeny having humans and Pongo as sister groups. However, this would have contradicted a phylogeny established more reliably on molecular data (Hasegawa et al, 1985; Bishop and Friday, 1986), and ontogenetic evidence showed that the possession of a medial superficial vein is a primitive character, and could thus only be regarded as a shared primitive character of humans and Pongo. The possession of a medial vein cannot, therefore, define a monophyly, and thus cannot be used as evidence to refute a phylogenetic hypothesis based on other evidence.

Functional hypotheses

Comparative study of some of the important features of the forelimb venous system, like the perforating veins and venous valves, has resulted in observations which form the basis of several functional hypotheses regarding the organisation of the limb venous system of modern humans. The number of perforators within the primates showed a positive allometric relationship with overall linear dimension, as determined by a surrogate measurement of arm length. The number of valves of the superficial veins was shown to be independent of overall size, although valve number was isometrically related to the length of vein. This finding vindicates the use of the valve index of Vankov.

The allometric increase in the number of perforators with size was suggested to be related to the increase in muscle mass within the primate forelimb, and may possibly aid the muscle pumps in decreasing the transmural pressures in the veins of the extremities. The relative constancy of the valve index between species, and the difference between the valve indices of fore- and hind limb veins of the same species being less pronounced than the difference between the valve indices of the veins in the same limb of that species, were all seen as a refutation of a traditionally held hypothesis that valves (their presence, numbers and position) are a specialisation for the increase in hydrostatic pressures faced by the dependent limb.

Retardation

It is proposed that the morphological evolution of some characters of the primate forelimb has been brought about by heterochronic changes to ancestral ontogenies. The human forelimb venous system presents a suite of primitive characters which are not found in our closest primate relatives, the African apes. These primitive features (some of which also appear in Pongo) are best interpreted within the framework of retardation (one of the heterochronic processes), and are consistent with other neotenuous and hypermorphic aspects of the human forelimb when compared with the other primate forelimbs.

Table 2.1: Specimen Numbers and Sex of Dissected Material (human)

Specimen no	Side	Sex
38	right	female
38	left	female
34	right	male
34	left	male
39	right	male
39	left	male
37	right	male
37	left	male
33	right	female
33	left	female
31	right	female
31	left	female
32	right	female
32	left	female
36	right	female
36	left	female
40	right	female
40	left	female
24	right	female
24	left	female
14	right	female
14	left	female
13	right	male
13	left	male
19	right	male
19	left	male
26	right	female
26	left	female
21	right	male
21	left	male
18	right	male
17	right	female
17	left	female
20	right	female
20	left	female
5	right	male
5	left	male
1	right	female
3	right	female
3	left	female
2	right	male
2	left	male
6	right	female
6	left	female
Li.2	right	-
Li.2	left	-
Li.33	right	-
Li.33	left	-
189	right	-
189	left	-

Table 2.2: Non-human Primate Material

	Genera	Number of Forelimbs
Prosimia	<u>Lemur</u> (<u>catta</u>)	2
	<u>Nycticebus</u> (<u>coucang</u>)	1
	<u>Perodicticus</u> (<u>potto</u>)	3
Ceboids	<u>Alouatta</u> (<u>caraya</u>)	3
	<u>Saimiri</u> (<u>sciureus</u>)	2
	<u>Lagothrix</u> (<u>lagothricha</u>)	2
Cercopithe- coids	<u>Papio</u>	12
	<u>Macaca</u> (<u>fascicularis</u>)	12
	<u>Mandrillus</u> (<u>sphinx</u>)	1
	<u>Theropithecus</u> (<u>gelada</u>)	1
	<u>Cercopithecus</u>	6
	<u>Colobus</u> (<u>quereza</u>)	2
Hominoids	<u>Hylobates</u>	6
	<u>Pongo</u>	4
	<u>Pan</u> (<u>troglodytes</u>)	5
	<u>Gorilla</u>	1

Table 2.3: Specimen Numbers of the Different Morphological
Types of Long and Short Human Cephalic Veins

Long Cephalic (LL)				Short Cephalic (LS)	
24	r,l	3	l	32	r,l
19	r,l	33	r,l	40	r
Li.33	r,l	Li.2	r	2	r
21	r,l	40	l	17	r,l
3	r	31	r,l	18	r
2	l	39	r,l	14	r,l
26	r,l	34	r,l	13	r,l
20	r,l	36	r,l	Li.2	l
1	r	38	r,l		
5	r,l	37	r,l		
6	r,l	189	r,l		

Table 2.4: Numbers of Perforators and Arm Length in Humans

Specimen No.	No of perforators	Arm Length (cm)
39 L	7	49
39 R	8	49
31 L	15	49
31 R	14	50
32 L	10	48
32 R	13	48.5
37 R	12	54
37 L	13	54
36 L	10	53
36 R	8	53
34 L	10	56
34 R	9	54
38 L	10	44
38 R	13	44.5
40 R	13	50
40 L	8	50
33 L	8	51.5
33 R	12	51

Table 2.5: No. of perforators and Arm Length in Non-human Primates

Spec. No.	Genus	No. of perforators	Arm length (cm)
016	Lemur	2	12
009	Perodicticus	6	11.5
007	Perodicticus	3	12.5
019	Nycticebus	1	11
093	Alouatta (R)	3	24
093	Alouatta (L)	2	23.6
088	Alouatta (R)	2	17.5
095	Lagothrix (R)	4	27
095	Lagothrix (L)	4	27.3
094	Saimiri	1	12
003	Papio	3	26
015	Papio	3	25.5
010	Papio	4	24
004	Papio	2	21
014	Papio	4	23.5
021	Papio	4	22.5
001	Papio	4	25
020	Papio	4	24.5
069	Papio	2	31
069	Papio	4	30.3
067	Papio	4	23
005	Papio	4	18.5
071	Macaca	3	19.5
072	Macaca	3	16
072	Macaca	3	16
081	Macaca	3	18
085	Colobus (R)	6	27
085	Colobus (L)	4	27
086	Cercopithecus (L)	4	23
086	Cercopithecus (R)	4	22.5
065	Cercopithecus (R)	3	16
066	Cercopithecus	5	22.5
063	Theropithecus	5	37
022	Mandrillus	5	43
096	Hylobates	4	42.5
096	Hylobates	4	42
025	Hylobates	6	36.5
024	Hylobates	7	43
090	Pongo	5	73
091	Pan (R)	5	49
091	Pan (L)	6	53
092	Pan (R)	8	53.5
092	Pan (L)	6	53
084	Pan (L)	5	48.5
084	Pan (R)	6	50.5
017	Gorilla	4	42

Table 2.6: Location and Constancy of Perforators in Humans

Connections of Perforators to:	Occurrence	S.D. of Position (cm)	Median Diameter (mm)	Range of Diameter (mm)
muscular veins of deltoid	44%	1.83	1.0	0.2-2.0
muscular veins of triceps	33%	0.99	0.9	0.15-1.5
muscular veins of upper arm flexors /deep basilic	44%	3.58	0.8	0.15-1.5
radial/ulnar v.c. in cubital fossa	100%	0.96	2.5	1.0-3.0
radial/ulnar v.c. in proximal and mid-forearm: anterior	33%	0.79	0.4	0.2-0.8
radial/ulnar v.c. in proximal and mid-forearm: posterior	33%	3.13	0.5	0.2-0.8
radial v.c. distal forearm: anterior	100%	0.93	0.6	0.2-0.9
ulnar v.c. distal forearm: posterior	100%	1.08	0.6	0.15-0.9
muscular & other distal forearm, radial side	72%	1.54	0.55	0.15-1.3
muscular & other distal forearm, ulnar side	33%	1.07	0.45	0.15-0.7
hand, radial side	100%	0.94	0.9	0.6-2.0

Table 2.7 Valve Indices (Short Saphenous Vein)

Investigator	Macaca Valve Index	Human Valve Index
Bardeleben	-	0.25
Kosinski	-	0.23
Marinov/Cotton	-	0.22
Williams	0.17	-
Chapple & Wood	0.62	-

Table 2.8: Arm Length, Vein Length and Valve Numbers in Humans

Specimen No.	Arm Length (cm)	Cephalic Length (cm)	No. of Valves Cephalic	Basilic Length (cm)	No. of Valves Basilic
33 R	50.5	55	14	30.5	12
33 L	50.5	55	10	25.5	4
2 L	55.5	21.7	4	33.8	11
2 R	56.5	56.5	12	34.7	14
24 L	49	52	7	26	4
24 R	48	52	7	35	7
14 L	50	19	4	25.5	6
14 R	50	19	5	30.0	3
13 L	52	23	6	33	10
13 R	52	22	3	28	6
19 L	57	61	7	26	5
19 R	56	66	11	18	5
26 L	49	54	8	30.5	4
26 R	49	52	8	23.5	4
21 R	57	60	14	24	3
21 L	58	53	11	42.5	10
18 R	57	23	3	26	4
18 L	57	26	6	35	7
17 R	-	26.5	3	32	5
1 R	49	66.5	12	34	6
3 L	48	53	8	33	6
3 R	49	58	9	30	7
5 L	57	64	13	36	10
5 R	57	55	10	31	7
6 L	50	57	14	27	6
2 L	54	69.5	15	28	8
36 R	53	56.5	10	30.5	8
34 L	56	61.5	10	28	7
34 R	54	59.1	11	31.5	6

Table 2.9: Arm Length and Lateral Vein Length in Nonhuman Primates

Spec.No	Genus	Arm length (cm)	Lat. vein Length (cm)	No. of valves
074	Macaca	16.5	17.3	4
074 L	Macaca	16.3	17	4
078 L	Macaca	20	19.3	5
078 R	Macaca	19.8	20.2	5
070 L	Macaca	18.5	19.3	4
070 R	Macaca	18.3	20.7	3
077 L	Macaca	18	18.5	2
077 R	Macaca	17.5	18.6	2
081 R	Macaca	18	19.2	3
092 R	Pan	53.5	22	4
091 R	Pan	49	32	4
084 R	Pan	50.5	19	5
084 L	Pan	48.5	20	6
017	Gorilla	42	19.8	2
025 L	Hylobates	36.5	42.8	7
025 R	Hylobates	37	41	6
024	Hylobates	43	44.8	7
096 R	Hylobates	42	38	5
096 L	Hylobates	42.5	34.3	6
066 L	Cercopithecus	22	23.2	5
066 R	cercopithecus	22.5	25.2	5
063 L	Theropithecus	37	43.2	6
095 L	Lagothrix	27	27.3	6
095 R	Lagothrix	27	29	6

Table 2.10 Valve Indices (Forelimb Superficial Vein)

Genus	Valve Index	No. of Specimens
<u>Macaca</u>	0.19	9
<u>Pan</u>	0.20	4
<u>Gorilla</u>	0.10	1
<u>Hylobates</u>	0.15	5
<u>Cercopithecus</u>	0.21	2
<u>Theropithecus</u>	0.14	1
<u>Lagothrix</u>	0.21	2
Human 'short'	0.17	7
Human 'long'	0.18	22

Table 2.11: Number of Valves in Deep Veins (Macaca)

Specimen No	Superficial brachial	Radial vena comitantes	Ulnar vena comitantes
074 R	1	3	2
074 L	1	2	2
078 R	3	3	2
078 L	2	3	3
070 L	3	2	0
070 R	4	1	1
077 L	0	0	2
077 R	2	0	0

Table 2.12: Number of Valves in Perforators (Macaca)

Specimen No	Perforator in cubital fossa	Perforators in the Distal Forearm	
		Radial side	Ulnar side
078 L	1	1	0
078 R	0	1	-
074 R	0	0	-
074 L	0	0	-
070 L	1	0	-
070 R	0	0	-
077 L	0	0	0
077 R	0	1	0

Table 2.13: Number of Valves in Perforators (Humans)

Specimen No.	Perforator in cubital fossa	Perforators in the Distal Forearm		
		radial	ulnar	pollex
H-1 R	0	0	-	0
H-1 L	0	0	0	0
H-2 R	0	0	-	0
H-2 L	0	0	-	0
H-3 R	0	0	0	1
H-3 L	0	0	0	0
H-4 R	0	0	0	-
H-4 L	0	0	0	-
H-5 R	0	0	1	-
H-5 L	1	0	1	-

Table 5.1 Valve Indices (Forelimb Superficial Veins)

Investigator	Cephalic/Lateral Vein		Basilic Vein
	<u>Macaca</u>	Human	Human
Bardeleben	-	0.21	0.27
Williams	0.16	-	-
Thiranagama	0.19 $\pm 0.02^1$	0.18 $\pm 0.01^1$	0.22 $\pm 0.01^1$

¹ Standard error of mean calculated from data in Tables 2.8 and 2.9.

Table 5.2 Valve Indices (Hind limb Superficial Veins)

Investigator	Long Saphenous	Short Saphenous	
	Human	<u>Macaca</u>	Human
Bardeleben	0.16	-	0.25
Kosinski	-	-	0.23
Williams	-	0.17	-
Cotton	0.11	-	-
Marinov/Cotton	-	-	0.22

REFERENCES

AYER, A.A. (1948) The anatomy of Semnopithecus entellus. Madras, The Indian Publishing House.

BARDELEBEN, K. (1880a) Das Klappen-Distanz-Gesetz. Jenaische Zeitschrift für Naturwissenschaft. 14: 467-529.

BARDELEBEN, K. (1880b) Die hauptvene des armes, Vena capitalis brachii. Jenaische Zeitschrift für Naturwissenschaft. 14: 587.

BEATTIE, J. (1927) The anatomy of the common marmoset (Hapale jacchus Kuhl). Proceedings of the Zoological Society of London 2: 513-718.

BISHOP, M.J. and FRIDAY, A.E. (1986) Molecular sequences and hominoid phylogeny. In Wood, B. et al (eds.) Major topics in primate and human evolution. Cambridge, Cambridge University Press: 150-156.

BJORDAL, R.I. (1977) Haemodynamic studies of varicose veins and the post-thrombotic syndrome. In Hobbs, J.T. The treatment of venous disorders. Lancaster, MTP.

BLECHSCHMIDT, E. (1961) The stages of human development before birth. An introduction to human embryology. Basel, Karger.

BOCK, W.J. and VON WAHLERT, G. (1965) Adaptation and the form-function complex. Evolution 19: 269-299.

BONDE, N. (1977) Cladistic classification as applied to vertebrates. In Hecht, M.K. et al (eds.) Major patterns in vertebrate evolution. New York, Plenum: 741-804.

BONDE, N. (1984) Primitive features and ontogeny in phylogenetic reconstructions. Vidensk. Meddr Dansk Naturh. Foren. 145: 219-236.

BOUCHET, A. et al (1973) Contribution a l'étude anatomique de la veine céphalique du bras. Compte Rendus de l'Association des Anatomistes 154: 971-985.

BOYD, J.D. (1960) The development of the human hand. The Medical Press 243: 157-160.

CAMPBELL, D.R. et al (1979) The use of arm veins in femoral-popliteal bypass grafts. Annals of Surgery 190: 740-742.

CARD, C.G. et al (1978) The mechanics of the circulation. Oxford, Oxford University Press.

CHAPPLE, C.R. and WOOD, B.A. (1980) Venous drainage of the hind limb in the monkey (Macaca fascicularis). Journal of Anatomy 131: 157-171.

CLARK, W.E LeGros (1959) The antecedents of man. Edinburgh, Edinburgh University Press.

- CLAYSON, K.R. et al (1976) Arm veins for peripheral arterial reconstruction. Archives of Surgery 111: 1276-1280.
- COTTON, L.T. (1961) Varicose veins. Gross anatomy and development. British Journal of Surgery 48: 589-598.
- DARDIK, H. and DARDIK, I. (1974) Axillo-axillary bypass with cephalic vein for correction of subclavian steal syndrome. Surgery 76: 413-418.
- DARWIN, C. (1859) On the origin of species by natural selection or the preservation of favoured races in the struggle for life. London, Murray.
- DAVIES, D.V. (1947) The cardiovascular system of the slow loris. Proceedings of the Zoological Society of London 117: 377-410.
- DEAN, M.C. and WOOD, B.A. (1984) Phylogeny, neoteny and growth of the cranial base in hominoids. Folia Primatologica 43: 157-180.
- EDWARDS, J.E. and EDWARDS, E.A. (1940) The saphenous valves in varicose veins. American Heart Journal 19: 338-351.
- FABRICIUS, H. (1603) De venarum ostioliis. Patavii.
- FOLKOW, B. and NEIL, E. (1971) Circulation. London, Oxford University Press.
- FOURNOL, S. et al (1985) Anatomical study of the forearm venous system. Abstracts, XII International Anatomical Congress, London: A.208.

A.208.

FRANKLIN, K.J. (1937) A monograph on veins. Springfield, Thomas.

GARSTANG, W. (1928) The morphology of the Tunicata, and its bearings on the phylogeny of the Chordata. Quarterly Journal of Microscopical Science 72: 51-187

GASSER, R.F. (1975) Atlas of human embryos. Baltimore, Harper and Roe.

GEDDES, A.C. (1912) The origin of the vertebrate limb. Journal of Anatomy and Physiology 46: 350-383

GOULD, S.J. (1977) Ontogeny and phylogeny. Cambridge, Harvard University Press.

GOULD, S.J. (1986) Evolution and the triumph of homology, or why history matters. American Scientist 74: 60-69.

GRAHAM, J.W. and LUSBY, R.J. (1982) Infrapopliteal bypass grafting: use of upper limb vein alone and in autogenous composite grafts. Surgery 91: 646-648.

HAEGER, K. (1967) The anatomy of the veins of the leg. In Hobbs, J.T. (ed.) The treatment of venous disorders. Lancaster, MTP.

HARVEY, P.H. and CLUTTON-BROCK, T.H. (1983) Life history variation in

primates. *Evolution* 39: 559-581.

HASEGAWA, M. et al (1985) Dating of human-ape splitting by a molecular clock of mitochondrial DNA. *Journal of Molecular Evolution* 22: 160-174.

HENNIG, W. (1965) Phylogenetic systematics. *Annual Review of Entomology* 10: 97-116.

HILL, W.C. Osman (1937) The pre-natal development of the grey langur, *Semnopithecus priam thersites*. *Ceylon Journal of Science (B)* 20: 211-251.

HILL, W.C. Osman (1953) The blood-vascular system of *Tarsius*. *Proceedings of the Zoological Society of London* 123: 655-694.

HILL, W.C. Osman (1974) Primates. Comparative anatomy and taxonomy, Volume 7. Edinburgh, Edinburgh University Press.

HOCHSTETTER, F. (1891) Ueber die entwicklung der extremitätsvenen bei den amnioten. *Morph Jahrbuch* 17: 1-43.

JONES, F. Wood (ed.) (1946) Buchanan's manual of anatomy. London, Balliere, Tindall and Cox.

KAKKAR, V.V. (1969) The cephalic vein as a peripheral vascular graft. *Surgery, Gynecology and Obstetrics*

- KAMPMEIER, O.F. and BIRCH, C. La Fleur (1926) The origin and development of the venous valves, with particular reference to the saphenous district. *American Journal of Anatomy* 38: 451-499.
- KOSINSKI, C.H. (1926) Observations on the superficial venous system of the lower extremity. *Journal of Anatomy* 60: 131-142.
- KUSTER, G. et al (1968) Anatomy of the veins of the foot. *Surgery Gynecology and Obstetrics* 127: 817-823.
- LEWIS, F.T. (1905) The development of the veins in the limbs of rabbit embryos. *American Journal of Anatomy* 51: 95-120.
- LEWIS, F.T. (1909) On the cervical veins and lymphatics in four human embryos. *American Journal of Anatomy* 9: 33-42.
- LEWIS, D.J. (1977) Joint remodelling and the evolution of the human hand. *Journal of Anatomy* 123: 157-201.
- LINEBACK, P. (1933) The vascular system. In Hartman, C.G. and Straus, W.L. *The anatomy of the rhesus monkey (Macaca mulatta)*.
- LUDBROOK, J. (1962) *Aspects of venous function in the lower limbs*. Thomas, Springfield.
- LUDBROOK, J. (1972) *The analysis of the venous system*. Bern, Huber.
- MANNERS-SMITH, T. (1910a) The limb arteries of primates. Part 1. *Journal of Anatomy and Physiology* 44: 271-302.
- MANNERS-SMITH, T. (1910b) The limb arteries of primates. Part 1

Continued. Journal of Anatomy and Physiology 45: 23-64.

MARTIN, R.D. (1986) Primates: a definition. In Wood, B. et al (eds.) Major topics in primate and human evolution. Cambridge, Cambridge University Press: 1-31.

NAPIER, J.R. (1980) Hands. London, Allen and Unwin.

NAPIER, J.R. and NAPIER, P.H. (1967) A handbook of living primates. London, Academic.

NELSON, G. (1978) Ontogeny, phylogeny, paleontology, and the biogenetic law. Systematic Zoology 27: 324-345.

NICKEL, R. et al (1981) The anatomy of the domestic animals. Volume 3. The circulatory system, the skin, and the cutaneous organs of the domestic mammals. Berlin, Parey.

PATTERSON, C. (1982a) Morphological characters and homology. In Joysey, K.A. and Friday, A.E. (eds.) Problems of phylogenetic reconstruction. Systematics Association Special Volume No. 21. London, Academic Press: 21-74.

PATTERSON, C. (1982b) Cladistics and classification. New Scientist 94: 303-306.

RAVEN, H.C. (1950) The anatomy of the gorilla. New York, Columbia University Press.

RIEDL, R. (1979) Order in living organisms. Chichester, Wiley.

ROBINSON, T.F. et al (1986) The heart as a suction pump. Scientific American 254: 62-69.

RODEN, T.C. (1839) The valvular structure of the veins, anatomically and physiologically considered, with a view to exemplify or set forth, by instance, or example, the wisdom, power, and goodness of God as revealed and declared in Holy Writ. Oxford.

ROTH, V.L. (1984) On homology. Biological Journal of the Linnean Society 22: 13-29.

SCHULMAN, M.L. and BADHEY, M.R. (1982) Late results and angiographic evaluation of arm veins as long bypass grafts. Surgery 92: 1032-1041.

SCHULTZ, A.H. (1924) Observations on colobus fetuses. Bulletin of the American Museum of Natural History 49: 443-457.

SCHULTZ, A.H. (1926) Fetal growth of man and other primates. Quarterly Review of Biology 1: 465-521.

SCHULTZ, A.H. (1933) Chimpanzee fetuses. American Journal of Physical Anthropology 18: 61-79.

SCHULTZ, A.H. (1937) Fetal growth and development of the rhesus

monkey. Contributions to Embryology of the Carnegie Institution, No. 159: 71-98.

SCHULTZ, A.H. (1940) Growth and development of the chimpanzee. Contributions to Embryology 28: 1-63.

SCHULTZ, A.H. (1941) The development of the orang-utan. Contributions to Embryology 29: 57-110.

SCHULTZ, A.H. (1949) Ontogenetic specialisations of man. Archiv Julius Klaus-Stiftung 24: 197-216.

SCHULTZ, A.H. (1956) Postembryonic age changes. Primatologia 1: 887-964.

SCHULTZ, A.H. (1958) The recent hominoid primates. In Washburn, S.L. and Jay, P.C. (eds.) Perspectives on human evolution, Volume 1. New York, Holt Rinehart and Winston: 122-195.

SCHWARTZ, J.H. (1984a) The evolutionary relationships of man and orang-utans. Nature 308: 501-505.

SCHWARTZ, J.H. (1984b) Hominoid evolution: a review and a reassessment. Current Anthropology 25: 655-672.

SHEPHERD, J.T. and VAN HOUTTE, P.M. (1975) Veins and their control. New York, Saunders.

- SINGH, S.P. et al (1982) A study of the superficial veins of the cubital fossa in Nigerian subjects. *Acta Anatomica* 114: 317-320.
- SONNTAG, C.F. (1923) The anatomy, physiology and pathology of the chimpanzee. *Proceedings of the Zoological Society of London* 1: 323-429.
- STIPA, S. (1971) Axillofemoral bypass graft with saphenous, cephalic and basilic veins. *Surgery Gynecology and Obstetrics* 133: 297-300.
- STREETER, G.L. (1945) Developmental horizons in human embryos. Description of Age Group XIII, embryos about 4 or 5 millimeters long, and age group XIV, period of indentation of the lens vesicle. *Contributions to Embryology* 31: 27-63.
- STREETER, G.L. et al (1951) Developmental horizons in human embryos. Description of age groups XIX, XX, XXI, XXII and XXIII. *Contributions to Embryology* 34: 165-196.
- SVEJCAR, J. et al (1962) Content of collagen, elastin, and water in walls of the internal saphenous vein in man. *Circulation Research* 11: 296-300.
- SWINDLER, D.S. and WOOD, C.D. (1973) An atlas of primate gross anatomy. Seattle, University of Washington Press.
- SZALAY, F.S. (1977) Ancestors, descendants, sister groups and testing of phylogenetic hypotheses. *Systematic Zoology* 26: 12-18.

THOMSON, H. (1979) The surgical anatomy of the superficial and perforating veins of the lower limb. *Annals of the Royal College of Surgeons of England* 61: 198-205.

VANKOV, V. (1968) Structure and vascularisation of the venous wall and its valves. Doctoral dissertation, Leningrad.

VON BAER, K.E. (1828) *Entwicklungsgeschichte der thiere: beobachtung und reflexion*. Königsberg, Bornträger.

WILLIAMS, A.F. (1954) A comparative study of the venous valves in the limbs. *Surgery Gynecology and Obstetrics* 99: 676-678.

WILLIAMS, P.L. and WARWICK, R. (eds.) (1980) *Gray's anatomy*. ~~London, Saunders.~~ Edinburgh, Churchill Livingstone.

WOOLLARD, H.H. (1922) The development of the principal arterial stems in the forelimb of the pig. *Contributions to Embryology* 14: 139-154.

WOOLLARD, H.H. (1925) The anatomy of Tarsius spectrum. *Proceedings of the Zoological Society of London* 2: 1071-1184.