

CASE BASED LEARNING POINTS

DOI: <https://doi.org/10.18502/fem.v7i3.13827>

Pulmonary hydatid cyst in pregnancy

Mustafa Mahmood Eid^{1*}, Alaa Al-Zubaidi²

1. Department of Emergency Medicine, Tawam Hospital, Al Ain, UAE.

2. College of Medicine, University of Diyala, Baqubah, Iraq.

*Corresponding author: Mustafa Mahmood Eid; Email: Dr.mustafa191982@gmail.com

Published online: 2023-09-29

Cite this article as: Eid MM, Al-Zubaidi A. Pulmonary hydatid cyst in pregnancy. Front Emerg Med. In Press.

1. Case presentation

A 26-year-old pregnant lady was referred from a private hospital to the emergency department with a cough, shortness of breath, decreased oxygen saturation, and repeated vomiting. She went to the private hospital for obstetrics and gynecology follow-up for her pregnancy. The patient is 21 weeks pregnant with no known comorbidities. She is gravida three and para two. The patient claimed that since 3 days, the shortness of breath (SOB) and cough have been worsening, and she has been inducing herself to vomit more frequently, however, there is no associated dysphagia. She denied fever, headache, dizziness, abdominal pain, or a change in bowel habits.

On further review, she claimed that she has had a chronic cough with white sputum production for many years, starting in 2016, associated with left anterior chest pain and burning that would be relieved by pain medication. Moreover, she has had on and off shortness of breath at home for the past 2 months that increased while she was lying down flat. She also has a heavy feeling in her chest after a few hours of eating and feels nauseous; however, she does not vomit and has been induced to vomit for 2 months. Her last trip was to Pakistan in October 2021. She has no sick contacts; however, there is one brother in Pakistan who has a chronic cough.

On patient examination, the patient was tachypneic, tachycardic, and maintaining saturation on room air but unable to speak full sentences. She has persistent clear vomiting, with food particles, non-bloody, non-bilious. Her vital signs included 91/53 mmHg blood pressure, 138 beats per minute heart rate, 37 °C body temperature, 22 breaths per minute respiratory rate, and 97% oxygen saturation on room air. Her chest auscultation showed a left-sided rub in the middle zone, reduced breath sounds in the left lower zone, and normal air entry on the right-side. The cardiovascular system revealed normal heart sounds, no murmurs, and no lower limb edema. The abdomen and neurological examination were unremarkable. Thus, the patient was started on oxygen with nebulizers, antiemetic medication, and intravenous (IV) fluid. The patient conditions improved, and blood pressure raised to 121/94 mmHg. The patient's blood tests revealed leukocytosis with left shift and lymphocytosis; other labs were within normal limits; and eosinophils were

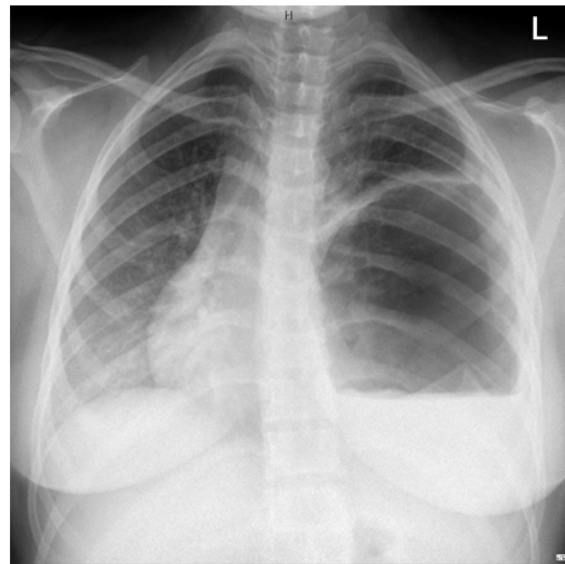


Figure 1 A chest X-ray showed a very large (14x13 cm) pulmonary cystic lesion with fluid level seen, occupying the mid and lower aspect of the left lung. The lesion that resulted in marked pressure on the heart and a marked mediastinal shift to the right side, Subtle opacity is seen in relation to the right lower zone

0.1×10^9 /L. The patient's chest X-ray showed a very large pulmonary cystic lesion in the left-side (Figure 1).

The diagnosis of pulmonary hydatid cyst was raised by the emergency medicine physician while the radiologist was not convinced about this diagnosis. The pulmonologist was consulted, who advised to admit the patient and to start the patient on antibiotics after blood culture, send echinococcosis antibodies in the serum, check the immunoglobulin E (Ig E) level, determine human immunodeficiency virus (HIV) status, and do a chest computerized tomography (CT) scan with contrast. The HIV and echinococcosis antibodies were negative, and the Ig E level was 439 IU/ml (normal high <100 IU/ml). The chest CT scan confirmed the presence of large left lower lobe hydatid cyst (Figure 2).

As a result, the patient was transferred to another hospital with a cardiothoracic facility. Upon arrival at the next hospital, the patient was tachypneic, tachycardic, in mild-to-moderate distress, and could not lie on her back. Her oxygen saturation was 92%-94%, and she was on an oxygen

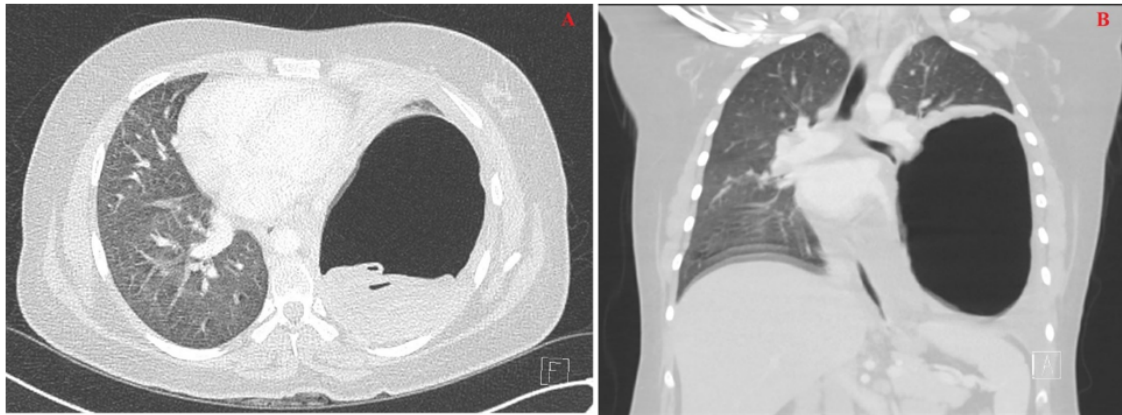


Figure 2 A and B: A chest CT scan showed a large left lower lobe cystic lesion measuring about 16x10 cm, with internal layering membrane seen in the dependent part in keeping with a hydatid cyst. A mild left-sided pleural effusion is seen. The mass has resulted in a mass effect with a right-sided mediastinal shift. A mass effect over the left bronchus is seen with consolidation. Multiple small right lobe areas of consolidation are seen

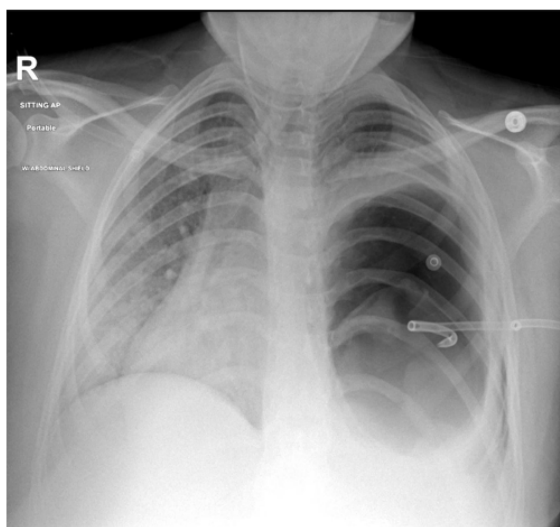


Figure 3 A chest X-ray showed a left-sided pigtail drain in situ with a large left cystic lesion causing compression of the adjacent lung and a mediastinal shift to the right, with a ground glass change seen in the right lung

face mask (5 L/min). A bedside ultrasound was done and showed an intrauterine pregnancy with fetal measurements commensurate with 21 weeks. The placenta was anteriorly high, and the amniotic fluid was normal. A multidisciplinary team meeting was done, including obstetrics, cardiothoracic surgery, infectious disease, and surgical intensive care unit doctors, and they decided the following: the patient needs admission to the intensive care unit and to start praziquantel for a few days, and then consider draining the cystic mass from the lungs by interventional radiology. Additionally, surgical excision of the hydatid cyst will be decided based on response to the above-mentioned plan of treatment and the need for complete excision while keeping in mind that the patient is still at 21 weeks of gestation. This treatment plan seemed reasonable in pregnancy, knowing that the patient is

still in a pre-viable stage of the pregnancy and that further delay of her treatment might result in deterioration of her already dire condition. The fetotoxic effect of the medication was clearly mentioned to the patient and her husband, and they agreed on the management plan.

Abdominal ultrasound was unremarkable, and no cystic or solid liver lesion was noted. A cardiac echo showed the heart shifted to the right sternum; the left ventricle looks normal in size with overall good left ventricle function and an estimated ejection fraction of 55%.

There was no pericardial effusion. Therefore, under CT scan and ultrasound guidance, the left lung's air-containing hydatid cyst was accessed with a micropuncture needle. A 14 French (F) locking pigtail drain was inserted, secured with silk suture, and attached to an underwater seal (Figure 3). Praziquantel 20 mg/kg, twice a day was decided for 2 weeks from drainage, and albendazole 400 mg, twice a day was commenced for planned periods of three months. The patient improved a lot post-procedure with no complications. She was able to sleep comfortably in the supine position with no fever or shortness of breath. The oxygen demand decreased to 2 L/min through nasal cannula, and then stopped. The chest drain continue to show zero output, and the patient doing well. One week post insertion of chest drain, the multidisciplinary team meeting was hold again and agreed about the necessity for surgical intervention: excision and decortication of the hydatid cyst as the patient is still suffering from continuous and bothering irritative cough and mid trimester would constitute the optimal timing of the surgery. The decision to have surgery was planned after 2 weeks of drain insertion and anthelmintic therapy. Her hospitalization continued uneventfully, apart from a persistent cough. On the agreed date, the patient underwent a left thoracotomy, the removal of the hydatid cyst, a left lower lobectomy, and a biopsy. Additionally, a chest drain was inserted on the same side and a chest X-ray was arranged (Figure 4). The patient did well post-operatively with no complications. The

chest, drains 720 milliliters (ml) of serosanguineous fluid. The biopsy from the operation revealed an appearance consistent with an echinococcus (hydatid) cyst; the surrounding lung exhibits chronic organizing inflammation with occasional foreign body granulomas, indicating a lack of malignancy. The infectious disease consultant planned to continue praziquantel, 1600 mg, twice a day, for 2 weeks after thoracic surgery and albendazole, 400 mg, twice a day, for 6 months after thoracic surgery. Post-operative physiotherapy continued, and on the fourth day, it yielded white and greenish sputum. As a result, a chest X-ray was scheduled, which revealed a worsening of her left hemithorax volume (Figure 5).

Thereafter, flexible bronchoscopy was arranged with bronchoalveolar lavage, which revealed thick whitish secretion occluding the left main bronchus. Suction was done, and bronchoalveolar lavage (BAL) was sent for culture and cytology which showed later clear result with no infection or malignancy. The patient's condition improved continuously, and her cough decreased significantly. Her chest drain output reached less than 20 ml of serosanguineous fluid with no air leak (Figure 6).

Obstetricians monitored the patient's pregnancy status, including fetal heart beats, and reassured her. The patient and fetus' total radiation dose assessment was arranged and appeared to be 15.241 mGy. This indicates that while it's unlikely to have any negative impacts on the child, the risk of a radiation-induced harm cannot be completely disregarded, according to the international commission for radiation protection. The patient was sent home to be monitored as an outpatient. She followed up with the thoracic surgery clinic after one week. The patient was doing well with a minimally intermittent dry cough and nausea. The chest tube was checked, and no air leak was confirmed. On the second follow-up, weeks later, the chest drain was removed after a chest X-ray (Figure 7).

The patient stopped following up with the clinic after that. Two months later, the patient went to an obstetric clinic due to lower abdominal pain. There was no vaginal bleeding or leaking. She denied any respiratory symptoms. Her obstetric ultrasound and fetal heart beats were within the normal range. However, they found she complained of anemia with a hemoglobin (Hb) level of 7.7 g/dl. The patient was admitted, where she had a blood transfusion of three units, and her hemoglobin improved to 10.2 g/dl. The pulmonologist was consulted about the delivery method, and he recommended vaginal delivery, so the patient was discharged home. Two days after her expected date of delivery, the patient presented to the labor and delivery ward due to a premature rupture of the membrane. The patient had an uneventful, normal vaginal delivery. She was then sent home in good condition with her baby.

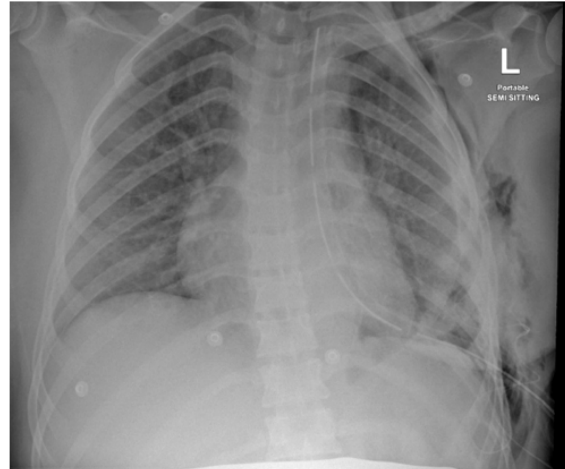


Figure 4 A chest X-ray revealed left-sided drainage tube catheter with its tip projecting over the apical region. Small effusion and surgical emphysema noted on left side. Mild atelectatic changes are seen in the left lung base

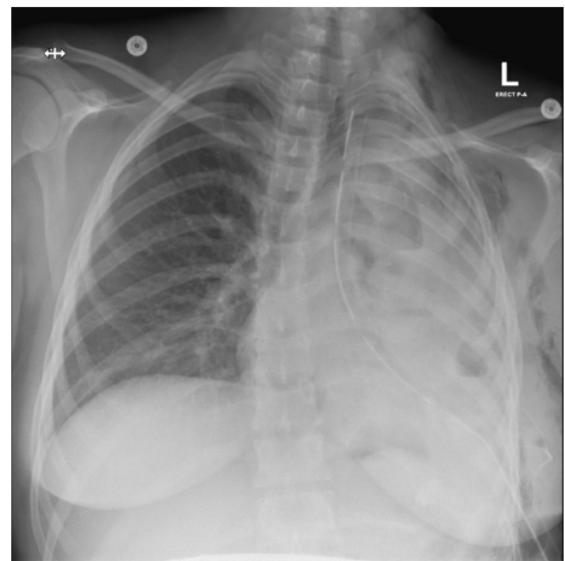


Figure 5 A chest X-ray revealed nearly complete whiteness of the left hemithorax with volume loss since the previous radiograph and a few small air-fluid levels. Stable left apical chest drain and surgical emphysema in the left chest wall

2. Learning points

A hydatid cyst diagnosis is frequently made using a combination of imaging and serological techniques. It is important to investigate the possibility of liver cysts in a patient with lung cysts (1).

The main investigative method for pulmonary hydatid cysts is chest imaging. The several imaging modalities helpful in the diagnosis of thoracic hydatid cysts include, conventional X-rays, computed tomography (CT), and magnetic resonance imaging (MRI) of the lungs. Whether or not the cysts are complex will affect how they appear on radiographs (2). A chest X-ray is typically the first imaging technique used.

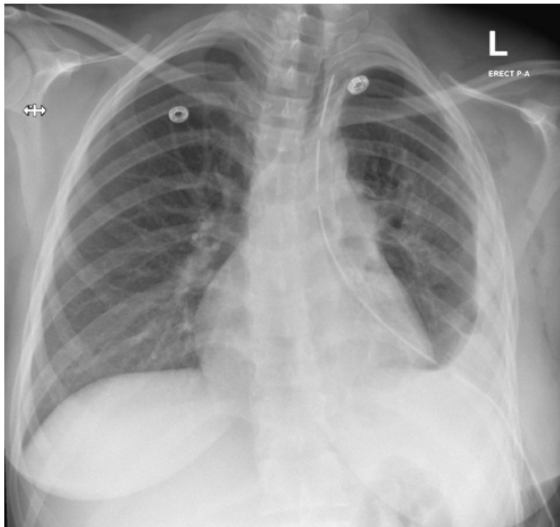


Figure 6 A chest X-ray showed a stable left apical chest drain, surgical emphysema in the left chest wall, and left pleural effusion

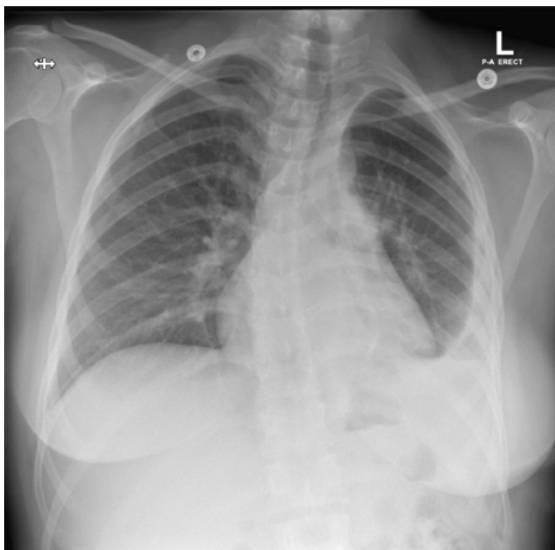


Figure 7 A chest X-ray showed the previously seen left-sided chest tube had been removed. Mild left-sided pleural effusion showing no significant changes since the previous examination. Previously observed subcutaneous emphysema has resolved

One or more well-defined, spherical homogenous density masses surrounded by healthy lung tissue are the typical observations in chest X-rays. Straightforward lung hydatid cysts show up as well-circumscribed uniform lesions on a CT scan, with smooth, hyperdense, low-density walls that can range in thickness. Several radiologic signs, including the air crescent sign, cumbo sign, air bubble sign, serpent sign, rising sun sign, and water lily sign, can be observed if the cyst is intricate. In T1-weighted MRI scans, cysts have low signal intensity, while on T2-weighted MRI scans, they have high signal intensity (1,3).

Regarding a pregnant lady, the USNRC advises that the total amount of radiation a fetus is exposed to while its mother is

pregnant be less than 5.0 mSv (500 mrem). Below 50 mGy, the radiation exposure to the fetus is deemed safe and harmless. Radiation dosages between 50 mGy and 100 mGy are regarded as being inconclusive in terms of their effects on the developing fetus, according to the center for disease control (CDC). According to observation, the lowest dose levels at which harmful effects on the fetus may develop are believed to be doses above 100 mGy, particularly those above 150 mGy. The majority of pregnancy-related diagnostic tests are under the cut-off point. In this case, the patient reported that her total radiation exposure was carefully calculated and appeared to be too low to harm the fetus (4).

In order to make the first diagnosis of hydatid cysts, serological testing is helpful. Since antibody detection is more sensitive than antigen detection, it is the basis for the bulk of serological testing. Serological tests do, however, have some drawbacks. Due to cross-reactions, they may result in a false-positive response in patients with other helminthic diseases. Patients with cancer, liver cirrhosis, and long-term immunological problems are a few more factors. The location, quantity, viability, assay format, and integrity all affect seropositivity. Hepatic cysts had a greater seropositivity rate than pulmonary cysts. For hepatic cysts, the sensitivity of serological testing is from 85% to 98%, while for pulmonary cysts, it is between 50% and 60%. In individuals with multiorgan involvement, the sensitivity is higher, between 90% and 100%. The presence of intact pulmonary hydatid cysts increases the likelihood of false-negative serological testing because the antigens are contained within the cysts, which may reduce the stimulation of the host immune system (2).

Treatment options for pulmonary hydatid cyst include medication and/or surgery.

The preferred course of treatment is surgery, while some individuals may also benefit from medication. Mebendazole (MBZ) and albendazole (ABZ) are two examples of the benzimidazoles category of medications used in the treatment of pulmonary hydatid cysts (2).

Smaller cysts, individuals with conditions that preclude surgery, such as surgery refusal and multiorgan disease, many cysts, and recurrent cysts are all indications for chemotherapy.

Because ABZ has better bioavailability than MBZ, it can be administered at lower doses and is more potent overall. A greater plasma and intracystic medication concentration is also attained with ABZ. In comparison to MBZ, its plasma concentration is 10-40 times higher.

For ABZ to produce a meaningful reaction, a minimum contact period of 11 days is necessary. ABZ is typically prescribed at a dosage of 10-15 mg/kg/day, given twice daily, and MBZ at a dosage of 40-50 mg/kg/day, taken three times daily. Meals high in fat boost a drug's bioavailability. Although the ideal time frame for pharmacotherapy in pulmonary hydatidosis is unknown, it should last at least 3-6 months. By inactivating protoscolices and lowering the tension of the cysts allowing simpler cyst removal, adjuvant chemotherapy appears to

lower the likelihood of recurrence. However, it is unknown how long chemotherapy should be given before and after surgery. In general, therapy should start four days or less before surgery and last for one to three months (1,2).

Albendazole has not been well researched in humans, however it is teratogenic in animals. There was no evidence of an increased risk of congenital abnormalities, stillbirth, or other unfavourable pregnancy outcomes in the limited trials assessing the effects of albendazole usage during pregnancy. The world health organization (WHO) advises against using albendazole during the first trimester but supports treating pregnant women with intestinal helminthiasis/anemia in the second and third trimesters if necessary (5).

An isoquinolone called praziquantel has also been utilized in therapy. It has been demonstrated to possess potent protoscolicidal activity and might even outperform albendazole in vitro. Praziquantel has been used both on its own and in conjunction with albendazole (40 mg/kg once per week). According to a few reports, the use of albendazole and praziquantel together as a medical treatment or as a preventative measure after spillage is more successful than using either treatment alone. Praziquantel's effectiveness varies, and its function in first chemotherapy is unclear (1).

Cysts that are large, superficial, and prone to burst, as well as those that are infectious, located in crucial anatomical regions, or that cause a sizable mass effect, are all reasons for surgery. Surgery is intended to remove the whole cyst while preserving as much lung parenchyma as feasible and preventing intraoperative leakage. Pericystectomy, enucleation, open aspiration, cystostomy with capitonnage, and lung resection are only a few of the surgical procedures that are accessible (2).

The most popular surgical technique is a standard posterolateral thoracotomy. Surgery to remove pulmonary hydatid cysts is a safe treatment with minimal morbidity and mortality. A meta-analysis of 4255 pulmonary hydatid disease patients who underwent surgery revealed a 1.45% mortality rate, a 0%-17% morbidity rate, and a good cure rate (6).

Percutaneous treatments are less non-invasive, and mortality and morbidity rates are lower. Different percutaneous techniques can be performed according to the size and stage of the lesions. Percutaneous aspiration appears to be a secure substitute for surgery in patients with pulmonary echinococcosis, although not always being effective (7). Others think that when medical therapy has failed, patients with pulmonary hydatid disease can get effective percutaneous treatments as an alternative to surgery (8). In order to improve mother and fetal outcomes, critical illness during pregnancy need a multidisciplinary approach. When providing care for a critically ill pregnant woman, it is important to consider the uteroplacental blood flow, alterations to the fetus, and pregnancy-related physiological changes. As maternal hypercapnia swiftly leads to fetal respiratory acidosis, permissive hypercapnia is not a viable choice. Obstetric patients can undergo invasive hemodynamic monitoring for the same

reasons as other patients. Body position and volume status require special consideration in the management of hypotension. Toxic drugs and unneeded radiation must be avoided at all costs (9). In this case, a multidisciplinary team meeting was held regularly to decide the best treatment for the patient and minimize any possible complications while ensuring the best possible outcome for the mother and her fetus.

3. Declarations

3.1. Acknowledgement

None.

3.2. Authors' contribution

The authors meet the four criteria for authorship based on the recommendations of the International Committee of Medical Journal Editors (ICMJE).

3.3. Conflict of interest

None.

3.4. Funding

None.

References

- Morar R, Feldman C. Pulmonary echinococcosis. *Eur Respir J*. 2003;21(6):1069–77.
- Sarkar M, Pathania R, Jhobta A, Thakur B, Chopra R. Cystic pulmonary hydatidosis. *Lung India*. 2016;33(2).
- Kumar R, Rawat S, Raja J, Singh R, Thingnam SS. Pulmonary hydatid cyst: review of literature. *J Family Med Prim Care*. 2019;8(9):2774.
- Yoon I, Slesinger TL. Radiation exposure in pregnancy. In: *StatPearls*. Treasure Island (FL): StatPearls Publishing; 2023.
- Ryan, Edward T., et al. *Hunter's tropical medicine and emerging infectious diseases e-book*. Elsevier Health Sciences, 2019.
- Athanassiadi K, Kalavrouziotis G, Loutsidis A, Bellenis I, Exarchos N. Surgical treatment of echinococcosis by a transthoracic approach: a review of 85 cases. *Eur J Cardiothorac Surg*. 1998;14(2):134-40.
- Koul P, Kanjwal MK, Gojwari T. Percutaneous aspiration for treatment of pulmonary echinococcal cysts. *Eur Respir J*. 2009;34.
- Akhan O, Ozmen MN, Dinçer A, Göçmen A, Kalyoncu E. Percutaneous treatment of pulmonary hydatid cysts. *Cardiovasc Radiol*. 1994;17(5).
- Hijazi MH, Al-Ansari MA. Pulmonary hydatid cyst in a pregnant patient causing acute respiratory failure. *Ann Thorac Med*. 2007;2(2):66–8.