

Collection Technique and Sample Processing for Impression Cytology of the Ocular Surface

Kátia Amaral Freitas and Paula Mendonça

Escola Superior de Tecnologia da Saúde de Lisboa - Instituto Politécnico de Lisboa, Portugal

Article Information

Received date: Nov 11, 2016

Accepted date: Apr 21, 2017

Published date: Apr 27, 2017

*Corresponding author

Kátia Amaral Freitas, Escola Superior de Tecnologia da Saúde de Lisboa - Instituto Politécnico de Lisboa, Portugal, Email: katiafreitas93@gmail.com

Distributed under Creative Commons CC-BY 4.0

Keywords Impression cytology; Collection method; Fixation; SureThin; Papanicolaou staining

Abstract

Introduction: The impression cytology of ocular surface is a minimally invasive technique that allows the analysis of conjunctival and corneal cells, as an alternative to smears and punch biopsies. These specific guidelines will help health professionals, such as nurses and doctors, to ensure better samples of ocular surface without hurting patients, and will provide a new method of fixation for impression cytology of ocular specimens. **Objective:** The aim of this study was to present a technique of collecting, fixing and staining for impression cytology of ocular specimens. **Materials and Methods:** 50 samples of bulbar conjunctiva taken from 50 ESTeSL volunteers were analyzed. The material was collected on a strip of cellulose acetate from Millipore Corporation, then fixed on SureThin and stained with Papanicolaou stain. The slides were analyzed by three independent evaluators, using an evaluation grid with the following parameters: cell size, detail and nuclear membrane, detail and cytoplasmic membrane, ratio N / C and tinctorial affinity.

Results: The filter paper with apex helped to correctly position the paper in the eye and the procedure that was applied allowed an effective collection of cells with 50-70% of the filter surface being filled without the need for topical anesthesia. The SureThin fixative presented quality in cell preservation, in addition to being more economical. The Papanicolaou technique proved to be ideal in the coloring of ocular epithelial cells. This developed methodology presented a response of 80, 9% to a maximum score 2.

Conclusions: The presented method proved to be very effective in evaluating of ocular cell samples, while simultaneously proving to be a very cheap and comfortable technique for the patient.

Introduction

The cytology of ocular impression has numerous clinical applications. Currently, health professionals opt for invasive techniques, such as biopsies and punctures, causing discomfort to the patient. The possibility of obtaining ocular surface samples with minimal discomfort for the patient, in a non-invasive procedure, makes it the ideal method for investigating the ocular surface [1]. When the filter paper is applied to the conjunctival surface, it is possible to remove epithelial cells, still viable, from one to three layers of the conjunctiva, preserving its morphological and structural characteristics [2]. The analysis of these cells allows the evaluation of the degree of metaplasias, immunocytochemical analyzes with specific cytokeratin markers, isolation of pathogens and the obtaining of mRNA, cells for phenotyping and the diagnosis of melanose and melanoma [3]. This work aims to demonstrate an efficient cellular preservation procedure, with a simple and easily adaptable methodology in the routine of the services of ophthalmology in health units. This will allow a cytological evaluation of diseases of the ocular surface, replacing invasive techniques and reducing the implications for the patient.

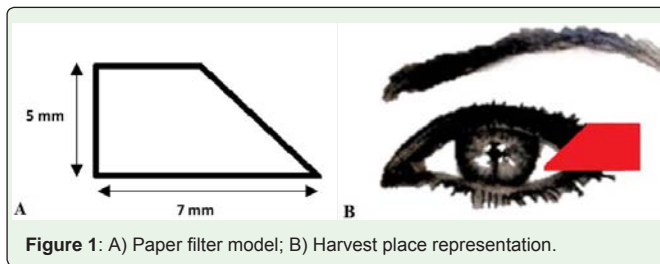
Methods

Studies cases

50 samples of ocular impression cytology of the bulbar conjunctiva were obtained from volunteers, students and teachers of the Escola Superior de Tecnologia da Saúde de Lisboa.

Collection and Handling of Samples

The technique of printing cytology required four fundamental methodological steps: harvest, fixation, staining and evaluation. The harvesting material includes a strip of cellulose acetate from Millipore Corporation, HAWP304F0 catalog code, with a 0.45 μ pore. A paper model [4], approximately 7mm wide by 5mm high with apex was applied (Figure 1). This format allows the specimen arrangement on the filter paper to be kept constant, and posteriorly its orientation on the blade. Without the need for topical anesthesia, the apex of the filter paper is applied to the corneal surface with the aid of a round-tipped forceps, pressing with a swab for a period of 2 to 5 seconds. It is removed by the peeling maneuver and placed immediately in SureThin. This filter is placed on a histological cassette previously identified with a code. Samples remained in the fixative liquid for 15minutes. At this stage, it is extremely important to always place the filter paper in the same position,



so that during the staining the face with the cell sample is facing upwards, avoiding contamination and loss of material. The adhesion of the conjunctiva on the filter at the time of withdrawal indicates an adequate harvest. The filter should be protected from contact with the tear. The samples were all stained with Papanicolaou staining that was performed on the same day of collection. It is important to note that the stage of color bleaching is extremely important because it allows the filter paper to become transparent. The slides were evaluated by three external evaluators, using a validated evaluation grid, which were rated with a score of 0 to 2.

Results

The shape of the filter paper allowed a correct positioning of the sample during fixation and staining. All cases had significant cell samples. Worse results were obtained in subjects with excessive eye tearing.

Regarding cell size, this was maintained, with 84.7% of the responses to the maximum score 2 ("Cell Size Not Altered"). The cells did not undergo retraction, being an indication that SureThin is a good fixative and had the intended effect. Regarding the parameter "Cytoplasmic Detail", it was verified that there was a higher absolute frequency for score 2 ("Visualization of all cytoplasmic details"), with 82.0% of the responses. The "Cytoplasmic Membrane" was preserved, with well-defined contours, obtaining 84.0% of the responses for the parameter "Well-defined Cytoplasmic Limits" and 2.7% for the parameter "Cytoplasmic Limits that make evaluation impossible". The "nuclear detail" presented 111 responses in 150 for score 2

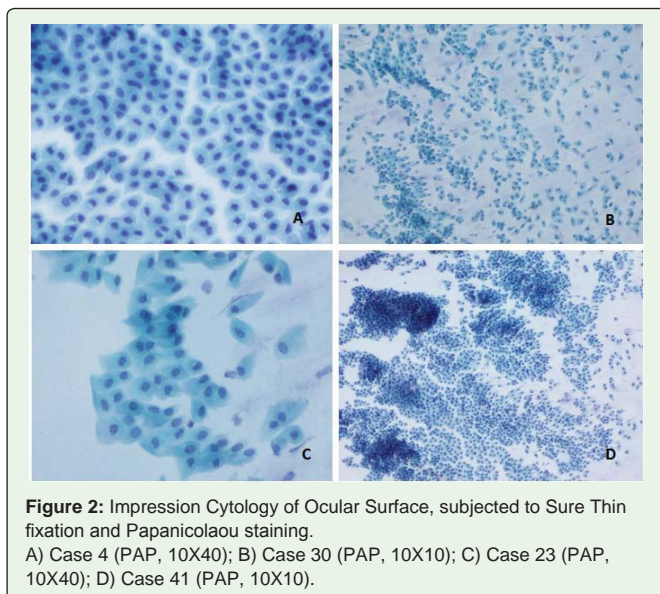


Figure 2: Impression Cytology of Ocular Surface, subjected to Sure Thin fixation and Papanicolaou staining. A) Case 4 (PAP, 10X40); B) Case 30 (PAP, 10X10); C) Case 23 (PAP, 10X40); D) Case 41 (PAP, 10X10).

("Visualization of all nuclear details"). The "nuclear membrane" remained intact and well defined, with 114 responses for score 2 (76.0%). It was observed that the SureThin fixative was effective in the preservation, since 83.3% of the answers were obtained for score 2 ("Small nucleus with N/C ratio 1:6). In general, the staining affinity was maintained, allowing to differentiate its cellular constituents, with 123 responses in 150 for score 2. (Figure 2 (a,b,c,d)) shows the quality of the samples collected in this study.

Discussion

Many cases in which corneal surface pathologies are present, biopsy are contraindicated [5]. The lack of literature to support the various steps of the cytological ocular printing technique, namely in the fixation step, poses a problem when practicing the technique. The method used proved to be ideal for the evaluation of cytological exams by ocular impression. Our technique differs from some authors mainly at the fixer level used. Adams et al. [5] reports the importance of fixation in this type of samples, suggesting other possible fixatives such as formaldehyde, ethanol, methanol and fixative spray. However, there are no studies in the literature that indicate the most effective fixation method. The coloring technique used presented good results, being easy to execute and economical, although it did not belong to Martinez et al. [6], which uses a modified method of Periodic Acid-Schiff, Hematoxylin and Papanicolaou. The clarification stage in xylene is emphasized by Stolz [2]. This will allow for the subsequent analysis by optical microscopy, once the filter paper becomes transparent in organic solvents, used in the stage of the diaphanization, during the staining. The use and care of alcohol-based reagents was based on quotes from Michalany [7], which recommends the exchange of ethanol and never re-use.

Conclusion

The present method proved to be effective for the evaluation of ocular surface cells, using a cost effective and comfortable technique for the patient, easily applicable in the hospital routine.

References

1. Rito I. Utilização da Citologia Conjuntival no Diagnóstico de Doenças Oculares. Texto Inédito. Universidade Técnica de Lisboa. 2009.
2. Stolz AP. Citologia de impressão conjuntival em voluntários saudáveis. Texto Inédito. Porto Alegre: Universidade Federal do Rio Grande do Sul. 2009.
3. Borges RF, de Freitas Cardoso KC, Bolzan AA, Momo C, dos Santos Honsho C. Estudo comparativo de métodos de coleta e coloração para citologia conjuntival em cães normais. *Veterinária e Zootecnia*, 2012; 19; 381-391.
4. Barros, Vera Lucia DMM, José Álvaro PG, de Freitas D, de Lima ALH. Citologia de impressão da superfície ocular: técnica de exame e de coloração. *Arq. Bras. Oftalmol.* São Paulo. 2001; 64: 127-131.
5. Adams GG, Dilly PN. Differential staining of ocular goblet cells. *Eye*, 1989; 3; 840-844.
6. Martinez AJ, Mills MB, Jaceldo KB, Tio FO, Aigbivbalu IB, Hilsenbeck SB, et al. Standardization of conjunctival impression cytology. *Cornea*. 1995; 14: 512-522.
7. Michalany J. Técnica histológica em anatomia patológica (com instruções para o cirurgião, enfermeira e citotécnico). São Paulo: Editora Michalany; 1990.