

Beware of the Unexpected: Acute Coronary Thrombosis Following the Mildly Symptomatic COVID-19 Infection and Two Different Therapeutic Options

Murat Gul, Sinan Inci

Department of Cardiology, Medical Faculty, Aksaray University, Aksaray, Turkey

ARTICLE INFO

Article history:

Submitted: 23. 5. 2022

Revised: 20. 6. 2022

Accepted: 25. 6. 2022

Available online: 20. 2. 2023

Klíčová slova:

Akutní koronární trombóza

Covid-19

Postupy při léčbě

SOUHRN

Onemocnění covid-19, které v březnu 2020 přerostlo v pandemii, se celosvětově vyznačovalo vysokou morbiditou a mortalitou. I když nejčastějším klinickým projevem jsou respirační symptomy, jsou časté i kardiální komplikace, které představují nové výzvy pro zdravotnický systém. Popisujeme případy dvou mírně symptomatických ambulantních pacientů s onemocněním covid-19, kteří se dostavili k lékařům s akutním infarktem myokardu s elevací úseku ST (STEMI) a vysokou zátěží tromby v koronárních tepnách bez aterosklerotických plátů. V kazuistice popisujeme dva odlišné postupy při léčbě, které dokonale ilustrují problémy, s nimiž se lze setkat při péči o pacienty s trombózou věnčitých tepen, u nichž byly diagnostikovány STEMI a onemocnění covid-19. Lékaři v klinické praxi musejí mít na paměti hyperkoagulační stav vyvolaný onemocněním COVID-19, a to i u mírně symptomatických ambulantních pacientů; účinnou alternativou perkutánní koronární intervence přitom může být agresivní farmakoterapie.

© 2023, ČKS.

ABSTRACT

COVID-19 infection was declared a pandemic in March 2020 and is responsible for high morbidity and mortality around the globe. Although the most common clinical presentation is respiratory, cardiac complications are common and create new challenges for healthcare. We discuss two mildly symptomatic outpatients with COVID-19 presenting with acute ST-elevation myocardial infarction (STEMI) and high coronary thrombus burden without atherosclerotic plaque. Our report describes two different therapeutic approaches that illustrate the challenges encountered in the management of disseminated coronary thrombosis in patients with STEMI and COVID-19. Clinicians should be aware of the high pro-coagulant state caused by COVID-19, even in mildly symptomatic outpatients, and aggressive pharmacological therapy may be an effective alternative treatment option to percutaneous coronary intervention.

Keywords:

Acute coronary thrombosis

COVID-19

Therapeutic options

Introduction

COVID-19 infection, which is caused by the novel coronavirus SARS-CoV-2, has rapidly emerged as a global public health problem. Although the most common clinical presentation is respiratory, cardiac complications are frequent and may be incidental even in the absence of underlying cardiovascular disease or comorbidities.¹ SARS-CoV-2 infection is closely associated with an increased thrombotic risk, mainly observed in the pulmonary or cerebral circulation.² However, these complications have been largely observed in hospitalized patients with extensive pulmonary involvement.³ Here, we report two patients with acute

coronary thrombosis following non-hospitalized mildly symptomatic COVID-19 infection. We also present two different therapeutic approaches that illustrate the challenges encountered in the management of severe coronary thrombosis in patients with ST-segment elevation myocardial infarction (STEMI) and COVID-19.

Case 1

A 47-year-old, healthy male patient was admitted to our emergency department with severe chest pain radiating to the jaw, which had started about 30 min before the

Address: Murat Gul, MD, Department of Cardiology, Medical Faculty, Aksaray University 68100 Aksaray, Turkey, e-mail: dmruratgul68@gmail.com

DOI: 10.33678/cor.2022.074

presentation. He did not have a history of coronary artery disease (CAD), diabetes mellitus, or hyperlipidemia. He also denied smoking, alcohol intake, or substance abuse. He had a history of COVID-19 infection 12 days earlier, which was confirmed with reverse transcriptase-polymerase chain reaction testing (RT-PCR). However, he was treated as an outpatient and no specific therapy was instituted for COVID-19, as the patient remained without respiratory symptoms. Physical examination was unremarkable, with BP 135/82 mmHg and heart rate 75 beats per minute, regular. Also, body temperature was 37.1 °C, and peripheral O₂ saturation was 96%. Electrocardiography revealed sinus rhythm with STEMI in the anterior leads (V₁-V₅ leads) (Fig. 1A) but the chest radiogram was completely normal. The echocardiogram revealed hypokinesia of the anterior, anteroseptal, and lateral left ventricular walls with an ejection fraction of 40%. The echocardiogram also excluded the possibility of paradoxical embolism due to a foramen ovale or atrial septal defect as well as an intracardiac embolic source. Other laboratory tests showed changes in C-reactive protein at 7.6 mg/L (normal range: 0-5 mg/L), D-dimer 0.564 µg/mL (normal range: <0.52 µg/mL), LDH 5600 U/L (normal range: 120 to 246 U/L) and leukocytosis of 12.33 cell/µL. Troponin I value was 462 pg/mL (normal range <17.50 pg/mL).

Medical treatment was started with clopidogrel 600 mg and acetylsalicylic acid 300 mg and an emergent coronary angiogram was performed through right femoral access. Coronary angiography revealed a large burden of thrombotic stenosis of the proximal left anterior descending (LAD) artery, which extended to the distal left main coronary artery and an occlusive filling defect compatible with thrombus at the middle segment of the LAD (Figs 1B, 1C). Additionally, there were no atherosclerotic lesions in other coronaries. After heparinization with

10.000 units of unfractionated heparin, wiring was successfully performed; however, multiple balloon dilatation failed to restore blood flow. Afterwards repeated thrombus aspiration attempts (Hunter, IHT Cordynamic, Barcelona, Spain) also failed. Local low-dose fibrinolytic was administered then (10 mg Alteplase over 5-10 min) via a guiding catheter followed by 3 more rounds of aspiration, with a minimal recovery of distal flow. The decision was to manage LAD thrombus medically for 5 days with low-molecular-weight heparin and dual antiplatelet therapy, and a new procedure was performed. The final angiogram revealed no thrombus in the proximal LAD that did not cause luminal stenosis, and a patent distal bed without underlying atherosclerotic plaque (Fig. 1D). Finally, STEMI was assumed due to in situ thrombosis in the absence of atheroma in the LAD. The screening was negative for prothrombotic states (protein C, protein S, anticardiolipin antibody, and Factor V Leiden). In the hospital follow-up, adverse clinical, electrocardiographic, echocardiographic changes, and major or minor complications were not observed. The patient was discharged uneventfully with acetylsalicylic acid, clopidogrel, atorvastatin, ramipril, and metoprolol therapy 3 days later. Three months later, there were no notes at the follow-up visit.

Case 2

A 48-year-old male patient without cardiovascular risk factors presented to the emergency department with acute onset chest pain for 1 h. At presentation, the patient was afebrile with a blood pressure of 142/82 mmHg, respiratory rate of 18, and oxygen saturation of 94% on room air. Pulmonary and cardiovascular physical exams were

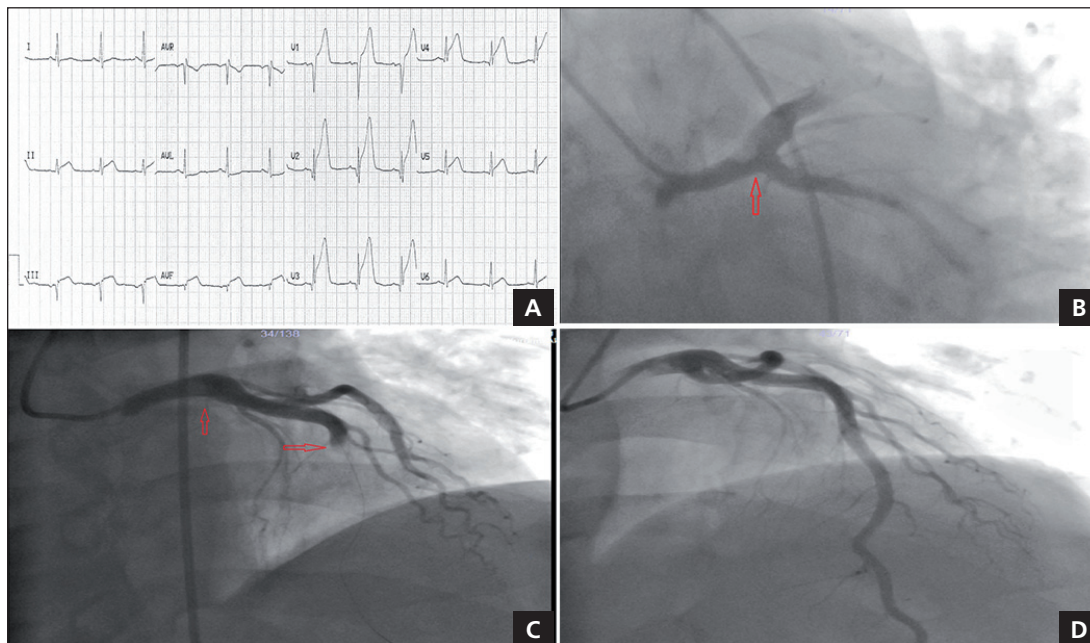


Fig. 1 – (A) Initial ECG revealed ST elevations in leads V₁-V₅. (B, C) Coronary angiography showed total occlusion of left anterior descending artery and left main thrombosis. (D) The final angiogram revealed resorbed thrombus in the left main and TIMI 3 flow is provided in left anterior descending artery.

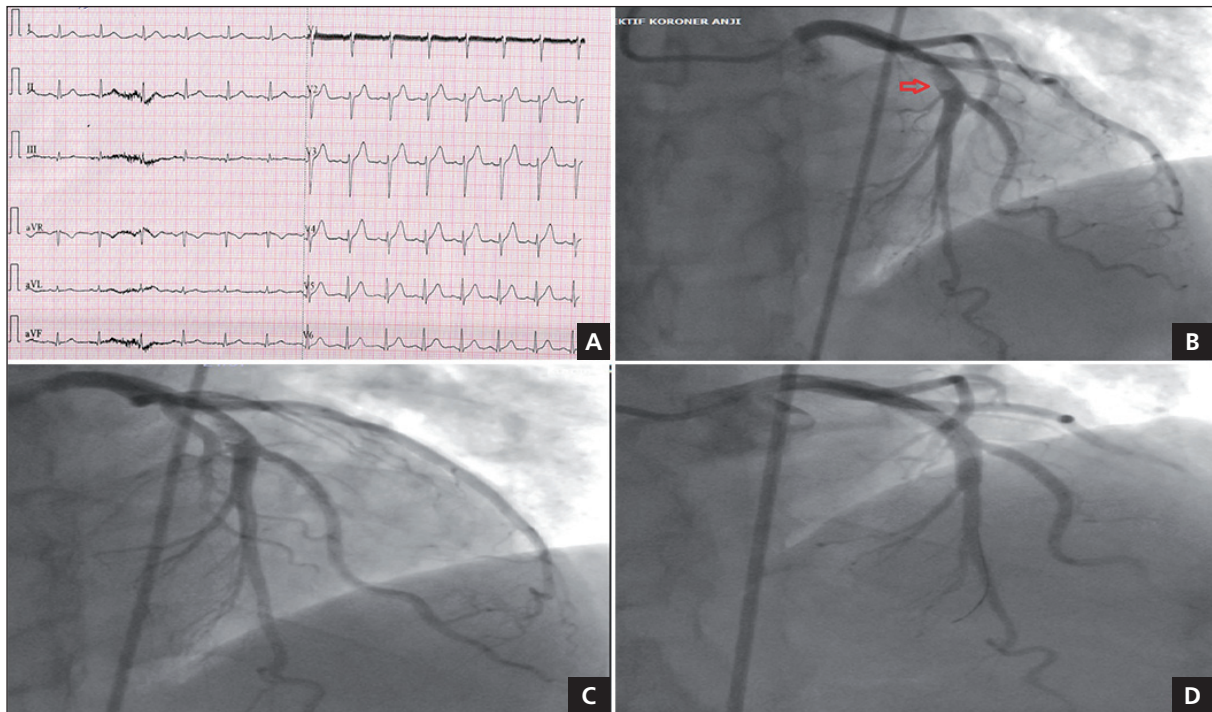


Fig. 2 – (A) The ECG showed new hyperacute T waves in leads V_1 – V_6 . **(B, C)** Coronary angiography demonstrated thrombus in the proximal left anterior descending artery. **(D)** The final angiogram showed excellent angiographic results and no complications after stenting.

also unremarkable. The ECG showed new hyperacute T waves in leads V_1 – V_6 (Fig. 2A) and the patient immediately received loading doses of dual antiplatelet therapy (clopidogrel 600 mg and acetylsalicylic acid 300 mg). Emergent coronary angiography demonstrated a massive intraluminal thrombus leading to 80–90% stenosis in the proximal region of the LAD with distal TIMI 2 flow and no stenosis or atherosclerotic plaque in other coronary vessels (Figs 2B, 2C). Because of stuttering chest pain and high thrombotic load, an intra-arterial weight-adjusted dose of heparin was administered, after which the lesion was successfully treated with a drug-eluting stent with excellent angiographic results and no complications (Fig. 2D). The patient was transferred to the intensive care unit with complete resolution of symptoms and electrocardiographic improvement. The patient was treated with dual antiplatelet therapy and additional anticoagulation for 5 days.

C-reactive protein level was elevated at 9 mg/L (normal value <5), which normalized in subsequent days. The blood D-dimer level was 0.697 $\mu\text{g/mL}$ (normal range: <0.52 $\mu\text{g/mL}$) and the fibrinogen level was 3.83 g/L, with only mild leucocyte elevation (14.3 cell/ μL). An echocardiogram was performed to evaluate the possibility of intracardiac thrombus, vegetation, or paradoxical embolism. Normal biventricular size and function (left ventricular ejection fraction: 55%) were found without shunt or thrombus. There were no episodes of atrial fibrillation during the follow-up. A nasopharyngeal swab was performed using RT-PCR for SARS-CoV-2 due to suspicion of COVID-19 and it was positive. Computed tomography revealed no pulmonary involvement associated with COVID-19. Usual specific treatment was initiated for

COVID-19, as the patient remained without respiratory symptoms. The patient was discharged with acetylsalicylic acid, clopidogrel, statin, ramipril, and beta-blocker therapy. He was still asymptomatic under the same medical therapy at the 3th-month follow-up visit.

Discussion

COVID-19 infection was declared a pandemic in March 2020 and is responsible for high morbidity and mortality around the globe. With growing knowledge about COVID-19, acute cardiac events are also increasingly being reported. Cardiovascular manifestations are well-known complications of COVID-19 and range from myocardial injury to myocardial infarction, fulminant myocarditis, heart failure, malign arrhythmias, and cardiogenic shock.⁴

Numerous studies have demonstrated that patients with COVID-19 are prone to both venous and arterial thromboembolic complications, including venous thromboembolism, stroke, acute myocardial infarction, and acute lower extremity ischemia.^{5,6} Additionally, coronary thrombotic events have been reported even in patients receiving optimal antithrombotic therapy⁷ and effective anticoagulation therapy.⁸ Many different pathophysiological mechanisms have been proposed to explain the hypercoagulable state of COVID-19 infection. These include endothelial damage, elevated proinflammatory cytokines that activate the coagulation cascade and inhibit fibrinolysis, increased nonspecific inflammatory biomarkers, as well as several pro-coagulant factors such as the von Willebrand factor and factor VIII.⁸

We reported two different mildly symptomatic COVID-19 patients with no risk factors for CAD and had an episode of STEMI with a high thrombotic burden without evidence of atherosclerotic disease in other coronary arteries. Since patients do not have other known risk factors for coronary thrombosis, viral infection, and inflammatory response are likely to play an important role in the activation of the coagulation cascade as a cause of coronary thrombosis. Similar to previous reported cases, our patients had massive coronary thrombosis that was not associated with the severe acute respiratory syndrome, supporting the possibility of spontaneous thrombotic events even in COVID-19 patients without severe respiratory or systemic manifestations.^{7,9} Consequently, regarding the prevalence of COVID-19 and the fact that many patients may be asymptomatic, clinicians should be aware of the potential risk of outpatients combining STEMI and COVID-19.

COVID-19 has a negative impact on STEMI patients, either directly with an increased incidence of developing acute heart failure or indirectly through the increased delay between primary percutaneous coronary intervention and the first medical contact.⁷ Furthermore, PCI in the context of STEMI and heavy thrombus burden can be challenging as it is associated with complications such as distal embolization, no-reflow, slow flow, and stent thrombosis. The pathophysiology of STEMI in COVID-19 patients may not be associated with an unstable culprit lesion.^{10,11} Indeed, previous reports revealed that COVID-19 can induce spontaneous coronary thrombosis, even in the absence of atheroma.¹² Therefore, in the context of severe coronary thrombus without atherosclerosis, a delayed stent strategy may also be preferable, considering stent implant only in cases where an obvious stenosis/culprit lesion has been identified. Intracoronary low-dose thrombolysis, which is a safe and effective treatment,¹³ may be an alternative treatment option in patients with COVID-19, STEMI, and massive thrombotic burden, as in our first case. We believe that more aggressive pharmacological treatments, such as intracoronary fibrinolytic, glycoprotein IIb/IIIa inhibitor, and long-term use of anticoagulants, should be kept in mind along with the prothrombotic state associated with COVID-19 infection, especially in the case of failed PCI.

The main limitation of our report was the lack of advanced intracoronary imaging (IVUS, OCT) for diagnostic evaluation. The use of intracoronary imaging methods could provide reliable information for identifying possible etiological pathologies (plaque rupture, calcification, spontaneous coronary artery dissection, intramural hematoma, and intramural inflammation) and optimal therapeutic option.

Conclusion

Clinicians should be aware of the high pro-coagulant state caused by COVID-19, even in mildly symptomatic outpatients, and aggressive pharmacological therapy may be an effective alternative treatment option to PCI.

Conflict of interest

None.

References

1. Madjid M, Safavi-Naeini P, Solomon SD, Vardeny O. Potential effects of coronaviruses on the cardiovascular system: a review. *JAMA Cardiol* 2020;5:831–840.
2. Dominguez-Erquicia P, Dobarro D, Raposeiras-Roubin S, et al. Multivessel coronary thrombosis in a patient with COVID-19 pneumonia. *Eur Heart J* 2020;41:2132.
3. Hanff TC, Mohareb AM, Giri J, et al. Thrombosis in COVID-19. *Am J Hematol* 2020;95:1578–1589.
4. Fried JA, Ramasubbu K, Bhatt R, et al. The variety of cardiovascular presentations of COVID-19. *Circulation* 2020;141:1930–1936.
5. Zhai Z, Li C, Chen Y, et al. Prevention and treatment of venous thromboembolism associated with coronavirus disease 2019 infection: a consensus statement before guidelines. *Thromb Haemost* 2020;120:937–948.
6. Al-Ani F, Chehade S, Lazo-Langner A. Thrombosis risk associated with covid-19 infection. A scoping review. *Thromb Res* 2020;192:152–160.
7. Lacour T, Semaan C, Genet T, Ivanec F. Insights for increased risk of failed fibrinolytic therapy and stent thrombosis associated with COVID-19 in ST-segment elevation myocardial infarction patients. *Catheter Cardiovasc Interv* 2021;97:E241–E243.
8. Hatamnejad MR, Tafti FF, Abdi A, et al. Coronary Thrombosis in a Patient with COVID-19 Who Was on Anticoagulant Therapy. *Int Cardiovasc Res J* 2021;15(3).
9. Zaldivar Zurita HJ, Leal Cavazos JE, Carrillo Fernandez CD, et al. Single-Vessel Massive Coronary Thrombosis in a Patient with COVID-19 Infection: A Case Report. *Am J Clin Cardiol* 2021;2:1012.
10. Viana T, Bezerra MLBG, Melo RMV, et al. Acute Myocardial Infarction with Coronary Thrombosis in a Covid-19 Patient without Risk Factors for Cardiovascular Disease. *Arq Bras Cardiol* 2021;116:511–515. [Article in English, Portuguese]
11. Zaldivar Zurita HJ, Leal Cavazos JE, Carrillo Fernandez CD, et al. Single-Vessel Massive Coronary Thrombosis in a Patient with COVID-19 Infection: A Case Report. *Am J Clin Cardiol* 2021;2:1012.
12. Espejo PP, Gonzales DAC, Jiménez MVM, Fernandez FJP. Acute thrombosis of the right coronary artery in a patient with COVID-19. *Eur Heart J Case Rep* 2020;4:1–3.
13. McCartney PJ, Eteiba H, Maznyczka AM, et al. Effect of lowdose intracoronary alteplase during primary percutaneous coronary intervention on microvascular obstruction in patients with acute myocardial infarction: a randomized clinical trial. *JAMA* 2019;321:56–68.