








# A rare case of autoimmune dysglycemia syndrome associated with systemic lupus erythematosus and dermatomyositis

José Paz-Ibarra <sup>1</sup> , Marcio Concepción-Zavaleta <sup>2\*</sup> , Juan Eduardo Quiroz-Aldave <sup>3</sup> , Mikaela Kcomt Lam <sup>4</sup> ,  
Edwards Gilvonio Huauya <sup>5</sup> , Diego Sueldo Espinoza <sup>5</sup> , George Gago Cajacuri <sup>5</sup> 

<sup>1</sup> Division of Endocrinology, Hospital Nacional Edgardo Rebagliati Martins, Universidad Nacional Mayor de San Marcos, Lima, PERU

<sup>2</sup> Division of Endocrinology, Norbert Wiener University, Voto Bernales Hospital, Lima, PERU

<sup>3</sup> Division of Medicine, Hospital de Apoyo Chepén, Chepén, PERU

<sup>4</sup> Department of Medicine, Universidad Privada Antenor Orrego, Trujillo, PERU

<sup>5</sup> Universidad Nacional Mayor de San Marcos, Lima, PERU

\*Corresponding Author: [marcio.concepcion@uwiener.edu.pe](mailto:marcio.concepcion@uwiener.edu.pe)

**Citation:** Paz-Ibarra J, Concepción-Zavaleta M, Quiroz-Aldave JE, Kcomt Lam M, Gilvonio Huauya E, Sueldo Espinoza D, Gago Cajacuri G. A rare case of autoimmune dysglycemia syndrome associated with systemic lupus erythematosus and dermatomyositis. *Electron J Gen Med.* 2023;20(5):em512. <https://doi.org/10.29333/ejgm/13294>

## ARTICLE INFO

Received: 05 Apr. 2023

Accepted: 09 May 2023

## ABSTRACT

Autoimmune dysglycemia syndrome (ADS) is a rare condition that presents as episodes of hypoglycemia as well as hyperglycemia and is classified as insulin autoimmune syndrome (IAS) and type B insulin resistance (TBIR). Autoimmunity plays a key role in the pathogenesis of this disorder, as evidenced by the presence of autoantibodies against endogenous insulin or the insulin receptor, and by its association with rheumatologic disorders. Treatment usually includes glycemic control and immunomodulatory agents. We report a case of a 31-year-old woman who was admitted for severe hypoglycemia. Further workup revealed underlying systemic lupus erythematosus (SLE) with renal involvement. During hospitalization, she continued to experience episodes of fasting hypoglycemia, as well as episodes of postprandial hyperglycemia. Hypoglycemia associated with a high serum insulin concentration and positive anti-insulin antibodies were consistent with IAS. Likewise, hyperglycemia and hypoglycemia in association with weight loss, acanthosis nigricans, polycystic ovarian syndrome, and normotriglyceridemia strongly suggested TBIR, although testing for antibodies against the insulin receptor was not available in Peru. Immunosuppressive therapy and metformin were indicated, resulting in remission of SLE and ADS. Years later, the patient exhibited features of dermatomyositis, such as Raynaud's phenomenon, muscular weakness, heliotrope exanthema, and elevated muscle enzymes. Once again, the patient received immunosuppressive therapy. ADS is an infrequent cause of hypoglycemia, and the coexistence of its two pathophysiological mechanisms in a patient with SLE and subsequent development of dermatomyositis is even more rare. Our case is the first one reported describing this association.

**Keywords:** hypoglycemia, hyperinsulinism, autoantibodies, systemic lupus erythematosus, dermatomyositis, autoimmune diseases

## INTRODUCTION

Autoimmune dysglycemia syndrome (ADS) is characterized by a high serum insulin concentration due to insulin autoantibodies or insulin receptor autoantibodies, resulting in dysglycemia [1]. ADS includes insulin autoimmune syndrome (IAS) and type B insulin resistance syndrome (TBIR), caused by insulin autoantibodies and insulin receptor autoantibodies, respectively [1, 2]. Several conditions have been linked to IAS, including the use of drugs containing a sulfhydryl group (metamizole, alpha-lipoic acid, penicillamine, glutathione, captopril, isoniazid, and thiamazole, among others), some viral infections, blood dyscrasias and autoimmune diseases, while TBIR is commonly associated with autoimmune diseases [2-4].

Autoimmune diseases that most commonly coexist with ADS include systemic lupus erythematosus (SLE), rheumatoid arthritis, scleroderma, and myositis. Patients with ADS may

even have overlapping clinical manifestations of multiple distinct immune disorders, such as SLE and dermatomyositis [5, 6]. This case report aims to present a female patient with initial manifestations compatible with the two known forms of ADS (IAS and TBIR) in association with SLE, followed by the development of dermatomyositis. This triple association has not been previously reported.

## CASE REPORT

This case describes a previously healthy 31-year-old Peruvian woman who was admitted to the Emergency Department with altered mental status, seizures, and a capillary glucose of 36 mg/dl, which prompted the administration of four ampoules of intravenous 33% dextrose, resulting in the complete resolution of her symptoms, meeting the criteria for Whipple's triad.

**Table 1.** Changes in laboratory parameters during natural history of diseases

Laboratory parameter (reference range)	Age (years)			
	31	34	39	41
Fasting glucose (70-100 mg/dL)	32 to 52	79	86	83
Fasting insulin (5-25 UI/ml)	69.3 to >300	4.5	16.8	11.2
Fasting C-peptide (0.5-2 ng/ml)	3 to 8.9	0.9	1.8	1.4
2 h postprandial glucose (<140mg/dL)	200 to 400	128	114	106
AIAb (<0.5 U/L)	4.7	<0.5	<0.5	<0.5
24-h urine protein (<150 mg/day)	4.2	0.04	0.05	0.03
ANA	Positive: 1/2560	Positive: 1/80	Positive: 1/320	Positive: 1/320
CPK (30-210 U/L)	33	8,347	14,800	136

Note. AIAb: Anti-insulin autoantibodies; ANA: Antinuclear antibodies; & CPK: Creatine phosphokinase

Once the hypoglycemia was corrected, she was hospitalized to complete diagnostic studies. In terms of her past medical history, she had tuberculosis at the age of 14, does not take any medications at home, and has no history of substance abuse. Regarding family history, her mother has type 2 diabetes mellitus, and her father has been diagnosed with thyroid cancer. She reported being asymptomatic until 6 months before admission when she started to present polyarthralgia, weight loss, hair loss, oral ulcers, and amenorrhea. Physical examination revealed normal vital signs, thin appearance (weight: 46 kg, body mass index: 19.2 kg/m<sup>2</sup>), acanthosis nigricans in the neck and armpits, mild hirsutism (modified Ferriman-Gallwey score: 14 points), palatal erythema, malar rash, polyarthritis, and mild pretibial edema. Her hospital course was complicated by persistent fasting hypoglycemia and some episodes of postprandial hyperglycemia between 200 mg/dl and 400 mg/dl.

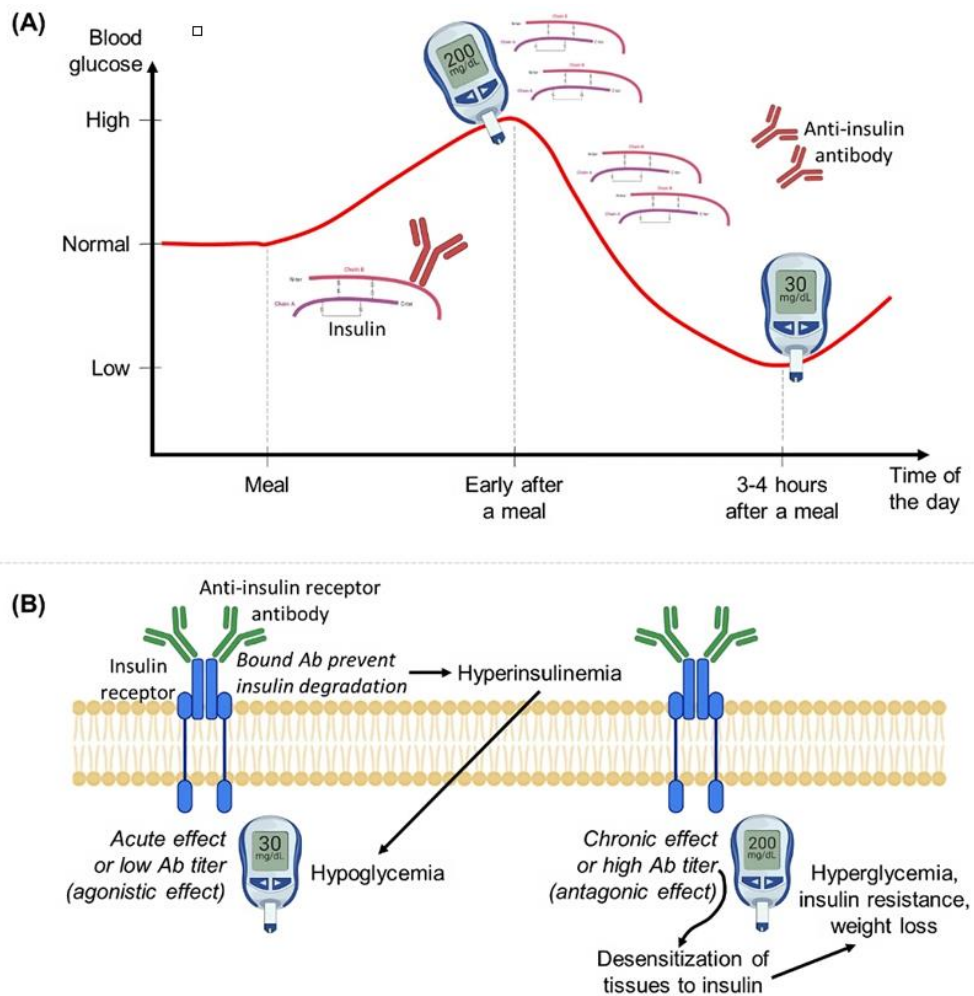
Laboratory studies revealed fasting hypoglycemia ranging from 32 to 52 mg/dL, elevated fasting insulin ranging from 69 up to more than 300 UI/mL, C-peptide of 3 ng/ml (reference range: 0.5-2 ng/ml), and positive anti-insulin antibodies with a value of 4.7 U/mL (reference value: <0.5 U/mL), which were consistent with hyperinsulinemic hypoglycemia. The complete blood count showed normocytic normochromic anemia. Thyrotropin and free thyroxine levels were normal, and anti-thyroid peroxidase and anti-thyroglobulin antibodies were negative. beta-human chorionic gonadotropin subunit was negative, androgens (free testosterone, androstenedione, and dehydroepiandrosterone sulfate) were normal, liver function tests were normal, and the lipid panel showed hypercholesterolemia with normotriglyceridemia. Anti-insulin receptor antibodies were not available at that time. Positive results were found for antinuclear antibodies (ANA) with a dense fine speckled pattern, anti-smith, and anti-double-stranded DNA (anti-dsDNA) antibodies, while anticardiolipin, anti-RNP (anti-ribonucleoprotein), anti-Ro, and anti-La antibodies were negative. Further laboratory workup revealed marked proteinuria (4.2 g/24 h), and hyperprolactinemia of 55 ng/ml (reference range: 5-25 ng/ml) (Table 1). Hypocomplementemia was also found. A kidney biopsy showed findings consistent with membranous glomerulonephritis.

Computed tomography (CT) of the chest, abdomen, and pelvis did not show significant abnormalities. As part of testing to determine the cause of elevated prolactin, magnetic resonance imaging (MRI) of the pituitary gland was ordered, but no changes were found in the pituitary gland. A triphasic dynamic contrast-enhanced CT scan of the pancreas was performed to rule out insulinoma as the cause of hypoglycemia.

Finally, the diagnosis made was ADS associated with SLE with renal, hematologic, and articular involvement. Initial treatment consisted of prednisone 30 mg/day, azathioprine 125 mg/day, and hydroxychloroquine 400 mg/day, resulting in the improvement of the proteinuria and arthritis symptoms. Glucose levels were initially stabilized with insulin (NPH 40 units/day and regular insulin 24 units/day) and subsequently, with metformin and diet.

The patient was followed up in the outpatient clinic, remaining asymptomatic and maintaining adequate glycemic control with metformin 500 mg BID, which was later suspended due to persistent euglycemia. Her menstrual cycle normalized, and acanthosis nigricans decreased significantly. According to Rheumatology follow-up visits, the proteinuria resolved, and SLE remained in remission without the use of additional corticosteroids.

At the age of 34, she presented with recurrent episodes of Raynaud's syndrome and proximal weakness of the lower extremities with difficulty going up and down the stairs. During hospitalization, we noticed crusty ulcers on the finger pads of both hands, Gottron's papules, butterfly rash, and heliotrope rash. Moreover, laboratory results showed a positive ANA (1/80) and elevated transaminases (AST: 377 UI/L, ALT: 263 UI/L) and creatine phosphokinase (CPK: 8347 UI/L). Glucose levels were normal and anti-insulin antibodies were negative. Electromyography revealed a mixed pattern that consisted of spontaneous activity with small, short, and polyphasic motor unit potentials and early recruitment. Muscle biopsy showed perifascicular atrophy as well as perivascular and perimysial inflammatory infiltrates containing CD4+ T lymphocytes and B lymphocytes. Dermatomyositis was diagnosed, and the patient was started on prednisone 60 mg/day, hydroxychloroquine 400mg/day, methotrexate 10 mg/day, and nifedipine 30 mg/day, achieving an adequate clinical and laboratory response. At the age of 39, the patient returned complaining of worsening proximal myopathy that did not improve despite an increase in prednisone dose from 15 to 60 mg daily. She also developed acanthosis nigricans on her neck and skin folds as well as a characteristic moon face. At the time, CPK level was elevated at 14 800 U/L and glucose levels were normal. As a result of these new findings, she was hospitalized and received a high dose of methylprednisolone, with subsequent favorable clinical and laboratory response. At the age of 41, during her follow-up via telemedicine throughout the pandemic, she reported feeling well without limitation of her daily activities. Her glucose levels (86 mg/dl) and insulin levels (12 UI/mL) remained normal and anti-insulin antibodies remained negative. Also, she had a decrease in CPK levels (136 UI/L) and proteinuria was absent. As of now, her episodes of dysglycemia have not recurred and she continues to have outpatient follow-up in rheumatology and endocrinology departments.



**Figure 1.** Underlying pathophysiology of (A) insulin autoimmune syndrome & (B) type B insulin resistance syndrome (Ab: Antibody) (Source: Authors' own elaboration)

## DISCUSSION

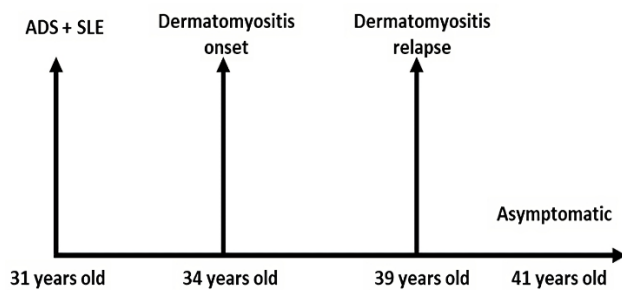
In this case, ADS was suspected due to episodes of recurrent hypoglycemia alternating with postprandial hyperglycemia associated with inappropriately elevated fasting insulin and was confirmed by the presence of anti-insulin antibodies, compatible with IAS. Remarkably, she also exhibited clinical features consistent with TBIR. Our patient had not received insulin prior to her hospitalization at age 31.

IAS affects white men and women with an average age between 40 and 80 years old and is characterized by hyperinsulinemic hypoglycemia associated with a high titer of anti-insulin antibodies, in the absence of pathologic abnormalities of the  $\beta$  islets and prior exposure to exogenous insulin [1, 7]. While 50% of reported cases of IAS are related to medications, such as methimazole, alpha-lipoic acid, clopidogrel, esomeprazole, and captopril, less than 5% of cases are associated with rheumatologic autoimmune diseases [7]. Acanthosis nigricans is rare in IAS and there is usually no hyperandrogenism. In IAS, hypoglycemia is usually described as fasting, reactive, or both, and there is also postprandial hyperglycemia [7]. IAS treatment usually involve withdrawing suspected medication, dietary adjustments, and  $\alpha$ -glucosidase inhibitors [7]. Patients who do not respond to initial therapy are treated with immunosuppression. It was shown that 41.7% of IAS cases required immunosuppressant treatment; while

54.4% recovered with changes in diet, discontinuation of triggering factor, and  $\alpha$ -glucosidase inhibitors [8].

Furthermore, our patient presented acanthosis nigricans, hyperandrogenism, and episodes of hyperglycemia; features found in TBIR [3]. This entity mainly affects black women between 40 and 50 years old, and is not typically drug-induced, but is associated with other autoimmune disorders, particularly SLE, which is present in 35% of cases [9]. Acanthosis nigricans and hyperandrogenism are common features of TBIR. There is mainly hyperglycemia, and less commonly, fasting, or reactive hypoglycemia. There are also normal or low levels of blood triglycerides [9]. Considering that the levels of antibodies against insulin were markedly elevated in association with the clinical manifestations described above, we concluded that the diagnosis of our patient was IAS and TBIR. Moreover, the coexistence of anti-insulin and anti-insulin receptor antibodies has been reported [10, 11]. TBIR is usually managed with dietary fragmentation, high doses of insulin, and immunosuppressants such as prednisone and cyclophosphamide [9].

The pathophysiology of IAS is not fully understood, however, after a meal or glucose load, anti-insulin antibodies bind the insulin secreted in response to rising blood glucose levels, leading to reduced insulin availability at the receptors in the liver and peripheral tissues, causing hyperglycemia and further insulin secretion [3, 7, 12]. When blood glucose levels start to decrease and insulin secretion declines, the insulin



**Figure 2.** Timeline describing main events of case reported (ADS: Autoimmune dysglycemia syndrome & SLE: Systemic lupus erythematosus) (Source: Authors' own elaboration)

bound to the antibodies is released, leading to inappropriately high free insulin concentrations for the blood glucose, causing hypoglycemia (part A in **Figure 1**) [3, 12].

About TBIR, anti-insulin receptor autoantibodies can initially act like insulin and prevent insulin degradation, leading to hyperinsulinemia and subsequent hypoglycemia [3, 13]. However, chronic exposure to these autoantibodies can lead to persistent hyperglycemia and insulin resistance [3, 9, 13]. The effect of these antibodies varies based on their concentration: high titers result in an antagonistic effect causing hyperglycemia, while low titers result in an agonistic effect causing hypoglycemia (part B in **Figure 1**) [3, 12, 13].

SLE is the most common autoimmune disease associated with ADS, specifically with TBIR [10, 11]. Dermatomyositis is also considered among the triggering autoimmune disorders for ADS [14]. Our patient had dermatomyositis, which was evidenced by proximal muscle weakness as well as elevation in CPK and confirmed by electromyography and muscle biopsy. Over the course of a 10-year follow-up, our patient presented ADS, SLE and dermatomyositis, making it a unique case that has not been reported in the literature so far (**Figure 2**).

Furthermore, our patient presented hyperprolactinemia, but no abnormalities were found on MRI of the pituitary gland. A possible association between hyperprolactinemia and SLE has been proposed. According to [15], elevated levels of prolactin are seen more frequently in patients with SLE than in the general population. The suggested mechanisms for this association include increased production of prolactin by lymphocytes, stimulation of pituitary prolactin secretion by proinflammatory cytokines and genetic factors [15].

Regarding treatment of IAS and TBIR, there are two approaches: glycemic control and immunosuppressive therapy. In our patient, glycemic control was achieved by insulin administration and subsequently metformin, which is usually used in TBIR [11]. Corticosteroids, azathioprine, plasmapheresis, and rituximab, among others, are usually used as immuno-modulating therapy for IAS and TBIR [16]. In this case, prednisone, hydroxychloroquine, and azathioprine were required for SLE treatment. The remission of SLE led to the stabilization of her blood sugars and resolution of the ADS. Cyclophosphamide and rituximab are reserved for severe cases of SLE [10, 17, 18].

In relation to the management of dermatomyositis [19], although the disease seemed controlled after its diagnosis, it progressed with an exacerbation that did not respond to an increase in the dose of prednisone (1 mg/kg/day), requiring high doses of methylprednisolone and cyclophosphamide;

combination previously used in four out of six cases of SLE and dermatomyositis [4].

## CONCLUSIONS

In conclusion, ADS (IAS and TBIR) is a rare but important cause of hypoglycemia. Although both have an autoimmune basis and both can cause hyperinsulinemic hypoglycemia, their pathophysiology, treatment, and prognosis are different. This case demonstrates the coexistence of both in a patient with SLE who subsequently developed DM, highlighting the importance of addressing the underlying autoimmune disorders in patients with ADS to achieve optimal glycemic control.

**Author contributions:** JPI, EGH, DSE, & GGC: designed outline of case report; JPI, MC-Z, & JEQ-A: performed literature review; & JPI & MKL: prepared manuscript. Kcomt-Lam M was translator and performed written contributions to the text body. All authors have agreed with the results and conclusions.

**Funding:** No funding source is reported for this study.

**Ethical statement:** Authors stated that the study was approved by the Ethics Committee of School of Medicine at National University of Trujillo on 18 March 2023.

**Declaration of interest:** No conflict of interest is declared by authors.

**Data sharing statement:** Data supporting the findings and conclusions are available upon request from the corresponding author.

## REFERENCES

1. Yu S, Yang G, Dou J, et al. Comparison of two autoimmune dysglycemia syndromes: Insulin autoimmune syndrome (IAS) and type B insulin resistance syndrome (B-IRS). *Horm Metab Res.* 2019;51(11):723-8. <https://doi.org/10.1055/a-1005-0071> PMID:31683342
2. Yukina MY, Davtyan DA, Troshina EA, Nuralieva NF. Autoimmune hypoglycemia. *Obes Metabol.* 2018;23(3):9-13. <https://doi.org/10.14341/omet9536>
3. Lupsa BC, Chong AY, Cochran EK, Soos MA, Semple RK, Gordon P. Autoimmune forms of hypoglycemia. *Medicine (Baltimore).* 2009;88(3):141-53. <https://doi.org/10.1097/MD.0b013e3181a5b42e> PMID:19440117
4. Łebkowska A, Krentowska A, Adamska A, et al. Type B insulin resistance syndrome associated with connective tissue disease and psoriasis. *Endocrinol Diabetes Metab Case Rep.* 2020;2020:20-0027. <https://doi.org/10.1530/EDM-20-0027> PMID:32755965 PMCid:PMC7424346
5. Maazoun F, Frikha F, Snoussi M, Kaddour N, Masmoudi H, Bahloul Z. Systemic lupus erythematosus myositis overlap syndrome: Report of 6 cases. *Clin Pract.* 2011;1(4):e89. <https://doi.org/10.4081/cp.2011.e89> PMID:24765389 PMCid:PMC3981442
6. Greidinger E. Overlap syndromes. In: Tsakos GC, editor. *Systemic lupus erythematosus: Basic, applied and clinical aspects.* Boston, MI: Academic Press; 2016. p. 425-30. <https://doi.org/10.1016/B978-0-12-801917-7.00048-6>
7. Lin M, Chen Y, Ning J. Insulin autoimmune syndrome: A systematic review. *Int J Endocrinol.* 2023;2023:e1225676. <https://doi.org/10.1155/2023/1225676> PMID:36844104 PMCid:PMC9946739

8. Patel M, Shah R, Ramteke-Jadhav S, et al. Management of insulin autoimmune hypoglycaemia: Single-centre experience from western India with systematic review of world literature. *Clin Endocrinol*. 2020;92(5):409-20. <https://doi.org/10.1111/cen.14174> PMID:32064669
9. Martins LM, Fernandes VO, Carvalho MMDD, Gadelha DD, Queiroz PCD, Montenegro RM. Type B insulin resistance syndrome: A systematic review. *Arch Endocrinol Metab*. 2020;64(4):337-48. <https://doi.org/10.20945/2359-399700000257> PMID:32813762
10. Zhang S, Wang G, Wang J. Type B insulin resistance syndrome induced by systemic lupus erythematosus and successfully treated with intravenous immunoglobulin: Case report and systematic review. *Clin Rheumatol*. 2013;32(2):181-8. <https://doi.org/10.1007/s10067-012-2098-x> PMID:23053690
11. Qing Y, Zhou JG, Yuan G. Systemic lupus erythematosus presenting as hypoglycaemia with insulin receptor antibodies and insulin autoantibodies. *Lupus*. 2009;18(5):457-9. <https://doi.org/10.1177/0961203308098188> PMID:19318401
12. Hughes LE, Fenn JS, Ford C, Gama R. Autoimmune hypoglycaemia: A narrative review from the laboratory perspective. *J Lab Precis Med*. 2021;6:1-8. <https://doi.org/10.21037/jlpm-20-111>
13. Willard DL, Stevenson M, Steenkamp D. Type B insulin resistance syndrome. *Curr Opin Endocrinol Diabetes Obes*. 2016;23(4):318-23. <https://doi.org/10.1097/MED.0000000000000263> PMID:27254267
14. Ernste FC, Reed AM. Idiopathic inflammatory myopathies: Current trends in pathogenesis, clinical features, and up-to-date treatment recommendations. *Mayo Clin Proc*. 2013;88(1):83-105. <https://doi.org/10.1016/j.mayocp.2012.10.017> PMID:23274022
15. Song GG, Lee YH. Circulating prolactin level in systemic lupus erythematosus and its correlation with disease activity: A meta-analysis. *Lupus*. 2017;26(12):1260-8. <https://doi.org/10.1177/0961203317693094> PMID:28420051
16. Censi S, Mian C, Betterle C. Insulin autoimmune syndrome: from diagnosis to clinical management. *Ann Transl Med*. 2018;6(17):335. <https://doi.org/10.21037/atm.2018.07.32> PMID:30306074 PMCid:PMC6174196
17. Willard D, Upadhyay J, Kim C, Steenkamp D. Diabetic ketoacidosis without diabetes. *J Clin Endocrinol Metab*. 2016;101(11):3870-3. <https://doi.org/10.1210/jc.2016-2146> PMID:27636019
18. Ismail AAA. The insulin autoimmune syndrome (IAS) as a cause of hypoglycaemia: An update on the pathophysiology, biochemical investigations and diagnosis. *Clin Chem Lab Med*. 2016;54(11):1715-24. <https://doi.org/10.1515/cclm-2015-1255> PMID:27071154
19. Dalakas MC. Inflammatory muscle diseases. *N Engl J Med*. 2015;372(18):1734-47. <https://doi.org/10.1056/NEJMra1402225> PMID:25923553