

1-3-2023

## Robotically Assisted Mitral Valve Repair—Port-Only Totally Endoscopic Approach

Kellen J. Round

Colin C. Yost

Jake L. Rosen

Jenna L. Mandel

Meagan Wu

*See next page for additional authors*

Follow this and additional works at: <https://jdc.jefferson.edu/surgeryfp>



Part of the [Cardiology Commons](#), and the [Surgery Commons](#)

**[Let us know how access to this document benefits you](#)**

---

This Article is brought to you for free and open access by the Jefferson Digital Commons. The Jefferson Digital Commons is a service of Thomas Jefferson University's [Center for Teaching and Learning \(CTL\)](#). The Commons is a showcase for Jefferson books and journals, peer-reviewed scholarly publications, unique historical collections from the University archives, and teaching tools. The Jefferson Digital Commons allows researchers and interested readers anywhere in the world to learn about and keep up to date with Jefferson scholarship. This article has been accepted for inclusion in Department of Surgery Faculty Papers by an authorized administrator of the Jefferson Digital Commons. For more information, please contact: [JeffersonDigitalCommons@jefferson.edu](mailto:JeffersonDigitalCommons@jefferson.edu).

---

**Authors**

Kellen J. Round, Colin C. Yost, Jake L. Rosen, Jenna L. Mandel, Megan Wu, Luke C. Olson, Jordan E. Goldhammer, and T. Sloane Guy



# Robotically assisted mitral valve repair—port-only totally endoscopic approach

Kellen J. Round<sup>1^</sup>, Colin C. Yost<sup>1</sup>, Jake L. Rosen<sup>1</sup>, Jenna L. Mandel<sup>1</sup>, Meagan Wu<sup>1</sup>, Luke C. Olson<sup>2</sup>, Jordan E. Goldhammer<sup>2</sup>, T. Sloane Guy<sup>3^</sup>

<sup>1</sup>Sidney Kimmel Medical College, Thomas Jefferson University, Philadelphia, PA, USA; <sup>2</sup>Division of Cardiothoracic Anesthesiology, Department of Anesthesia, Thomas Jefferson University, Philadelphia, PA, USA; <sup>3</sup>Division of Cardiac Surgery, Department of Surgery, Thomas Jefferson University, Philadelphia, PA, USA

Correspondence to: T. Sloane Guy, MD, MBA. Professor of Surgery, Director, Minimally Invasive & Robotic Cardiac Surgery, 1025 Walnut Street, Suite 607, Philadelphia, PA 19107, USA. Email: sloane.guy@jefferson.edu.

**Abstract:** Robotic mitral valve repair (MVR) is an emerging option to treat degenerative valve disease. Compared to open thoracotomy, robotic mitral valve surgery has been shown to afford decreased postoperative length of stay with comparable rates of mortality and morbidity. Among the variety of techniques for robotic MVR, the totally endoscopic approach remains the least invasive method to date. In this report, we describe our technique for totally endoscopic robotically-assisted MVR. In particular, we seek to highlight the use of several unique techniques in MVR. Percutaneous cannulation with use of the endoballoon is employed for cardiopulmonary bypass (CPB), thus avoiding traditional aortic cross-clamping. Moreover, intercostal nerve cryoanesthesia is performed from T3–T9 to reduce post-operative pain and aid in reducing opioid management. Barbed, nonabsorbable sutures are used throughout the procedure (for left atrial appendage closure, mitral valve annuloplasty band placement, left atrial closure, pericardial re-approximation), eliminating the need for knot-tying at several steps. We also detail the installation of two sets of neochords for mitral regurgitation and the fastening of the mitral annuloplasty band. Finally, we would like to highlight the small size of each port used in the case (eight millimeters maximum diameter). Taken together, these features of the robotic platform make it notable for its minimally invasive approach to MVR.

**Keywords:** Robotic cardiac surgery; mitral valve repair (MVR); totally endoscopic approach; percutaneous cardiopulmonary bypass (percutaneous CPB)

Received: 01 August 2022; Accepted: 22 November 2022; Published online: 03 January 2023.

doi: 10.21037/jovs-22-36

View this article at: <https://dx.doi.org/10.21037/jovs-22-36>

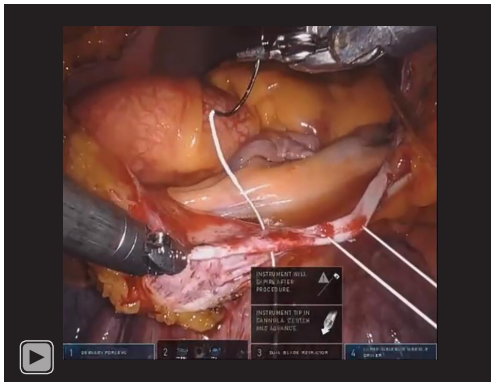
## Introduction

For patients with degenerative mitral valve disease, mitral valve repair (MVR) is often indicated. In recent decades, the approach to MVR has evolved substantially, growing from the traditional sternotomy approach to include numerous less invasive techniques (1). Among them include minimally invasive MVR, which often requires an open thoracotomy. Moreover, robot-assisted MVR typically refers to the use of a robot system to assist in MVR through a mini-

thoracotomy. Finally, totally endoscopic robotic mitral valve repair (teMVR) remains the least invasive of the several approaches to MVR.

Among its chief benefits, teMVR demonstrates comparable operative mortality and morbidity with shorter postoperative length of stay when compared to open thoracotomy (2,3). Additionally, teMVR allows better visualization of the mitral valve than minimally invasive approaches using mini-thoracotomy (4). Moreover, the approach seems to be cost-

<sup>^</sup> ORCID: Kellen J. Round, 0000-0002-9850-8560; T. Sloane Guy, 0000-0002-9250-4403.



**Video 1** Port-only, totally endoscopic approach to robotic mitral valve repair.

neutral compared to open sternotomy (5). Despite these benefits, there appears to be a learning curve early in the implementation of a robotic program as measured by longer cardiopulmonary bypass (CPB) and aortic cross-clamp times (6). As such, case volume is essential for success of teMVR to successfully navigate the learning curve (7). Here we describe the approach to teMVR, an evolving option for the management of degenerative mitral valve disease and mitral regurgitation (*Video 1*).

## Surgical techniques

### Anesthesia

With the patient supine, a dual-lumen endotracheal tube was placed for intubation with the right chest elevated to 15°. The cardiothoracic anesthesia team placed bilateral upper extremity arterial monitoring lines and a single-lumen internal jugular central line for later use during bicaval cannulation. All procedures performed in this study were in accordance with the ethical standards of the institutional and/or national research committee(s) and with the Helsinki Declaration (as revised in 2013). Written informed consent was obtained from the patient for publication of this manuscript and the accompanying video. A copy of the written consent is available for review by the editorial office of this journal.

### Prepping and draping

The patient was positioned in reverse Trendelenburg and surgical preparation of the patient's neck, chest, abdomen, and pelvis was performed in the usual sterile fashion.

### Post placement

In preparing the patient for the robotic console, an eight-millimeter robotic camera port was placed in the right 4<sup>th</sup> or 5<sup>th</sup> intercostal space just anterior to the anterior axillary line. The importance of the specific space is secondary to the importance of centering the camera port between the sternal notch and xyphoid process. Four additional eight-millimeter ports were placed: a robotic right arm port (7<sup>th</sup> intercostal space at anterior axillary line), left arm port (3<sup>rd</sup> intercostal space just anterior to anterior axillary line), atrial retractor port (5<sup>th</sup> intercostal space just medial to midclavicular line), and air-seal working port (5<sup>th</sup> intercostal space at anterior axillary line). In addition to the robotic ports, the right lateral chest wall was prepped with three 14-gauge long angiocatheters for future use in exteriorizing retraction sutures. Finally, a 12-French peel-away sheath was used to place a 12-French cardiac sump drain via Seldinger technique.

### Cannulation

To prepare for percutaneous CPB, the femoral vein was dilated to accommodate a 26-French femoral venous cannula which was inserted percutaneously with the tip in the superior vena cava. Similarly, a 23-French Edwards EndoReturn arterial cannula (Edwards Lifesciences, Irvine, CA, USA) was placed percutaneously. Next, the endoballoon was placed in the arterial cannula side port while the superior vena cava was cannulated with a 19-French drainage catheter via the right internal jugular vein for connection to the venous side of the bypass circuit.

### Intercostal cryoablation and pericardiectomy

With the surgeon at the console, a GORE-TEX CV-2 figure of eight suture (Gore Medical, Flagstaff, AZ, USA) was used to tent up the tendon of the right hemidiaphragm to minimize injury to the liver and to provide better exposure. Cryoablation was performed from T3–T9 of the right chest intercostal nerves staying greater than five centimeters from the spine for two minutes each at –60 °C to offer the potential for reduced post-operative pain. At our institution, there have been a small number of cases in which patients experienced transient bulging of the right upper quadrant abdominal musculature as a result of cryoanesthesia at approximately 3–6 months postoperatively (which aligns with nerve regeneration).

The right lateral surface of the pericardium was incised, with special attention paid to avoid phrenic nerve injury. After the pericardium was opened, two pericardial retraction sutures were placed through the lateral edge of the pericardiectomy site and exteriorized through the 14-gauge angiocatheters.

#### *CPB initiation and arrest with the endoballoon*

CPB was initiated and the heart was arrested with the endoballoon. Due to its ability to facilitate an entirely transcatheter approach to CPB, the endoballoon is preferable to traditional aortic cross-clamping in teMVR. However, several considerations should be assessed before its use. We do not use the endoballoon in patients with moderate to severe aortic regurgitation, grade four or five atheroma of the descending aorta, or insufficient femoral artery diameter. Preoperative imaging required for use of the endoballoon include coronary angiogram, transthoracic/transesophageal echocardiography, and computed tomography angiography (CTA) of the chest/abdomen/pelvis. CTA allows for identification of aortic disease, aberrations of major arteries and veins, and diameter measurement of the ascending aorta. Ascending aorta diameters greater than 42 millimeters should be considered for cross-clamping due to the risk of incomplete occlusion or improper cardioplegia delivery. Finally, a mean arterial pressure between 60–90 mmHg is maintained while using the endoballoon.

#### *Induction of cardioplegia, atriotomy, and left atrial appendage closure*

Antegrade cardioplegia was delivered at a rate to avoid distal migration of the endoballoon by keeping the aortic root pressure less than the systemic pressure. Once arrest was achieved, a left atriotomy was performed at Waterston's groove. A suture was then placed into the posterior left atrium just superior to the P2/3 segment of the mitral valve to increase valve exposure. Subsequently, the left atrial appendage was closed with a double-layer, 3-0 V-Loc suture (Medtronic, Minneapolis, MN, USA).

#### *MVR*

Static testing of the mitral valve confirmed the prominent prolapse of the P2 mitral leaflet segment. Two sets of neochords were placed to address mitral regurgitation: one from the anterolateral papillary muscle to the left-sided P2

and one from the right posterior medial papillary muscle to the right-sided P2 segment. After adjustment under static testing, these were tied with ten knots.

The mitral valve was then sized to a 34-millimeter SimuPlus flexible annuloplasty band (Medtronic, Minneapolis, MN, USA). True sizing rather than downsizing is performed in cases of mitral prolapse. However, the decision is made on a case-by-case basis with the overall goal of avoiding systolic anterior motion. The band was placed with two 3-0 V-Loc™ sutures in a running horizontal mattress fashion. Each suture was started at the trigones, meeting in the middle of P2. Furthermore, an everting, pledgeted 2-0 Ethibond Excel polyester suture (Ethicon Inc., Raritan, NJ, USA) was used to reinforce the band and was secured to the annuloplasty ring with a Cor-Knot device (LSI Solutions, Victor, NY, USA). A cleft closure between P2 and P3 was performed. Afterwards, static testing revealed a competent valve. At this point, the left atriotomy was closed with two 3-0 V-Loc™ sutures with each starting at the side and meeting in the middle of the incision. Afterwards, the heart was de-aired. On the robotic platform with a totally-endoscopic approach, it should be noted that insufflation occurs in a near-complete CO<sub>2</sub> environment, which should be protective of stroke. Moreover, positioning patients in reverse Trendelenburg elevates the ascending aorta in relation to the rest of the heart. As the atrium was closed, the aorta was passively de-aired. A vent was placed in the left apex and left until no air remained. It was at this point that the endoballoon was deflated and a right ventricular pacing wire was placed and exteriorized through the left atrial retractor port. After hemostasis of the left atriotomy was confirmed, the pericardium was loosely reapproximated with one 3-0 V-Loc™ suture. When performing a loose pericardial reapproximation, which is used to create a well-identifiable landmark in the case that re-operation is required, it is crucial to avoid phrenic nerve injury.

#### *Decannulation and completion*

With the surgeon at the bedside, decannulation was initiated. A Bentson wire was placed in the right common femoral artery across the arterial cannula. The cannula was removed over the wire with manual pressure while protamine was given. The rationale for removing the arterial cannula during the administration of protamine versus after complete heparin reversal reflects an effort to avoid ischemia or potential clot in the leg. Leaving the

wire inserted allows the cannula to be re-inserted should a protamine reaction occur. The two ProGlide devices (Abbott Laboratories, Chicago, IL, USA) were tightened and an eight-French AngioSeal (Terumo Corporation, Tokyo, Japan) was used to further ensure hemostasis. The venous cannula was then removed and the ProGlides™ were cut. The 19-French superior vena cava drainage catheter was removed, and the insertion site was tightened with a Rumel. The chest tube sites were closed with 4-0 V-Loc™ sutures and a 24 French Ethicon BLAKE silicone drain (Ethicon Inc., Raritan, NJ, USA) was inserted at the end of the procedure. The five port sites and two groin puncture sites were closed in standard fashion.

## Comments

The robotic approach to MVR demonstrates similar morbidity and mortality with shorter in-hospital length of stay when compared to open sternotomy (2,3). At our institution, five eight-millimeter robotic arm ports are used to facilitate teMVR. This approach, to our knowledge, remains the least invasive approach to teMVR in the world. As such, patients with an uncomplicated postoperative course are regularly discharged on postoperative day one or two.

There are some eligibility considerations for who should undergo teMVR. Generally, patients with deep chest cavities and long aortic roots are preferable. Patients with a larger body habitus require a larger diameter cannula for percutaneous cannulation, so lack of adequate femoral or axillary arterial access can prevent the option of percutaneous cannulation. At our center, we have successfully performed re-do mitral valve operations using the robotic approach and endoballoon (which does not require exposure of the ascending aorta for placement of an antegrade cardioplegia needle). However, in the case of extensive adhesions preventing adequate maneuvering of the robotic instrumentation within the thoracic cavity, the case must be converted to an open sternotomy approach.

In addition to the quality-of-life improvements conferred by a shorter length of hospital stay (3), several other benefits to teMVR express potential to improve patient outcomes. The small port size in the absence of rib-splitting, combined with cryoablation to the intercostal nerves, helps reduce pain postoperatively and improve forced expiratory volume in the first second (FEV1) recovery (8). This further supports an effort to reduce post-operative narcotic requirements.

A criticism of the robotic approach is the prolonged operative time compared to open sternotomy. Our approach

utilizes V-loc™ sutures; the use of V-loc™ at various procedural steps eliminates the need for knot tying, allowing the potential to improve intraoperative efficiency as seen in many other noncardiac subspecialties (9,10). Finally, percutaneous CPB avoids the higher rate of post-operative groin complications associated with open cutdown (11).

The primary pitfalls to teMVR are the large initial equipment and training cost to initiate a robotic program and the team-based learning curve (6,12). Individual patient anatomy may also preclude some patients as eligible candidates for the robotic repair. Moreover, there are a number of intraoperative challenges which surgeons may encounter when employing a totally-endoscopic approach. Right chest wall access likely increases the incidence of liver injury compared to traditional open sternotomy approaches. It is important to alert the post-operative care team for signs of potential liver injury, as many do not naturally associate liver injury with cardiac procedures. Lung injury also may occur, especially on re-ventilation. Finally, chest wall bleeding is a potential complication. In this case, it is important to recognize the signs of a chest wall bleed early to ensure proper blood products can be provided and any alternative access can be established.

Despite these drawbacks, the totally endoscopic approach to teMVR presents an exciting opportunity to continue to advance the treatment of degenerative mitral valve disease. As popularity grows and more surgeons utilize the robotic approach to cardiac surgery, it is our hope that teMVR becomes a more readily available option for patients.

## Acknowledgments

*Funding:* None.

## Footnote

*Provenance and Peer Review:* This article was commissioned by the Guest Editor (Johannes Bonatti) for the series “Robotic Mitral Valve Repair” published in *Journal of Visualized Surgery*. The article has undergone external peer review.

*Peer Review File:* Available at <https://jovs.amegroups.com/article/view/10.21037/jovs-22-36/prf>

*Conflicts of Interest:* All authors have completed the ICMJE uniform disclosure form (available at <https://jovs.amegroups.com/article/view/10.21037/jovs-22-36>)

36/coif). The series “Robotic Mitral Valve Repair” was commissioned by the editorial office without any funding or sponsorship. TSG reports that he is a consultant for Edwards Lifesciences, Medtronic, and a case observation site and proctor for Intuitive Surgical. The authors have no other conflicts of interest to declare.

*Ethical Statement:* The authors are accountable for all aspects of the work in ensuring that questions related to the accuracy or integrity of any part of the work are appropriately investigated and resolved. All procedures performed in this study were in accordance with the ethical standards of the institutional and/or national research committee(s) and with the Helsinki Declaration (as revised in 2013). Written informed consent was obtained from the patient for publication of this manuscript and the accompanying video. A copy of the written consent is available for review by the editorial office of this journal.

*Open Access Statement:* This is an Open Access article distributed in accordance with the Creative Commons Attribution-NonCommercial-NoDerivs 4.0 International License (CC BY-NC-ND 4.0), which permits the non-commercial replication and distribution of the article with the strict proviso that no changes or edits are made and the original work is properly cited (including links to both the formal publication through the relevant DOI and the license). See: <https://creativecommons.org/licenses/by-nc-nd/4.0/>.

## References

1. Marin Cuartas M, Javadikasgari H, Pfannmueller B, et al. Mitral valve repair: Robotic and other minimally invasive approaches. *Prog Cardiovasc Dis* 2017;60:394-404.
2. Bonatti J, Crailsheim I, Grabenwöger M, et al. Minimally Invasive and Robotic Mitral Valve Surgery: Methods and Outcomes in a 20-Year Review. *Innovations (Phila)* 2021;16:317-26.
3. Bush B, Nifong LW, Alwair H, et al. Robotic mitral valve surgery-current status and future directions. *Ann Cardiothorac Surg* 2013;2:814-7.
4. Tarui T, Ishikawa N, Horikawa T, et al. First Major Clinical Outcomes of Totally Endoscopic Robotic Mitral Valve Repair in Japan - A Single-Center Experience. *Circ J* 2019;83:1668-73.
5. Cohan G, Wei LM, Althouse A, et al. Robotic mitral valve operations by experienced surgeons are cost-neutral and durable at 1 year. *J Thorac Cardiovasc Surg* 2018;156:1040-7.
6. Toolan C, Palmer K, Al-Rawi O, et al. Robotic mitral valve surgery: a review and tips for safely negotiating the learning curve. *J Thorac Dis* 2021;13:1971-81.
7. Güllü AÜ, Senay S, Kocyigit M, et al. An analysis of the learning curve for robotic-assisted mitral valve repair. *J Card Surg* 2021;36:624-8.
8. Lau WC, Shannon FL, Bolling SF, et al. Intercostal Cryo Nerve Block in Minimally Invasive Cardiac Surgery: The Prospective Randomized FROST Trial. *Pain Ther* 2021;10:1579-92.
9. Krishnamoorthy B, Shepherd N, Critchley WR, et al. A randomized study comparing traditional monofilament knotted sutures with barbed knotless sutures for donor leg wound closure in coronary artery bypass surgery. *Interact Cardiovasc Thorac Surg* 2016;22:161-7.
10. Han Y, Yang W, Pan J, et al. The efficacy and safety of knotless barbed sutures in total joint arthroplasty: a meta-analysis of randomized-controlled trials. *Arch Orthop Trauma Surg* 2018;138:1335-45.
11. Moschovas A, Amorim PA, Nold M, et al. Percutaneous cannulation for cardiopulmonary bypass in minimally invasive surgery is associated with reduced groin complications. *Interact Cardiovasc Thorac Surg* 2017;25:377-83.
12. Moss E, Halkos ME. Cost effectiveness of robotic mitral valve surgery. *Ann Cardiothorac Surg* 2017;6:33-7.

doi: 10.21037/jovs-22-36

**Cite this article as:** Round KJ, Yost CC, Rosen JL, Mandel JL, Wu M, Olson LC, Goldhammer JE, Guy TS. Robotically assisted mitral valve repair—port-only totally endoscopic approach. *J Vis Surg* 2023;9:12.