



Case Report

Isolated subdural hematoma due to dengue hemorrhagic fever: Surgical intervention and review of the literature

Mohammad Ashraf¹ , Syed Shahzad Hussain², Minaam Farooq³ , Laveeza Fatima⁴, Nadia Majeed⁵, Naveed Ashraf²

¹Wolfson School of Medicine, University of Glasgow, Scotland, United Kingdom, ²Department of Neurosurgery, National Hospital and Medical Centre, ³School of Medicine, King Edward Medical University, Lahore, Punjab, Pakistan, ⁴School of Medicine, Allama Iqbal Medical College, Lahore, Punjab, Pakistan, ⁵Department of Infectious Diseases, National Hospital and Medical Centre, Lahore, Punjab, Pakistan.

E-mail: *Mohammad Ashraf - mohammad_5676@hotmail.com; Syed Shahzad Hussain - drshahzadns@yahoo.com; Minaam Farooq - minaamkemu2018@gmail.com; Laveeza Fatima - laveezaghafoor2002@gmail.com; Nadia Majeed - dr.nadyamajeed@gmail.com; Naveed Ashraf - drnashraf@yahoo.com



*Corresponding author:

Mohammad Ashraf,
Wolfson School of Medicine,
University of Glasgow, Scotland,
United Kingdom.

mohammad_5676@hotmail.com

Received : 09 April 2022

Accepted : 18 May 2022

Published : 10 June 2022

DOI

10.25259/SNI_334_2022

Quick Response Code:



ABSTRACT

Background: Central nervous system (CNS) complications of dengue fever, a mosquito-borne single standard RNA virus illness, are reported in <1% of all cases. Hemorrhagic complications in severe forms of the disease can be life-threatening. The literature on cases, where hemorrhagic CNS complications necessitated neurosurgical intervention, is exceedingly sparse. The authors report their experience of a patient who developed an isolated acute subdural hematoma (SDH) due to dengue hemorrhagic fever (DHF) in the critical period of the illness with a poor prognosis. Despite a moribund patient, the SDH was immediately evacuated, achieving a good outcome.

Case Description: A 65-year-old male patient was admitted with high-grade febrile illness and diagnosed with dengue. The patient had no focal neurology and was managed adequately following the primary survey on admission but, then, developed severe thrombocytopenia and eventually the critical phase of dengue illness. On the 5th admission day, the patient collapsed. Glasgow Coma Score was 3/15 with bilaterally dilated, fixed pupils. Immediate computed tomography head revealed a large left SDH with a significant midline shift. SDH was emergently evacuated with two units of platelets transfused peroperatively and two additional units postoperatively. Thrombocytopenia resolved within 48 h, and interval scanning showed gradual resolution of SDH. The patient was discharged 18 days later. Five months later, on follow-up, the patient is well with mild left-sided weakness and an Extended Glasgow Outcome Score of 7.

Conclusion: Isolated SDH is a rare but life-threatening hemorrhagic complication of DHF. Even in the critical phase of illness, with severe thrombocytopenia, surgical evacuation should be considered if the SDH is present in isolation, within an accessible area, and can be operated on immediately.

Keywords: Dengue, Dengue hemorrhagic fever, Dengue shock syndrome, Neurological complication, Subdural hematoma

INTRODUCTION

Dengue is a single-stranded RNA viral infection transmitted by the bite of *Aedes aegypti* or *albopictus* mosquitoes.^[3] Infection with one of four strains (DENV1 to 4) leads to lifelong immunity against that particular strain.^[13] Pakistan is one typical developing country with numerous risk factors that facilitate the growth of the dengue carrying mosquitoes and hence the spread of the virus. Thus, dengue has become a regular endemic in Pakistan.^[3] With all four strains now documented, cases peak nationally between July and October due to the

This is an open-access article distributed under the terms of the Creative Commons Attribution-Non Commercial-Share Alike 4.0 License, which allows others to remix, transform, and build upon the work non-commercially, as long as the author is credited and the new creations are licensed under the identical terms.

©2022 Published by Scientific Scholar on behalf of Surgical Neurology International

monsoon season facilitating the reproduction of the *Aedes* mosquitoes.^[3] In most cases, the illness has a mild course. Management is supportive, which has significantly reduced mortality, but individuals who are reinfected with a different serotype may go on to develop severe forms of dengue.^[4] This includes dengue hemorrhagic fever (DHF) or dengue shock syndrome (DSS).^[1,4,13] DHF leads to a severe increase in vascular permeability, hemorrhage, and shock with multisystem failure, which is life-threatening and carries mortality as high as 44% if untreated.^[1,4]

Neurological or central nervous system (CNS) involvement/ complications of dengue are exceedingly rare, with a reported incidence of <1%.^[15] Naturally, this means very little guidance about how these patients are to be managed should a complication requiring neurosurgical intervention occur. Subdural hematomas (SDHs) are among the most common neurosurgical entities that may be managed conservatively or surgically depending on injury severity. Reports on SDH occurring due to DHF or DSS are sparse; therefore, optimal management is uncertain. We report a case of a DHF patient who presented with a short febrile illness and developed an acute SDH secondary to dengue illness, which was surgically evacuated. A literature review is provided.

CASE PRESENTATION

A 65-year-old male presented to the emergency department on the night of October 19 reporting high-grade fever and body aches for 3 days. The patient acutely developed dizziness and abdominal pain and complained of a new-onset headache. On arrival, he was hypotensive, tachycardic, with a temperature of 39.8°C, and oliguric. His Glasgow Coma Score (GCS) was 15/15, and examination revealed no focal neurology. Dengue fever was suspected, and an ultrasound revealed pericholecystic edema and free fluid in the patient's abdomen. The patient was managed adequately with fluid resuscitation, admitted for observation, and managed according to our national guidelines by the Punjab Dengue Expert Advisory Group.^[2,8]

Dengue test revealed

1. Soluble nonstructural protein 1 (test method – dengue NS 1 Antigen, detection window day 1–5)
2. Dengue viral RNA (test method – dengue real-time polymerase chain reaction, detection window day 1–5)
3. Dengue IgM antibodies indicating an acute or recent infection
4. Dengue IgG in high levels indicating a secondary infection.

The patient was clinically stable over the next 3 days but developed a sharp progressive decline in his platelet count

and eventually severe thrombocytopenia. Changes in platelet counts and deterioration of important biochemical parameters are summarized in Figures 1 and 2. In the early hours of October 24, a blood count revealed platelet count of 26 units= $\times 10^9/l$ (reference range 150–400). The following morning after breakfast, the patient suddenly collapsed, and his GCS dropped to 3/15 with bilaterally fixed and dilated pupils. He was shifted to the intensive care unit, intubated, and put on mechanical ventilation with supportive management. Computed tomography (CT) head revealed a large acute left parietal SDH with significant mass effect and midline shift [Figure 3]. The patient's attendants were thoroughly counseled and opted for surgical intervention. An emergent SDH evacuation was performed with a left parietal craniotomy. Peroperatively, two units of platelets were transfused, and the hematoma was evacuated without complication. Postoperatively, two additional units of platelets were transfused to maintain a platelet count of above 50. Same day CT scan showed a marked decrease in the midline shift and air in the evacuated hematoma cavity. Over the next few days, his platelets gradually rose to the normal range [Figure 1].

The patient developed signs of a chest infection on October 28 and was diagnosed with ventilator-associated pneumonia, for which he was treated. Compared to the previous interval scans, his final CT scan performed on November 3 showed complete resolution of the subdural hemorrhage and midline shift and resorption of residual air [Figure 4]. He was discharged on November 11. The patient remained in our follow-up, and at his last clinic visit in April 2022, he felt well with minor left-sided weakness. His Extended Glasgow Outcome Score was deemed to be 7.

DISCUSSION

Whether dengue fever will be asymptomatic or manifest as a mild infection or severe disease is determined by a complex interaction of the hosts' immune system to the virus. The immunological basis of DHF and DSS is secondary infection with a different serotype with an antibody-dependent enhancement of the dengue virus infection, whereby nonprotective antibodies against the virus bind to the Fc receptor of immune cells.^[13] Other contributing mechanisms include monocyte activation and cytokine production, serotype cross-reactivity mediated T-cell response, and cytokine production from dengue virus-specific T-cells, all of which may lead to increased vascular permeability, capillary fragility, and thrombocytopenia.^[13]

Cases reporting neurological complications from dengue are sparse. The previous case reports include an isolated fatal subarachnoid hemorrhage (postmortem confirming no previous intracranial arterial aneurysms) or isolated

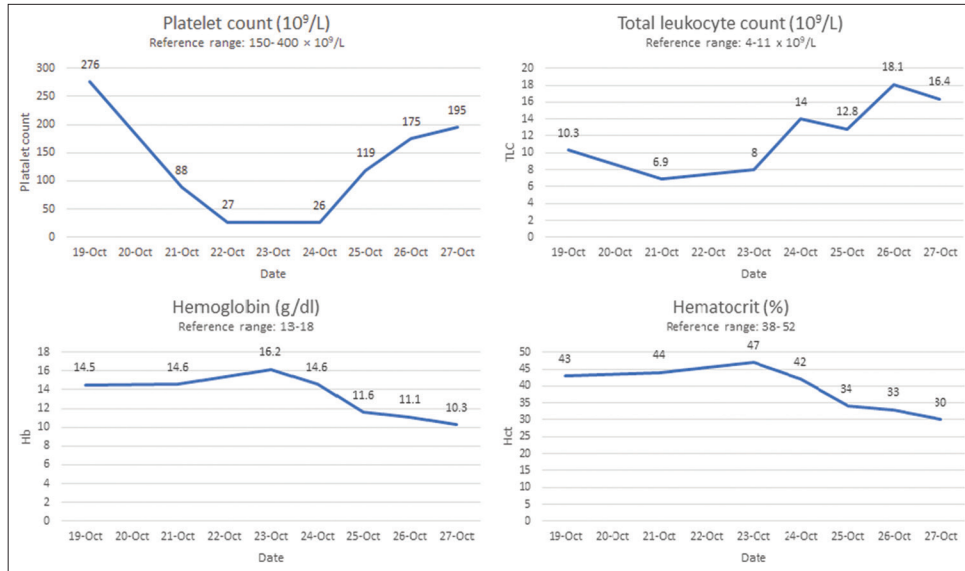


Figure 1: Changes in the patient’s full blood count parameters of platelets of total white cell count, hemoglobin, and hematocrit from his 3rd fever day (1st day of admission), during his subdural hematoma development and surgical evacuation (October 24), and subsequent recovery of platelets.

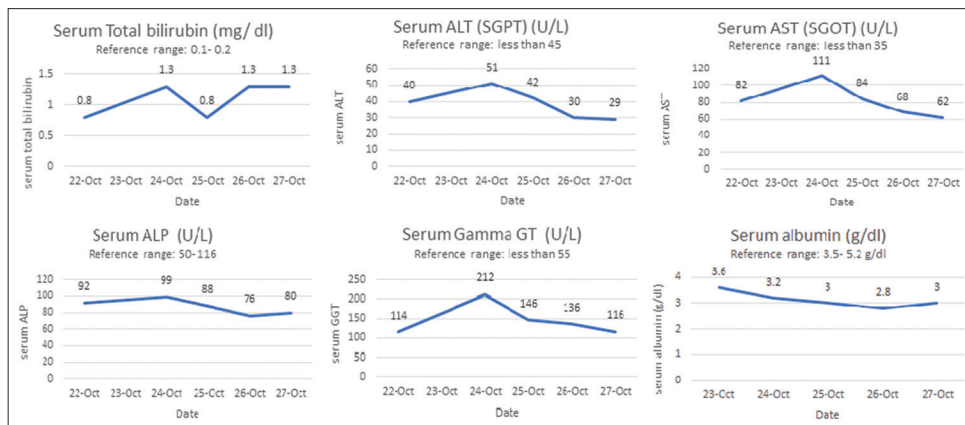


Figure 2: Changes and derangement of the patient’s liver function tests after his dengue test came back positive.

SDHs.^[5,7] A single patient has also been reported to develop multiple diffuse cerebral hemorrhages, SDH, cranial diabetes insipidus, and subsequent subarachnoid hemorrhages followed by brainstem herniation and death.^[6] In addition, bilateral SDHs and pure motor quadriplegia from axonal polyneuropathy have also been documented.^[12] A case, where surgical interventions were made, includes a pediatric patient with SDH and subfalcine and transtentorial herniation.^[9] Cases with further unusual complications reported include a delayed SDH post dengue after 2 months and a spontaneous SDH of the dorsal spine managed successfully surgically.^[10,11] The summary of cases where neurological complications from dengue occurred, the type of complication, management strategy, and outcome is summarized in Table 1.

According to the literature, the critical phase of dengue is characterized by the abatement of temperature, which reduces from a high-grade fever to approximately 37.5–38°C and is seen on days 3 to 7 of the illness.^[14] This critical phase is characterized by a rapid decrease in platelet count, changes in hematocrit and leukopenia (which may occur 24 h before the decrease in platelets), in which DHF and DSS result in plasma leakage and bleeding due to capillary fragility.^[14] All of these findings were consistent with our patient’s case. Intracranial hemorrhage is exceedingly uncommon relative to other hemorrhagic complications of dengue. Among intracranial hemorrhages, parenchymal hemorrhages are more common than isolated SDHs.^[9] In addition to the streamlined supportive intensive care guidelines for dengue fever, DHF, and DSS,^[2,8] there should be a strong

Table 1: Summary of dengue cases reporting neurological complications.

Author	Age (years)/gender	Reported neurological complications from dengue	Intervention	Outcome
Jensenius <i>et al.</i> ^[7]	30/Female	• Subarachnoid hemorrhage	Conservative	Death
Jain <i>et al.</i> ^[5]	22/Male	• Subdural hemorrhage	Conservative	Death
Jayasinghe <i>et al.</i> ^[6]	24/Female	• Cerebral hemorrhages • Subdural hematoma • Subarachnoid hemorrhage	Conservative	Death
Mittal and Jain ^[12]	27/Male	• Cranial diabetes insipidus • Brainstem herniation • Bilateral subdural hematoma	Conservative	Death
Kumar <i>et al.</i> ^[9]	9/Male	• Pure motor quadriplegia • Severe headache, vomiting, and generalized seizure • Large frontotemporal subdural hemorrhage	Surgical	Recovered
Mahale <i>et al.</i> ^[10]	21/Male	• Subfalcine and transtentorial herniation • Subdural hemorrhage	Conservative	Recovered
Maheshwari <i>et al.</i> ^[11]	54/Female	• Spinal subdural hematoma	Laminectomy	Recovered

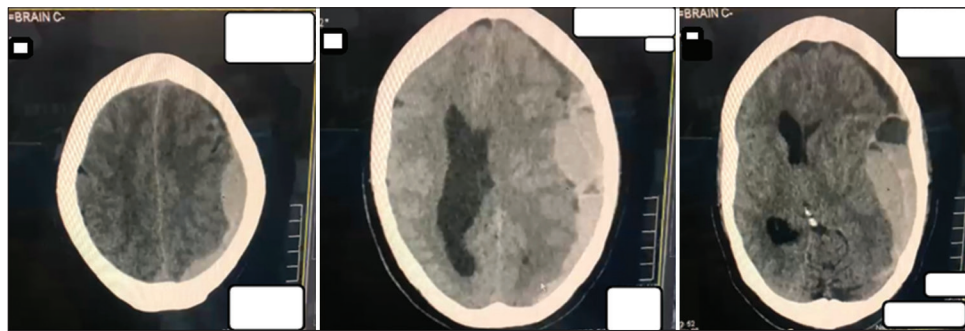


Figure 3: Axial cuts of patient’s preoperative noncontrast CT scan in the morning October 24, showing extensive left subdural hematoma with significant midline shift, ipsilateral ventricular obliteration, contralateral ventricular dilation.

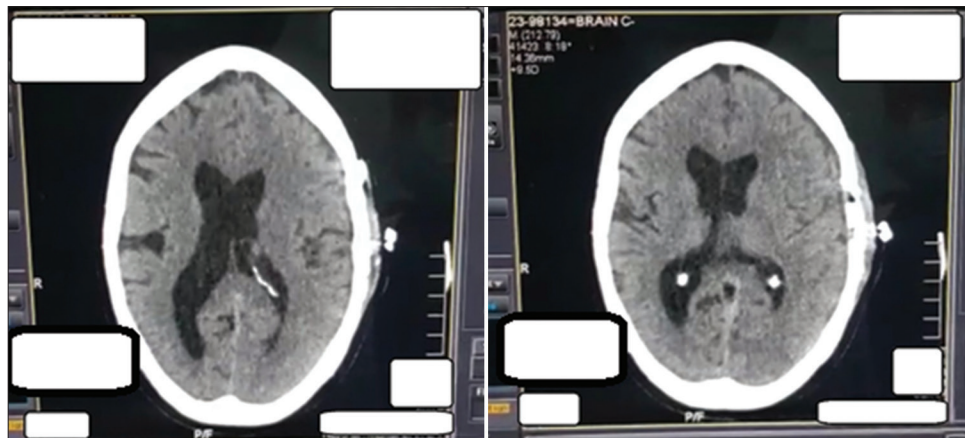


Figure 4: Final CT scan, taken on November 3, confirming complete resolution of subdural hemorrhage and absorption of air.

suspicion of CNS hemorrhage if neurological symptoms develop as this can be fatal. An urgent neurosurgical review should be sought, and neurosurgical intervention should be considered. Some authors did not attempt surgical intervention in the case of isolated SDH during the critical phase of dengue, with severe thrombocytopenia and low

GCSs close to ours, and the outcome was death. Even in the critical phase of dengue, we advocate considering surgical evacuation with concurrent platelet transfusion to be lifesaving. This may prevent mortality if the SDH is present in isolation, in an accessible area, and can be operated on immediately.

CONCLUSION

Severe forms of dengue illness are common in areas, where the virus is an endemic or epidemic. Hemorrhagic complications greatly increase mortality, and while neurological complications, including CNS hemorrhage, are very rare, they can be fatal. There should be a high clinical suspicion of intracranial hemorrhage when neurological complications manifest, and urgent neurosurgical review should be sought. Timely, surgical intervention in select cases such as ours may change the outcome to a favorable one in this rare but severe complication of dengue.

Declaration of patient consent

The authors certify that they have obtained all appropriate patient consent.

Financial support and sponsorship

Nil.

Conflicts of interest

There are no conflicts of interest.

REFERENCES

- Alejandria MM. Dengue haemorrhagic fever or dengue shock syndrome in children. *BMJ Clin Evid* 2015;2015:0917.
- Dengue Expert Advisory Group Guidelines. Available from: <https://deag.punjab.gov.pk> [Last accessed on 2022 Apr 06].
- Haider Z, Ahmad FZ, Mahmood A, Waseem T, Shafiq I, Raza T, *et al.* Dengue fever in Pakistan: a paradigm shift; changing epidemiology and clinical patterns. *Perspect Public Health* 2015;135:294-8.
- Hasan S, Jamdar SF, Alalowi M, Al Ageel Al Beiji SM. Dengue virus: A global human threat: Review of literature. *J Int Soc Prev Community Dent* 2016;6:1-6.
- Jain N, Gutch M, Kumar V, Naik AK. A fatal combo of dengue shock syndrome with acute subdural hematoma. *Neurol India* 2012;60:105-6.
- Jayasinghe NS, Thalagala E, Wattedgama M, Thirumavalavan K. Dengue fever with diffuse cerebral hemorrhages, subdural hematoma and cranial diabetes insipidus. *BMC Res Notes* 2016;9:265.
- Jensenius M, Berild D, Ormaasen V, Maehlen J, Lindegren G, Falk KI. Fatal subarachnoidal haemorrhage in a Norwegian traveller with dengue virus infection. *Scand J Infect Dis* 2007;39:272.
- Khurram M. Management of adult dengue shock syndrome patients not improving with DEAG guidelines based therapy. *J Rawalpindi Med Coll* 2016;20:2-6.
- Kumar R, Prakash O, Sharma BS. Dengue hemorrhagic fever: A rare presentation as atypical acute subdural hematoma. *Pediatr Neurosurg* 2008;44:490-2.
- Mahale RR, Mehta A, Shankar AK, Srinivasa R. Delayed subdural hematoma after recovery from dengue shock syndrome. *J Neurosci Rural Pract* 2016;7:323-4.
- Maheshwari V, Kumar S, Kumar A, Kumar A. Spontaneous subdural hematoma of dorsal spine secondary to dengue fever: A rare case report with review of literature. *Asian J Neurosurg* 2019;14:550-2.
- Mittal M, Jain N. Subdural haematoma and axonal polyneuropathy complicating dengue fever. *BMJ Case Rep* 2011;2011:bcr1220103672.
- Rothman AL, Ennis FA. Immunopathogenesis of Dengue hemorrhagic fever. *Virology* 1999;257:1-6.
- Schaefer TJ PP, Wolford RW. *Dengue Fever*. Treasure Island, FL: StatPearls Publishing; 2018.
- Solomon T, Dung NM, Vaughn DW, Kneen R, Thao LT, Raengsakulrach B, *et al.* Neurological manifestations of dengue infection. *Lancet* 2000;355:1053-9.

How to cite this article: Ashraf M, Hussain SS, Farooq M, Fatima L, Majeed N, Ashraf N. Isolated subdural hematoma due to dengue hemorrhagic fever: Surgical intervention and review of the literature. *Surg Neurol Int* 2022;13:244.