

## Primary hydatidosis of the tibia: A tricky diagnosis

James Choueiry<sup>1</sup>, Gilbert Maroun<sup>2</sup>, Mark Abou Ghaida<sup>3</sup>, Luke Heinrichs<sup>4</sup>, Edgard Traboulsi<sup>5</sup>, Davide Aliani<sup>6</sup>, Charbel Maroun<sup>7</sup>

<sup>1</sup> Cliniques Universitaires Saint-Luc, Brussels, Belgium

<sup>2</sup> American University of Beirut, Beirut, Lebanon

<sup>3</sup> University of Alberta, Edmonton, Canada

<sup>4</sup> University of Alberta, Edmonton, Canada

<sup>5</sup> Central Military Hospital, Beirut, Lebanon

<sup>6</sup> University of Parma, Parma, Italy

<sup>7</sup> University of Alberta, Edmonton, Canada

---

**Abstract:** Primary hydatidosis of the tibia is a rare disease. In an endemic area, it should be considered in the differential diagnosis of a hypolucent osteolytic lesion on xray. If not properly managed, anaphylactic shock may occur intraoperatively, as well as increased recurrence of the disease. This is a case report of a primary tibial hydatid cyst, treated first with curettage and phenolization, and then after recurrence, treated with total knee arthroplasty. We will review the literature of diagnosis and treatment of a hydatid cyst of the tibia.

**Keywords:** Hydatid cyst; knee arthroplasty; knee tumor

---

### 1. Introduction

Hydatidosis consists mainly of cystic hydatid and alveolar hydatid disease, both are caused by *Echinococcus granulosus* and *Echinococcus multilocularis*, respectively. *Echinococcus granulosus* is a tapeworm cestode and is acquired through a cycle in which the humans are intermediate hosts. Most patients have hydatid cysts of their liver, spleen, and lungs, which are the major filtering organs of these parasites. It is rare for the hydatid cyst to escape these filtering mechanisms and be present primarily in the tibia. When present in the tibia, it is difficult to diagnose radiologically. Therefore, there should be a high level of suspicion in endemic areas, such as Mediterranean region, Central Asia, East Africa, Australia and New Zealand<sup>[1]</sup>. Suspicion of a hydatid cause may prevent recurrence and complications. We studied a 33 year old patient with recurrent hydatid cyst in the tibia, after curettage, treated with total knee arthroplasty.

### 2. Patients and Methods

A 33 year-old female patient presented for right leg pain of five weeks that is present in the day and night, exacerbated by weight bearing. She grades the pain as 6 over 10, relieved with non steroidal anti-inflammatory agents. She is previously healthy without history of trauma. There is mild edema, no redness, mild increase of the pain upon palpation. There was no neurovascular abnormalities. Examination of the back, hip, and knee was normal. X-ray showed a large hypolucent spherical lesion in the proximal third of the tibia (fig 1). MRI on T1 showed the lesion to be hypointense, and on T2 to be hyperintense (fig 2, 3). The lesion showed to be osteolytic, extending anteroposteriorly through the

---

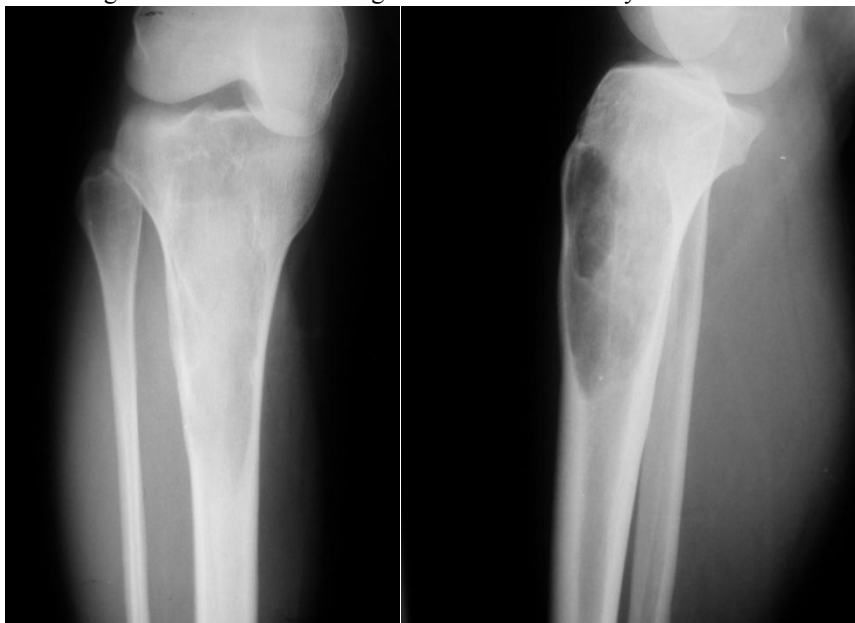Copyright © 2018 James Choueiry *et al.*

doi: 10.18686/aem.v7i1.118

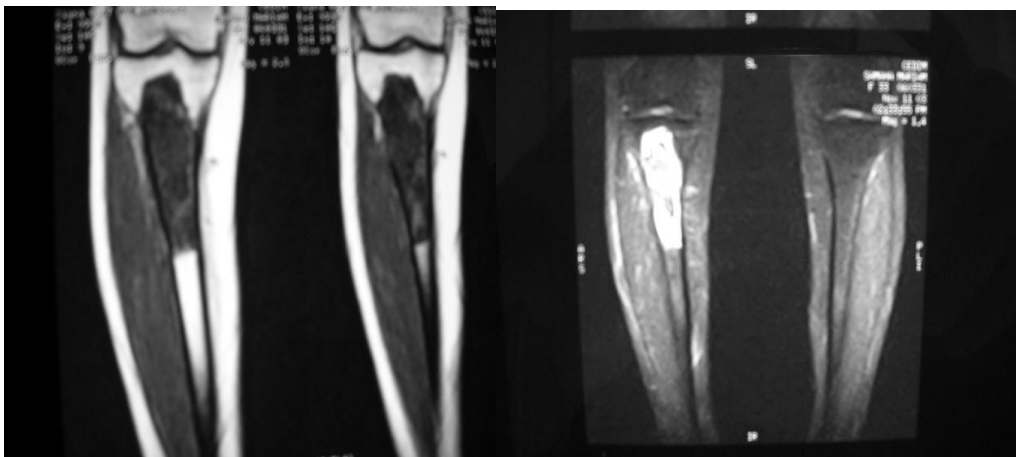
This is an open-access article distributed under the terms of the Creative Commons Attribution Unported License

(<http://creativecommons.org/licenses/by-nc/4.0/>), which permits unrestricted use, distribution, and reproduction in any medium, provided the original work is properly cited.

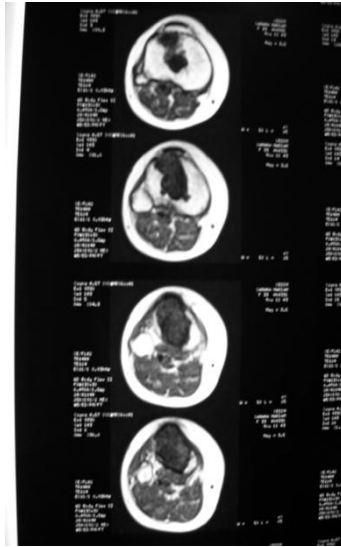
cortex at some levels, but it did not reach the articular surface, nor the surrounding soft tissues. Decision was taken to biopsy it. The pathology report showed lamellated cysts and scattered scoleces. Albendazole was given 400 mg PO twice for 2 months. A second operation was made with extensive curettage, then extensive excision of bone layers with burr, then phenolization and bone grafting of cancellous chips inside the cavity. The patient was free radiologically of the disease for two years, then in the third year, multilocular cysts reappeared on xray (fig 4), with possible extension to the articular surface. A decision of total knee arthroplasty was taken after wide resection of the diseased segment (fig 5). Negative margins were obtained. The patient post operatively was rehabilitated; pain subsided with no radiological signs of recurrence. She was given albendazole 400 mg bid for 3 months orally.



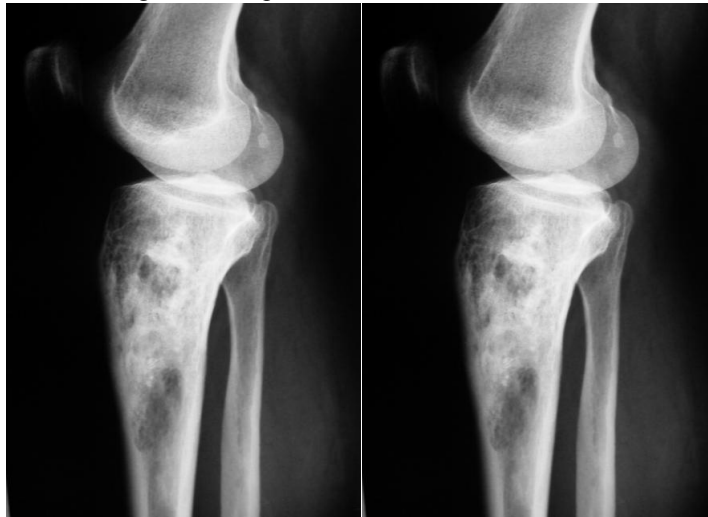**Fig 1, A and B;** X-ray of the right tibia showing metaphyso-diaphyseal cystic lesion of the proximal tibia.



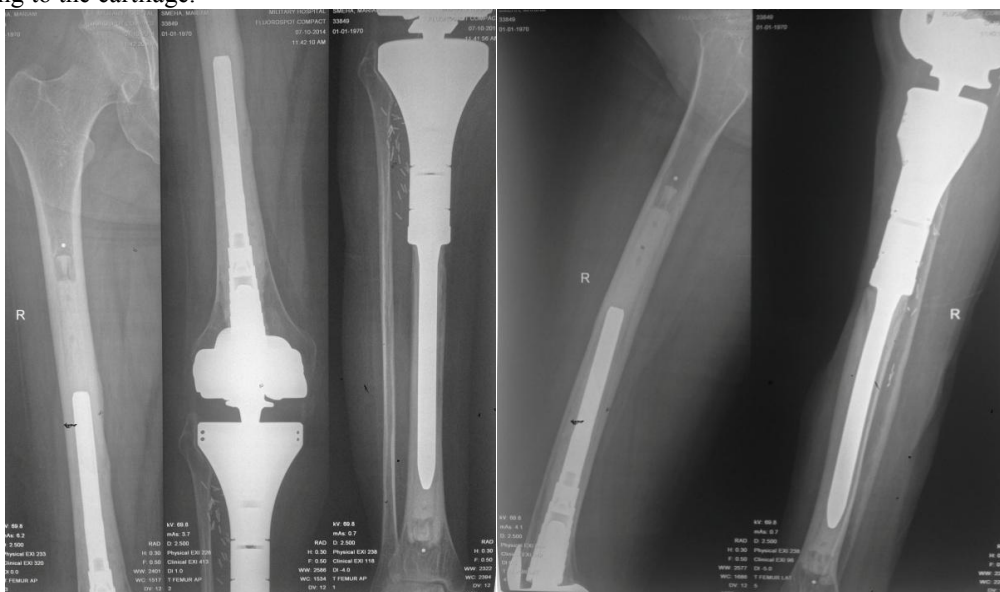
**Fig 2, A and B;** On the left: T1 coronal cuts showing hypointense proximal tibia lesion not reaching the articular surface, nor invading the surrounding soft tissues. On the right: T2 coronal cuts showing hyperintense lesion.



**Fig 3;** Transverse T1 cuts, showing the anteroposterior involvement of the tibia. No soft tissue invasion.



**Fig 4, A and B;** Three years after curettage and bone grafting, multiloculated osteolytic lesions of the proximal tibia extending to the cartilage.



**Fig 5, A and B;** Total knee arthroplasty was put after radical excision of the lesion.

### 3. Discussion

Definite hosts, in which the echinococci mature from the larval stage, are carnivores such as dogs and foxes. In their intestines, the ingested larvae are attached by hooklets to the mucosa. They become adults and their eggs are excreted in the stools contaminating vegetables. Herbivores, the intermediate hosts, such as sheep and cattle, as well as humans, may ingest the eggs which will give embryos in their intestines. They will invade, through the portal circulation, the liver and lungs maturing only to the larval stage when they form cysts. These herbivores by becoming food source for the carnivores will close the cycle.

The bones are infected in 0.45% to 2.5% of all cases of hydatid cysts<sup>[2]</sup>, 10 % of bony involvement is in the tibia, 35% in the spine, 21% in the pelvis, 16% in the femur, 6% in the ribs, 4% in the skull, 4% in the scapula, 2% in the humerus, and 2% in the fibula<sup>[3]</sup>. The cysts are present in metaphyseal and epiphyseal areas first. The cortex is a hard structure, and the cysts have a thinner envelope due to the absence of a pericyst in the bones. Both of these factors will orient the development of the cysts into the area of least resistance towards the diaphysis, lysing the trabeculae, and slowly eroding into the cortex. As a result, the cysts grow in an irregular, branching fashion in the bone. It may take 20 years before the symptoms appear<sup>[4]</sup>, making bone involvement less common in the younger population. If soft tissue is reached, the cyst will grow more rapidly and uniformly to form a large, spherical cyst. The patient may present with leg pain along with a palpable tumor, a pathologic fracture, or an infection. X-rays will show a single or multiple osteolytic cystic images<sup>[5]</sup>, it can be multilocular with reactive sclerosis forming a honeycombing pattern<sup>[6]</sup>. Periosteal thickening may appear on xray if there is a pathological fracture<sup>[7]</sup>. The differential diagnosis is benign bone cyst, giant cell tumor, brown tumor in hyperparathyroidism, fibrous dysplasia, chondromyxoid fibroma, tuberculosis, metastasis, aneurysmal bone cyst. In front of such image further imagery is required. CT scan will better evaluate, as well as the MRI, the lesion and its possible soft tissue invasion. CT scan will show non enhancing cystic lesions. A calcified rim will only surround soft tissue cysts, not cysts in the bone<sup>[8,9]</sup>. It is suggested that calcification varies according to the disease course and duration since calcification is caused by dystrophic changes of dead cysts<sup>[3]</sup>. MRI will show hypointense on T1 and hyperintense on T2 daughter cysts separated by various amounts of fluid collections. MRI may show on T2 a low signal intensity if nonviable scolices are present in the daughter cysts upon the pathology<sup>[10]</sup>. A water-lily sign has been suggested as a pathognomonic MRI sign, it is the image of detachment of the germinative layer of the cyst from the pericyst, but it is rarely observed<sup>[11,1]</sup>. It has been suggested that xray and even CT scan of hydatid disease are similar to those of metastases, giant cell tumors, tuberculosis, and bone cysts. Only MRI may aid in the diagnosis of hydatid cyst<sup>[12,13]</sup>.

Serological tests depend on the state of the cysts. If the cyst is calcified and dead, immunoreactivity is low, but it increases if there is cyst rupture and spillage of the content. Tests can either detect cyst antigens, or antibodies. The so called eight tests provide 92% sensitivity and 91% specificity. It consists of the gold labeled method and of the ELISA test of the following antigens: the Ag of the cyst fluid, of the cephalomere, of the alveolar echinococcus, and the half purified antigen of the cyst fluid<sup>[14]</sup>.

There is still no definite diagnostic test more than the histopathological testing through bone biopsy<sup>[9]</sup>. The incision is anteromedial to avoid compartmental dissemination. Bone is biopsied taking care not to spill the cystic fluid. Desensitization to this fluid has been reported ineffective<sup>[2]</sup>. Pathology report shows lamellated acellular cyst with germinal layer and scolex.

The main methods of treatment are suggested: curettage or radical resection, both with or without chemotherapy. Many have advocated the better results of radical resection with or without pre and post operative chemotherapy<sup>[15-17]</sup>. They consider cysts as a low grade malignancies with locally invasive properties. But Booz revealed good results with curettage and bone grafting with pre and post operative chemotherapy and indicated radical resection for "uncontrollable cases"<sup>[18]</sup> while still considering total resection as the best solutions in the fibula and ribs. After curettage, scolecidal agents may be used, such as formalin and hypertonic saline, but it has been suggested that they do not kill all microscopic daughter cysts<sup>[6]</sup>. Yildiz has suggested the use of PMMA to fill the cavity instead of bone

grafts, because cysts can recur in these bone grafts<sup>[6]</sup>. It was suggested that the thermal energy and free radicals released during polymerization have a scolicial effect. Monomers released from the PMMA are also toxic to living cells<sup>[19-21]</sup>. The chemotherapy consists of albendazole, mebendazole and praziquantel. Albendazole is preferred because it has the highest concentration inside the cyst.

If the patient lives in an endemic area or is in close contact with cattle, hydatid disease is suspected. While in the bones it does not probably affect long term survival, it is difficult to cure. Furthermore, in the spine, it may result in paraplegia and high morbidity<sup>[22]</sup>. To break the cycle of transmission, in Bulgaria, infected sheep were killed in Karaguiosov in 1970. In Kuwait, inspectors examine dog meat in the abattoirs<sup>[18]</sup>. Lebanon is considered an endemic area, but still no measures are taken to prevent this disease that is difficult to cure. Despite all radiological and serological tests, good history taking, such as exposure to cattle or living in a rural area, is still the mainstay of suspicion of the hydatid cyst.

## References

1. Vasilevska V, Zafirovski G, Kirjas N. Imaging diagnosis of musculoskeletal hydatid disease. *Prilozi* 2007 Dec; 28(2): 199-209
2. Sapkas GS, Stathakopoulos DP, Babis GC. Hydatid disease of bones and joints. 8 cases followed for 4-16 years. *Acta Orthop Scand* 1998; 69: 89-94.
3. Merkle EM, Schulte M, Vogel J. Musculoskeletal involvement in cystic echinococcosis: Report of eight cases and review of the literature. *Am J Roentgenol* 1997; 168: 1531-4.
4. Markakis P, Markakis S, Prevedorou D. Echinococcosis of bone: Clinico-laboratory findings and differential diagnostic problems. *Arch Anat Cytol Pathol* 1990; 38 (3): 92-4.
5. Dahniya MH, Hanna MR, Ashebu S. The imaging appearance of hydatid disease at some unusual sites. *British Journal of Radiology* 2001; 74: 283-9.
6. Y. Yildiz, K. Bayrakci, M. Altay. The use of polymethylmethacrylate in the management of hydatid disease of bone. *J Bone Joint Surg [Br]* 2001; 83-B: 1005-8.
7. Ersin Kuyucua, Mehmet Erdil B, Ali Dulgeroglu. An unusual cause of knee pain in a young patient: Hydatid disease of femur. *International Journal of Surgery Case Reports* 3 2012; 403- 406.
8. Booz MY. The value of plain film findings in hydatid disease of bone. *Clin Radiol* 1993; 47: 265-268.
9. Torricelli P, Martinelli C, Biagini R. Radiographic and computed tomographic findings in hydatid disease of bone. *Skeletal Radiol* 1990; 19: 435e439.
10. Garcia-Diez, Ros Mendosa LH, Villacampa VM. MRI evaluation of soft tissue hydatid disease. *Eur Radiol* 2000; 10(3): 462-6.
11. Comert RB, Aydingoz U., Ucaner A. Water-lily sign on MR imaging of primary intramuscular hydatidosis of sartorius muscle. *Skeletal Radiol* 2003; 32: 420-423.
12. Loudiye H, Aktaou S, Hassikou H, *et al.* Hydatid disease of bone: Review of 11 cases. *Joint Bone Spine* 2003; 70: 352-355.
13. Schneppenheim M, Jerosch J. Echinococcosis granulosa/cystica of the tibia. *Arch Orthopaed Trauma Surg Including Arthrosc Sports Med* 2003; 123: 107-111.
14. X H Song, L W Ding, H Wen. Bone hydatid disease. *Postgrad Med J* 2007; 83: 536-542.
15. Natarajan MV, Kumar AK, Sivaseelam A. Using a custom mega prosthesis to treat hydatidosis of bone: A report of 3 cases. *J Orthop Surg (Hong Kong)* 2002; 10: 203-5.
16. Zlitni M, Ezzaouia K, Lebib H. Hydatid cyst of the bone: Diagnosis and treatment. *World J Surg.* 2001; 25: 75e82.
17. Mnaymneh W, Yacoubian V, Bikhazi K. Hydatidosis of the pelvic girdle-treatment by partial pelvicotomy. A case report. *J Bone Joint Surg Am* 1977; 59: 538-40.
18. Booz MK. The management of hydatid disease of bone and joint. *Journal of Bone and Joint Surgery.* Dec 1972; 54(4): 698-709.
19. Strube HD, Komitowski D. Experimental studies of the treatment of malignant tumors with bone cement. In: Enneking WF, ed. *Limb salvage in musculoskeletal oncology.* New York: Churchill Livingstone 1987; 459-69.
20. Mjoberg B, Pettersson H, Rosenqvist R. Bone cement, thermal injury and the radiolucent zone. *Acta Orthop Scand* 1984; 55: 597-600.
21. Rock MG. Treatment of bone cysts and giant cell tumors. *Current Opinion in Orthopaedics* 1990; 1: 423-34. Yasir N Gashi, Walaa M Makki, Omiaa AO. Paraplegia due to a large solitary hydatid cyst of the lumbar spine: A case report and review of the literature. *Sudan Med J* 2013 April; 49(1).