

# Periprosthetic fractures after shoulder arthroplasty: a systematic review

Maciej Otworowski<sup>1</sup>, Dariusz Grzelecki<sup>2</sup>, Krzysztof Starszak<sup>3</sup>, Andrzej Boszczyk<sup>4</sup>, Mateusz Piorunek<sup>5</sup> and Bartłomiej Kordasiewicz<sup>1,4</sup>

<sup>1</sup>Idea Ortopedia, Warsaw, Poland

<sup>2</sup>Department of Orthopedics and Rheumoorthopedics, Centre of Postgraduate Medical Education, Otwock, Poland

<sup>3</sup>Department of Human Anatomy, Medical University of Silesia, Katowice, Poland

<sup>4</sup>Trauma and Orthopedics Department, Centre of Postgraduate Medical Education, Otwock, Poland

<sup>5</sup>Medical University of Warsaw, Warsaw, Poland

Correspondence should be addressed to M Otworowski

**Email**  
maciej.otworowski@gmail.com

- **Purpose:** The goal of this study was to review available literature on periprosthetic shoulder fractures to evaluate epidemiology, risk factors and support clinical decision-making regarding diagnostics, preoperative planning, and treatment options.
- **Methods:** Two authors cross-checked the PubMed and Web of Science medical databases. The inclusion criteria were as follows: original human studies published in English, with the timeframe not limited, and the following keywords were used: ‘periprosthetic shoulder fracture,’ ‘total shoulder arthroplasty periprosthetic fractures,’ ‘total shoulder arthroplasty fracture,’ and ‘total shoulder replacement periprosthetic fracture.’ Seventy articles were included in the review. All articles were retrieved using the aforementioned criteria.
- **Results:** The fracture rate associated with total shoulder arthroplasty varied between 0 and 47.6%. Risk factors for periprosthetic fractures were female gender, body mass index < 25 kg/m<sup>2</sup>, smoking, rheumatoid arthritis, and Parkinson’s disease. The most commonly used classification is the Wright and Coefield classification. Periprosthetic fractures can be treated both, conservatively and operatively.
- **Conclusion:** Periprosthetic fracture frequency after shoulder arthroplasty ranges from 0 to 47.6%. The most common location of the fracture is the humerus and most commonly occurs intraoperatively. The most important factor influencing treatment is stem stability. Fractures with stem instability require revision arthroplasty with stem replacement. Fractures with a stable stem depending on the location, displacement and bone stock quality can be treated both conservatively and operatively. For internal fixation plates with cables and screws are most commonly used.

## Keywords

- ▶ periprosthetic fracture
- ▶ shoulder arthroplasty
- ▶ humerus fracture

EFORT Open Reviews  
(2023) 8, 748–758

## Introduction

First results of total shoulder arthroplasty (TSA) were published in the 1970s by Near *et al.* (1). Later, in the 1980s, Garmont presented reverse shoulder arthroplasty (RSA) (2, 3, 4, 5). Currently, shoulder replacement is the third most commonly performed type of arthroplasty. It has been increasingly popular in the last 40 years, showing exponential growth (6, 7, 8, 9, 10, 11, 12, 13, 14, 15, 16, 17, 18, 19).

Degenerative changes related to osteoarthritis (OA) remain the most common reason for performing arthroplasty, but there is a growing number of procedures being performed due to other indications (11, 20). Many reports have shown good functional results and

high satisfaction rates comparable to total hip and knee replacements (2, 11, 13, 21, 22, 23, 24, 25, 26, 27, 28, 29, 30, 31, 32).

Despite satisfactory implant survival rate (at 88.13% in 10 years of observation), shoulder replacement is associated with some complications: aseptic loosening, secondary rotator cuff damage, infection, neural injury, and finally, periprosthetic fracture (33). A significantly higher complication rate (four times higher) is being observed after reverse total shoulder replacements (2, 19, 32, 34, 35).

Periprosthetic fracture is a universal complication for all kinds of arthroplasties. In shoulder arthroplasties they are less common, but, nevertheless, they pose a complex challenge for clinicians (4, 15, 21, 36, 37, 38, 39, 40).

Such complications could potentially sabotage surgical outcomes. In the literature, there is a limited amount of reports discussing the treatment and risk factors of periprosthetic shoulder fractures (21, 33, 36).

The goal of this study was to review available literature on periprosthetic shoulder fractures to evaluate epidemiology, risk factors and support clinical decision-making regarding diagnostics, preoperative planning, and treatment options.

## Methodology

Methodology of this systematic review was designed according to Preferred Reporting Items for Systematic Reviews and Meta-Analyses (PRISMA) recommendations (41).

Two authors cross-checked the PubMed and Web of Science medical databases. The timeframe was not limited. The language was limited to English, and studies' subject was limited to human. The key words used were 'periprosthetic shoulder fracture,' 'total shoulder arthroplasty periprosthetic fractures,' 'total shoulder arthroplasty fracture,' 'total shoulder replacement periprosthetic fracture.' The initially selected articles were screened for eligibility criteria by reading abstracts. Bibliography of the selected articles were reviewed for further articles that could be potentially included in the review.

The included studies must have evaluated the complications following shoulder arthroplasty. We included original retrospective and randomized studies and case series. Letters to the editor, expert consensus, case reports, and review papers were excluded.

Quality assessment was undertaken by two independent investigators. The Cochrane Collaboration's 'Risk of bias' tool as reported in the Cochrane Handbook for Systematic Reviews of Interventions was utilized to evaluate the risk of bias in randomized controlled trials and the Newcastle–Ottawa Scale and Modified Newcastle–Ottawa Scale were used to assess the methodological rigor in observational studies (Supplementary Tables 1 and 2; see section on [supplementary materials](#) given at the end of this article) (42, 43, 44).

## Results

We identified 4362 studies in the primary search. Overall, 212 papers met the inclusion criteria. One hundred sixty-six were selected based on their title, 82 after abstract review. Twenty were rejected as these were duplicates. From quotations of the searched works, 30 works were initially selected of which 13 were rejected. In the end, 70 articles were included in the review (Fig. 1).

Two researchers extracted data from the eligible studies: first author's or authors' names, type of procedure that resulted in periprosthetic fracture (TSA, RTSA, HA, revision arthroplasty), duration of follow-up, prevalence of periprosthetic fractures, classification of periprosthetic fractures, risk factors, treatment, outcome measures, and results.

## Epidemiology

In the analysis of the National Joint Registry, intraoperative fractures of the humerus were the 14th most common complication (1.3%), postoperative fractures were 17th (1%), and glenoid fractures were 19th (6).

The general rate of periprosthetic fracture in the studies included in this review was as follows: 0–10% in TSA, 0–11% in HA, 0.4–29% in RTSA, and 3.4–40% in revision procedures. Individual data from all of the studies are presented in [Tables 1, 2, 3, and 4](#). The most common location was the humerus. The rate of scapular fractures was between 0 and 15.6%.

The prevalence of intraoperative fractures varied between 0 and 47.6%, postoperative between 0 and 16.1%.

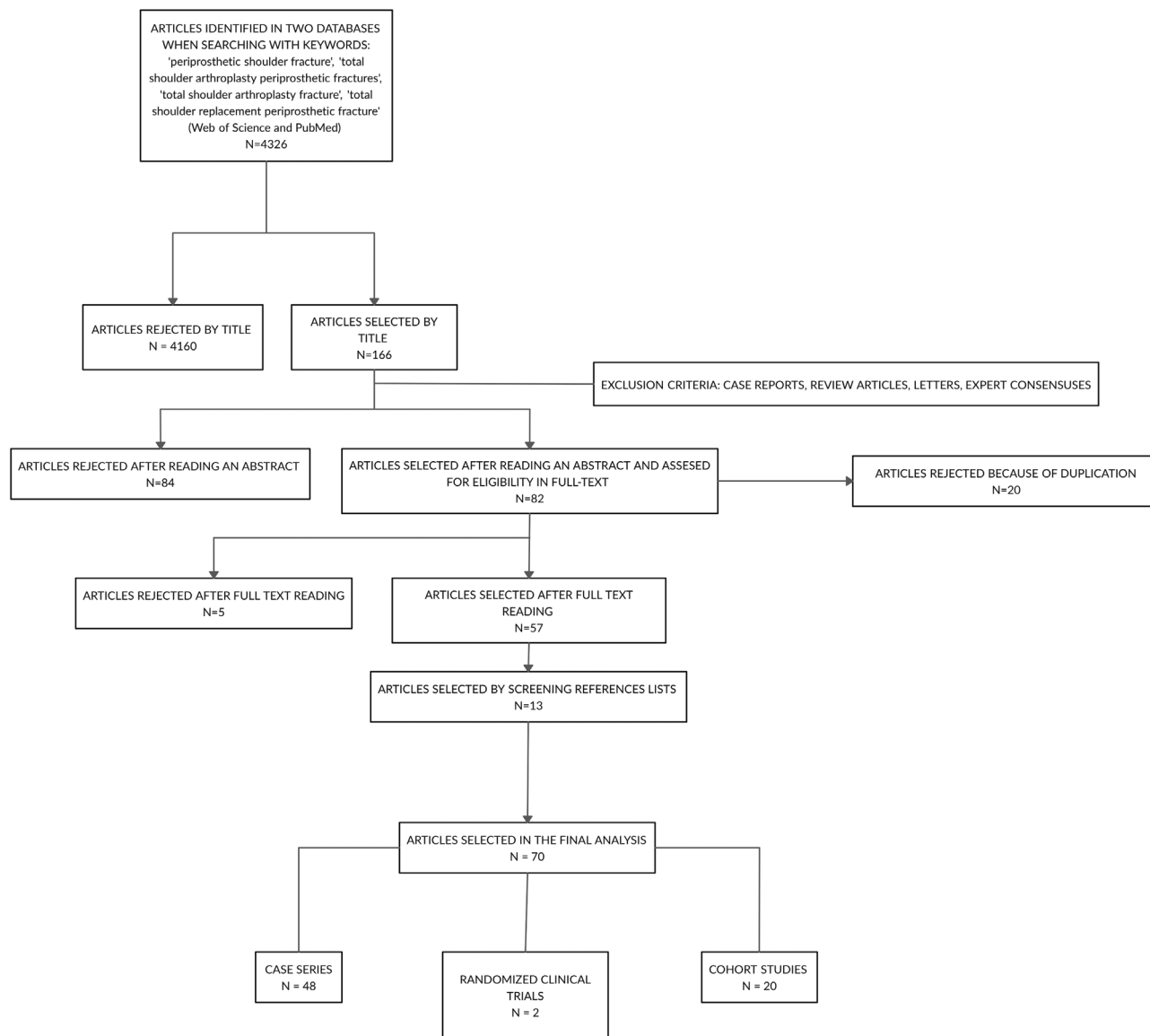
In studies describing periprosthetic fracture mechanism intraoperative fractures occurred most commonly during the final or test stem impaction. Less frequently, they were associated with stem removal or medullary canal reaming. Rarely, they occurred during glenoid exposition, retractor positioning, or shoulder dislocation/reposition (15, 22, 40). Postoperative fractures occurred as often due to aseptic loosening as during injuries (14, 21, 40, 45). The average time from arthroplasty to postoperative fracture diagnosis was between 1 and 5.8 years after primary procedure and 3.2 years after revision (4, 21, 23, 28).

In TSA periprosthetic fractures were more common when cemented stems were used (2%) compared to uncemented (1.63%), in revisions when the uncemented stem was used (relative ratio = 2.9) (15, 46).

## Risk factors

All the described risk factors in the analyzed studies and their influence on the periprosthetic fracture occurrence are presented in [Table 6](#) (11, 15, 22, 23, 36, 47, 48, 49, 50, 51).

Factors most strongly associated with a periprosthetic fracture were female sex, previous shoulder operations (including arthroplasties), long operative time (>174 min), history of solid organ transplantation, posttraumatic arthritis, inflammatory arthritis, and implant instability. Hatta *et al.* demonstrated a statistically



**Figure 1**  
Flowchart summarizing our search methodology and results.

significant correlation between a history of smoking and periprosthetic fractures. Also, there was a higher prevalence of fracture occurrence in the actively smoking group comparing to patients who quit smoking at least 1 month before the procedure (52). In Testa *et al.* joint registry analysis, the authors found that periprosthetic fractures in 1 year postoperatively are more common in patients younger than 80 years of age compared to older patients (odds ratio=0.35) (53).

In Walters *et al.* study, the authors compared the results of bilateral shoulder arthroplasty based on the interval between two procedures. They found that having the second arthroplasty before 3 months from the initial

procedure increased the likelihood of periprosthetic fracture compared to interval of more than a year (54).

### Classifications

We found five classifications describing periprosthetic shoulder fractures (Fig. 2, 3, 4, and 5).

Wright–Cofield (W-C) classification was the most commonly used in the analyzed studies (Table 5) (4, 15, 21, 33, 38). Along with two other classifications – Groh and Campbell – it divides the fracture based on its pattern either in relation to the tip of the stem or humerus region

**Table 1** Epidemiology of periprosthetic fractures associated with TSA.

Study	Prevalence of fractures			Comments
	General	Intraoperative	Postoperative	
Mansat <i>et al.</i> (68)	0%	–	–	In all patients, the indication for surgery was AVN. All were cemented.
Gartsman <i>et al.</i> (29)	0%	–	–	In all patients, the indication for surgery was OA. All were cemented.
Kiet <i>et al.</i> (14)	0%	–	–	In all patients, the indication for surgery was OA. All stems were cemented.
Schoch <i>et al.</i> (7)	0.6%	–	0.6%	The prevalence of fractures requiring revision procedure.
Cowling <i>et al.</i> (8)	1.6%	1.6%	–	NJR analysis
Desmkuh <i>et al.</i> (23)	2.8%	0.3%	2.5%	In the majority of patients, the indication for surgery was rheumatoid arthritis (69%). Components were cemented. Glenoid fracture: 0.3%
Singh <i>et al.</i> (36)	2.8%	1.8%	1%	Glenoid fracture: 0.3%
Somerson <i>et al.</i> (6)	3%	–	–	Analysis of the FDA MAUDE database for reporting side effects during therapy. Intraoperative fractures of the humerus constituted 1.3% of all complications, postoperative fractures of the humerus 1%
Chin <i>et al.</i> (69)	3%	2.8%	0.2%	Different indications. Uncemented. Glenoid fracture: 0%
Lo <i>et al.</i> (13)	10%	10%	–	In all patients, the indication for surgery was OA. Cemented and uncemented. Glenoid fracture: 5%
Waterman <i>et al.</i> (11)	0.05%	–	–	Analysis of national database. Complications within 30-days after TSA.
Uribe <i>et al.</i> (70)	2.8%	–	2.8%	Inlay prosthesis. In all patients, the indication for surgery was OA. Glenoid fracture: 2.8%
Aibinder <i>et al.</i> (18)	0%	–	–	Analysis of the results of short stem implantation.

(32, 37). Worland classification is the only classification that assess the stability of the stem (55).

There is only one described classification of periprosthetic scapular fractures. It was proposed by Levy *et al.* and classifies acromion fractures (Fig. 6) (56). It was reproduced by one study (47). In the rest of the article the classification used for further descriptions will be W-C.

## Treatment

### Conservative

According to most authors, periprosthetic fractures, regardless of whether they occur during or after surgery, can be treated conservatively or surgically (4, 16, 23, 32, 34, 37, 38, 45, 57, 58).

In Hasler *et al.* study, the authors did not introduce any treatment or modified rehabilitation protocol after incidentally diagnosed intraoperative fractures that occurred during RTSA. All fractures healed (59).

Type A and C fractures (W-C) were treated conservatively if there was no loosening of the implant and the fracture did not extend to the cement mantle (4, 32, 37, 58, 60). Type B fractures were treated conservatively for up

to 3 months if the implant was stable (38, 60, 61). For nonoperative treatment, the authors used different types of immobilization: hanging cast, sugar tong splints, and orthosis. After failed conservative treatment they performed surgical interventions (37, 38). The average time to achieve bone union was 3.5 months (37).

Scapular fractures were treated conservatively only (16, 32, 34, 57).

### Open reduction and internal fixation

Metaphyseal fractures were treated with wires or cerclage (4, 15, 32, 62, 63). Wagner *et al.* additionally used cortical strut allografts in displaced fractures (15).

In type B humeral shaft fractures with stable stem and markedly displaced type C fractures, the most commonly used treatment was plate (either locking compression plate or dynamic compression plate) with screws and wires (4, 16, 32, 38, 60, 64, 65, 66, 67). Schoch *et al.* used matching lengthening plates designed specifically for treating periprosthetic fractures of the humerus (76). In four studies fixation was reinforced with allografts (38, 64, 66, 67). The bone union was achieved in 91.67–100% of the cases. The mean time to achieve union was between 3.7 and 12 months (38, 60, 64, 65, 66).

**Table 2** Epidemiology of periprosthetic fractures associated with HA.

Study	Prevalence of fractures			Comments
	General	Intraoperative	Postoperative	
Feeley <i>et al.</i> (71)	0%	–	–	In all patients, the indication for surgery was AVN.
Gartsman <i>et al.</i> (29)	0%	–	–	In all patients, the indication for surgery was OA. All stems were uncemented.
Rispoli <i>et al.</i> (30)	0%	–	–	In all patients, the indication for surgery was OA. Cemented and uncemented.
Gadea <i>et al.</i> (27)	1.1%	–	–	Different indications. Cemented; No differentiation between intra- and postoperative fractures.
Singh <i>et al.</i> (36)	2.3%	1%	1.3%	Different indications. Analysis of periprosthetic fractures. Glenoid fracture: 0.6%
Lo <i>et al.</i> (13)	9.5%	9.5%	–	In all patients, the indication for surgery was OA. Cemented and uncemented. Glenoid fracture: 0%
Boileau <i>et al.</i> (26)	11%	4.4%	6.6%	

**Table 3** Epidemiology of periprosthetic fractures associated with RTSA.

Study	Prevalence of fractures			Comments
	General	Intraoperative	Postoperative	
Lindbloom <i>et al.</i> (72)	0.4%	–	0.4%	Different indications. Cemented and uncemented. Acromion fracture: 0.1% In all patients, the indication for surgery was rotator cuff tear. Cemented stem. Scapular spine fracture: 2%
Cuff <i>et al.</i> (73)	2%	–	2%	
Ascione <i>et al.</i> (60)	1.6%	–	1.6%	Different indications. Cemented and uncemented stems. Different indications. Scapular fracture: 1.8%; Glenoid fracture: 0.9%
Saltzman <i>et al.</i> (24)	2.7%	2.7%	–	
Choi <i>et al.</i> (2)	7.5%	–	7.5%	In all of the patients, the indication for surgery was rotator cuff tear. n cemented stems were used. Glenoid fracture: 2.6%
Garcia-Fernandez <i>et al.</i> (4)	1.96%	0.98%	0.98%	
Cho <i>et al.</i> (19)	7.5%	2.5%	5%	Only humeral fractures analyzed. Different indications. Cemented and uncemented. Irreparable rotator cuff tears. Only postoperative acromial fractures
Ji <i>et al.</i> (34)	14%	9.5%	5%	
Hasler (59)	5%	5%	–	Different indications. Cemented stem. Glenoid fracture: 2.5% Only intraoperative fractures diagnosed incidentally
Rangarajan <i>et al.</i> (74)	5.6%	5.6%	–	
Kiet <i>et al.</i> (14)	7.5%	7.5%	–	Custom-made glenoid component Rotator cuff arthroplasty. All of the stems were cemented. Scapular fracture: 7.5%; Glenoid fracture: 3.75%
Kriechling <i>et al.</i> (75)	7.8%	7.8%	–	
Mangano <i>et al.</i> (76)	9.6%	3.2%	6.4%	Scapular fracture: 5.3% Over 79 years of age population. Different indications. Cemented and uncemented. Scapular fracture: 3.2%
Holcom <i>et al.</i> (17)	12%	4%	8%	
Jeong <i>et al.</i> (80)	8.9%	8.9%	–	In all patients, the indication for surgery was rheumatoid arthritis with rotator cuff insufficiency. Cemented stems. Scapular fracture: 12%; Glenoid fracture: 8% Treatment of complex proximal humeral fractures. Cemented stems. All of the fractures in non-fracture stem (16%).
Atoun <i>et al.</i> (5)	29%	9.7%	19.3%	

**Revision**

In majority of the studies, the authors decided whether to perform open reduction and internal fixation (ORIF) or make a revision arthroplasty based on the presence of stem loosening (60). The method of choice was a revision procedure with the use of a long stem (12, 23, 28, 37, 38, 58, 67). Campbell *et al.* proposed the appropriate length of the stem. The tip of the stem should be implanted at least three times the cortical diameter from the most distal part of the fracture. When complying to this rule, the average time to achieve bone union was 2.3 months compared to 8.7 months without it (37). If supplementary fixation was needed, the authors employed plates and wires (12, 37, 38, 32, 58, 64). Andersen *et al.* used strut

allografts when the bone stock was assessed to be poor intraoperatively (67).

In two B3 fractures (W) Wolf *et al.* performed revision arthroplasty (one with a long stem implantation and other with a resection prosthesis) (61).

Swell *et al.* in their study described the treatment of complex periprosthetic fractures with a custom-made prosthesis. Seven prostheses were used, nine stems in total; in three cases, a custom-made implant of the elbow and shoulder was used. In two cases, the bridging prosthesis was used. In one case, the standard revision stem was used. The radiological and clinical union was achieved in 12 patients after an average time of 27 weeks (33).

**Table 4** Epidemiology of periprosthetic fractures associated with revision shoulder arthroplasties.

Study	Prevalence of fractures			Comments
	General	Intraoperative	Postoperative	
Ingoe <i>et al.</i> (77)	3.4%	3.4%	–	NJR analysis. Only long and medium-long stems. Cemented and uncemented. No information on the primary procedures. Scapular fracture: 0%
Owens <i>et al.</i> (58)	7.5%	6.25%	1.25%	
Saltzman <i>et al.</i> (24)	15.3%	3.8%	11.5%	Conversion of HA or TSA to RSA due to glenoid failure and/or rotator cuff insufficiency. Scapular fracture: 0%
Melis <i>et al.</i> (59)	13.5%	10.8%	2.7%	
Wagner <i>et al.</i> (15)	15.7%	15.7%	1.7%	TSA to RSA due to aseptic loosening of the acetabulum. Cemented and uncemented. Scapular fracture: 0% Conversion of HA or TSA to RSA.
Levy <i>et al.</i> (28)	15.8%	–	15.8%	
Flury <i>et al.</i> (25)	22%	22%	–	Conversion of HA to RSA. All stems were cemented. Scapular fracture: 10%; Acromion fracture: 10% Conversion of TSA to RSA due to cuff insufficiency. All stems were cemented. Scapular fracture: 0%
Wieser <i>et al.</i> (40)	40%	27%	13%	
Austin <i>et al.</i> (78)	30%	30%	–	Conversion of HA or TSA to RSA due to rotator cuff failure. Cemented and uncemented. Scapular fracture: 15.6%; Acromion fracture: 11%; Glenoid fracture: 4.4% Revision reverse shoulder arthroplasties. Both. conversions and reverse to reverse. Different indications. All stems were cemented. No description of fractures.
Antoni <i>et al.</i> (9)	27.1%	24.3%	2.7%	
Bartels <i>et al.</i> (79)	24.8%	24%	0.8%	All types of revisions. Different indications. All stems were cemented. Scapular fracture: 0% Conversion of TSA to RSA due to glenoid component loosening.

**Table 5** The distribution of types of fractures in evaluated studies using Wright and Cofield classification.

Study	A	B	C	Other
Wutzler <i>et al.</i> (21)	3	1	–	B+C 1
Kumar <i>et al.</i> (38)	6	6a	3	–
Carlos <i>et al.</i> (4)	1	3	–	–
Wagner <i>et al.</i> (15)	36	–	–	–
Sewell <i>et al.</i> (33)	11	6	4	–

**Complications**

Kumar *et al.* and Novi *et al.* described complications of periprosthetic fractures treatment. The most common was acromial fracture followed by implant instability, infection, and nonunion (38, 64). Novi *et al.* reported high prevalence of neurological complications (12.5%) and infections (6.25%).

**Discussion**

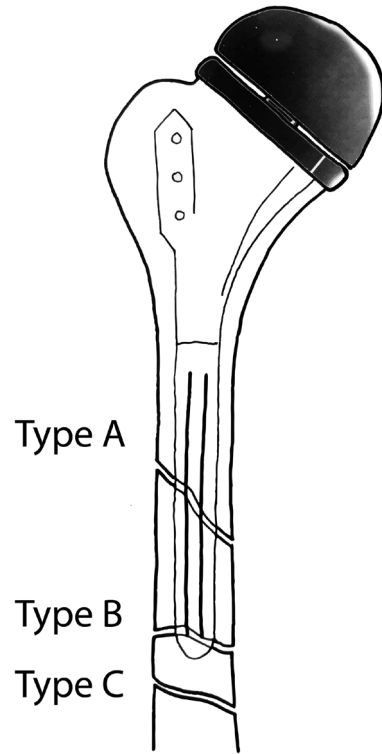
Periprosthetic fracture frequency depends mainly on the type of surgery. Revision procedures are much more commonly associated with periprosthetic fractures than primary procedures. For primary surgeries, the lowest risk of periprosthetic fracture is associated with an anatomical shoulder replacement and hemiarthroplasty. Significantly higher periprosthetic fracture occurrence was associated with RTSA. The additional risk factors increasing risk of fracture by the most are female gender, smoking history, and conditions associated with steroid intake.

The most common location of the fracture was the humerus, although scapular fractures are given more consideration in recent times.

Periprosthetic fractures of the humerus most often occur intraoperatively. Special attention and care must be taken during the preparation of the medullary canal

**Table 6** Risk factors presented in the analyzed studies along with the calculated odds ratio, relative ratio, or hazard ratio.

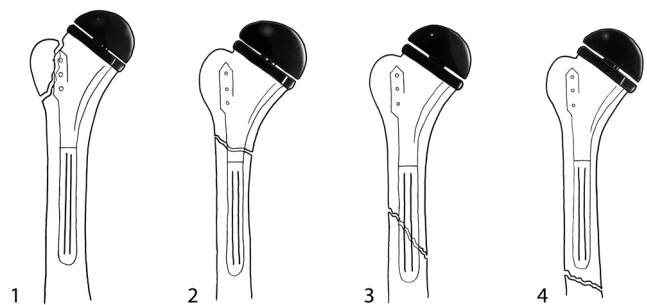
Risk factor	OR	RR	HR
Female sex	2.41–4.39	3.3	
Low mineral bone density		1.6	
Osteoporosis	1.49–1.86		
BMI <25 kg/m <sup>2</sup>			1.12
Long operative time (>174 min)	4.05		
History of solid organ transplantation			8.18
Parkinson’s disease	1.5		
Smoking			4.56–7.27
RA		1.9	
Post-traumatic arthritis	2.17	1.9	
AVN	1.1		
Revision surgery	2.8		
Implant instability	2.65		
Excessive deltoid lengthening	1.04		
Previous shoulder operations	2.91	2.8	
Early bilateral shoulder arthroplasty	4.18		
Inflammatory arthritis	2.57		
Previous HA	2.34		



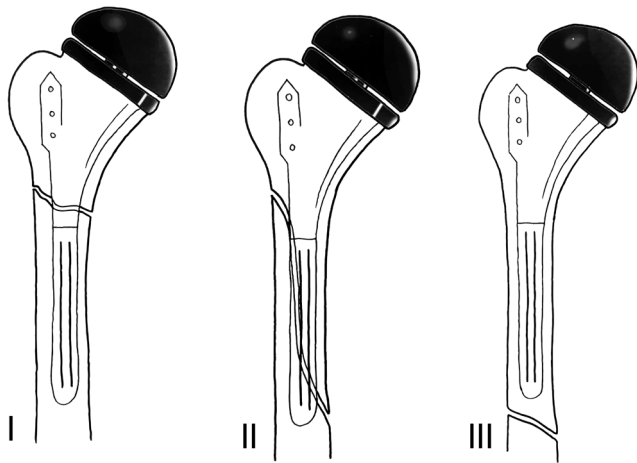
**Figure 2** Wright and Cofield classification. It divides periprosthetic fractures into three types. Type A – fracture located near the tip of the stem. Extending proximally. Type B – fracture located near the tip of the stem. Extending distally. Type C – fracture located distally to the stem.

and inserting both trial and final implants. Postoperative fractures most commonly occur after one up to 5 years after the surgery. Therefore, it is necessary to pay special attention for periprosthetic fractures in all patients with shoulder prosthesis who present in the emergency department after injury.

Limited use of fracture classification was noticed – in only 10 out of 70 studies. The most commonly used



**Figure 3** Campbell classification. Region 1 – tuberosity fracture. Region 2 – proximal metaphysis. Region 3 – proximal part of the diaphysis. Region 4 – middle and distal part of the diaphysis.

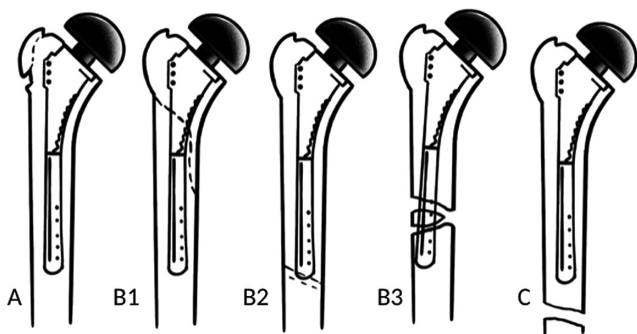


**Figure 4**  
Groh classification. I – fracture occurs proximally to the tip of the stem. II – fracture occurs proximally to the tip of the stem and extends distally. III – fracture originates distally to the tip of the stem.

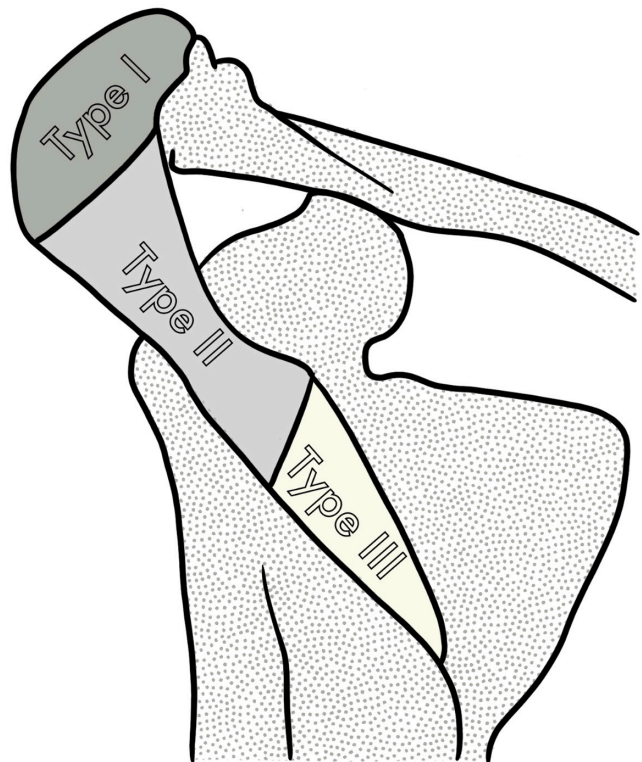
classification is the Wright and Cofield’s one. Comparing the fracture types among these studies, we noticed that most fractures are classified as distal from the tip of the stem. That may suggest the need to extend these classifications with subtypes, which could be helpful in preoperative planning. Given the factors influencing the therapeutic decisions stability of the stem in all of the fracture types should be assessed and bone stock also.

Fractures located distally from the tip of the stem or around metaphysis with a stable stem can be initially treated conservatively.

Fractures around the stem usually require revision surgery. In most cases, it might be necessary to replace the stem. During this procedure, the Campbell’s rule



**Figure 5**  
Worland classification. It divides fractures into three types: A, B, C and type B further into three subtypes: B1, B2, B3. Type A and C are similar to regions 1 and 4 of Campbell classification (fracture around tuberosity and fracture distal to the tip of the stem, respectively). Type B fractures are located around the stem: B1 – spiral pattern of fracture, B2 – transverse or short oblique pattern of fracture, B3 – fracture with stem instability.



**Figure 6**  
Levy classification. Type I – anterior and middle deltoid origin; type II – involvement of at least the entire middle deltoid origin; type III – entire middle and posterior deltoid origin.

should be applied – the tip of the new stem should be implanted at least three times the cortical diameter from the most distal part of the fracture. In metaphyseal fractures without stem instability, a bone suture or wires may be considered. For diaphysis fractures without the implant instability, plates systems with screws and/or wires could be used. The use of matching lengthening plates for the treatment of periprosthetic fractures of the humerus seems especially promising.

Bone union after both nonoperative and surgical treatment should be obtained after about 3 months.

The promising method for particularly complicated humerus fractures could be custom-made prostheses, as the initial results are encouraging.

**Conclusion**

Periprosthetic fracture frequency after shoulder arthroplasty ranges from 0 to 47.6%. The most common location of the fracture is the humerus and

most commonly occurs intraoperatively. risk factors increasing risk of fracture by the most are female gender, smoking history, and conditions associated with steroid intake. The most popular classification of periprosthetic humeral fractures is W-C classification and for acromial fractures Levy classification. The most important factor influencing treatment is stem stability. Fractures with stem instability require revision arthroplasty with longer stem replacement or custom-made implant. Fractures with a stable stem depending on the location, displacement, and bone stock quality can be treated both conservatively and operatively. Nondisplaced fractures can usually be treated without surgical intervention with plaster cast or orthosis. Displaced fractures require ORIF; plates with cables and screws are most commonly used.

**Supplementary materials**

This is linked to the online version of the paper at <https://doi.org/10.1530/EOR-22-0097>.

**ICMJE Conflict of Interest Statement**

The authors declare that there is no conflict of interest that could be perceived as prejudicing the impartiality of the research reported.

**Funding statement**

This research did not receive any specific grant from any funding agency in the public, commercial, or not-for-profit sector.

**References**

1. Neer CS, Watson KC & Stanton FJ. Recent experience in total shoulder replacement. *Journal of Bone and Joint Surgery. American Volume* 1982 **64** 319–337. (<https://doi.org/10.2106/00004623-198264030-00001>)
2. Choi S, Bae JH, Kwon YS & Kang H. Clinical outcomes and complications of cementless reverse total shoulder arthroplasty during the early learning curve period. *Journal of Orthopaedic Surgery and Research* 2019 **14** 53. (<https://doi.org/10.1186/s13018-019-1077-1>)
3. Russo R, Della Rotonda GD, Ciccirelli M & Cautiero F. Analysis of complications of reverse total shoulder arthroplasty. *Joints* 2015 **3** 62–66. (<https://doi.org/10.1138/jts/2015.3.2.062>)
4. García-Fernández C, Lópiz-Morales Y, Rodríguez A, López-Durán L & Martínez FM. Periprosthetic humeral fractures associated with reverse total shoulder arthroplasty: incidence and management. *International Orthopaedics* 2015 **39** 1965–1969. (<https://doi.org/10.1007/s00264-015-2972-7>)
5. Atoun E, Van Tongel A, Hous N, Narvani A, Relwani J, Abraham R & Levy O. Reverse shoulder arthroplasty with a short metaphyseal humeral stem. *International Orthopaedics* 2014 **38** 1213–1218. (<https://doi.org/10.1007/s00264-014-2328-8>)
6. Somerson JS, Hsu JE, Neradilek MB & Matsen FA. Analysis of 4063 complications of shoulder arthroplasty reported to the US Food and Drug Administration from 2012 to 2016. *Journal of Shoulder and Elbow Surgery* 2018 **27** 1978–1986. (<https://doi.org/10.1016/j.jse.2018.03.025>)

7. Schoch B, Werthel JD, Schleck CD, Harmsen WS, Sperling J, Sánchez-Sotelo J & Cofield RH. Optimizing follow-up after anatomic total shoulder arthroplasty. *Journal of Shoulder and Elbow Surgery* 2017 **26** 997–1002. (<https://doi.org/10.1016/j.jse.2016.10.024>)
8. Cowling PD, Holland P, Kottam L, Baker P & Rangan A. Risk factors associated with intraoperative complications in primary shoulder arthroplasty. *Acta Orthopaedica* 2017 **88** 587–591. (<https://doi.org/10.1080/17453674.2017.1362155>)
9. Antoni M, Barthoulot M, Kempf JF & Clavert P. Revisions of total shoulder arthroplasty: clinical results and complications of various modalities. *Orthopaedics and Traumatology, Surgery and Research* 2016 **102** 297–303. (<https://doi.org/10.1016/j.otsr.2016.01.009>)
10. Filho GM, Galvão MV, Monteiro M, Cohen M & Brandão B. Shoulder arthroplasty records. *Revista Brasileira de Ortopedia* 2009 **44** 125–133. ([https://doi.org/10.1016/S2255-4971\(15\)30059-8](https://doi.org/10.1016/S2255-4971(15)30059-8))
11. Waterman BR, Dunn JC, Bader J, Urrea L, Schoenfeld AJ & Belmont PJ. Thirty-day morbidity and mortality after elective total shoulder arthroplasty: patient-based and surgical risk factors. *Journal of Shoulder and Elbow Surgery* 2015 **24** 24–30. (<https://doi.org/10.1016/j.jse.2014.05.016>)
12. Ortmaier R, Resch H, Matis N, Blocher M, Auffarth A, Mayer M, Hitzl W & Tauber M. Reverse shoulder arthroplasty in revision of failed shoulder arthroplasty—outcome and follow-up. *International Orthopaedics* 2013 **37** 67–75. (<https://doi.org/10.1007/s00264-012-1742-z>)
13. Lo IKY, Litchfield RB, Griffin S, Faber K, Patterson SD & Kirkley A. Quality-of-life outcome following hemiarthroplasty or total shoulder arthroplasty in patients with osteoarthritis: a prospective, randomized trial. *Journal of Bone and Joint Surgery. American Volume* 2005 **87** 2178–2185. (<https://doi.org/10.2106/JBJS.D.02198>)
14. Kiet TK, Feeley BT, Naimark M, Gajiu T, Hall SL, Chung TT & Ma CB. Outcomes after shoulder replacement: comparison between reverse and anatomic total shoulder arthroplasty. *Journal of Shoulder and Elbow Surgery* 2015 **24** 179–185. (<https://doi.org/10.1016/j.jse.2014.06.039>)
15. Wagner ER, Houdek MT, Elhassan BT, Sanchez-Sotelo J, Cofield RH & Sperling JW. What are risk factors for intraoperative humerus fractures during revision reverse shoulder arthroplasty and do they influence outcomes? *Clinical Orthopaedics and Related Research* 2015 **473** 3228–3234. (<https://doi.org/10.1007/s11999-015-4448-x>)
16. Hevesi M, Houdek MT, Cofield RH, Sperling JW, Sanchez-Sotelo J & Wagner ER. Can a reverse shoulder arthroplasty be used to revise a failed primary reverse shoulder arthroplasty? Revision reverse shoulder arthroplasty for failed reverse prosthesis. *Bone and Joint Journal* 2018 **100B** 1493–1498. (<https://doi.org/10.1302/0301-620X.100B11.BJJ-2018-0226.R2>)
17. Holcomb JO, Hebert DJ, Mighell MA, Dunning PE, Pupello DR, Pliner MD & Frankle MA. Reverse shoulder arthroplasty in patients with rheumatoid arthritis. *Journal of Shoulder and Elbow Surgery* 2010 **19** 1076–1084. (<https://doi.org/10.1016/j.jse.2009.11.049>)
18. Aibinder WR, Bartels DW, Sperling JW & Sanchez-Sotelo J. Mid-term radiological results of a cementless short humeral component in anatomical and reverse shoulder arthroplasty. *Bone and Joint Journal* 2019 **101-B** 610–614. (<https://doi.org/10.1302/0301-620X.101B5.BJJ-2018-1374.R1>)
19. Cho CH, Song KS & Koo TW. Clinical outcomes and complications during the learning curve for reverse total shoulder arthroplasty: an analysis of the first 40 cases. *Clinics in Orthopedic Surgery* 2017 **9** 213–217. (<https://doi.org/10.4055/cios.2017.9.2.213>)



- 20. Norris TR & Iannotti JP.** Functional outcome after shoulder arthroplasty for primary osteoarthritis: a multicenter study. *Journal of Shoulder and Elbow Surgery* 2002 **11** 130–135. (<https://doi.org/10.1067/mse.2002.121146>)
- 21. Wutzler S, Laurer HL, Huhnstock S, Geiger EV, Buehren V & Marzi I.** Periprosthetic humeral fractures after shoulder arthroplasty: operative management and functional outcome. *Archives of Orthopaedic and Trauma Surgery* 2009 **129** 237–243. (<https://doi.org/10.1007/s00402-008-0746-z>)
- 22. Athwal GS, Sperling JW, Rispoli DM & Cofield RH.** Periprosthetic humeral fractures during shoulder arthroplasty. *Journal of Bone and Joint Surgery. American Volume* 2009 **91** 594–603. (<https://doi.org/10.2106/JBJS.H.00439>)
- 23. Deshmukh AV, Koris M, Zurakowski D & Thornhill TS.** Total shoulder arthroplasty: Long-term survivorship, functional outcome, and quality of life. *Journal of Shoulder and Elbow Surgery* 2005 **14** 471–479. (<https://doi.org/10.1016/j.jse.2005.02.009>)
- 24. Saltzman BM, Chalmers PN, Gupta AK, Romeo AA & Nicholson GP.** Complication rates comparing primary with revision reverse total shoulder arthroplasty. *Journal of Shoulder and Elbow Surgery* 2014 **23** 1647–1654. (<https://doi.org/10.1016/j.jse.2014.04.015>)
- 25. Flury MP, Frey P, Goldhahn J, Schwyzer HK & Simmen BR.** Reverse shoulder arthroplasty as a salvage procedure for failed conventional shoulder replacement due to cuff failure—midterm results. *International Orthopaedics* 2011 **35** 53–60. (<https://doi.org/10.1007/s00264-010-0990-z>)
- 26. Boileau P, Watkinson D, Hatzidakis AM & Hovorka I.** Neer Award 2005: the Grammont reverse shoulder prosthesis: results in cuff tear arthritis, fracture sequelae, and revision arthroplasty. *Journal of Shoulder and Elbow Surgery* 2006 **15** 527–540. (<https://doi.org/10.1016/j.jse.2006.01.003>)
- 27. Gadea F, Alami G, Pape G, Boileau P & Favard L.** Shoulder hemiarthroplasty: outcomes and long-term survival analysis according to etiology. *Orthopaedics and Traumatology, Surgery and Research* 2012 **98** 659–665. (<https://doi.org/10.1016/j.otsr.2012.03.020>)
- 28. Levy JC, Virani N, Pupello D & Frankle M.** Use of the reverse shoulder prosthesis for the treatment of failed hemiarthroplasty in patients with glenohumeral arthritis and rotator cuff deficiency. *Journal of Bone and Joint Surgery. British Volume* 2007 **89** 189–195. (<https://doi.org/10.1302/0301-620X.89B2.18161>)
- 29. Gartsman GM, Roddey TS & Hammerman SM.** Shoulder arthroplasty with or without resurfacing of the glenoid in patients who have osteoarthritis. *Journal of Bone and Joint Surgery. American Volume* 2000 **82** 26–34. (<https://doi.org/10.2106/00004623-200001000-00004>)
- 30. Rispoli DM, Sperling JW, Athwal GS, Schleck CD & Cofield RH.** Humeral head replacement for the treatment of osteoarthritis. *Journal of Bone and Joint Surgery. American Volume* 2006 **88** 2637–2644. (<https://doi.org/10.2106/JBJS.E.01383>)
- 31. Mellano CR, Kupfer N, Thorsness R, Chalmers PN, Feldheim TF, O'Donnell P, Cole BJ, Verma NN, Romeo AA & Nicholson GP.** Functional results of bilateral reverse total shoulder arthroplasty. *Journal of Shoulder and Elbow Surgery* 2017 **26** 990–996. (<https://doi.org/10.1016/j.jse.2016.10.011>)
- 32. Groh GI & Groh GM.** Complications rates, reoperation rates, and the learning curve in reverse shoulder arthroplasty. *Journal of Shoulder and Elbow Surgery* 2014 **23** 388–394. (<https://doi.org/10.1016/j.jse.2013.06.002>)
- 33. Sewell MD, Kang SN, Al-Hadithy N, Higgs DS, Bayley I, Falworth M & Lambert SM.** Management of peri-prosthetic fracture of the humerus with severe bone loss and loosening of the humeral component after total shoulder replacement. *Journal of Bone and Joint Surgery. British Volume* 2012 **94** 1382–1389. (<https://doi.org/10.1302/0301-620X.94B10.29248>)
- 34. Ji JH, Jeong JY, Song HS, Ok JH, Yang SJ, Jeon BK, Kim TG, Moon YS & Kim YS.** Early clinical results of reverse total shoulder arthroplasty in the Korean population. *Journal of Shoulder and Elbow Surgery* 2013 **22** 1102–1107. (<https://doi.org/10.1016/j.jse.2012.07.019>)
- 35. Noguera L, Trigo L, Melero V, Santana F & Torrens C.** Reverse shoulder arthroplasty for acute proximal humeral fractures: postoperative complications at 7 days, 90 days and 1 year. *Injury* 2019 **50** 371–375. (<https://doi.org/10.1016/j.injury.2019.01.002>)
- 36. Singh JA, Sperling J, Schleck C, Harmsen W & Cofield R.** Periprosthetic fractures associated with primary total shoulder arthroplasty and primary humeral head replacement: a thirty-three-year study. *Journal of Bone and Joint Surgery. American Volume* 2012 **94** 1777–1785. (<https://doi.org/10.2106/JBJS.J.01945>)
- 37. Campbell JT, Moore RS, Iannotti JP, Norris TR & Williams GR.** Periprosthetic humeral fractures: mechanisms of fracture and treatment options. *Journal of Shoulder and Elbow Surgery* 1998 **7** 406–413. ([https://doi.org/10.1016/S1058-2746\(98\)90033-7](https://doi.org/10.1016/S1058-2746(98)90033-7))
- 38. Kumar S, Sperling JW, Haidukewych GH & Cofield RH.** Periprosthetic humeral fractures after shoulder arthroplasty. *Journal of Bone and Joint Surgery. American Volume* 2004 **86** 680–689. (<https://doi.org/10.2106/00004623-200404000-00003>)
- 39. Sommacal R, Bloch HR, Ghidelli A, Bettelli G & Dalla Pria P.** Comminuted periprosthetic humeral fracture after reverse shoulder prosthesis. *Chirurgia Degli Organi di Movimento* 2009 **93**(Supplement 1) S83–S87. (<https://doi.org/10.1007/s12306-009-0013-7>)
- 40. Wieser K, Borbas P, Ek ET, Meyer DC & Gerber C.** Conversion of stemmed hemi- or total to reverse total shoulder arthroplasty: advantages of a modular stem design. *Clinical Orthopaedics and Related Research* 2015 **473** 651–660. (<https://doi.org/10.1007/s11999-014-3985-z>)
- 41. Page MJ, McKenzie JE, Bossuyt PM, Boutron I, Hoffmann TC, Mulrow CD, Shamseer L, Tetzlaff JM, Akl EA, Brennan SE, et al.** The PRISMA 2020 statement: an updated guideline for reporting systematic reviews. *BMJ* 2021 **372** n71 doi:[10.1136/bmj.n71](https://doi.org/10.1136/bmj.n71)
- 42. Wells GA, Wells G, Shea B, Shea B, O'Connell D, Peterson J, Welch L, M, Tugwell P, Ga SW, et al.** *The Newcastle-Ottawa Scale (NOS) for Assessing the Quality of Nonrandomised Studies in Meta-analyses.* 2014. Available at [https://www.ohri.ca/programs/clinical\\_epidemiology/oxford.asp](https://www.ohri.ca/programs/clinical_epidemiology/oxford.asp)
- 43. Murad MH, Sultan S, Haffar S & Bazerbachi F.** Methodological quality and synthesis of case series and case reports. *BMJ Evidence-Based Medicine* 2018 **23** 60–63. (<https://doi.org/10.1136/bmjebm-2017-110853>)
- 44. Higgins JPT, Altman DG, Gatzsche PC, Jani P, Moher D, Oxman AD, Savovic J, Schulz KF, Weeks L, Sterne JA, et al.** The Cochrane Collaboration's tool for assessing risk of bias in randomised trials. *BMJ* 2011 **343** d5928 doi:[10.1136/bmj.d5928](https://doi.org/10.1136/bmj.d5928)
- 45. Melis B, Bonnevalle N, Neyton L, Lévine C, Favard L, Walch G & Boileau P.** Glenoid loosening and failure in anatomical total shoulder arthroplasty: is revision with a reverse shoulder arthroplasty a reliable option? *Journal of Shoulder and Elbow Surgery* 2012 **21** 342–349. (<https://doi.org/10.1016/j.jse.2011.05.021>)
- 46. Werthel JD, Lonjon G, Jo S, Cofield R, Sperling JW & Elhassan BT.** Long-term outcomes of cemented versus cementless humeral components in arthroplasty of

- the shoulder: a propensity score-matched analysis. *Bone and Joint Journal* 2017 **99–B** 666–673 doi:[10.1302/0301-620X.99B5.BJJ-2016-0910.R1](https://doi.org/10.1302/0301-620X.99B5.BJJ-2016-0910.R1)
- 47. Cho CH, Rhee YG, Yoo JC, Ji JH, Kim DS, Kim YS, Rhee SM & Kim DH.** Incidence and risk factors of acromial fracture following reverse total shoulder arthroplasty. *Journal of Shoulder and Elbow Surgery* 2021 **30** 57–64. (<https://doi.org/10.1016/j.jse.2020.04.031>)
- 48. Wagner ER, Houdek MT, Schleck C, Harmsen WS, Sanchez-Sotelo J, Cofield R, Sperling JW & Elhassan BT.** Increasing body mass index is associated with worse outcomes after shoulder arthroplasty. *Journal of Bone and Joint Surgery. American Volume* 2017 **99** 929–937. (<https://doi.org/10.2106/JBJS.15.00255>)
- 49. Burrus MT, Werner BC, Cancienne JM, Gwathmey FW & Brockmeier SF.** Shoulder arthroplasty in patients with Parkinson's disease is associated with increased complications. *Journal of Shoulder and Elbow Surgery* 2015 **24** 1881–1887. (<https://doi.org/10.1016/j.jse.2015.05.048>)
- 50. Casp AJ, Montgomery SR Jr, Cancienne JM, Brockmeier SF & Werner BC.** Osteoporosis and implant-related complications after anatomic and reverse total shoulder arthroplasty. *Journal of the American Academy of Orthopaedic Surgeons* 2020 **28** 121–127. (<https://doi.org/10.5435/JAAOS-D-18-00537>)
- 51. Hatta T, Statz JM, Itoi E, Cofield RH, Sperling JW & Morrey ME.** Shoulder arthroplasty in patients with immunosuppression following solid organ transplantation. *Journal of Shoulder and Elbow Surgery* 2020 **29** 44–49. (<https://doi.org/10.1016/j.jse.2019.05.042>)
- 52. Hatta T, Werthel JD, Wagner ER, Itoi E, Steinmann SP, Cofield RH & Sperling JW.** Effect of smoking on complications following primary shoulder arthroplasty. *Journal of Shoulder and Elbow Surgery* 2017 **26** 1–6. (<https://doi.org/10.1016/j.jse.2016.09.011>)
- 53. Testa EJ, Yang D, Steflik MJ, Owens BD, Parada SA, Daniels AH & DeFroda S.** Reverse total shoulder arthroplasty in patients 80 years and older: a national database analysis of complications and mortality. *Journal of Shoulder and Elbow Surgery* 2022 **31** S71–S77. (<https://doi.org/10.1016/j.jse.2022.01.146>)
- 54. Walters JD, Denard PJ, Brockmeier SF & Werner BC.** The relationship of bilateral shoulder arthroplasty timing and postoperative complications. *Journal of Shoulder and Elbow Surgery* 2021 **30** 317–323. (<https://doi.org/10.1016/j.jse.2020.06.010>)
- 55. Worland RL, Kim DY & Arredondo J.** Periprosthetic humeral fractures: management and classification. *Journal of Shoulder and Elbow Surgery* 1999 **8** 590–594. ([https://doi.org/10.1016/s1058-2746\(99\)90095-2](https://doi.org/10.1016/s1058-2746(99)90095-2))
- 56. Levy JC, Anderson C & Samson A.** Classification of postoperative acromial fractures following reverse shoulder arthroplasty. *Journal of Bone and Joint Surgery. American Volume* 2013 **95** e104. (<https://doi.org/10.2106/JBJS.K.01516>)
- 57. Walker M, Willis MP, Brooks JP, Pupello D, Mulieri PJ & Frankle MA.** The use of the reverse shoulder arthroplasty for treatment of failed total shoulder arthroplasty. *Journal of Shoulder and Elbow Surgery* 2012 **21** 514–522. (<https://doi.org/10.1016/j.jse.2011.03.006>)
- 58. Owens CJ, Sperling JW & Cofield RH.** Utility and complications of long-stem humeral components in revision shoulder arthroplasty. *Journal of Shoulder and Elbow Surgery* 2013 **22** e7–12. (<https://doi.org/10.1016/j.jse.2012.10.034>)
- 59. Hasler A, Kriechling P, Passaplan C & Wieser K.** Inadvertent, intraoperative, non- to minimally displaced periprosthetic humeral shaft fractures in RTSA do not affect the clinical and radiographic short-term outcome. *Archives of Orthopaedic and Traumatic Surgery* 2021. (<https://doi.org/10.1007/s00402-021-03930-z>)
- 60. Ascione F, Domos P, Guarrella V, Chelli M, Boileau P & Walch G.** Long-term humeral complications after Grammont-style reverse shoulder arthroplasty. *Journal of Shoulder and Elbow Surgery* 2018 **27** 1065–1071. (<https://doi.org/10.1016/j.jse.2017.11.028>)
- 61. Wolf H, Pajenda G & Sarahrudi K.** Analysis of factors predicting success and failure of treatment after type B periprosthetic humeral fractures: a case series study. *European Journal of Trauma and Emergency Surgery* 2012 **38** 177–183. (<https://doi.org/10.1007/s00068-011-0145-y>)
- 62. Ristow JJ, Ellison CM, Mickschl DJ, Berg KC, Haidet KC, Gray JR & Grindel SI.** Outcomes of shoulder replacement in humeral head avascular necrosis. *Journal of Shoulder and Elbow Surgery* 2019 **28** 9–14. (<https://doi.org/10.1016/j.jse.2018.06.031>)
- 63. Eyberg BA, Walker JB, Harmsen SM, Gobezie R, Denard PJ & Lederman ES.** Suture cerclage for stabilizing the humeral shaft during shoulder arthroplasty. *JSES International* 2020 **4** 688–693. (<https://doi.org/10.1016/j.jseint.2020.03.002>)
- 64. Novi M, Porcellini G, Donà A, Tarallo L, Micheloni G, Giorgini A, Paladini P & Catani F.** A long-term follow-up of post-operative periprosthetic humeral fracture in shoulder arthroplasty. *Geriatric Orthopaedic Surgery and Rehabilitation* 2021 **12** 21514593211039908. (<https://doi.org/10.1177/21514593211039908>)
- 65. Schoch B, Mehta S & Namdari S.** Surgical fixation of periprosthetic humerus fractures using an extension plate: surgical technique and report of 5 cases. *Journal of Orthopaedic Trauma* 2017 **31** e432–e435. (<https://doi.org/10.1097/BOT.0000000000000935>)
- 66. Vincenti G, Solarino G, Carrozzo M, Simone F, Ottaviani G, Bizzoca D, Zavattini G, Zaccari D, Buono C & Moretti B.** Is the Posterior Approach with Posterior locking compression plate and Anterior Allograft Useful and Safe in the Treatment of periprosthetic Humeral Fractures Following Reverse Total shoulder Arthroplasty? *Geriatric Orthopaedic Surgery and Rehabilitation* 2022 **13** 21514593221080961. (<https://doi.org/10.1177/21514593221080961>)
- 67. Andersen JR, Williams CD, Cain R, Mighell M & Frankle M.** Surgically treated humeral shaft fractures following shoulder arthroplasty. *Journal of Bone and Joint Surgery. American Volume* 2013 **95** 9–18. (<https://doi.org/10.2106/JBJS.K.00863>)
- 68. Mansat P, Huser L, Mansat M, Bellumore Y, Rongières M & Bonnevalle P.** Shoulder arthroplasty for atraumatic avascular necrosis of the humeral head: nineteen shoulders followed up for a mean of seven years. *Journal of Shoulder and Elbow Surgery* 2005 **14** 114–120. (<https://doi.org/10.1016/j.jse.2004.06.019>)
- 69. Chin PYK, Sperling JW, Cofield RH & Schleck C.** Complications of total shoulder arthroplasty: are they fewer or different? *Journal of Shoulder and Elbow Surgery* 2006 **15** 19–22. (<https://doi.org/10.1016/j.jse.2005.05.005>)
- 70. Uribe JW, Zvijac JE, Porter DA, Saxena A & Vargas LA.** Inlay total shoulder arthroplasty for primary glenohumeral arthritis. *JSES International* 2021 **5** 1014–1020. (<https://doi.org/10.1016/j.jseint.2021.07.014>)
- 71. Feeley BT, Fealy S, Dines DM, Warren RF & Craig EV.** Hemiarthroplasty and total shoulder arthroplasty for avascular necrosis of the humeral head. *Journal of Shoulder and Elbow Surgery* 2008 **17** 689–694. (<https://doi.org/10.1016/j.jse.2008.03.009>)
- 72. Lindbloom BJ, Christmas KN, Downes K, Simon P, McLendon PB, Hess AV, Mighell MA & Frankle MA.** Is there a relationship between preoperative diagnosis and clinical outcomes in reverse shoulder arthroplasty? An experience in 699

shoulders. *Journal of Shoulder and Elbow Surgery* 2019 **28** S110–S117. (<https://doi.org/10.1016/j.jse.2019.04.007>)

**73. Cuff DJ, Pupello DR, Santoni BG, Clark RE & Frankle MA.** Reverse shoulder arthroplasty for the treatment of rotator cuff deficiency a concise follow-up, at a minimum of 10 years, of previous reports. *Journal of Bone and Joint Surgery. American Volume* 2017 **99** 1895–1899. (<https://doi.org/10.2106/JBJS.17.00175>)

**74. Rangarajan R, Blout CK, Patel VV, Bastian SA, Lee BK & Itamura JM.** Early results of reverse total shoulder arthroplasty using a patient-matched glenoid implant for severe glenoid bone deficiency. *Journal of Shoulder and Elbow Surgery* 2020 **29** S139–S148. (<https://doi.org/10.1016/j.jse.2020.04.024>)

**75. Kriechling P, Zaleski M, Loucas R, Loucas M, Fleischmann M & Wieser K.** Complications and further surgery after reverse total shoulder arthroplasty : report of 854 primary cases. *Bone and Joint Journal* 2022 **104–B** 401–407. (<https://doi.org/10.1302/0301-620X.104B3.BJJ-2021-0856.R2>)

**76. Mangano T, Cerruti P, Repetto I, Felli L, Ivaldo N & Giovale M.** Reverse shoulder arthroplasty in older patients: is it worth it? A subjective functional outcome and

quality of life survey. *Aging Clinical and Experimental Research* 2016 **28** 925–933. (<https://doi.org/10.1007/s40520-015-0493-2>)

**77. Ingoe HM, Holland P, Cowling P, Kottam L, Baker PN & Rangan A.** Intraoperative complications during revision shoulder arthroplasty: a study using the National Joint Registry dataset. *Shoulder and Elbow* 2017 **9** 92–99. (<https://doi.org/10.1177/1758573216685706>)

**78. Austin L, Zmistowski B, Chang ES & Williams GR.** Is reverse shoulder arthroplasty a reasonable alternative for revision arthroplasty? *Clinical Orthopaedics and Related Research* 2011 **469** 2531–2537. (<https://doi.org/10.1007/s11999-010-1685-x>)

**79. Bartels DW, Marigi E, Sperling JW & Sanchez-Sotelo J.** Revision reverse shoulder arthroplasty for anatomical glenoid component loosening was not universally successful: a detailed analysis of 127 consecutive shoulders. *Journal of Bone and Joint Surgery. American Volume* 2021 **103** 879–886. (<https://doi.org/10.2106/JBJS.20.00555>)

**80. Jeong JJ, Kong CG, Park SE, Ji JH, Whang WH & Choi BS.** Non-fracture stem vs fracture stem of reverse total shoulder arthroplasty in complex proximal humeral fracture of Asian elderly. *Archives of Orthopaedic and Trauma Surgery* 2019 **139** 1649–1657. (<https://doi.org/10.1007/s00402-019-03190-y>)