



SIMULTANEOUS MULTIFOCAL INTRACRANIAL HAEMORRHAGES ASSOCIATED WITH STAPHYLOCOCCUS AUREUS ENDOCARDITIS: A PLAUSIBLE ROLE FOR DICLOFENAC ADMINISTRATION

Ariella Tvito¹, Ariel Rokach², Eliel Ben-David³, Moshe Simons⁴, Samuel Noam Heyman⁴

¹ Department of Hematology, Shaare Zedek Medical Center, Jerusalem, Israel

² Pulmonary Institute, Shaare Zedek Medical Center and Faculty of Medicine, Hebrew University of Jerusalem, Jerusalem, Israel

³ Department of Radiology, Shaare Zedek Medical Center, Jerusalem, Israel

⁴ Department of Medicine, Hadassah Hebrew University Hospital, Mt. Scopus, Jerusalem, Israel

Corresponding author: Samuel Noam Heyman **e-mail:** Heyman@cc.huji.ac.il

Received: 31/07/2023 Accepted: 15/08/2023 Published: 05/09/2023

Conflicts of Interests: The Authors declare that there are no competing interests.

Patient Consent: Written informed consent was obtained from the patient.

This article is licensed under a Commons Attribution Non-Commercial 4.0 License

How to cite this article: Tvito A, Rokach A, Ben-David E, Simons M, Heyman SN. Simultaneous multifocal intracranial haemorrhages associated with staphylococcus aureus endocarditis: a plausible role for diclofenac administration. *EJCRIM* 2023;10:doi:10.12890/2023_004044.

ABSTRACT

Introduction: Intracranial haemorrhage may complicate infective endocarditis, caused by ruptured mycotic aneurysms or haemorrhagic transformation of brain septic emboli. The risk of intracranial bleeding may increase with the use of non-steroidal anti-inflammatory agent (NSAIDs).

Case description: We report on a 53-year-old male patient with a past history of intravenous drug abuse, who was treated with diclofenac (75 mg IM) for a few hours of preceding fever and arthralgia. Seven hours later he was hospitalised with impaired consciousness and hemiparesis. Evaluation revealed multiple intracranial haemorrhages, at least one originating from a mycotic aneurysm. Repeated blood cultures grew methicillin-resistant *Staphylococcus aureus* (MRSA), and echocardiography revealed a vegetation on the mitral valve, establishing the diagnosis of bacterial endocarditis.

Conclusion: The abrupt simultaneous multifocal intracranial bleeds shortly following the administration of NSAIDs for a few hours of febrile disease, one clearly originating from a mycotic aneurysm, are exceptional. This raises a possibility of a role for diclofenac the intracranial bleeding diathesis in this unique clinical presentation. Intracranial haemorrhage in the set-up of undiagnosed infective endocarditis (IE) might be added to the long list of potential adverse outcomes of NSAID administration, and the possibility of IE should be considered before their administration for febrile disease of undetermined cause.

KEYWORDS

Infective endocarditis, NSAIDs, diclofenac, mycotic aneurysm, haemorrhagic stroke

LEARNING POINTS

- Intracranial haemorrhage in the set-up of undiagnosed infective endocarditis might be added to the long list of potential adverse outcomes of NSAID administration.
- The possibility of infective endocarditis should be considered before the administration of NSAIDs for febrile disease of an undetermined cause.



BACKGROUND

Non-steroidal anti-inflammatory drugs (NSAIDs) inhibit platelet cyclooxygenase, thereby blocking the formation of thromboxane A₂. These drugs produce a systemic bleeding tendency by impairing thromboxane-dependent platelet aggregation and consequently prolonging the bleeding time. Bleeding diathesis related to the use of NSAIDs has been reported, particularly involving the gastrointestinal tract. Intracranial bleeds due to NSAIDs may also be particularly important, with the potential development of neurologic deficits and life-threatening conditions. A meta-analysis of 13 observational studies, evaluating patients with acute ischaemic stroke, indicates that the use of NSAIDs increases the risk of haemorrhagic transformation of brain infarcts by 33%^[1]. In a similar fashion, in a study of over 30,000 patients with low back pain, the use of NSAIDs was found to be associated with a 60% increase in the risk of developing haemorrhagic stroke^[2], and the use of NSAIDs by patients with flu-like syndrome was associated with a 2.3 times increased risk of developing intracranial bleeds^[3]. Aspirin, an archetype of NSAIDs, is administered to patients with ischaemic stroke as a secondary prevention and substantially reduces the likelihood of developing a repeat stroke. Yet, this protection is achieved with a 69% increased risk of intracranial bleeding^[4]. NSAIDs may differ in their potency to increase the risk of intracranial bleeding. For instance, another meta-analysis did not show enhanced risk of intracranial bleeding with NSAIDs grouped together; yet, enhanced risk was shown with the use of diclofenac^[5], with bleeding reported to develop as early as 30 minutes following intramuscular injection of this drug^[6].

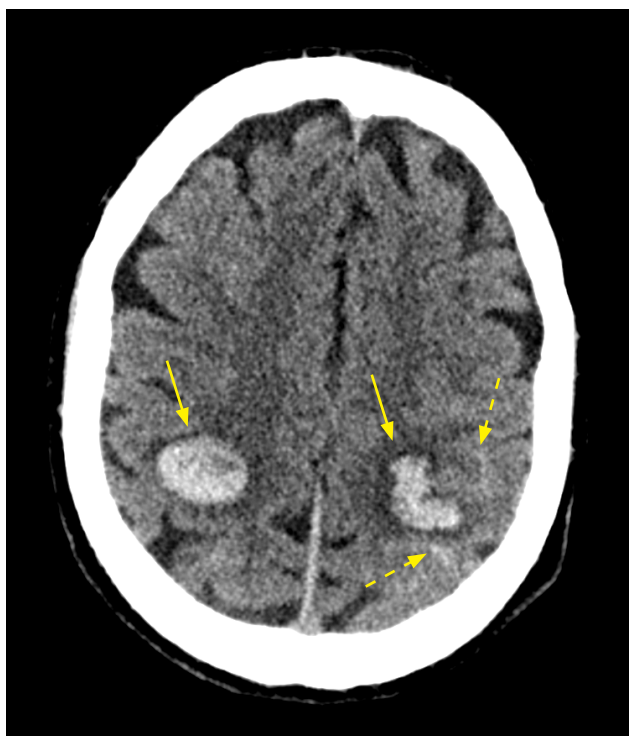

Figure 1. Axial non-contrast CT. Image demonstrating bilateral parenchymal haemorrhages (solid arrows) with a small amount of subarachnoid haemorrhage on the left (dashed arrows)

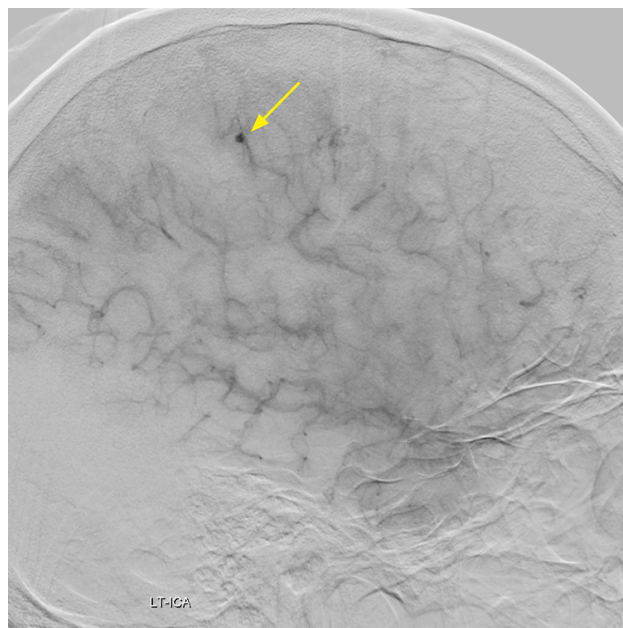


Figure 2. Digital subtraction angiography (DSA). Image in a lateral view demonstrates an aneurysm (solid arrow) in the left parietal lobe, in a distal branch of the left MCA

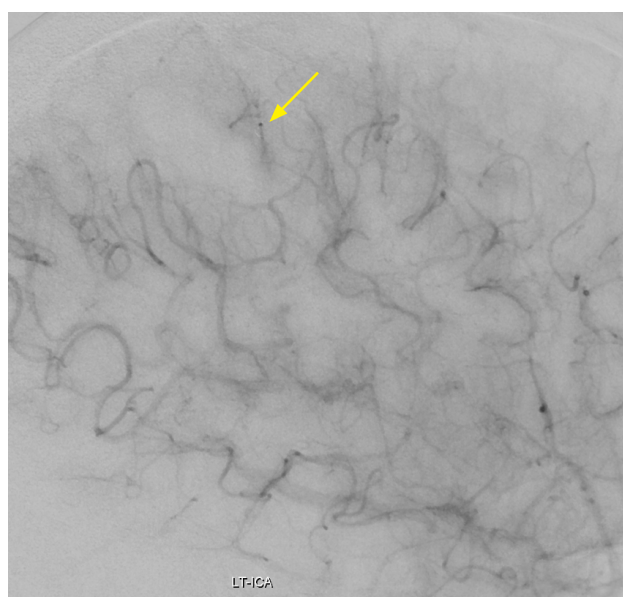


Figure 3. Post-embolisation DSA. Image in a lateral view demonstrates a normal appearance after injection of a sclerosing agent, occluding the aneurysm

Patients with vascular structural lesions known to predispose to spontaneous intracranial haemorrhage, such as vascular malformations or amyloid angiopathy, are at a special risk for this complication while on NSAIDs. Subjects with infective endocarditis (IE) should be considered as possibly having vascular malformations, since bacterial spread may take the form of mycotic aneurysms prone to rupture and bleeding, and as embolic strokes may undergo haemorrhagic transformation.

Our report is related to a patient with staphylococcal IE, manifested as fever for a few hours, who developed simultaneous multiple intracranial bleeds within hours following an intramuscular injection of diclofenac. It is

suggested that this agent may have contributed to the devastating outcome by promoting intracranial bleeding diathesis.

CASE REPORT

A 53-year-old male patient presented at a Health Care Clinic at 21:00 complaining of fever and excessive sweating since the morning. His medical history was remarkable for drug abuse in the past and he was cared for in an ambulatory rehabilitation facility and administered methadone, clonazepam and methylphenidate. He had previously been successfully treated for hepatitis C virus infection, displayed serologic evidence for past infection with hepatitis B virus, and had liver fibrosis with intact synthetic function.

On admission, he complained of abdominal and low back pain, and arthralgia. Physical examination was reported as unremarkable. He was diagnosed in the clinic as suffering from a viral infection and dehydration, and was administered diclofenac 75 mg (IM). Early in the morning, seven hours later, he was found with decreased consciousness and right hemiparesis. Brain CT revealed bilateral large parietal hemorrhages with three additional microbleeds and subarachnoid extension (Fig. 1) Blood cultures grew methicillin-resistant *Staphylococcus aureus* (MRSA).

Cardiac echocardiography identified a vegetation on a left ventricular papillary muscle and CT angiography disclosed an evolving mycotic aneurism in the distal left middle cerebral artery (Fig. 2), which was managed by an endovascular procedure (Fig. 3). The patient underwent a protracted hospitalisation course of antibiotics, followed by rehabilitation, regained cognitive capabilities but remained triplegic, incapacitated and wheelchair-bound.

DISCUSSION

The described patient, with a very short clinical course of MRSA IE spanning 14 hours, developed multiple intracerebral bleeds within seven hours following the intramuscular injection of diclofenac. Though IE may be complicated by a haemorrhagic stroke, it is possible that there was inactivation of the platelet-based immediate haemostatic mechanism with the administration of diclofenac prior to an initiation of antimicrobial therapy. This led the way to the early development of extensive simultaneous cerebral bleeding foci.

Symptomatic thromboembolic complications caused by the release of infected vegetations occur in 25% of patients with IE, and about half of them manifest with stroke. This is the rationale for the administration of anticoagulants or anti-platelet medications in such patients. In a large retrospective analysis of 600 patients with IE, the continuous use of anti-platelets was associated with a 65% reduction of symptomatic embolic events^[7]. In an additional small prospective clinical trial, the administration of aspirin was found to reduce the size of vegetations and the risk of embolic stroke^[8]. Of note, however, all patients in these two studies were given anti-platelet agents while on effective

antimicrobial therapy, likely reducing the risk of both emboli and bleeding from an enlarging mycotic aneurysm. Continuation of anticoagulants is also recommended in patients with valvular heart disease, acquiring and treated for IE, including those with prosthetic valves, especially since the risk of stroke and bleeding dramatically declines within days of the initiation of antimicrobial treatment.

On the other hand, however, patients with IE may develop haemorrhagic strokes; it has been reported in 5–7% of patients with IE in studies performed 30–50 years ago^[9]. In an additional large cohort of patients with IE in China during 2003–2017, 4% of the patients developed haemorrhagic stroke^[10]. Yet its incidence declined more recently to some 2% of patients, possibly reflecting an earlier and more efficient medical intervention.

Brain haemorrhage in patients with IE may reflect haemorrhagic transformation of ischaemic stroke caused by infected emboli. Additionally, intracranial bleeding may originate from mycotic aneurysms, caused by septic arteritis and blood-vessel-wall injury. These vascular lesions may leak and evolve into microbleeds and major haemorrhagic strokes. MRI studies disclosed that some 50% of patients with IE show microbleeds^[11], a finding also confirmed in autopsies^[12], and that their presence predicts the likelihood of developing a haemorrhagic stroke. In large historic studies, brain haemorrhage occurred primarily at the time of presentation, particularly in intravenous drug abusers, and predominantly associated with uncontrolled *S. aureus* infection.

It is, therefore, not surprising that the administration of fibrinolytic agents, anticoagulants or anti-platelet agents in patients with stroke, related to unrecognised and untreated IE, increases the risk of developing haemorrhagic strokes^[13]. Detailed case reports exemplify this point describing patients, retrospectively identified as having IE, who developed extensive and multifocal intracranial haemorrhagic lesions following thrombolytic therapy for a large ischaemic stroke^[14,15]. These case reports underscore the need to consider the possibility of IE before the initiation of thrombolysis in patients with ischaemic stroke. In this respect, guidelines recommend avoidance of anticoagulants or anti-platelet medications in patients with valvular diseases and IE, until there is control and stabilisation of the infective disorder.

Our patient presented within hours of the first symptoms of IE, and developed simultaneous multifocal haemorrhagic strokes and microbleeds shortly after receiving diclofenac. To the best of our knowledge, there are no comparable cases of patients treated with NSAIDs for undiagnosed IE, who developed haemorrhagic strokes. Although the concomitant multifocal intracranial bleeding as the natural clinical course of MRSA endocarditis cannot be ruled out, it is tempting to assume that the administration of diclofenac facilitated the development of these devastating complications. This assumption is based on the very short preceding period of symptoms of infection, on the temporal association of

simultaneous multifocal intracranial bleeding preceded by the administration of the drug, and particularly on the well-documented capacity of NSAIDs to predispose to haemorrhagic stroke irrespective of IE.

CONCLUSION

The possible amplification of bleeding risk by the administration of NSAIDs in the set-up of disseminated and untreated MRSA infective cerebral arteritis is suggested. Intracranial haemorrhage in the set-up of undiagnosed IE might be added to the long list of potential adverse outcomes of NSAID administration, and the possibility of IE should be considered before their administration for febrile disease of undetermined cause.

REFERENCES

1. Islam MM, Poly TN, Walther BA, Yang HC, Lin MC, Li M-C. Risk of hemorrhagic stroke in patients exposed to nonsteroidal anti-inflammatory drugs: a meta-analysis of observational studies. *Neuroepidemiology* 2018;**51**:166–176.
2. Wang H-C, Su Y-C, Luk H-N, Wang JH, Hsu C-Y, Lin S-Z. Increased risk of strokes in patients with chronic low back pain (CLBP): a nationwide population-based cohort study. *Clin Neural Neurosurg* 2020;**192**:105725.
3. Wen Y-C, Hesiao F-Y, Lin Z-F, Fang C-C, Shen L-J. Risk of stroke associated with use of nonsteroidal anti-inflammatory drugs during acute respiratory infection episode. *Pharmacoepidemiol Drug Saf* 2018;**27**:645–651.
4. Lin J, Han Z, Yi X, Luo H, Zhou Q, Zhou J. Prestroke aspirin use is associated with clinical outcomes in ischemic stroke patients with atherothrombosis, small artery disease, and cardioembolic stroke. *J Atheroscler Thromb* 2019;**26**:528–537.
5. Ungprasert P, Matteson EL, Thongprayoon C. Nonaspirin nonsteroidal anti-inflammatory drugs and risk of hemorrhagic stroke: a systematic review and meta-analysis of observational studies. *Stroke* 2016;**47**:356–364.
6. Kornowski R, Pines A, Levo Y. Ischemic stroke following an intramuscular injection of diclofenac. Case report. *Angiology* 1995;**46**:1145–1147.
7. Anavekar NS, Tleyjeh IM, Anavekar NS, Mirzoyev Z, Steckelberg JM, Haddad C, et al. Impact of prior antiplatelet therapy on risk of embolism in infective endocarditis. *Clin Infect Dis* 2007;**44**:1180–1186.
8. Taha TH, Durrant SS, Mazeika PK, Nihoyannopoulos P, Oakley CM. Aspirin to prevent growth of vegetations and cerebral emboli in infective endocarditis. *J Intern Med* 1992;**231**:543–546.
9. Hart RG, Foster JW, Luther MF, Kanter MC. Stroke in infective endocarditis. *Stroke* 1990;**21**:695–700.
10. Cao G-F, Liu W, Bi Q. Stroke in patients with infective endocarditis: a 15-year single-center cohort study. *Eur Neurol* 2018;**80**:171–178.
11. Okazaki S, Sakaguchi M, Hyun B, Nagano K, Tagaya M, Sakata Y, et al. Cerebral microbleeds predict impending intracranial hemorrhage in infective endocarditis. *Cerebrovasc Dis* 2011;**32**:483–488.
12. Masuda J, Yutani C, Waki R, Ogata J, Kuriyama Y, Yamaguchi T. Histopathological analysis of the mechanisms of intracranial hemorrhage complicating infective endocarditis. *Stroke* 1992;**23**:843–850.
13. Marquardt RJ, Cho S-M, Thatikunta P, Deshpande A, Wisco D, Uchino K. Acute ischemic stroke therapy in infective endocarditis: case series and systematic review. *J Stroke Cerebrovasc Dis* 2019;**28**:2207–2212.
14. Maeoka R, Nakagawa I, Ohnishi H, Takahashi K, Nakase H, Ohnishi H. Catastrophic multiple microbleeds caused by infective endocarditis following intravenous thrombolysis and endovascular thrombectomy. *J Stroke Cerebrovasc Dis* 2019;**28**:e123–e125.
15. Bhuvu P, Kuo S-H, Hemphill JC, Lopez GA. Intracranial hemorrhage following thrombolytic use for stroke caused by infective endocarditis. *Neurocrit Care* 2010;**12**:79–82.