

Case Report

Multi-modal approach in management of vulvo-vaginal gingival syndrome — a rare variant of oral lichen planus

Shwetha V. *, Sujatha S., Rakesh N., Pavan T., Pooja Rathore

Department of Oral Medicine and Radiology, Faculty of Dental Sciences, Ramaiah University of Applied Sciences, Bangalore, Karnataka, India

(Received: 15 November 2022, accepted: 17 July 2023)

Keywords:
vulvo-vaginal
gingival syndrome /
Atrophic oral lichen
planus /
autoimmune /
photodynamic
therapy /
corticosteroids /
methylene blue

Abstract – Lichen planus (LP) is a chronic autoimmune relapsing mucocutaneous disease that significantly affects the patient's quality of life (QoL) and is associated with several etiological factors. Vulvo-vaginal gingival syndrome (VVGs) is characterized as a clinical triad of gingival, vaginal and vulval LP. In previous literature, it has been described as a distinctive pattern of erosive plurimucosal LP. This condition if progressed can lead to multiple complications such as urethral and vaginal stenosis. This case report highlights the management of VVGs using a multidisciplinary strategy that includes dermatological consultation, oral hygiene maintenance, topical steroid application using custom-made trays and photodynamic therapy.

Introduction

Lichen planus (LP) is a chronic inflammatory and immune mediated disease that affects the skin, nails, hair, and mucous membranes. LP can involve the skin or mucous membranes including the oral, vulvovaginal, oesophageal, laryngeal, and conjunctival mucosa. Cutaneous Lichen planus (CLP) most commonly involves the flexor surfaces of the extremities and presents as small itchy violaceous papules in middle-aged adults [1].

Mucosal involvement is usually characterized by oral mucosal lesions and involvement of other mucosal surfaces such as vulvovaginal region is rare and may also be challenging to manage. Based on the clinical presentation of the lesions, Oral LP is classified into six clinical subtypes. The presence of erosive LP of the vulva and vagina with desquamative gingivitis (DG) has been described as VVGs or Hewitt-Pelisse Syndrome and there are only a few case reports regarding this rare syndrome in the literature [2]. In 1937, Guogerot and Burnier described the coexistence of oral, cervical, and stomach LP lesions with no cutaneous involvement as "plurimucosal LP". In 1982, Pelisse and colleagues reintroduced a similar variant of mucosal LP as VVGs with erosive lesions involving the oral and vulvovaginal mucosa [1,2]. It is considered as a clinical triad of

vulval, vaginal, and gingival lichen planus (LP) and can have significant negative impact on QoL ultimately leading to complications like urethral and vaginal stenosis [3].

The worsening of mucosal lesions could impact on regional functions such as opening of the mouth, dysurea, dyspareunia, postcoital bleeding and increased risk of malignant change in long time duration.

Though the working diagnosis can be easily made based upon the clinical presentation of the lesions, final diagnosis can be confirmed with histopathological examination. Several antigen-specific and nonspecific inflammatory pathways have been proposed to explain the pathogenesis. In nature, CD8+ T lymphocytes promote the death of oral epithelial cells at the basal layer, involving keratinocyte antigen expression and antigen unmasking in the disease mechanism [4].

Systemic and local corticosteroids, LASER therapy, surgery, and other treatments are available for these lesions [5]. Corticosteroids, on the other hand, have been linked to candidiasis, mucosal atrophy, stomach issues, hypertension, adrenal insufficiency, and diabetes over long periods of time [6]. Photodynamic therapy (PDT) can alleviate many of the clinical effects that have not yet been discovered. PDT is a clinically successful therapeutic modality for OLP and can also be used as an alternative management strategy for VVGs [7]. Cellular degradation, membrane lysis, and protein inactivation are the primary effects of PDT. The effectiveness of PDT depends

* Correspondence: shwetha.vg@gmail.com

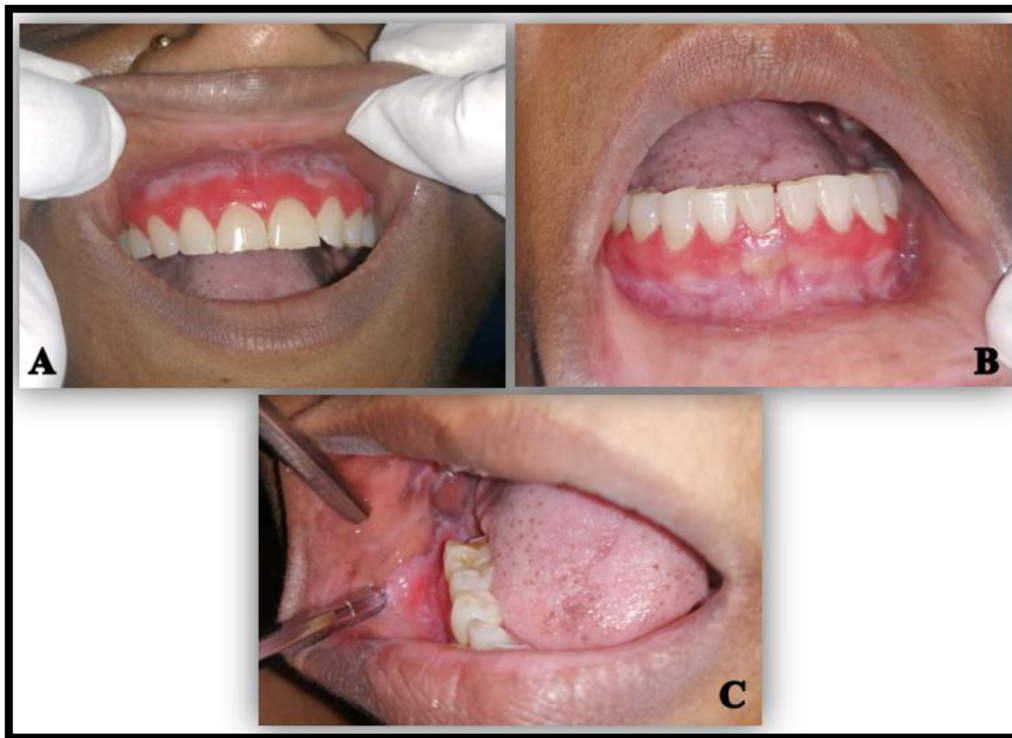


Fig. 1. (A–C) Intraoral pictures at first visit [preoperative] of the patient representing the erythematous areas in relation to maxillary and mandibular gingival region and erythematous areas intermingled with reticular pattern in relation to right buccal mucosa.

on the type of photosensitizer (PS) used. The type of PS used or the impact of confounding factors like the location of the lesion, the wavelength, or the duration of the irradiation on therapeutic responses have not been clarified even though numerous studies have examined the effectiveness of PDT. Additionally, it is unclear whether methylene blue (MB) is effective in the management of these lesions [7]. Surgery is usually reserved for the removal of high-risk dysplastic regions [6]. Reticular type of OLP has a better prognosis when compared to erosive and atrophic variants [8]. This paper reports a case of oral lichen planus with cutaneous and vaginal involvement representing VVGS treated with the multimodal management approach.

Case report

A female patient aged 51 years, reported to the outpatient department of Oral Medicine and Radiology with the chief complaint of pain and burning sensation while eating hot and spicy food in her mouth for the past 6 months. She was consuming fish oil and multivitamins for the past few years with no relevant medical history. She also gave history of hair dye application once in four to five months. Visual Analogue Scale (VAS) score of 9 for pain and 6 for burning sensation was given by the patient. The Hospital Anxiety and Depression Scale was calculated as 4 indicating the normal score.

Extraoral examination revealed presence of small itchy violaceous papules on lower extremities and genital areas. Intraoral examination revealed generalised erythematous and oedematous areas on marginal, attached and interdental gingiva (Fig. 1). Also, multiple irregular white striae intermingled with the erythematous areas were seen on right and left buccal mucosa representing the classic sign of OLP, *i.e.*, Wickham's striae. The lesion was tender on palpation and non-scrapable. Based on the oral findings, a provisional diagnosis of Oral Lichen Planus (Atrophic or Erythematous type) on right and left buccal mucosa with desquamative gingivitis (DG) was given. A differential diagnosis of atrophic candidiasis and pemphigus vulgaris was given. The patient was referred for dermatological consultation for the review of cutaneous lesions where a provisional diagnosis of VVGS was given. Patient was advised to undergo routine blood investigations, exfoliative cytology and oral incisional biopsy for confirmatory diagnosis.

Blood investigations revealed the values within the normal range and exfoliative cytology was negative for oral candidiasis. Oral punch biopsy revealed the histopathological findings as atrophic hyper-parakeratotic stratified squamous epithelium with basal cell degeneration and no dysplastic features within the cells (Fig. 2). A final diagnosis of OLP, reticular type on right and left buccal mucosa and atrophic type on upper and lower marginal and attached gingiva was recorded. To eliminate the intraoral local factors, oral prophylaxis with the stoppage of consumption of fish oil was advised before commencement of the

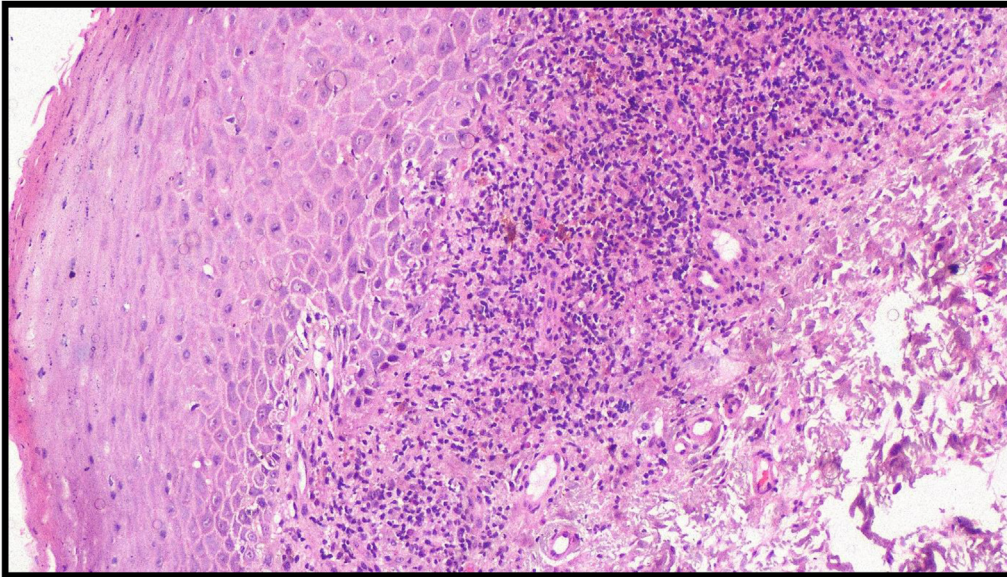


Fig. 2. Microscopic image showing an atrophic hyper-parakeratotic stratified squamous epithelium with basal cell degeneration and no dysplastic features within the cells.

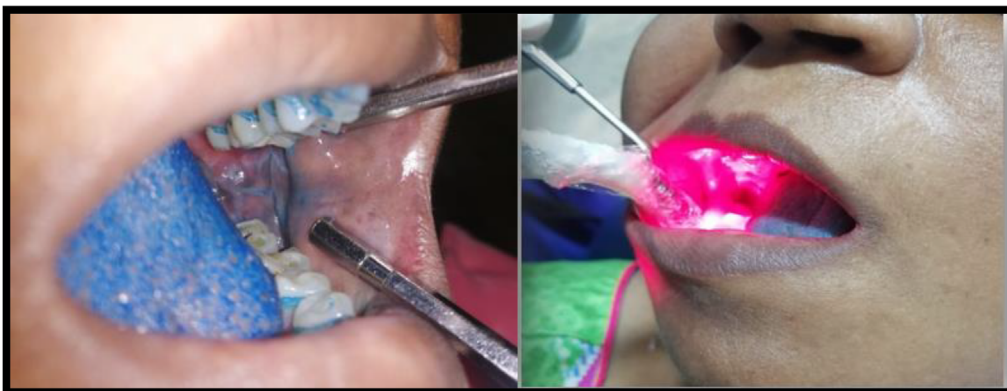


Fig. 3. Photo-dynamic therapy (PDT). Methylene blue 0.01% was applied onto the lesional areas and low-level LASER therapy was given for approximately 2 min per lesional site.

steroid therapy and at regular intervals with TESS ointment (triamcinolone acetonide buccal paste 0.1% w/w) and Betnesol® (Betamethasone sodium phosphate tablet 0.5 mg) (crush and swish) was advised to be used 4 times a day for 1 week.

Since photo-dynamic therapy (PDT) has shown promising results in the management of oral mucosal lesions [9] the patient was advised with the regular sessions of the same. PDT involves the use of a photosensitizer and a light source of specific wavelength. In our case, low-level LASER therapy (LLLT) at a wavelength of 660nm with methylene blue (MB) (0.02%) as a photosensitizer was used. A total of 10 sessions was given where MB was applied onto the lesional areas for 7–10 min followed with LLLT (Fig. 3) for 4 min per lesional site at 660 nm delivering energy of approximately 24 J/cm². In addition, to promote the healing, Vitamin-E application was

done onto the erythematous/lesional areas after the completion of session and was left for 30 min. For the vulval and cutaneous lesions, patient was prescribed with fluticasone skin cream 0.05% w/w and hydroxy-chloroquines (HCQs) 20 mg, twice a day for 30 days from the department of dermatology.

After 2 weeks of follow-up, though there was a significant reduction in the vaginal and cutaneous lesions but, no improvement in the VAS score was noted intraorally. Hence, a customized gingival tray was fabricated for the gingival region such as to increase the duration of action and the contact time of topical steroid intraorally. Regular follow-up was done for 4 months with significant reduction in VAS score of 3 for pain and 2 for burning sensation indicating the remarkable results (Fig. 4).

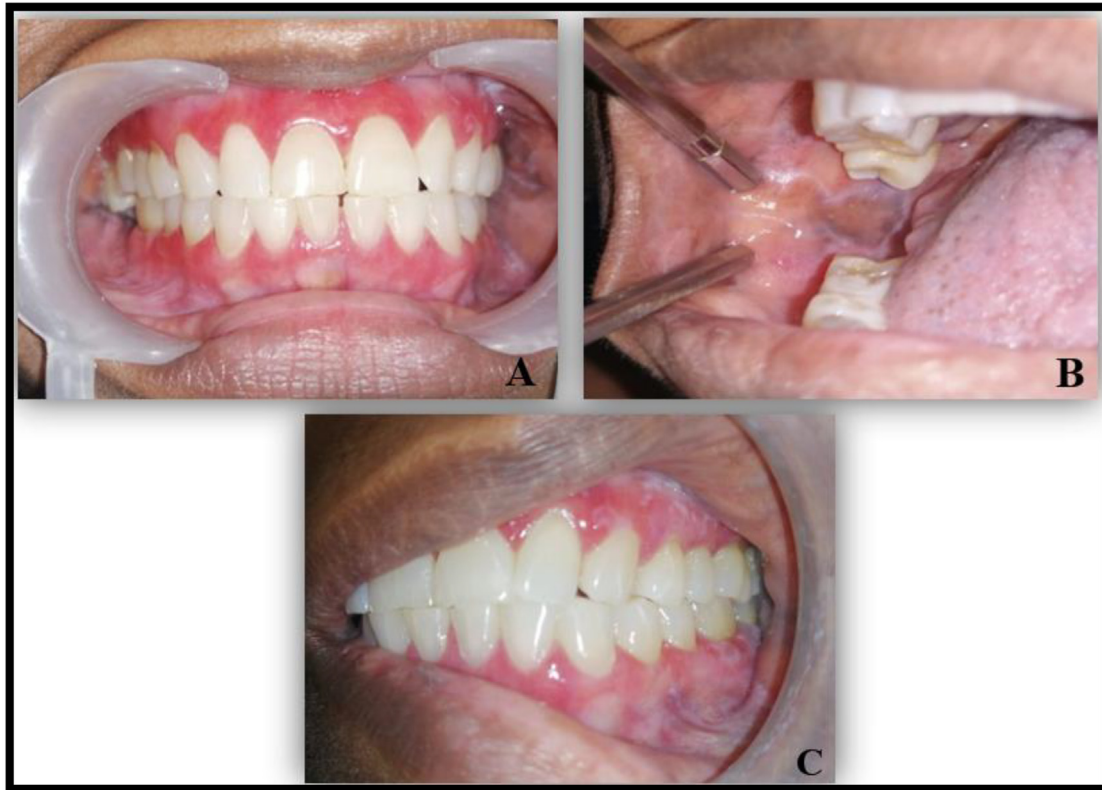

Fig. 4. (A–C) Intraoral pictures at the end of 4 months of follow-up [postoperative] of the patient representing the significant reduction in the erythematous areas in relation to maxillary and mandibular marginal and attached gingiva and erythematous areas and in relation to right buccal mucosa.

Discussion

VVGS is a rare variant of oral and vaginal lichen planus. In a retrospective study by Micheletti *et al.*, (2000), the frequency of vulval LP was found to be 3.7% in the population. These OLP forms are often resistant to treatment and have a higher tendency for malignant transformation ranging between 0.5 and 5% [10]. The early diagnosis and management of such lesions could go a long way in improving the quality of life of these patients.

In our case, the cutaneous and vaginal lesions were also managed alongside the oral lesions. Since the oral lesions were more severe, the customised tray was fabricated for the delivery of the medicine and PDT was advised to the patient. PDT includes the interaction of a light source with a chemical dye or photosensitizer in the presence of oxygen. As a result of this interaction, reactive oxygen species are formed, causing oxidative damage to microbial cell walls as well as pre-malignant and malignant cells [9,10]. This helps in reduction in the size of the lesion as well as induction of local and systemic anti-inflammatory effects [11]. According to a study by Sadaksharam *et al.*, Methylene Blue (MB) mediated PDT was used in 20 oral lichen planus patients and significant reduction in sign and symptoms were noted after 4th week follow-up

[12]. MB is a cationic heterocyclic aromatic chemical compound (methylthioninium chloride) that has been used for more than 130 years in medicine as a vital dye with very low tissue toxicity. Several studies have been conducted on the effectiveness of MB as a photosensitizer in lesions like oral lichen planus. Since PDT is safe, convenient, non-invasive and does not cause scarring, it can be used alone or in conjunction with other treatment modalities. Use of MB as a topical medication has been demonstrated to be helpful in the management of persistent oral pain from mucositis in cancer patients. After being used safely in this group of patients, it plays a highly encouraging function in the treatment of chronic pain [13,14]. Thus, combining topical therapy with custom-made trays, PDT for the oral lesions and systemic therapy for the cutaneous lesions brought about a significant improvement in the patient QoL in our case.

The major challenge in the management of OLP is relapse and recalcitrant nature of the lesion. Along with the other treatment strategies, local factors also play a major role in the management of such type of lesions. Oral hygiene maintenance is of utmost important including the regular prophylaxis to ensure the penetration of the medication effectively. In our case report, regular follow-up of the patient was maintained and no major adverse effects were noted.

Conclusion

The use of a multimodal approach in the management of VVGS with significant oral-mucosal lesions has been linked to a remarkable improvement in patient QoL [15]. Though treating erythematous lesions might be difficult, a combination therapy such as topical therapy with custom-made trays and PDT can be employed to control these problems. Local aggravating variables can be reduced significantly with supportive and conservative treatment. Dermatological approach should be employed for the cutaneous lesions with concurrent management of oral health. For the better treatment outcomes, multidisciplinary approach should be applied on the patients instead of following one line of management. Because OLP has a higher risk of recurrence and malignant transformation, patients must be monitored and maintained on a frequent basis.

Conflict of Interest

There are no conflicts of interest.

Funding

The authors declare that no funding was received.

Ethical approval

The authors declare that ethical approval was not required.

Informed Consent

Patient's consent was taken before presenting the case report and intraoral pictures. Patient was not willing to share the pictures of cutaneous lesions.

Authors contribution

Shwetha V.: Conceptualization, Methodology, writing original draft
Sujatha S.: Supervision and editing, Rakesh N.: Reviewing and editing, Pavan T: Reviewing and editing., Pooja Rathore: Writing draft and editing.

References

1. Gorouhi F, Davari P, Fazel N. Cutaneous and mucosal lichen planus: a comprehensive review of clinical subtypes, risk factors, diagnosis, and prognosis. *Scientific World J* 2014;1–22.
2. Sharma N, Malhotra SK, Kuthial M, Chahal KS. Vulvo-vaginal anogingival syndrome: Another variant of mucosal lichen planus. *Indian J Sex Transm Dis AIDS*. 2017;8:86–88.
3. Pelisse M, Leibowitch M, Sedel D, Hewitt J. Un nouveau syndrome vulvo-vagino-gingival. Lichen plan érosif plurimuqueux [A new vulvovagino-gingival syndrome. Plurimucous erosive lichen planus. *Ann Dermatol Venereol* 1982;109:797–798.
4. Eversole LR. Immunopathogenesis of oral lichen planus and recurrent aphthous stomatitis. *Semin Cutan Med Surg* 1997;16:284–294.
5. Saheb JM, Arbabi KF. Management of oral lichen planus.
6. Gupta S, Jawanda MK. Oral lichen planus: an update on etiology, pathogenesis, clinical presentation, diagnosis and management. *Indian J Dermatol* 2015;60:222–229.
7. Waingade M, Medikeri RS, Rathod P. Effectiveness of methylene blue photosensitizers compared to that of corticosteroids in the management of oral lichen planus: a systematic review and meta-analysis. *J Dent Anesth Pain Med* 2022;22:175–186.
8. Lavanya N, Jayanthi P, Rao UK, Ranganathan K. Oral lichen planus: an update on pathogenesis and treatment. *J Oral MaxillofacPathol* 2011;15:127–132.
9. Choudhary R, Reddy SS, Nagi R, Nagaraju R, Kunjumon SP, Sen R. The effect of photodynamic therapy on oral-premalignant lesions: a systematic review. *J Clin Exp Dent* 2022;14:e285–e292.
10. Cosgarea R, Pollmann R, Sharif J, Schmidt T, Stein R, Bodea A, Auschill T, Sculean A, Eming R, Greene B, Hertl M, Arweiler N. Photodynamic therapy in oral lichen planus: a prospective case-controlled pilot study. *Sci Rep* 2020;10:1667.
11. Mostafa D, Tarakji B. Photodynamic therapy in treatment of oral lichen planus. *J Clin Med Res* 2015;7:393–399.
12. Sadaksharam J, Nayaki KP, Selvam NP. Treatment of oral lichen planus with methylene blue mediated photodynamic therapy—a clinical study. *Photodermatol Photoimmunol Photomed* 2012;28:97–101.
13. Lecor PA, Touré B, Moreau N, Braud A, Dieb W, Boucher Y. Could methylene blue be used to manage burning mouth syndrome? A pilot case series. *J Oral Med Oral Surg* 2020;26:35–41
14. Roldan CJ, Nouri K, Chai T, Huh B. Methylene blue for the treatment of intractable pain associated with oral mucositis. *Pain Pract* 2017;17:1115–1121.
15. Gougerot H, Burnier R. Lichen plan du col uterin, accompagnant un lichen plan jugal et un lichen plan stomacal: lichen plurimuqueux sans lichen cutane. *Bull Soc Française Dermatol Syphiligr* 1937;44:637–640.